

# UC Davis

## Dermatology Online Journal

### Title

Precalcaneal congenital fibrolipomatous hamartoma

### Permalink

<https://escholarship.org/uc/item/00q4s69z>

### Journal

Dermatology Online Journal, 24(1)

### Authors

Hafez, Dhafer  
Almasoudi, Ashjan  
Al Assiri, Waleed  
et al.

### Publication Date

2018

### DOI

10.5070/D3241037967

### Copyright Information

Copyright 2018 by the author(s). This work is made available under the terms of a Creative Commons Attribution-NonCommercial-NoDerivatives License, available at <https://creativecommons.org/licenses/by-nc-nd/4.0/>

Peer reviewed

# Precalcaneal congenital fibrolipomatous hamartoma

Dhafer Hafez<sup>1</sup> MD, Ashjan Almasoudi<sup>1</sup> MD, Waleed Al Assiri<sup>2</sup> MD, Maha Alassmi<sup>1</sup> MD, Najla A Al-Dawsari<sup>3</sup> MD FAAD

Affiliations: <sup>1</sup>Department of Dermatology, Aseer Central Hospital, Abha, Saudi Arabia, <sup>2</sup>Department of Pediatrics, Aseer Central Hospital, Abha, Saudi Arabia, <sup>3</sup>Department of Dermatology, Johns Hopkins Aramco Health Care, Dhahran, Saudi Arabia

Corresponding Author: Dhafer Hafez MD, Aseer Central Hospital Saudi Arabia, Al Rabwah, 7745 Al Amir Sultan Ibn Abdul Aziz, Abha 62523, Saudi Arabia, Email: Hafez73@hotmail.com

## Abstract

Precalcaneal congenital fibrolipomatous hamartoma is a benign condition of infancy that is sometimes misdiagnosed due to lack of reports in the literature. Lesions usually present with painless, non-pruritic, skin colored bilateral, solitary, symmetric nodules located in the middle of the heels. The lesions gradually increase in size and then regress by the age of 2 to 3 years old.

*Keywords: precalcaneal, congenital, fibrolipomatous, hamartoma, dermatology, pediatric*

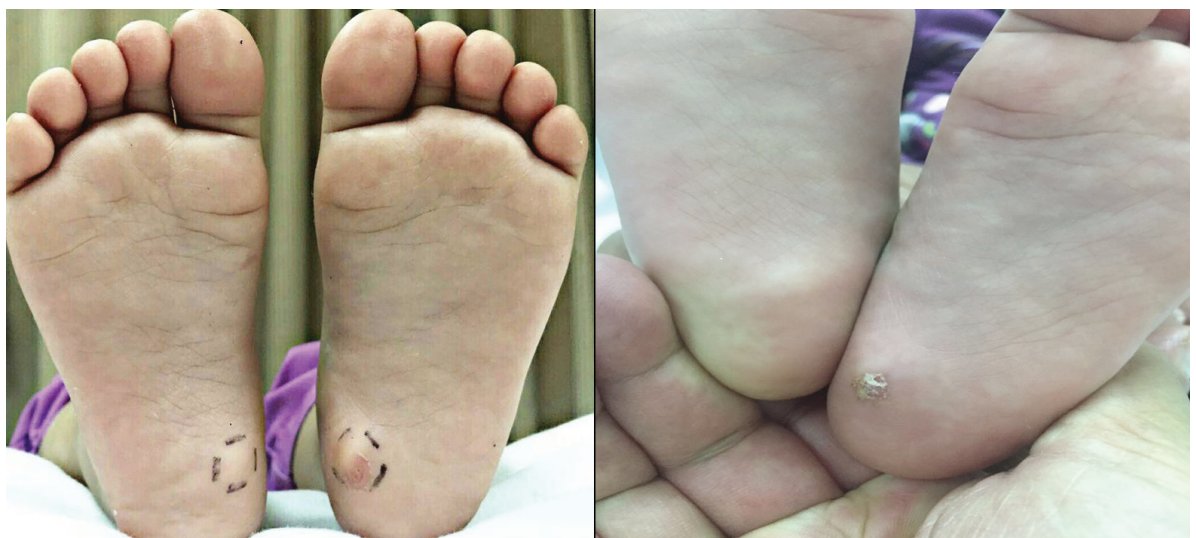## Introduction

Pericalcaneal congenital fibrolipomatous hamartoma (PCFH) was first described in 1990 by Larralde de Luna et al. [1] and the name "pedal papules in the newborn" was given. Other names for PCFH include bilateral congenital adipose plantar nodules [2], benign anteromedial plantar nodules of childhood [3], bilateral congenital fatty heel pad [4], and

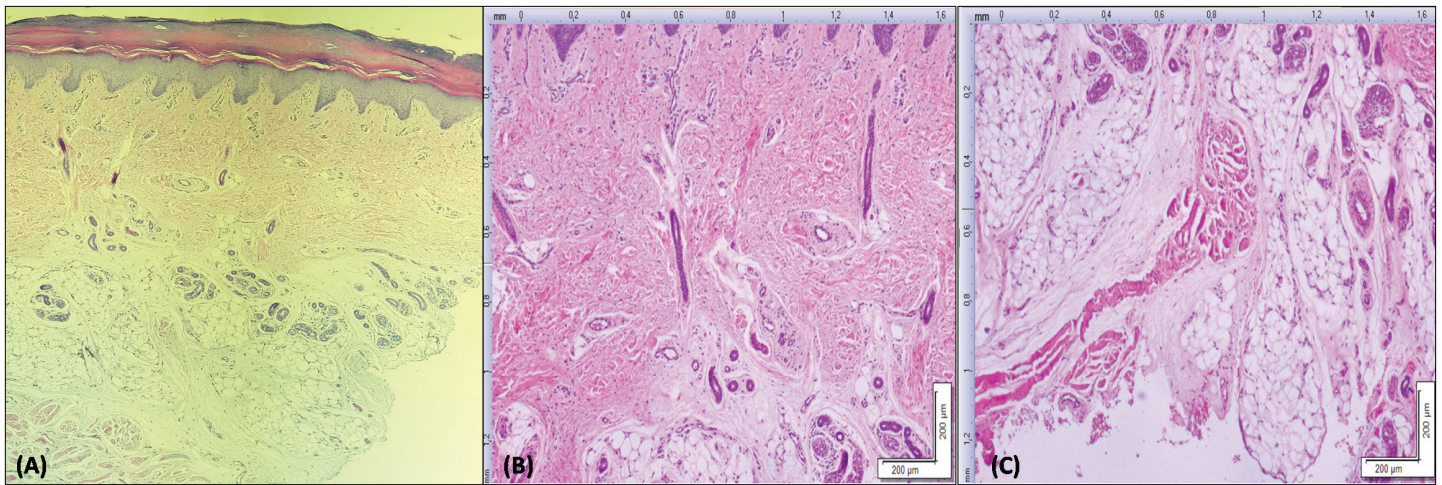
hypertrophic infantile pedal papule [5]. PCFH is characterized clinically by painless, non-pruritic, skin colored bilateral, solitary, symmetric nodules located in the middle of the heels with an average diameter of 1 cm. These nodules tend to increase in size along with the growth of the child and frequently regress at the age of 2 to 3 years [6, 7]. Malignant change or gait disturbance are not reported to be features of PCFH [1].

## Case Synopsis

A 14-month-old healthy full-term girl born to consanguineous parents and a product of normal spontaneous vaginal delivery following an uncomplicated pregnancy presented to the dermatology clinic with her parents who were concerned about an asymptomatic swelling noticed in her heels bilaterally since birth. The swelling was not associated with pain, itching, discomfort,



**Figure 1.** Solitary bilateral skin colored soft mobile sub-cutaneous nodules (1x1cm in left foot and 0.5x0.3cm in right foot). Left foot showing site of biopsy after suture removal.



**Figure 2.** A) H&E demonstrating hyperkeratosis, multiple lobules of mature adipose tissues slightly protruding into the dermis, 4%. B) H&E demonstrating multiple lobules of mature adipose tissues slightly protruding into the dermis, 10%. C) H&E demonstrating mature adipocytes separated by collagenous fibrous tissues, 10%.

discharge, or gait disturbance. Systemic review along with pre-natal, natal, and post-natal history was unremarkable. Her development was proportional to her age and her vaccinations were up to date. There were no family members with similar lesions.

On physical examination, she was found to have solitary bilateral skin colored soft mobile non tender sub-cutaneous nodules (1x1cm in left foot and 0.5x0.3cm in right foot), **Figure 1**. Full skin examination showed no other suspicious lesions. Lymph node examination was normal. There were no nail or dental abnormalities.

Histologic examination of one of the nodules showed hyperkeratosis, normal appearing dermis with thickness of 1.2 mm (normal dermal thickness of soles ~1.5mm), [8]. The subcutaneous layer showed compact collagenous fibrous tissue surrounding well defined mature lobules of adipose tissue with slight protrusion to the dermis.

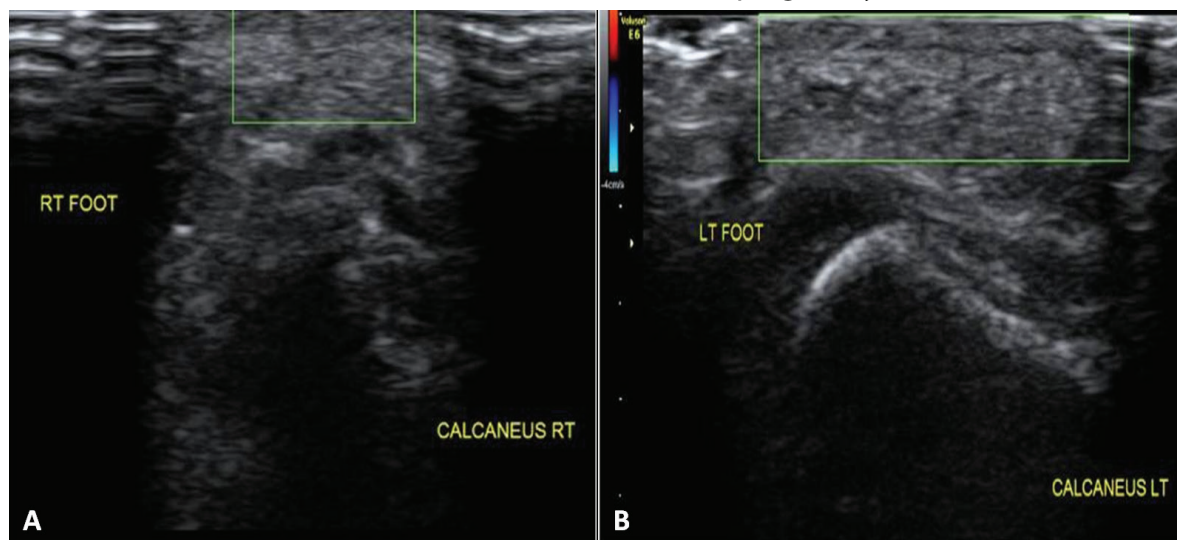
Ultrasound examination showed an ill-defined homogenous,

hyperechoic subcutaneous lesion in the planter aspect of the heel with lack of vascularity (**Figure 3**)

### Discussion

Larralde de Luna et al. reported 4 similar cases known as adult piezogenic papules. However, the adult-type piezogenic pedal papules consist of fat herniation through a defect in the dermis apparent only when individuals stand upright [5, 6].

The mechanism of developing a PCFH is unclear, but there have been three hypotheses. The first hypothesis suggests that PCFH is related to incomplete regression of fetal tissue. The fibro-connective trabecular system of the sole develops in the fetal stage and is completely formed during the last months of pregnancy or in the first months



**Figure 3.** A) Ultrasound of the right foot (green square) showing hyperechoic non vascular subcutaneous lesion B) Ultrasound of the left foot showing same findings as right foot.

after birth [1]. The second hypothesis is that PCFH is caused by fat herniation through defects in the plantar fascia [9]. The third hypothesis is the presence of an underlying genetic defect caused by an autosomal dominant or X-linked inheritance [10, 11]. Histologically lesions show the presence of mature adipose tissue enveloped in predominantly collagen-fibrous sheaths extending to the mid- and reticular dermis. It may also show an increased number of blood vessels without associated perivascular alterations [9, 12]. Nerve fibers and fibrous tissue appear normal in size and number [6]. Since the majority of such lesions regress over time [6, 7], this might explain the near to normal skin histopathology of our 14-month-old patient. A matched control could have aided our evaluation. Ultrasound imaging may show an ill-defined, homogeneous, hyperechoic lesion near the subcutaneous layer [10]. Fat is known to be hyperechoic on ultrasound examination [13, 14]. PCFH is underreported in the literature and thus under recognized [15]. The differential diagnosis for PCFH includes: juvenile fibromatosis, particularly childhood fibrous hamartoma, plantar aponeurotic fibroma, adult-type piezogenic papules, nevus lipomatosus, connective-tissue nevus, and focal dermal hypoplasia [6, 9, 15]

## Conclusion

Precalcaneal congenital fibrolipomatous hamartoma is a benign condition of infancy which can be misdiagnosed owing to lack of reports in the literature. With age the lesions may regress. The diagnosis is made clinically. Histopathology and ultrasound may aid the diagnosis if obtained at an early age. No treatment is required, but surgical excision can be performed if lesions persist or are symptomatic, but since spontaneous regression is the likely result, observation is prudent.

## References

1. Larralde de Luna M, Ruiz Leon J, Cabrera HN. Pedal papules in newborn infants. *Med Cutan Ibero Lat Am*. 1990;18:9-12. [PMID: 2214934]
2. Espana A, Pujol RM, Idoate MA, Vazquez-Doval J, Romani J. Bilateral congenital adipose plantar nodules. *Br J Dermatol*. 2000;142:1262-1264. [PMID: 10848775].
3. Jacob CI, Kumm RC. Benign anteromedial plantar nodules of childhood: a distinct form of plantar fibromatosis. *Pediatr Dermatol*. 2000;17:472-474. [PMID: 11123783].
4. Livingstone JA, Burd DA. Bilateral congenital fatty heel pads. *Br J Plast Surg*. 1995;48:252-253. [PMID: 7640861].
5. Conde-Taboada A, Mayo E, Gonzalez B, Pardavila R, De la Torre C,

6. Cruces M. Hypertrophic infantile pedal papules. *Pediatr Dermatol*. 2007;24:339-340. [PMID: 17542904].
6. Semadeni BL, Mainetti C, Itin P, Lautenschlager S. Precalcaneal congenital fibrolipomatous hamartomas: report of 3 additional cases and discussion of the differential diagnosis. *Dermatology*. 2009;218:260-264. [PMID: 19155614].
7. Corella F, Dalmau J, Garcia Muret MP, Baselga E, Alomar A. Precalcaneal congenital fibrolipomatous hamartoma: a discussion of two cases. *Int J Dermatol*. 2007;46:947-949. [PMID: 17822498].
8. Burns DA, Breathnach SM, Cox N, Griffiths CE, eds. *Rook's Textbook of Dermatology*. 7th ed. Malden, Mass: Blackwell Science; 2004.
9. Ortega-Monzo C, Molina-Gallardo I, Monteagudo-Castro C, Carda-Batalla C, Pinazo-Canales I, Smith-Ferres V, et al. Precalcaneal congenital fibrolipomatous hamartoma: a report of four cases. *Pediatr Dermatol*. 2000;17:429-431. [PMID: 17822498].
10. Fangman WL, Prose NS. Precalcaneal congenital fibrolipomatous hamartomas: report of occurrence in half brothers. *Pediatr Dermatol*. 2004;21:655-656. [PMID: 15575850].
11. Yang JH1, Park OJ, Kim JE, Won CH, Chang SE, Lee MW, Choi JH, Moon KC. Precalcaneal congenital fibrolipomatous hamartoma. *Ann Dermatol*. 2011;23:92-94. [PMID: 21738373].
12. Chiaradia G, Fiss RC, Silva CM, Kiszewski AE. Precalcaneal congenital fibrolipomatous hamartoma: report of 2 cases. *J Pediatr Surg*. 2011;46:e11-12. [PMID: 21376179].
13. Behan M, Kazam E. The echographic characteristics of fatty tissues and tumors. *Radiology*. 1978 Oct;129(1):143-51. [PMID: 693867].
14. Wagner JM1, Lee KS, Rosas H, Kliewer MA. Accuracy of sonographic diagnosis of superficial masses. *J Ultrasound Med* 2013; 32: 1443-1450. [PMID: 23887955].
15. Greenberg S, Krafchik BR. Infantile pedal papules. *J Am Acad Dermatol*. 2005;53:333-334. [PMID: 16021133].