

UC Davis

Dermatology Online Journal

Title

Secondary mucinous carcinoma of the skin

Permalink

<https://escholarship.org/uc/item/0398x9qg>

Journal

Dermatology Online Journal, 20(4)

Authors

Frances, Laura
Cuesta, Laura
Leiva-Salinas, Maria
et al.

Publication Date

2014

DOI

10.5070/D3204022361

Copyright Information

Copyright 2014 by the author(s). This work is made available under the terms of a Creative Commons Attribution-NonCommercial-NoDerivatives License, available at <https://creativecommons.org/licenses/by-nc-nd/4.0/>

Peer reviewed

Case Presentation

Secondary mucinous carcinoma of the skin

Laura Frances, Laura Cuesta, Maria Leiva-Salinas, Jose Bañuls

Dermatology Online Journal 20 (4): 10

Hospital General Universitario de Alicante

Correspondence:

Laura Frances
Hospital General Universitario de Alicante
frances.rodriquez.laura@gmail.com

Abstract

We report a case of a woman who presented with a cystic-appearing nodule on her left nipple. After cutaneous biopsy and gynecological staging study, she was diagnosed with skin invasion of mucinous carcinoma of the breast. We describe the main features of this rare tumor and the controversies in its diagnosis because primary and metastatic mucinous carcinomas in skin are histologically indistinguishable.

Introduction

Mucinous carcinoma of the breast accounts for approximately 1.5-5% of all primary breast malignancies and it is usually seen in elderly patients. It is generally associated with a good prognosis, better than other breast neoplasms. The 10-year survival rate is 90 to 100% for the pure type (mucinous areas comprise more than 90% of the neoplasm) and about 60% for the mixed type (invasive ductal component of usual type in addition to the mucinous pattern) [1,2]. The skin is an unusual site of metastatic involvement of mucinous adenocarcinoma of the breast (called secondary mucinous carcinoma of skin) [3]. Usually, this infrequent cutaneous extension occurs in very advanced stages of the disease and may represent a diagnostic challenge when the primary neoplasm is unknown, because it may be easily confused with primary mucinous carcinoma of the skin (mucinous eccrine carcinoma); both show identical clinical and histological features.

Case synopsis

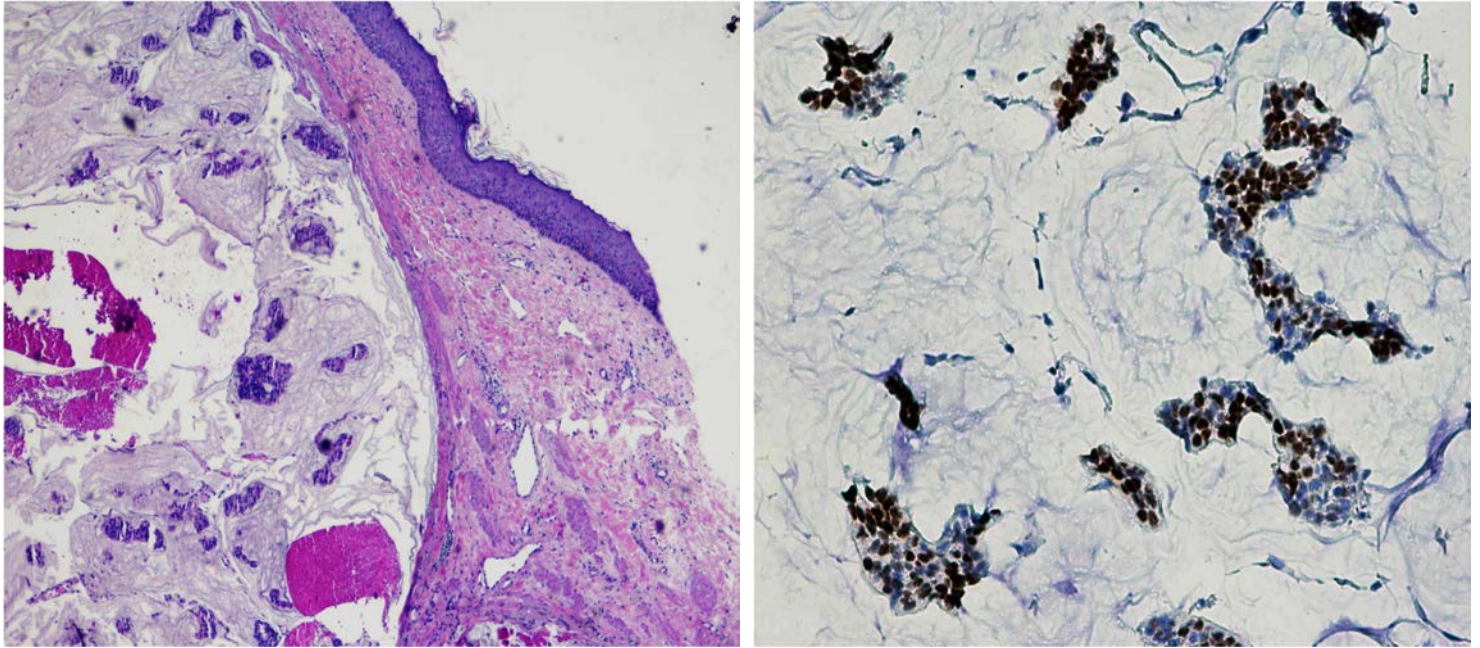
An 88-year-old woman presented with a 1-year history of a slowly enlarging tumor at the left nipple. The patient's medical history was significant for hypertension, type 2 diabetes, and bronchial carcinoid tumor surgically treated.

The patient was found to have a 3cm x 3cm soft, sessile, multilobulated polychrome nodule on her left nipple (Figure 1). It was asymptomatic and other skin lesions or axillar lymphadenopathy were not observed. She was otherwise well and reported no history of weight loss, loss of appetite, fever, or altered bowel habits.

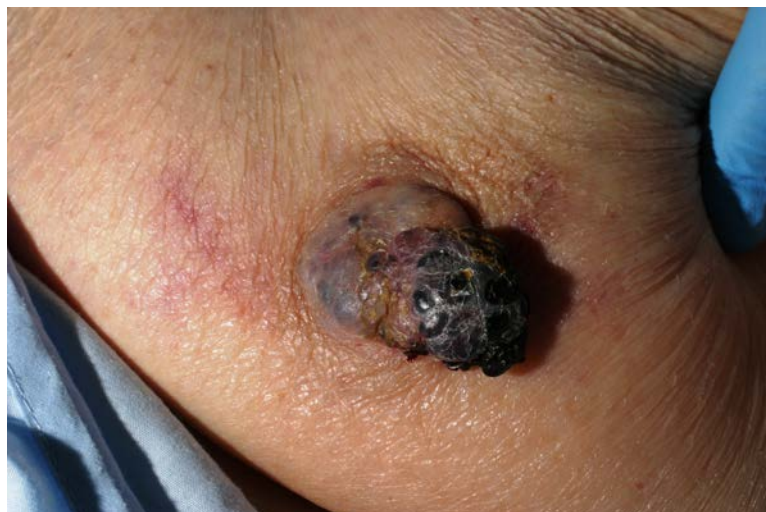

Figure 1. Nipple tumor

A punch biopsy was performed and it showed islands of epithelial basaloid cells with some mitosis within pools of mucin (Figure 2), separated by strands of fibrous tissue. Immunohistochemically the tumor was positive for estrogen receptors (60%) (Figure 3), Bcl-2 protein, and e-cadherina. It was negative for HER-2 receptor status, p63, and CK5-6. The Ki-67 index was low (8%).



Figures 2 and 3. Islands of epithelial basaloid cells with some mitosis within pools of mucin (H&E x10). The tumor was positive for estrogen receptors (H&E x40).

The patient was referred for further investigation to the Breast Pathology Unit. A chest radiography showed a left breast tumor underlying the skin nodule without any finding of chest wall or axillary lymph node invasion. Because of the patient's age and comorbidities a conservative approach was recommended; hormonal therapy with tamoxifen was instituted. We made a final diagnosis of advanced breast cancer with skin invasion, but we cannot rule out metastatic disease owing to the lack of additional studies (no CT or MRI were made) or surgery to confirm extension. Currently, the disease remains stable with no evidence of progression.

Discussion

Metastases of mucinous carcinoma of the breast (secondary mucinous carcinoma of the skin) are found principally in lymph nodes, lungs, and bone and they tend to occur late in the disease. The longest latency period reported for development of a distant metastasis is 30 years after primary resection of the tumor. The skin is a very rare site of metastasis and only very a few cases have been published [4,5]. Invasion of the overlying skin by the tumor also is an extremely rare feature. Only one similar case of massive mucinous carcinoma of the breast untreated for 6 years in a 47-year-old woman has been previously reported with this behavior; a good prognosis was described [6]. On the other hand, mucinous eccrine carcinoma (primary mucinous carcinoma of the skin) is a rare form of adenocarcinoma, first described by Lennox in 1952 [7]. This is a subtype of sweat gland carcinoma. There is some controversy about its eccrine or apocrine differentiation, although there are studies that suggest that there is differentiation toward the lowest portion of the eccrine sweat glands [8]. It generally affects 60+ year-old male patients (M/F 2:1) [9] and clinically it manifests as a bluish nodule with a vascular or cystic appearance. Common sites of involvement are the face, especially eyelid (38%), the scalp (16%), and the axilla (10%). It rarely metastasizes to lymph nodes or more distant organs [10], but it has a high recurrence rate (30%) with narrow surgical excision [11].

When the patient has not a previous history of breast cancer suggesting its origin, mucinous skin metastasis of the breast (secondary mucinous carcinoma of the skin) may be confused with primary mucinous carcinoma of the skin (mucinous eccrine carcinoma), because of their clinical and histological similarity. In order to differentiate them, some immunohistochemical markers have been studied, such as p63, CD15, cytokeratins CK5/6, CK7, CK20, e-cadherin, myoepithelial cells, calponin, D2-40, and breast hormone receptor. Levy et al [12] studied the expression pattern of cytokeratins in five patients with primary and two patients with secondary mucinous carcinomas and found that all cases were CK7 positive, but primary skin neoplasms expressed slightly more frequent CK5/6. All cases were negative for CD15, D2-40, CK20, and calponin. The largest series of mucinous carcinomas described the histopathologic, immunohistochemical, electron microscopic, and cytogenetic features [13]. It concluded that the better clues to compare primary and secondly involvement were the presence of an in situ component, which defines the neoplasm as a primary cutaneous neoplasm, and the location on the breast, that

indicates probable skin invasion of underlying adenocarcinoma. Immunohistochemical panel data were found to be similar in both origins and therefore inconclusive.

In conclusion, primary and secondary involvement of skin show identical microscopic findings and there are no patterns of staining specific enough to differentiate between these entities. Therefore, a carefully clinical assessment is essential with an exhaustive examination to rule out a skin metastasis or infiltrative disease from an occult ipsilateral breast primary tumor.

References

1. Komaki K, Sakamoto G, Sugano H, et al. Mucinous carcinoma of the breast in Japan. A prognostic analysis based on morphologic features. *Cancer*. 1988;61:989-96. [PMID: 2827884].
2. Toikkanen S, Kujari H. Pure and mixed mucinous carcinomas of the breast: a clinicopathologic analysis of 61 cases with long-term follow-up. *Hum Pathol*. 1989;20:758-64. [PMID: 2545592].
3. Karimipour DJ, Johnson TM, Kang S, et al. Mucinous carcinoma of the skin. *J Am Acad Dermatol*. 1997;36(2 Pt 2):323-6. [PMID: 9039211].
4. Schwartz RA, Wiederkehr M, Lambert WC. Secondary mucinous carcinoma of the skin: metastatic breast cancer. *Dermatology Surgery*, 2004; 30:234-5. [PMID: 14756660].
5. Nahass GT, Otrakji CJ, Gould E. Mucinous breast carcinoma. Single cutaneous metastasis. *J Dermatol Surg Oncol*. 1993;19:878-80. [PMID: 8396163].
6. Yoneyama F, Tsuchie K, Sakaguchi K. Massive mucinous carcinoma of the breast untreated for 6 years. *Int J Clin Oncol*. 2003;8:121-3. [PMID: 12720107].
7. Lennox B, Pearse AG, Richards HG. Mucin-secreting tumours of the skin with special reference to the so-called mixed-salivary tumour of the skin and its relation to hidradenoma. *J Pathol Bacteriol*. 1952;64:865-80. [PMID: 13000598].
8. Abenoza P, Ackerman AB. Mucinous carcinoma. In: *Neoplasms with eccrine differentiation*. Philadelphia: Lea & Febiger, 1990: 441–56
9. Snow SN, Reizner GT. Mucinous eccrine carcinoma of the eyelid. *Cancer*. 1992 15;70:2099-104. [PMID: 1327486].
10. Pilgrim JP, Kloss SG, Wolfish PS, Heng MC. Primary mucinous carcinoma of the skin with metastases to the lymph nodes. *Am J Dermatopathol*. 1985;7:461-9. [PMID: 3004247].
11. Bellezza G, Sidoni A, Bucciarelli E. Primary mucinous carcinoma of the skin. *Am J Dermatopathol*. 2000;22:166-70. [PMID: 10770439].
12. Levy G, Finkelstein A, McNiff JM. Immunohistochemical techniques to compare primary vs. metastatic mucinous carcinoma of the skin. *J Cutan Pathol*. 2010;37:411-5. [PMID: 19788442].
13. Kazakov DV, Suster S, LeBoit PE et al. Mucinous carcinoma of the skin, primary, and secondary: a clinicopathologic study of 63 cases with emphasis on the morphologic spectrum of primary cutaneous forms: homologies with mucinous lesions in the breast. *Am J Surg Pathol*. 2005 Jun;29:764-82. [PMID: 15897743].