

UC Davis

Dermatology Online Journal

Title

Unilateral purpura annularis telangiectodes of majocchi in an elderly male: an atypical presentation

Permalink

<https://escholarship.org/uc/item/03j9v3zb>

Journal

Dermatology Online Journal, 19(8)

Authors

Wang, Apphia
Shuja, Fareesa
Chan, Audrey
et al.

Publication Date

2013

DOI

10.5070/D3198019263

Copyright Information

Copyright 2013 by the author(s). This work is made available under the terms of a Creative Commons Attribution-NonCommercial-NoDerivatives License, available at <https://creativecommons.org/licenses/by-nc-nd/4.0/>

Peer reviewed

Case presentation

Unilateral purpura annularis telangiectodes of majocchi in an elderly male: an atypical presentation

Apphia Wang, Fareesa Shuja MD, Audrey Chan MD, and Carina Wasko MD

Dermatology Online Journal 19 (8): 6

Department of Dermatology, Baylor College of Medicine, Houston, Texas.

Correspondence:

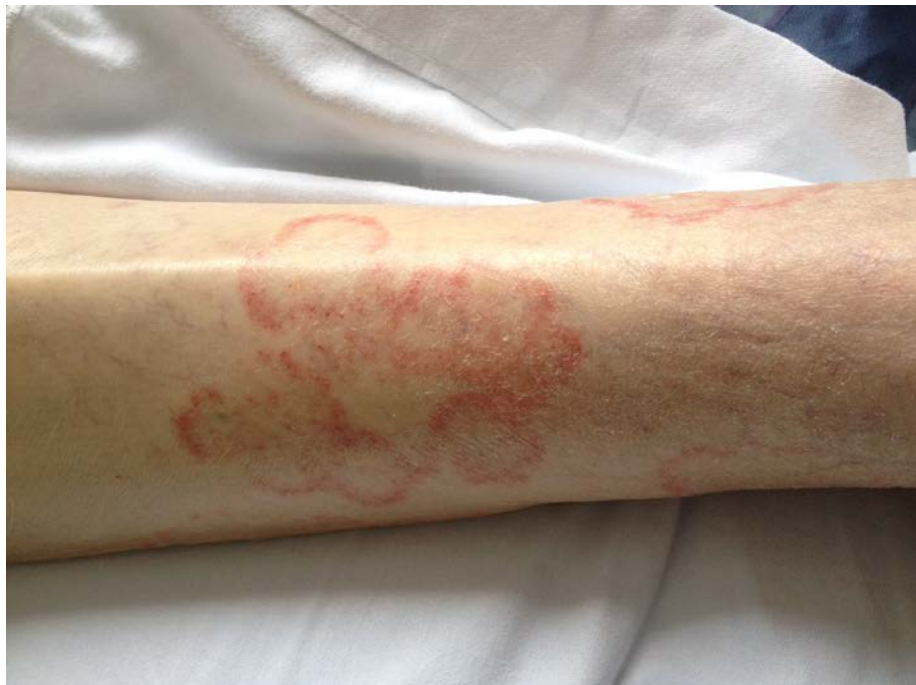Carina Wasko, MD
Baylor College of Medicine
Houston, TX, USA
carinawasko17@yahoo.com

Abstract

Purpura annularis telangiectodes (PAT), also known as Majocchi purpura, is a rare form of pigmented purpuric dermatosis characterized by non-palpable red-brown, occasionally pruritic patches which progress to hyperpigmented halos. Purpura annularis telangiectodes usually presents in female adolescents as benign symmetric lesions with a predilection for the lower extremities. We present an atypical case of unilateral PAT in an elderly male. To our knowledge, our patient at 85-years-old is the oldest PAT and first unilateral purpura annularis telangiectodes case described in the literature.

Introduction

Purpura annularis telangiectodes, also known as Majocchi purpura, is a rare form of pigmented purpuric dermatitis characterized by non-palpable red-brown, telangiectatic, non-blanching, occasionally pruritic patches that favor the lower extremities [1]. These benign symmetrical cutaneous hemorrhages span 2-20 mm in diameter and undergo peripheral expansion to hyperpigmented halos, which demonstrate central clearing, atrophy, and alopecia [2]. The first case of purpura annularis telangiectodes was described in 1896 by Domenico Majocchi in a 21-year-old male with annular red-brown patches with purpura and telangiectasias on the lower extremities [3]. We present an atypical case of unilateral PAT in an elderly male.



Case synopsis

An 85-year-old man was admitted to the hospital with dysphagia and a urinary tract infection as well as a one-week history of asymptomatic unilateral annular patches on his left leg. New medications included gentamicin, quetiapine, docusate sodium, nitrofurantoin, and hydralazine. Complete blood count and coagulations studies were within normal limits. Skin exam showed multiple scattered erythematous annular patches with central clearing along the left calf, pretibial area, ankle, and dorsal foot, without edema or scaling (Figure 1). Punch biopsy revealed perivascular lymphohistiocytic infiltrate with extravasated red blood cells compatible with Majocchi purpura clinically (Figure 2, 3).

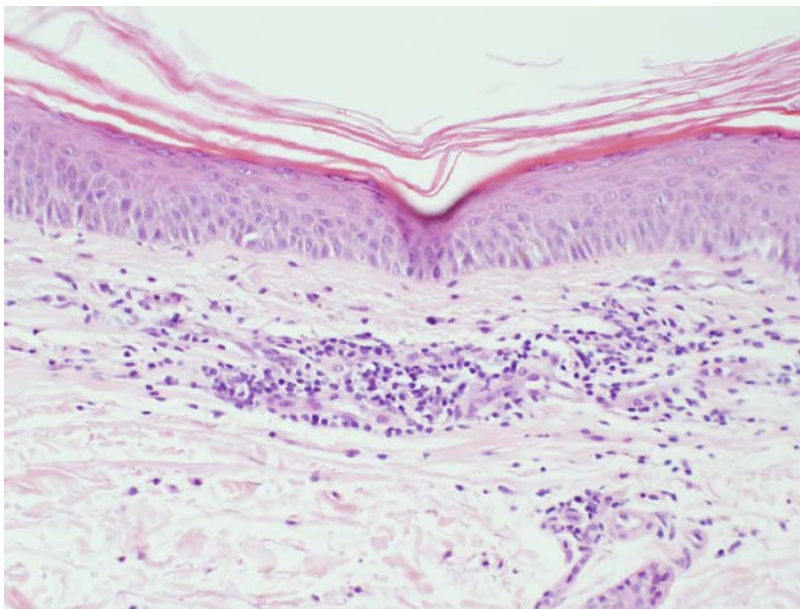


Figure 2. Perivascular lymphohistiocytic infiltrate in the superficial dermis (H&E x100)

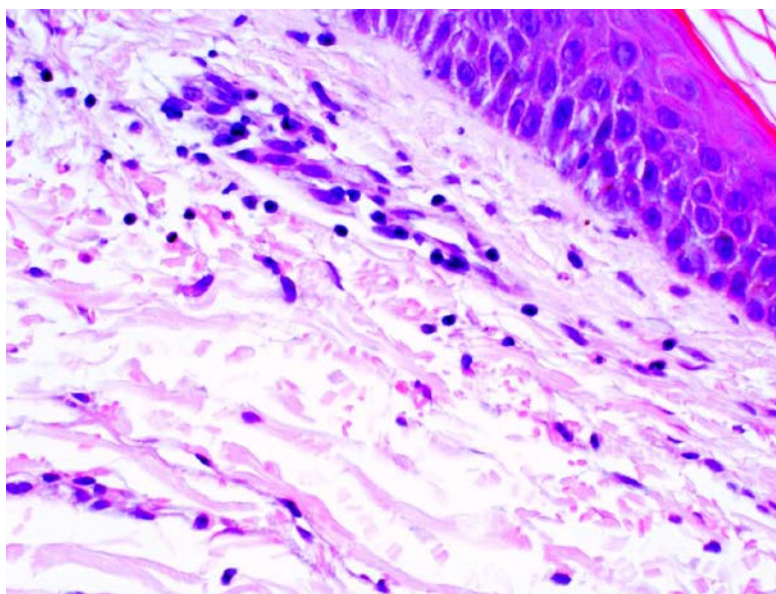


Figure 3. Mild perivascular inflammation with extravasated red blood cells (H&E x200)

Discussion

Purpura annularis telangiectodes (PAT) is a subtype of pigmented purpuric dermatosis (PPD), which includes five variants: (i) progressive pigmented purpuric dermatosis (Schamberg's disease); (ii) purpura annularis telangiectodes (Majocchi's disease); (iii) pigmented purpuric lichenoid dermatosis of Gougerot and Blum (lichenoid purpura of Gougerot and Blum); (iv) lichen aureus; and (v) eczematid-like purpura of Doucas and Kapetanakis. All variants of PPD are chronic benign dermatoses that share the same histopathological features and are differentiated by clinical morphology [1].

Although mostly annular, other forms including stellate, serpiginous, and linear have been described [4]. There are conflicting reports regarding population predilection for purpura annularis telangiectodes, although most reports support adolescent females [4]. Purpura annularis telangiectodes have also been described in newborn and elderly patients [1, 5].

Histopathological inspection of PAT reveals superficial papillary dermal capillary dilation and perivascular lymphocytic infiltration. The resulting erythrocyte extravasation and hemosiderin deposition lead to the classic red-brown appearance of lesions of PAT, although the degree of hemosiderin deposition may vary [2].

Purpura annularis telangiectodes is of unknown etiology, but medications, elevated venous pressure, and reactive oxygen species may contribute to the pathogenesis [2, 6]. A wide variety of medications including NSAIDs, diuretics, sedatives, and antibiotics have been implicated to cause vascular disruption by antigen-antibody complex deposition in which the medication acts as a hapten [7, 8]. Though uncommon, there have been familial cases with autosomal dominant inheritance of Majocchi's disease [9].

The differential diagnosis of PAT is extensive and can include tinea corporis, urticaria, erythema annulare centrifugum, granuloma annulare, stasis dermatitis, and mycosis fungoides [8, 10]. It is also important to exclude thrombocytopenia and coagulation abnormalities.

A skin biopsy is helpful in distinguishing between PPD and CTCL (cutaneous T-cell lymphoma) owing to a similarity in histologic and molecular pattern in the early stages of CTCL [2]. There have also been reports of PPD undergoing clonal expansion and transformation into CTCL, especially mycosis fungoides [1, 11]. Similarly, it has also been hypothesized that CTCL may mimic PPD in some instances [12].

Purpura annularis telangiectodes does not warrant treatment given its benign and self-resolving nature. It can persist from months to years with frequent recurrence. Evidence for various treatments is sparse because of the rarity of these cases, but treatments used in the past include systemic and topical glucocorticoids, antihistamines, colchicine, griseofulvin, rutoside (a bioflavonoid), ascorbic acid, cyclosporine A, methotrexate, psoralen ultraviolet A (PUVA), and narrowband ultraviolet B (NB-UVB) [1, 13]. Supportive measures include bed-rest, pressure stockings, and leg elevation. In the case of drug-induced PAT, removal of the offending agent will lead to resolution in months [14].

References

1. Hoesly FJ, Huerter CJ, Shehan JM. Purpura annularis telangiectodes of Majocchi: case report and review of the literature. *Int J Dermatol* 2009; 48(10): 1129-33. [PMID:19775410]
2. Sardana K, Sarkar R, Sehgal VN. Pigmented purpuric dermatoses: an overview. *Int J Dermatol* 2004; 43(7): 482-8. [PMID:15230884]
3. Majocchi D. Sopra una dermatosis non ancora descritta, "purpura annularis telangiectode". *G Ital Mal Venereol* 1896; 31: 263-4.
4. Kim HJ, Skidmore RA, Woosley JT. Pigmented purpura over the lower extremities. Purpura annularis telangiectodes of Majocchi. *Arch Dermatol* 1998; 134(11): 1477, 1480. [PMID:9828887]
5. Honda M, Saijo S, Tagami H. Majocchi's disease in a newborn baby: as familial case. *Br J Dermatol* 1997; 137: 655-6. [PMID:9390356]
6. Reinhold U, Seiter S, Ugurel S, Tilgen W. Treatment of progressive pigmented purpura with oral bioflavonoids and ascorbic acid: an open pilot study in 3 patients. *J Am Acad Dermatol* 1999; 41(2 Pt 1): 207-8. [PMID:10426890]
7. Mar A, Fergin P, Hogan P. Unilateral pigmented purpuric eruption. *Australas J Dermatol* 1999; 40(4): 211-4. [PMID:10570559]
8. Adams BB, Gadenne AS. Glipizide-induced pigmented purpuric dermatosis. *J Am Acad Dermatol* 1999; 41(5 Pt 2): 827-9. [PMID:10534660]
9. Sethuraman G, Sugandhan S, Bansal A, DAS AK, Sharma VK. Familial pigmented purpuric dermatoses. *J Dermatol* 2006; 33(9): 639-41. [PMID:16958811]
10. Suurmond D. Section 7. Miscellaneous Inflammatory Disorders. In: Suurmond D, ed. *Fitzpatrick's Color Atlas & Synopsis of Clinical Dermatology*. 6th ed. New York: McGraw-Hill; 2009.
11. Magro CM, Schaefer JT, Crowson AN, Li J, Morrison C. Pigmented purpuric dermatosis: classification by phenotypic and molecular profiles. *Am J Clin Pathol* 2007; 128(2): 218-29. [PMID:17638655]
12. Georgala S, Katoulis AC, Symeonidou S, Georgala C, Vayopoulos G. Persistent pigmented purpuric eruption associated with mycosis fungoides: a case report and review of the literature. *J Eur Acad Dermatol Venereol* 2001; 15(1): 62-4. [PMID:11451328]
13. Fathy H, Abdelgaber S. Treatment of pigmented purpuric dermatoses with narrow-band UVB: a report of six cases. *J Eur Acad Dermatol Venereol* 2011; 25(5): 603-6. [PMID:21492246]

15. Ratnam KV, Su WP, Peters MS. Purpura simplex (inflammatory purpura without vasculitis): a clinicopathologic study of 174 cases. *J Am Acad Dermatol* 1991; 25(4): 642-7. [PMID:1791222]