

UC Irvine

Clinical Practice and Cases in Emergency Medicine

Title

19-Year-Old with Sudden Onset Left Testicular Pain

Permalink

<https://escholarship.org/uc/item/05s0z3wd>

Journal

Clinical Practice and Cases in Emergency Medicine, 6(4)

Authors

Small, Elan
Ashenburg, Nicholas
Schertzer, Kimberly

Publication Date

2022

DOI

10.5811/cpcem.2022.7.56747

Copyright Information

Copyright 2022 by the author(s). This work is made available under the terms of a Creative Commons Attribution License, available at <https://creativecommons.org/licenses/by/4.0/>

Peer reviewed

19-Year-Old with Sudden Onset Left Testicular Pain

Elan Small, MD
 Nicholas Ashenburg, MD
 Kimberly Schertzer, MD

Stanford University School of Medicine, Department of Emergency Medicine
 Residency, Palo Alto, California

Section Editors: Joel Moll, MD

Submission history: Submitted March 20, 2022; Revision received March 26, 2022; Accepted July 02, 2022

Electronically published October 24, 2022

Full text available through open access at http://escholarship.org/uc/uciem_cpem

DOI: 10.5811/cpcem.2022.7.56747

Case Presentation: A previously healthy 19-year-old man presented to the emergency department with severe, sudden onset of left testicular pain. Physical exam revealed a left high-riding, horizontally oriented testicle without cremasteric reflex. Point-of-care ultrasound was used to confirm the diagnosis of testicular torsion, as well as to guide manual detorsion, verifying return of blood flow after reduction.

Discussion: Testicular torsion is a urologic emergency in which testicular viability is time dependent. Point-of-care ultrasound can be an important and helpful tool to not only confirm suspicion but help guide adequacy of blood flow return after manual detorsion in conjunction with comprehensive ultrasound. [Clin Pract Cases Emerg Med. 2022;6(4):327–329.]

Keywords: *point-of-care ultrasound; testicular torsion; testicle pain.*

CASE PRESENTATION

A 19-year-old man was brought by ambulance to the emergency department with left-sided testicular pain. He reported sudden severe, non-radiating left testicular pain that woke him from sleep 30 minutes prior to arrival. He presented in severe pain, tremulous from discomfort. His exam revealed a high-riding, firm, left testicle in a horizontal lie with absent cremasteric reflex. Urology was consulted and a comprehensive ultrasound ordered. The patient's testicles were immediately examined with point-of-care ultrasound (POCUS) (Image 1). After receiving 100 micrograms of fentanyl, manual detorsion was conducted, and repeat ultrasonography was performed (Image 2). The patient was then transported for comprehensive ultrasonography (Image 3).

DISCUSSION

Testicular torsion is a urologic emergency in which the testicle rotates 180-720 degrees, compromising venous and ultimately arterial circulation, leading to ischemia, necrosis, and nonviability. The literature has demonstrated good survivability at six hours, although it is time dependent with improved outcomes at quicker intervention.¹ Classic history and exam features include sudden onset of pain, and a firm, horizontally oriented testicle with absent cremasteric reflex.² Conventional

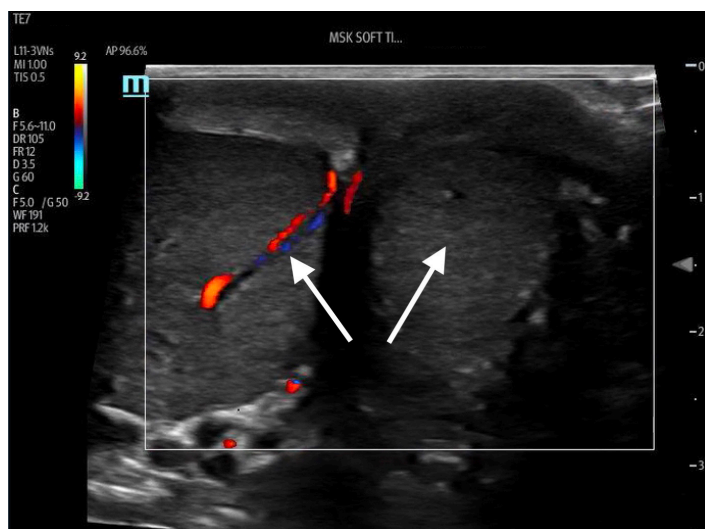

Image 1. Side-by-side view of initial testicular assessment using point-of-care ultrasound. The testicle on the image-right corresponds to the patient's painful left testicle which was found to be enlarged with surrounding edema and absent Doppler flow. Arrows highlight presence of flow in unaffected testicle and absence of flow in affected testicle.

teaching invokes early urologic consultation in highly suspicious cases prior to comprehensive ultrasonography.

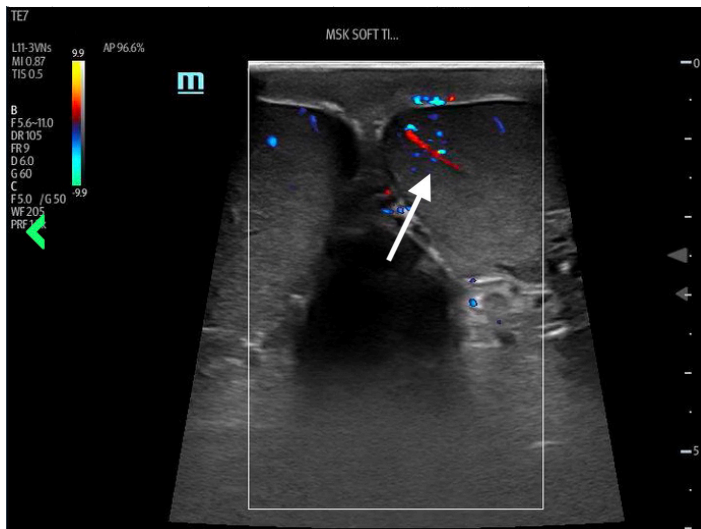


Image 2. Side-by-side view of testicular assessment with point-of-care ultrasound after manual detorsion. The testicle on the image-right corresponds to the patient's left testicle, with bilateral appreciable Doppler flow highlighted by the included arrow.

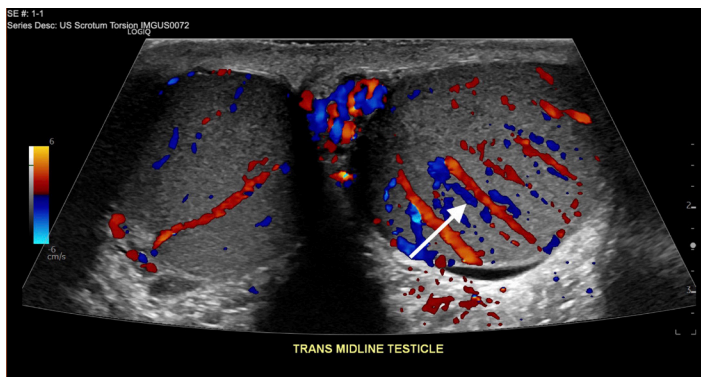


Image 3. Comprehensive ultrasonographic side-by-side view of testicles after manual detorsion. The image-right corresponds to the patient's left testicle, which demonstrated hyperemia likely related to detorsion event highlighted by the included arrow. Surrounding edema over affected testicle is also seen.

POCUS has emerged as an important diagnostic tool, with up to 100% sensitivity reported in small-sample studies for both fellowship- and non-fellowship trained emergency physicians.^{3,4} Ultrasonographic features can include the following: an enlarged edematous hypoechoic testicle without Doppler flow; a whirlpool sign (spiral twist of the spermatic cord at the external inguinal ring or scrotal sac); and epididymal enlargement without hyperemia.⁵ This patient underwent bedside manual detorsion with return of flow after approximately two lateral rotations. Comprehensive ultrasound demonstrated a hyperemic testicle consistent with recent detorsion. Depending on availability of resources and timing, POCUS can be an important tool in identifying testicular torsion and

CPC-EM Capsule

What do we already know about this clinical entity?

Testicular torsion is a time-sensitive emergent condition for which point-of-care ultrasound has emerged as a potential tool for both identification and management.

What is the major impact of the image(s)?

These images illustrate classic ultrasound findings of testicle edema, and absence of Doppler flow and demonstrate return of Doppler flow after attempted detorsion.

How might this improve emergency medicine practice?

Depending on resources, providers should consider point-of-care ultrasound, paired with comprehensive studies, to identify testicular torsion and confirm detorsion.

helping guide adequacy of reduction in conjunction with comprehensive ultrasonography.

The authors attest that their institution does not require Institutional Review Board approval. Patient consent has been obtained and filed for the publication of this case report. Documentation on file.

Address for Correspondence: Elan Small, MD, Stanford University, Department of Emergency Medicine, 900 Welch Road Ste 350, Palo Alto, CA 94034. Email: esmall17@stanford.edu.

Conflicts of Interest: By the *CPC-EM* article submission agreement, all authors are required to disclose all affiliations, funding sources and financial or management relationships that could be perceived as potential sources of bias. The authors disclosed none.

Copyright: © 2022 Small et al. This is an open access article distributed in accordance with the terms of the Creative Commons Attribution ([CC BY 4.0](https://creativecommons.org/licenses/by/4.0/)) License. See: <http://creativecommons.org/licenses/by/4.0/>

REFERENCES

1. Blaivas M, Batts M, Lambert M. Ultrasonographic diagnosis of testicular torsion by emergency physicians. *Am J Emerg Med.* 2000;18(2):198-200.
2. Germann C, Holmes, Jeffery. 2017. Selected urologic disorders

- In: Rosen's Emergency Medicine: Concepts and Clinical Practice.* Amsterdam, Netherlands. Elsevier.
3. Friedman N, Pancer Z, Savic R, et al. Accuracy of point-of-care ultrasound by pediatric emergency physicians for testicular torsion. *J Pediatr Urol.* 2019;15(6):608.e1-608.e6.
 4. Blaivas M, Sierzenski P, Lambert M. Emergency evaluation of patients presenting with acute scrotum using bedside ultrasonography. *Acad Emerg Med.* 2001;8(1):90-3.
 5. Lee DY, Lee SH, Yoon JA, et al. Detection of testicular torsion with preserved intratesticular flow by point of care ultrasound in the emergency department: a case report. *J Emerg Med.* 2022;62(4):e88-e90.