

UC Davis

Dermatology Online Journal

Title

Unusual case of Paget disease of the nipple diagnosed by nipple scraping cytology

Permalink

<https://escholarship.org/uc/item/0b64c7mh>

Journal

Dermatology Online Journal, 26(3)

Authors

Herbst, Ewa
Tismenetsky, Mikhail
McIntosh, Violet Merle

Publication Date

2020

DOI

10.5070/D3263048030

Copyright Information

Copyright 2020 by the author(s). This work is made available under the terms of a Creative Commons Attribution-NonCommercial-NoDerivatives License, available at <https://creativecommons.org/licenses/by-nc-nd/4.0/>

Peer reviewed

Unusual case of Paget disease of the nipple diagnosed by nipple scraping cytology

Ewa Herbst¹ PhD, Mikhail Tismenetsky² MD, Violet Merle McIntosh³ MD FACS

Affiliations: ¹h2med LLC, Edgewater, New Jersey, USA, ²Department of Pathology, Englewood Hospital and Medical Center, Englewood, New Jersey, USA, ³Department of Breast Surgery, Englewood Hospital and Medical Center, Englewood, New Jersey, USA

Corresponding Author: Mikhail Tismenetsky M.D., Department of Pathology, Englewood Hospital and Medical Center, 350 Engle Street, Englewood, New Jersey 07631, Tel: 201-894-3424, Email: Mikhail.Tismenetsky@EHMCHealth.org

Abstract

Paget disease of the nipple is a rare presentation of breast cancer. It is sometimes mistaken for a benign skin condition of the nipple and surrounding areola, which can significantly delay the diagnosis and treatment. In over 90% of cases there is an underlying carcinoma, either ductal carcinoma in situ (DCIS) or invasive breast cancer. We present a rare case of Paget disease of the nipple without the typical characteristics, detected by simple nipple scraping technique. A 62-year-old woman presented with a small fissure on the left nipple with scant clear nipple discharge. There were no other changes to the nipple-areola complex. The mammography and ultrasound were unremarkable. However, nipple scraping provided the immediate cytological diagnosis of Paget disease. Breast MRI with core biopsy showed high grade ductal carcinoma in situ with suggestion of microinvasion, confirmed histologically after mastectomy. Nipple scraping is a simple and inexpensive technique, which can be used in the office without anesthesia and with minimal discomfort to the patient. It could allow for significantly earlier cancer detection and treatment at the earliest stage of breast cancer. However, if the results are negative, full thickness biopsy may be needed if clinically indicated.

Keywords: Paget disease, breast, cancer, eczema, nipple inversion, nipple retraction, nipple discharge, intraductal carcinoma, DCIS, nipple scraping, cytology

Introduction

Mammary Paget disease is a rare presentation of breast cancer seen in 1%-4.3% of all cases [1]. It is

sometimes mistaken for a benign skin condition of the nipple and surrounding areola, which can significantly delay the diagnosis and treatment.

The purpose of this case report is twofold: 1) to show that even with early presentation of Paget disease of the nipple there may already be significant and high grade underlying carcinoma requiring timely treatment and 2) to show that Paget disease of the nipple, with minimal signs and symptoms, can be diagnosed by a simple nipple scraping technique [2-5].

The National Cancer Institute lists the following signs and symptoms of Paget disease of the nipple [6]:

- Itching, tingling, or redness in the nipple and/or areola
- Flaking, crusty, or thickened skin on or around the nipple
- A flattened nipple
- Discharge from the nipple that may be yellowish or bloody

Although, these are the most common symptoms of Paget disease, it can also present with clear nipple discharge, or inverted or retracted nipple.

The differential diagnosis for skin changes of the nipple-areola complex may include: "atopic or contact dermatitis, chronic eczema, psoriasis, nipple duct adenoma, malignant melanoma, basal cell carcinoma, and Bowen's disease" [7]. Chronic breast eczema is common, particularly if bilateral, although bilateral Paget disease has been reported [8]. The changes may be subtle, so even minor changes should not be ignored.

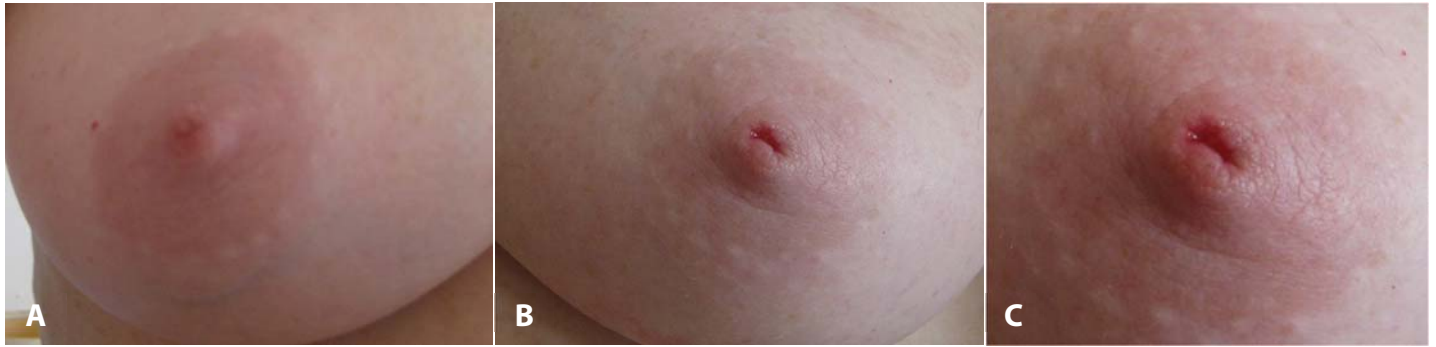

Figure 1. **A)** Right, unaffected, breast. **B)** Left breast showing only small fissure in the nipple but no other changes to the nipple and areola. **C)** An enlarged view of the left nipple—observe the small fissure in the nipple and a droplet of clear fluid in the upper corner.

As the patient is seldom seen by the breast specialist at the outset, cancer treatment is often delayed. It can take several months before Paget disease of the breast is correctly diagnosed.

The diagnosis of Paget disease has traditionally been made by a punch biopsy, requiring a local anesthetic. The technique of nipple scraping cytology [2-5] is an alternative quick, non-invasive, and economical method of diagnosing Paget disease of the nipple.

Case Synopsis

Patient is a 62-year-old woman who observed a scant clear discharge from the left nipple, which also exhibited a small fissure (**Figure 1B, C**). There were no other visible changes to the nipple and the surrounding areola. **Figure 1A** shows the contralateral breast.

The patient immediately contacted a dermatologist, who prescribed a topical cream. Two weeks later the patient scheduled a screening digital mammography, which showed benign appearing microcalcifications in the left breast. Physical examination showed no palpable abnormality and no inverted nipple. Microscopic evaluation of the discharge exhibited rare clusters of epithelial cells. Owing to dense breast tissue, ultrasound was performed and was unremarkable. On the same day a scraping of the nipple was performed and provided an immediate cytological diagnosis of Paget disease (**Figure 2**). Subsequent diagnostic digital mammography confirmed benign appearing stable calcifications. There was also stable left nipple

retraction compared to a mammogram from two years prior.

The subsequent MRI revealed an inverted nipple and clumped heterogeneous enhancement extending from the nipple into the lower inner quadrant, approximately 4cm from the nipple. The MRI guided core biopsy revealed high grade ductal carcinoma in situ (DCIS) with necrosis and suspected microinvasion. Because of the extent of DCIS, mastectomy was recommended. The patient elected to have bilateral mastectomies with reconstruction.

Post mastectomy histological evaluation of the left breast showed high grade DCIS (solid and comedo types) with microinvasion (<0.1cm), extending to the subareolar duct and involving the nipple epidermis (**Figure 3**). There was no lymph node involvement.

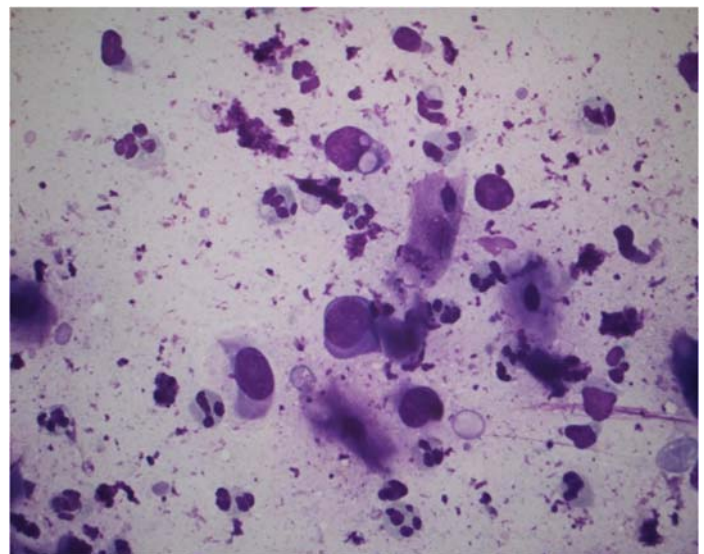


Figure 2. Cytology of nipple scraping. The nipple scraping shows scattered enlarged malignant cells in a background of acute inflammatory cells and squamous cells. Diff Quick stain, 400x.

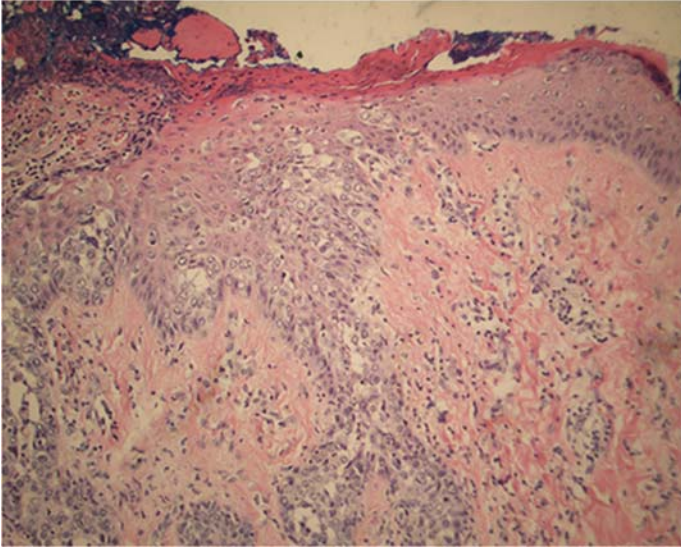


Figure 3. Histology from mastectomy. Section of the left nipple shows malignant cells with clear cytoplasm involving the epidermis and causing ulceration (left). H&E, 100x.

Both estrogen and progesterone receptors were negative, as in the previous DCIS core biopsy. Small foci of lobular carcinoma in situ (LCIS) of pleomorphic type were present in the right breast.

Case Discussion

The case presented here is unusual, as the Paget disease of the nipple was diagnosed early, before significant skin changes in the nipple areola complex developed. There was only a small fissure on the nipple with scant clear discharge and no eczematous changes. Although a clear nipple discharge is often not thought of as a cause of concern, it was present in this case, as well as in 12 (48%) of 25 cases with discharge described by Kothari et al. [9]. Timely treatment is essential, as even with the minimal symptoms of Paget disease in our case, there was already an extensive underlying high-grade DCIS with microinvasion.

Paget disease of the nipple is a rare presentation of breast cancer and most publications report only small retrospective patient series or individual cases. In a comprehensive review of the literature Karakas [1] describes clinical, radiological, and pathological features of Paget disease, with an extensive coverage of diagnosis, differential diagnosis, and treatment.

In the majority of cases of Paget disease of the nipple, the diagnosis is made first when there are already significant changes to the nipple area. In a study of 223 women from 13 Swedish hospitals between 1976 and 2001 by Dalberg et al. [10], 98% had, as a main symptom, eczema or ulceration of the nipple. Similarly, Kollmorgen et al. [11] reported nipple ulceration in 90% and discharge in 18% of 68 patients with clinical Paget disease. Kothari et al. [9] reviewed 70 cases of women with a clinical diagnosis of Paget disease treated by mastectomy. In 98.5% of cases there was an underlying breast carcinoma, with an invasive malignancy in 58% of all cases [9]. Both DCIS without microinvasion and invasive breast cancer had high nuclear grade in 96.5% and 100% of cases, respectively [9]. Eczematoid changes of the nipple were seen in 56% of cases, nipple erythema in 29%, nipple ulceration in 27%, and inversion of the nipple in 20% [9]. Nipple discharge was present in 36% of cases, of which 52% was bloody and 48% clear [9].

Karakas [1] reported that in over 90% of cases of Paget disease of the breast, there was a high-grade carcinoma present in the milk ducts (DCIS) at the time of diagnosis, with an invasive breast carcinoma seen in approximately 50% of cases. In the majority of cases, estrogen and progesterone receptors were negative (ER- and PR-) and the human epidermal growth factor receptor (HER-2) was overexpressed [1]. Kollmorgen et al. [11] found that in almost 30% of cases the underlying invasive breast cancer can be peripherally located. Owing to the fact that the early symptoms of Paget disease of the breast are often mistaken for a benign skin condition and mammography can be normal in up to 50% of cases, the cancer treatment is in most cases delayed by several months [6].

High clinical awareness is required for diagnosis of Paget disease, as exemplified in the case described by Gaspari et al. [7] of a 56-year-old woman reporting only itchiness to the left nipple, with no alteration of the nipple-areola complex, no palpable mass, no nipple discharge, and no axillary lymphadenopathy. Microcalcifications observed on mammogram did not appear suspicious for malignancy and ultrasound was unremarkable. However, results of

the MRI examination suggested Paget disease, which was confirmed by biopsy.

The early diagnosis in our case had been made utilizing nipple scraping and cytology. Nipple scraping, as a method to diagnose Paget disease of the breast, was first described in 1966 by Dutra [5], who discussed the superiority of the scraping over cytological smears of the exudates from the ducts.

In a recent article Raivoherivony et al. [2] suggested that nipple scraping is underutilized in cases of clinical suspicion of Paget disease and provided results from their study of 140 nipple scrapings obtained over a period 2000-2018, of which 62 cases were excluded because of the absence of histological correlation. Cytological diagnosis of Paget disease was made in 35 cases, of which 32 cases (91.4%) were confirmed by histology after punch biopsy, lumpectomy, or total mastectomy. Three cases were false-negative. Three cases were false-positive, with corresponding histological sections showing nipple adenomas.

In two earlier retrospective case series by Lucarotti et al. [4] and Gupta et al. [3], Paget disease was correctly diagnosed with scrape cytology in 8 of 14 patients, with no false negatives or false positives [4], and in 11 of 11 patients [3], respectively.

The technique can be performed in an ambulatory setting. Eczematous nipple lesions can be scraped with a glass slide. It is important to remove the dry superficial layer or crust to permit exudation of underlying tissue fluid containing tumor cells. The scraped material is smeared on a slide that can be air-dried and forwarded to a pathology laboratory, where it can be stained and evaluated by a cytopathologist for the presence of malignant cells (**Figure 2**). This procedure is simple and inexpensive and can yield results with minimal discomfort to the

patient compared to a full thickness skin biopsy. An instructional video on the smearing technique is available online [12]. Although this video deals with a fine needle aspiration sample, the smearing technique is identical for scraping cytology.

Conclusion

Dermatologists and primary care physicians have an important role in the early detection of Paget disease of the nipple. They are usually the first medical practitioners to be consulted by the patient in case of any nipple-areola changes. This report shows that even benign looking changes of the nipple and/or a scant clear discharge (not necessarily yellowish or bloody) can be an early manifestation of Paget disease of the nipple with significant, high grade underlying DCIS with microinvasion already present. Early referral to a breast specialist can expedite cancer treatment by several months. Patients with intraductal tumors have an excellent prognosis.

Cytologic evaluation of nipple scraping can be a rapid, non-invasive, and cost-effective screening method for diagnosing Paget disease of the nipple that can lead to an earlier cancer treatment. However, a negative result does not exclude Paget disease and if clinically concerning, a full thickness skin biopsy may be necessary.

Potential conflicts of interest

The authors declare no conflicts of interests.

Acknowledgements

We thank Patricia A. LoPinto, APN, Department of Breast Surgery, Englewood Hospital and Medical Center for the initial manuscript discussions.

References

1. Karakas C. Paget's disease of the breast. *J Carcinog*. 2011;10:31. [PMID: 22279416].
2. Raivoherivony ZI, Feron J, Kljaniienko J. The utility of nipple scraping in the diagnosis of Paget disease of the breast. *Diagn Cytopathol*. 2019; 47: 249-250. [PMID: 30484956].
3. Gupta RK, Simpson J, Dowle C. The role of cytology in the diagnosis of Paget's disease of the nipple. *Pathology*. 1996;28:248-50. [PMID: 8912355].
4. Lucarotti ME, Dunn JM, Webb AJ. Scrape cytology in the diagnosis of Paget's disease of the breast. *Cytopathology*. 1994;5:301-5.

- [PMID: 7529588].
5. Dutra FR. Paget's disease of the breast. Simple method of cytological diagnosis. *JAMA*. 1966;195:873-5. [PMID: 12608188].
 6. National Cancer Institute. Paget disease of the breast. 2012 Apr 10 <https://www.cancer.gov/types/breast/paget-breast-fact-sheet> Accessed on February 11, 2020.
 7. Gaspari E, Ricci A, Liberto V, et al. An Unusual Case of Mammary Paget's Disease Diagnosed Using Dynamic Contrast-Enhanced MRI. *Case Rep Radiol*. 2013;2013:206235. [PMID: 23607031].
 8. Babu B, Dev B, Mohanapriya T, Shalini CNS. Bilateral mammary Paget disease in a young adult female. *Radiol Case Rep*. 2018;13:586-591. [PMID: 30008979].
 9. Kothari AS, Beechey-Newman N, Hamed H, et al. Paget disease of the nipple: a multifocal manifestation of higher-risk disease. *Cancer*. 2002;95:1-7. [PMID: 12115309].
 10. Dalberg K, Hellborg H, Wärnberg F. Paget's disease of the nipple in a population based cohort. *Breast Cancer Res Treat*. 2008;111:313-9. [PMID: 17952590].
 11. Kollmorgen DR, Varanasi JS, Edge SB, Carson WE 3rd. Paget's disease of the breast: a 33-year experience. *J Am Coll Surg*. 1998;187:171-7. [PMID: 9704964].
 12. Slide preparation video: USCAP Your Academy. Fine Needle Aspiration Biopsy (FNA) Techniques - Dividing & Smearing Technique. 2018 Dec 19. https://www.youtube.com/watch?v=THcBELB8drg&list=PLaWBzZZDOvpecETKjD7_gupwB34tlcOWZ&index=18. Accessed on February 11, 2020.