

# UC Davis

## Dermatology Online Journal

### Title

Aquagenic palmar wrinkling in two Indian patients with special reference to its dermoscopic pattern Sudip Kumar

### Permalink

<https://escholarship.org/uc/item/0hr3d0bn>

### Journal

Dermatology Online Journal, 21(6)

### Authors

Ghosh, Sudip Kumar  
Agarwal, Megha  
Ghosh, Shouvik  
et al.

### Publication Date

2015

### DOI

10.5070/D3216027822

### Copyright Information

Copyright 2015 by the author(s). This work is made available under the terms of a Creative Commons Attribution-NonCommercial-NoDerivatives License, available at <https://creativecommons.org/licenses/by-nc-nd/4.0/>

Peer reviewed

**Photo vignette**

**Aquagenic palmar wrinkling in two Indian patients with special reference to its dermoscopic pattern**

**Sudip Kumar Ghosh MD DNB<sup>1</sup>, Megha Agarwal MBBS<sup>1</sup>, Shouvik Ghosh MBBS<sup>1</sup>, Amit Kumar Dey MBBS<sup>2</sup>**

**Dermatology Online Journal 21 (6): 13**

**<sup>1</sup>Department of Dermatology, Venereology, and Leprosy and <sup>2</sup>Department of Medicine, R.G. Kar Medical College, Kolkata-700004, India.**

**Correspondence:**

Sudip Kumar Ghosh  
Department of Dermatology, Venereology, & Leprosy  
1, Khudiram Bose Sarani, Kolkata 700004  
E-mail: dr\_skghosh@yahoo.co.in

---

**Abstract**

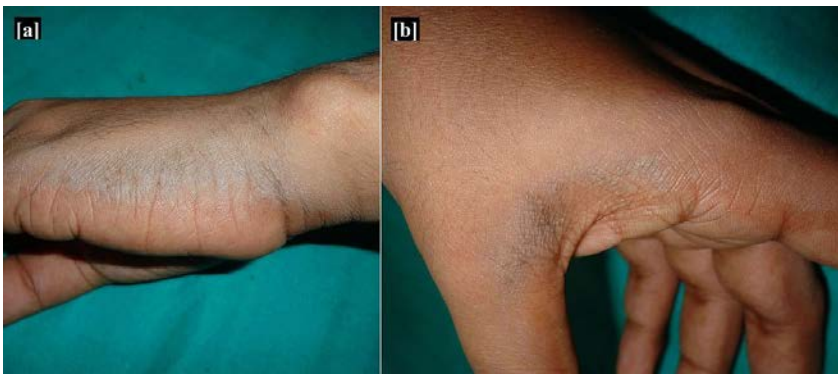
Aquagenic palmar wrinkling (APW), synonymously known as aquagenic syringeal acrokeratoderma, transient aquagenic palmar hyperwrinkling, aquagenic palmoplantar keratoderma, or transient reactive papulotranslucent acrokeratoderma, is a distinctive dermatosis characterized by whitish papules, excessive wrinkling, and possible desquamation of the palms and/or soles after immersion into water for a short time[1-5]. We describe herein two cases of aquagenic palmar wrinkling in Indian patients with special reference to its dermoscopic pattern. Since its initial description, only a few cases of APW have been described in literature. To the best of our knowledge, APW is a hitherto unreported condition in Indian population.

**Keywords: Aquagenic palmar wrinkling, cystic fibrosis, dermoscopy**

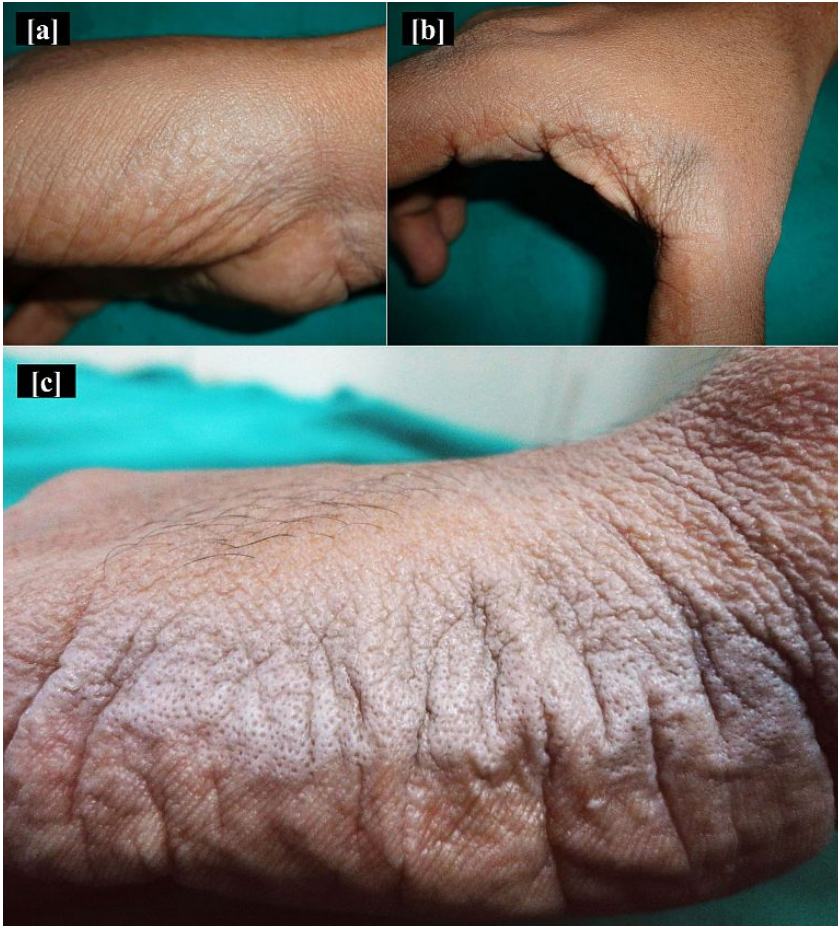**Case synopsis**

Patient 1:

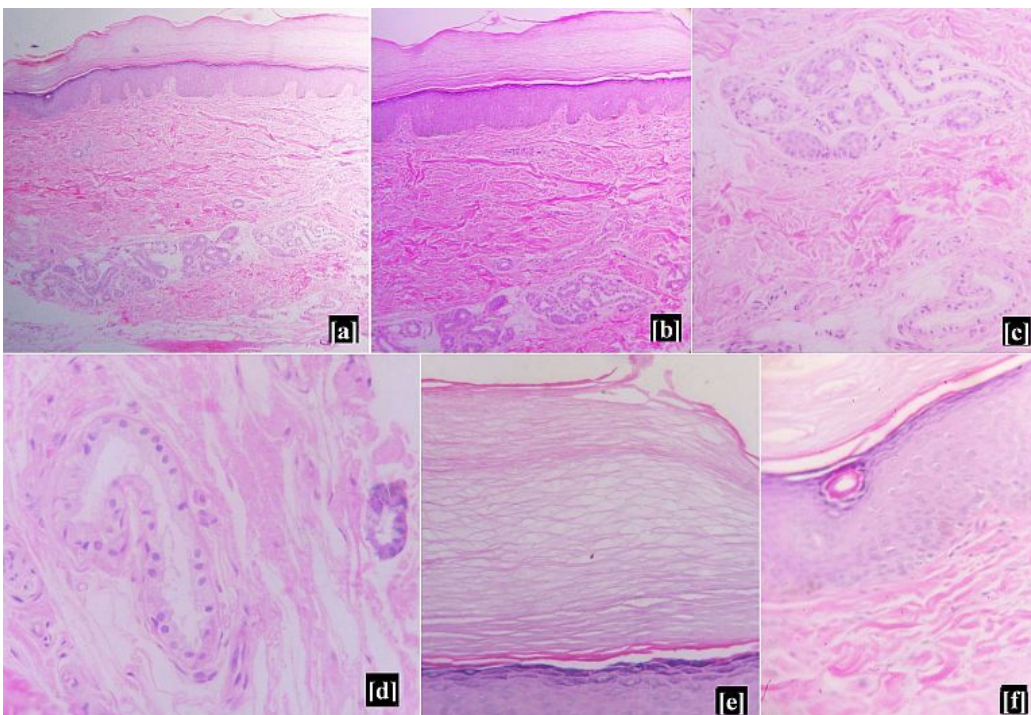
A 25-year-old man presented to us with a 6-month history of relapsing whitish eruptions on his palms after immersion in water irrespective of its temperature. His medical and surgical history was uneventful and he was not on any medication prior to these eruptions. There was no history of atopy and none of his first degree relatives had any similar problem. He had no history of any particular systemic problem related to the respiratory or gastrointestinal systems apart from recurrent sneezing and frontal headache. Dermatological examination revealed {Figure 1 and 2} a few whitish plaques and a few subtle papules on his palms, particularly on its lateral borders and web spaces. Within 30 seconds of initiation of hand washing under running tap water at room temperature, white plaques studded with multiple papules with central puncta and exaggerated wrinkling became more evident. These palmar lesions persisted for about 20 minutes before disappearing. Biochemical panels and complete hemogram were normal. In this active state, a 3-mm punch biopsy was performed from the lesional skin. Histological evaluation {Figure 3} showed compact ortho-hyperkeratosis and relative intraepidermal dilatation of eccrine ducts. The stratum corneum was spongy in appearance. Hyperplasia of the eccrine glandular epithelia was observed in the reticular dermis, and lumina of the dilated eccrine glands had irregular shapes. Dermoscopy revealed {Figure 5} dilated pores on the affected areas in comparison to the clinically uninvolved areas. The size of the pores of the lesional areas increased many folds when dermoscopy was done after immersion of hands in water. Based on the clinical, histopathological, and dermoscopic features, a diagnosis of Aquagenic palmar wrinkling (APW) was made.



**Figure 1.** Few subtle papules and whitish plaques on the (a) ulnar border of palm and (b) finger web.



**Figure 2.** (a,b): The papules and plaques becoming more prominent along with dilatation of pores on the affected site after water immersion.(c)close-up view showing dilated pores and exaggerated wrinkling along the ulnar border of palm after water immersion



**Figure 3.** Photomicrograph showing (a, b): compact ortho-hyperkeratosis, relative intraepidermal dilatation of eccrine ducts and hyperplasia of the eccrine glandular epithelia in the reticular dermis. (H & E, x100), (c, d): dilated eccrine glands in the reticular dermis (H & E, x400), (e): spongy appearance of stratum corneum (H & E, x400), (f): a dilated eccrine duct in the epidermis. (H & E, x400)



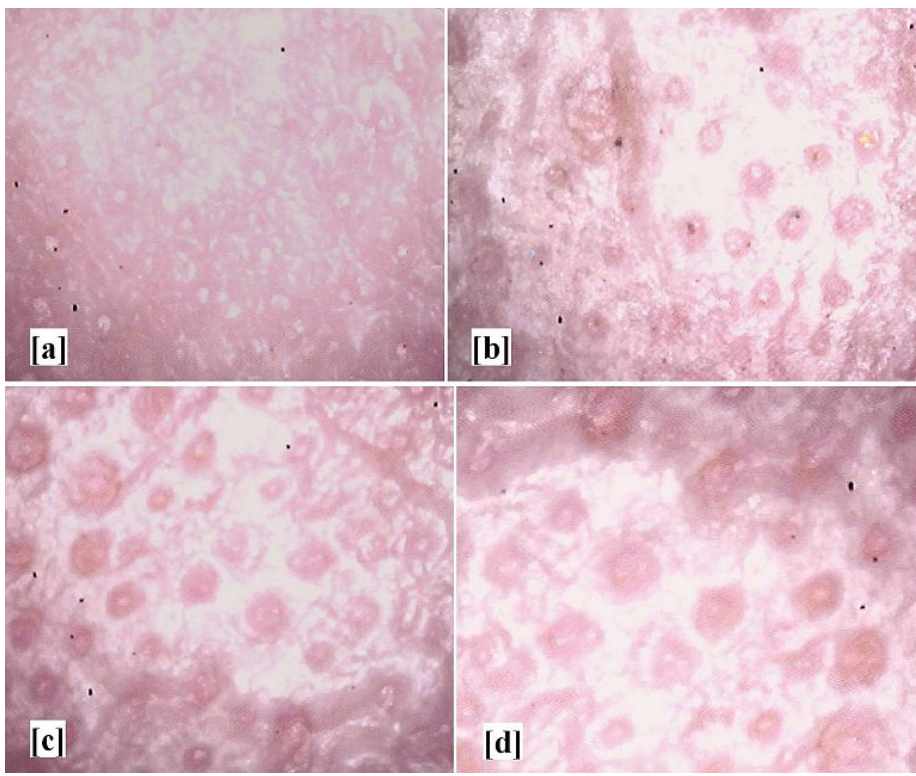


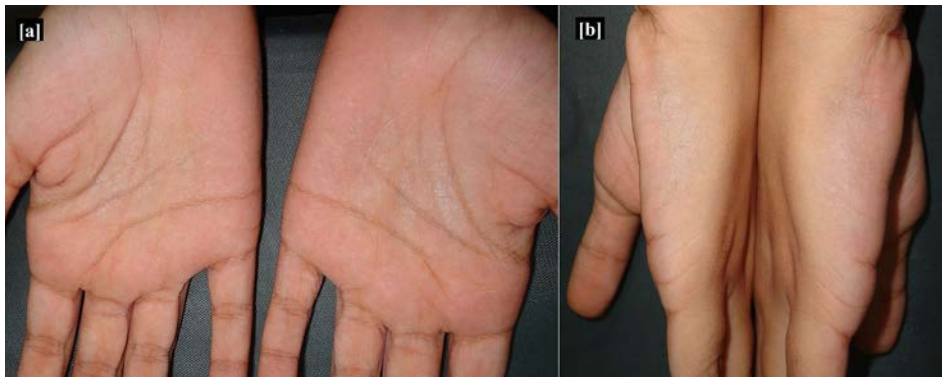
Fig 4 : Dermoscopic examination (Original magnification x50)in the first patient-

- A. Unaffected site before water immersion
  - B. Affected site before water immersion
  - C. Affected site showing dilatation of pores after one minute of water immersion
  - D. Affected site showing marked dilatation of pores after two minutes of water immersion.
- 

Patient 2:

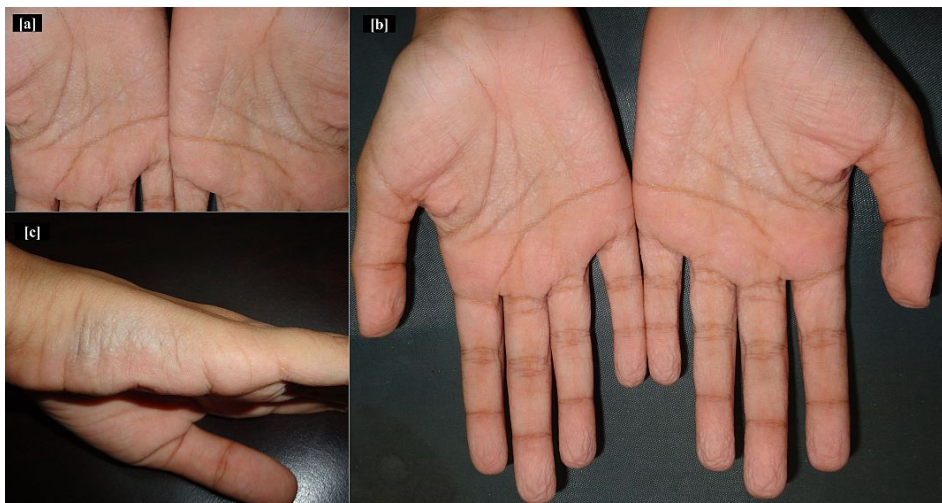
A 17-year-old girl presented to us with a 4-month history of relapsing whitish eruptions on her palms after immersion in water irrespective of the temperature of water. Her medical and surgical history was noncontributory and there was no suggestive history of any prior medication.

There was no history of atopy and family history was not significant. She had no respiratory or gastrointestinal symptom. Dermatological examination {Figure 5, 6} revealed a few whitish plaques and a few faint papules on her palms.



**Figure 5.** Whitish papules and plaques on the palms of the second patient before water immersion

---

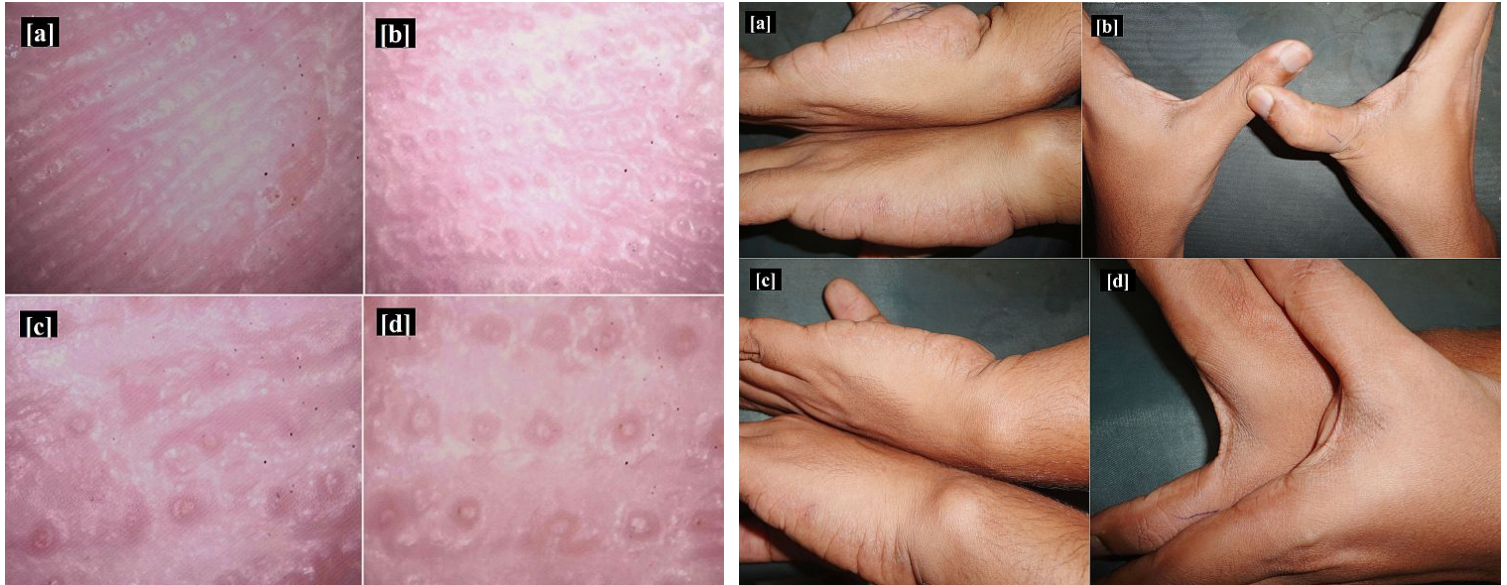


**Figure 6.** Whitish papules and plaques on the palms becoming more prominent after one minute of water immersion in the second patient

---

Within one minute of initiation of hand washing under running tap water at room temperature, white plaques studded with multiple papules with central puncta and exaggerated wrinkling became evident. These palmar lesions persisted for about 15 minutes before disappearing. Routine biochemical panels and complete hemogram were normal. Dermoscopy revealed {figure 7} features similar to that of the first patient. Her parents did not give consent to undergo skin biopsy. Based on the clinical and dermoscopic features, a diagnosis of Aquagenic palmar wrinkling (APW) was made.

We specifically ruled out any history of cystic fibrosis in the family members of our patients. In both of our patients X rays of the paranasal sinuses and chest were normal. We prescribed 20% aluminum chloride lotion twice daily for topical application to both of them. In order to further rule out any carrier state of cystic fibrosis, we referred them to our colleagues from general medicine and chest departments. Within 6 weeks, the cutaneous lesions showed marked improvement in the first patient {Figure 8}, while the second patient was lost to follow-up.



**Figure 7.** Dermoscopic examination (Original magnification x50) in the second patient. (a): Unaffected area of palm before water immersion (b): Unaffected area of palm after 1 minute of water immersion (c): Affected area of palm before water immersion (d): Affected area of palm showing marked dilatation of pores after 1 minute of water immersion. **Figure 8.** Treatment outcome of the first patient. (a, b): Affected sites before water immersion (c, d): Affected sites after three minutes of water immersion.

## Discussion

The first connotation of APW, way back in 1974, was by Elliott who observed ‘skin wrinkling’ among children with cystic fibrosis (CF) [6] and it was subsequently termed as ‘transient reactive papulotranslucent acrokeratoderma’ by English and McCollough [7]. This condition was further described as Aquagenic wrinkling of the palms by Carder et al in 2002[8].

The precise etiopathogenesis of this condition remains elusive. Several hypotheses do exist. Some reports suggest that there might be an increased frequency of this condition among patients and carriers with cystic fibrosis (CF) [9-11].

An excessive electrolyte content of sweat, determined by mutations of the gene CFTR, accountable for CF, may play an important role in the pathogenesis of APW [9-11]. Drugs like aspirin, rofecoxib, salazopyrin, and celecoxib have also been implicated as possible triggering factors [12]. Bhojani et al reported a case of APW on exposure to alcohol gel, used to cleanse the hands [13].

Aquagenic palmar wrinkling manifests as white to translucent papules on edematous palms, within 3 minutes of immersion in water (‘hand in bucket sign’) [1, 10, 11]. It may be asymptomatic or may be associated with pruritus, tingling or burning sensation, or even pain [1]. Plantar involvement is uncommon. As symptoms rapidly resolve with drying of the skin and are often transient, it often remains unrecognized. Hence it is often helpful to reproduce the lesions by immersing the patient’s hands in water for a few minutes.

Dermoscopic evaluation of the normal palmar skin surface discloses tiny, round, whitish spots suggestive of sweat duct puncta [14]. In our cases, we found marked enlargement of the sweat duct puncta when compared with unaffected palmar regions, more so after water immersion. Literature review showed that there is a dearth of data regarding the dermoscopic features of APW. A PubMed search revealed only one previous report demonstrating dermoscopically enlarged sweat duct pores in case of APW when compared with a normal-looking palmar skin area [14].



Histopathological examination of the lesional skin shows a thickened stratum corneum, due to water imbibition and not due to true hyperkeratosis; and dilated eccrine ducts in the deepest part, probably related to retention of sweat. The biopsy should be taken after water exposure because biopsy after drying the skin often revealed no abnormalities [15].

Several treatment options for APW have been proposed: 15–20% topical aluminum chloride is the most frequently prescribed with variable results, followed by botulinum toxin injections [16], topical corticosteroids, topical salicylic acid, formalin in alcohol, barrier agents, antihistamines and topical erythromycin. 12% ammonium lactate creams or petroleum jelly or the use of gloves have not been shown to be effective [17].

In conclusion, the diagnosis of APW is straightforward if we know the existence of this entity, and could be extremely important to identify an associated pauci-symptomatic CF or CF mutation heterozygosity, enabling heterozygous patients and their families to undergo genetic counseling before conception. Moreover, understanding the pathophysiology of APW could lead to a better understanding of CF. In this illustrative report, we further seek to emphasize that dermoscopy is a valuable alternative / adjunct to skin biopsy in the diagnosis of Aquagenic palmar wrinkling.

## References

1. Suchak R, Lawlor F. Water-induced palmar tingling and swelling. *Clin Exp Dermatol* 2007;32:119-20. [PMID:17305920]
2. Wilder-Smith EP. Aquagenic wrinkling of the palms is due to vasoconstriction of palmar skin vasculature. *Med Hypotheses* 2013;81:963-5. [PMID:24080203]
3. Stewart LC, Doe SJ, Bourke SJ, Leech S. Aquagenic palmar wrinkling as a presenting feature of cystic fibrosis gene dysfunction. *Clin Exp Dermatol* 2009; 34:e647-9. [PMID:19548945]
4. Neri I, Bianchi F, Patrizi A. Transient aquagenic palmar hyperwrinkling: the first instance reported in a young boy. *Pediatr Dermatol* 2006; 23:39-42. [PMID:16445410]
5. Ertürk-Özdemir E, Ozcan D, Seçkin D. Acquired aquagenic syringeal acrokeratoderma: A case series of 10 patients. *Australas J Dermatol* 2013. doi: 10.1111/ajd.12122. [Epub ahead of print] [PMID:24283504]
6. Elliott RB. Letter: Skin wrinkling in cystic fibrosis. *Lancet* 1974;2:1383. [PMID:4143337]
7. English JC 3rd, McCollough ML. Transient reactive papulotranslucent acrokeratoderma. *J Am Acad Dermatol* 1996;34:686-7. [PMID:8601664]
8. Carder KR, Weston WL. Rofecoxib-induced instant aquagenic wrinkling of the palms. *Pediatr Dermatol*. 2002;19:353-5. [PMID:12220285]
9. Katz KA, Yan AC, Turner ML. Aquagenic wrinkling of the palms in patients with cystic fibrosis homozygous for the delta F508 CFTR mutation. *Arch Dermatol* 2005;141:621-4. [PMID:15897385]
10. Gild R, Clay CD, Morey S. Aquagenic wrinkling of the palms in cystic fibrosis and the cystic fibrosis carrier state: a case-control study. *Br J Dermatol* 2010;163:1082-4. [PMID: 20560957]
11. Gild R, Clay CD. Aquagenic wrinkling of the palms in a cystic fibrosis carrier. *Australas J Dermatol* 2008;49:19-20. [PMID:18186841]
12. Gündüz O, Ozsaraç KÇ, Ercin ME. Aquagenic palmar wrinkling induced by combined use of salazopyrin and indomethacin. *Case Rep Dermatol*. 2013;5:21-6. [PMID:23466824]
13. Bhojani S, Sriskandan S, Bush A. Aquagenic wrinkling of palms on exposure to alcohol gel. *Pediatr Pulmonol* 2011;46:98-9. [PMID:21171188]
14. Sezer E, Erkek E, Duman D, Sahin S, Cetin E. Dermoscopy as an adjunctive diagnostic tool in aquagenic syringeal acrokeratoderma. *Dermatology* 2012;225:97-9. [PMID:22813714]
15. Weedon D. *Skin Pathology*. 3rd ed. Philadelphia: Churchill Livingstone- Elsevier; 2010.
16. Diba VC, Cormack GC, Burrows NP. Botulinum toxin is helpful in aquagenic palmoplantar keratoderma. *Br J Dermatol* 2005;152:394-5. [PMID:15727674]
17. Syed Z, Wanner M, Ibrahim OA. Aquagenic wrinkling of the palms: A case report and literature review. *Dermatol Online J* 2010;16:7. [PMID:20673535]