

# UC Davis

## Dermatology Online Journal

### Title

Circle hair: report of two cases and brief review of the literature

### Permalink

<https://escholarship.org/uc/item/0md8v63f>

### Journal

Dermatology Online Journal, 25(6)

### Authors

Durmaz, Emel Öztürk  
Demirkesen, Cüyan

### Publication Date

2019

### DOI

10.5070/D3256044450

### Copyright Information

Copyright 2019 by the author(s). This work is made available under the terms of a Creative Commons Attribution-NonCommercial-NoDerivatives License, available at <https://creativecommons.org/licenses/by-nc-nd/4.0/>

Peer reviewed

# Circle hair: report of two cases and brief review of the literature

Emel Öztürk Durmaz<sup>1</sup> MD, Cüyan Demirkesen<sup>2</sup> MD

Affiliations: <sup>1</sup>Department of Dermatology, Acıbadem Mehmet Ali Aydınlar University School of Medicine, İstanbul, Turkey, <sup>2</sup>Department of Pathology, Acıbadem Mehmet Ali Aydınlar University School of Medicine, İstanbul, Turkey

Corresponding Author: Emel Öztürk Durmaz MD, Acıbadem Maslak Hospital, Büyükdere Caddesi 40, Maslak 34457, İstanbul, Turkey, Tel: 90-212-3044619, Fax: 90-212-2861566, Email: [emelerkek@yahoo.com](mailto:emelerkek@yahoo.com)

## Abstract

Circle hair (CH) is an interesting subtype of ingrown hair, characterized by the growing of hair shaft in a spiral or circular morphology underneath a translucent layer of stratum corneum, parallel to skin surface. In contrast to rolled hair, neither perifollicular inflammation nor abnormal follicular keratinization are known to accompany CH. The reason why the hair shaft grows circumferentially and transversely under the skin instead of emerging through an apparently open hair follicle ostium and growing vertically remains to be determined. Although CH is a frequent benign incidental finding in normal skin examination, reports on this disorder are scarce. Herein we report two cases of CH and briefly review the existing literature. We believe that CH develops because of trauma in patients having a genetic susceptibility for this disorder and that CH is more common than the relevant medical literature suggests.

Keywords: circle hair, rolled hair

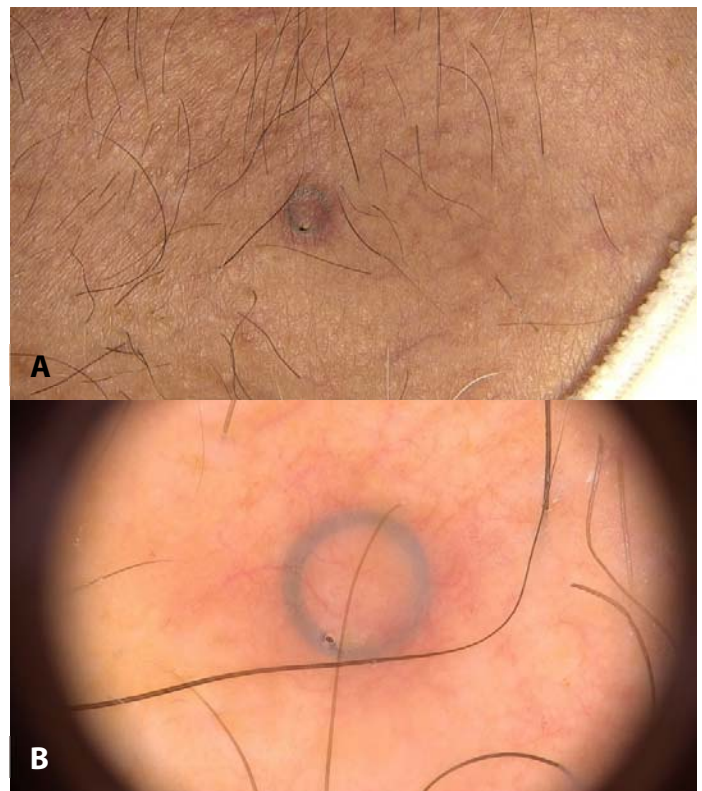
## Introduction

Circle hair (CH) is a unique disorder of hair growth characterized by growing of a hair in a circular or spiral configuration under a translucent layer of stratum corneum, without accompanying abnormality in follicular keratinization or inflammatory perifollicular component [1-5]. It represents an uncommon subtype of ingrown hair [6, 7]. The disorder is usually only of cosmetic

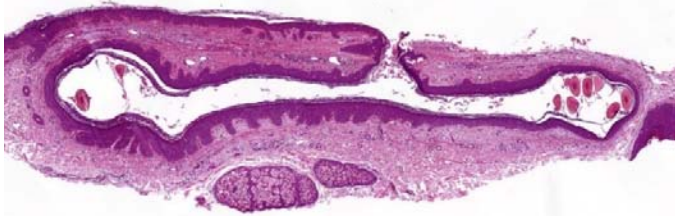
concern [2]. Until now, about 30 patients have been reported to our knowledge [1].

## Case Synopsis:

*Case 1:* A 43-year-old man presented with a newly developed asymptomatic 'black mole' on the chest of one-month duration. The black color had led to a



**Figure 1. A)** Clinical and **B)** dermatoscopic appearance of circle hair. 'Stone ring' configuration; a perfectly ring-like subcorneal concentric hair and a stone-like dilated follicular orifice.



**Figure 2.** A 'river-bed' of dilated, distorted follicular infundibulum, containing transverse-cut sections of a single hair shaft within the lumen. H&E, 100x.

concern for melanoma. He could recall no traumatic insult to the area. His medical and family histories were unremarkable.

On dermatological examination, there was a discoid, slightly elevated, 5mm papule with a blue-black rim, located on the anterior chest (**Figure 1A**). Slight erythema around the lesion has been attributed to manipulation. Dermatoscopy revealed a perfect blue-black concentric hair with a dilated follicular orifice at one side, conforming to the appearance of a 'stone ring' (**Figure 1B**).

Histological examination displayed a "river-bed" of a dilated, distorted follicular infundibulum, containing transverse-cut sections of a single hair shaft within the lumen (**Figure 2**).

**Case 2:** A 5-year-old boy was being followed annually with digitalized dermatoscopy for a one-cm congenital hairy melanocytic nevus on the right buttock. This year, dermatoscopic examination surprisingly revealed two partially embedded circle hairs within the nevus, which were clinically invisible (**Figure 3**).

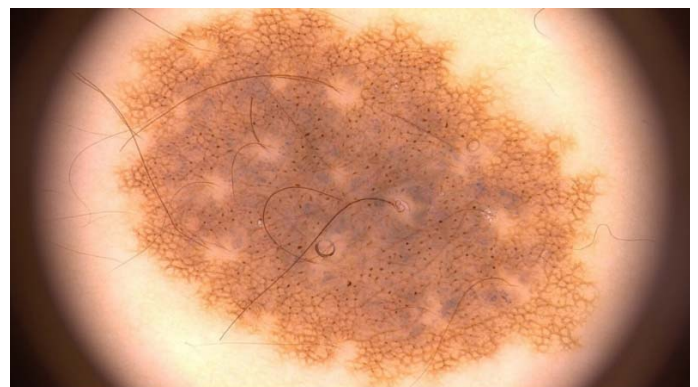## Case Discussion

In 1963 Fergusson and Derblay reported four cases of keratosis pilaris with rolled hairs (RH), [8]. In the same year, Adatto declared that RH may be encountered without evident abnormality of the hair follicles [9]. Thereafter, the term CH has been coined to describe perfectly circular or spiral hair shafts without associated hair follicle abnormality or perifollicular inflammation [4, 10]. Although CH and RH are not synonymous and denote distinct entities,

they are still commonly used interchangeably in the medical literature [3, 6, 10].

The frequency of CH has been estimated at 12–16% of the population in France [5]. The scarcity of published cases of CH may be explained by the asymptomatic nature of this disorder and invisibility of most lesions to the naked eye. Medical consultation is rarely requested for CH and as exemplified in Case 2, this minor alteration is frequently a benign incidental finding during skin examination for other complaints [1-5, 11]. We believe that CH is more common than the relevant literature implicates. Most of the reported patients with CH are adult males older than 50 years [1, 3, 6, 10]. Our second case is the youngest patient reported to date and possibly refutes the role of age as a distinctive epidemiological criterion.

Circle hairs are usually discovered on the torso (back, chest, shoulders, abdomen) and thighs of overweight hairy elderly male patients [1, 3-5, 7, 11]. Buttocks and upper limbs may also be involved [2, 5]. A similar disorder affecting the eyelashes (circle lash) has been reported [12]. CH are usually interspersed among normal straight hairs as perfect rings or circles embedded in stratum corneum [1, 3-5]. Tightly twisted hair shafts form round loops under a thin skin layer and by dermatoscopy, they are visualized as dark concentric rings or circles next to hair follicle ostia [2, 4, 11]. In our first case, a dilated hair follicle ostium and the perfect circling of hair underneath the skin led to a 'stone ring-like' appearance. Whole or part of CH may protrude out of the skin [1, 2]. Hair can easily be extracted after



**Figure 3.** Dermatoscopy showing two circle hairs partially embedded within a congenital melanocytic nevus.

superficial scraping with a sharp blade and uncoiled to a length of less than 2.5cm. When released, the hair regains its original format by either partially or fully recoiling [2-5, 7, 11]. When uncoiled, CH demonstrates a typical “question mark” outline and its diameter tends to be slightly less than surrounding straight hairs [1-5]. Treatment is unnecessary in CH and reassurance is all that is required [5].

The histopathologic portrait of CH encompasses a “river bed” of a dilated follicular infundibulum with entrapped hair shaft. There is no obstruction at the follicular ostium and there is no evidence of perifollicular inflammation [1, 4].

The etiology and pathogenesis of CH remains elusive. Trauma (waxing, friction) has been suggested as a potential etiological factor [2]. Currently the pathogenesis is based on three theories. Some authors speculate that CH has a small hair diameter and insufficient hair shaft strength impedes perforation of the stratum corneum, which in turn causes the hair to grow in a circular/spiral horizontal track in a subcorneal location [1-4, 11]. Other authors claim that the follicular ostium is always open and does not hinder vertical hair growth; thus, they propose that CH is probably a genetically determined predisposition [1, 2, 5, 11]. Finally, some authors suggest that since CH usually develops in hairy individuals, the possibility that it represents vestigia (or remnants) of the woolly mammal undercoat that once had a part in preserving body heat and has disappeared during human evolution cannot be discounted [1, 2, 4, 5, 11].

In our first case, the follicular ostium was not only open, but clinically visibly dilated, probably secondary to infundibular dilatation. We believe that CH develops because of trauma (picking of hairs, pulling by clothing, friction) in patients having a genetic susceptibility for this disorder.

## References

1. Lacarrubba F, Misciali C, Gibilisco R, Micali G. Circle hairs: clinical, trichoscopic and histopathologic findings. *Int J Trichology*. 2013;5:211-3. [PMID: 24778535].
2. Nair PA, Patel T, Navadiya R. Circle Hairs Involving the Extremities in a Young Girl. *Int J Trichology*. 2018;10:26-28. [PMID: 29440855].
3. Smith JB, Hogan DJ. Circle hairs are not rolled hairs. *J Am Acad Dermatol*. 1996;35:634-5. [PMID: 8859298].

The most important condition in the differential diagnosis is RH, a disorder similar but distinct from CH [3, 7]. RH is comparatively a more frequent disorder of hair growth and it is almost exclusively associated with follicular hyperkeratosis, keratin plugging, and signs of inflammation [2-4]. Familial and acquired variants have been described [6]. It affects males between 55 to 69 years of age and the sites of predilection include the extensor aspects of the upper arms, backs, buttocks, and shoulders [4, 10]. In contrast to CH, RH are not perfectly circular. Rather, they appear as irregularly twisted spirals within hyperkeratotic follicular plugs [1-4]. The list of disorders and conditions accompanying RH includes keratosis pilaris, atopic dermatitis, scurvy (corkscrew hairs), corticosteroid and cyclosporine therapy, Cushing disease, juvenile hypothyroidism, xerosis, neurodermatitis, ichthyosis, hypertrichosis, and palmoplantar keratoderma [1-7, 10, 11]. Some authors believe that RH is caused by mechanical trauma such as repeated and vigorous rubbing [4]. Histologic examination reveals follicular hyperkeratosis. Therefore, it has been postulated that RH develops because of abnormal keratinization of the distal hair follicle that blocks the hair shaft from emerging in normal style and leads to spiral transverse growth underneath the skin [4, 6, 10].

## Conclusion

Although CH is a frequent benign incidental finding in normal skin examination, reports on this disorder are scarce. We believe that CH develops because of trauma in patients having a genetic susceptibility for this disorder and that CH is more common than the relevant medical literature suggests.

## Potential conflicts of interest

The authors declare no conflicts of interests.

4. Panchaprateep R, Tanus A, Tosti A. Clinical, dermoscopic, and histopathologic features of body hair disorders. *J Am Acad Dermatol*. 2015;72:890-900. [PMID: 25748313].
5. Contreras-Ruiz J, Duran-McKinster C, Tamayo-Sanchez L, Orozco-Covarrubias L, Ruiz-Maldonado R. Circle hairs: a clinical curiosity. *J Eur Acad Dermatol Venereol*. 2000;14:495-7. [PMID: 11444273].
6. Itin PH, Bircher AJ, Lautenschlager S, Zuberbühler E, Guggenheim R. A new clinical disorder of twisted and rolled body hairs with multiple, large knots. *J Am Acad Dermatol*. 1994;30:31-5. [PMID: 8277027].
7. Whiting DA. Structural abnormalities of the hair shaft. *J Am Acad Dermatol*. 1987;16(1 Pt1):1-25. [PMID: 3805378].
8. Fergusson AG, Derblay PR. Rolled hairs, a possible complication of corticosteroid therapy. *Arch Dermatol*. 1963;87:311-4. [PMID: 13944754].
9. Adatto R. [Spiral hair (coiled hair)]. *Dermatologica*. 1963;127:145-7. [PMID: 14045370].
10. Levit F, Scott MJ Jr. Circle hairs. *J Am Acad Dermatol*. 1983;8:423-5. [PMID: 6833546].
11. Nair PA, Kota RS, Gandhi S, Singhal RR. A Rare Association of Pili Multigemini and Rolled Hairs in a Young Female. *Int J Trichology*. 2016;8:29-31. [PMID: 27127374].
12. Happle R. Cilium circinatum (circle lash, ringelwimper, cil enroulé). *Dermatology*. 1996;192:292. [PMID: 8726655].