

UC Irvine

Clinical Practice and Cases in Emergency Medicine

Title

CPC-EM Full-Text Issue

Permalink

<https://escholarship.org/uc/item/0p03278v>

Journal

Clinical Practice and Cases in Emergency Medicine, 2(2)

Author

Hernandez, Nancy G.

Publication Date

2018

Copyright Information

Copyright 2018 by the author(s). This work is made available under the terms of a Creative Commons Attribution License, available at <https://creativecommons.org/licenses/by/4.0/>

Peer reviewed

CPC Emergency Medicine

Volume II, Number 2, May 2018

Open Access at www.cpcem.org

ISSN: 2474-252X

Clinical Practice and Cases in Emergency Medicine

In Collaboration with the *Western Journal of Emergency Medicine*

Clinicopathological Cases from the University of Maryland

- 103 **52-Year-Old Jehovah's Witness Female with Weakness**
LA Weiner, G Willis, ZDW Dezman, LJ Bontempo

Medical Legal Case Reports

- 109 **Emergency Physicians: Beware of the Consent Standard of Care**
GP Moore, AG Matlock, JL Kiley, KD Percy

Case Reports

- 112 **Latest Considerations in Diagnosis and Treatment of Appendicitis During Pregnancy**
S Lotfipour, M Jason, VJ Liu, M Helmy, W Hoonpongsimanont, CE McCoy, B Chakravarthy,
- 116 **Intra-abdominal Rupture of a Live Cervical Pregnancy with Placenta Accreta but Without Vaginal Bleeding**
A Tariq, M O'Rourke, SJ Carstens, VY Totten
- 121 **Trigeminal Trophic Syndrome Leading to Orbital Cellulitis**
LB Thompson, SL Powell
- 125 **Papilledema: Point-of-Care Ultrasound Diagnosis in the Emergency Department**
JR Sinnott, MR Mohebbi, T Koboldt
- 128 **Significant Lactic Acidosis from Albuterol**
M Hockstein, D Diercks
- 132 **Diagnosis of Hand Infections in Intravenous Drug Users by Ultrasound and Water Bath: A Case Series**
J DeAngelis, E St. James, PC Lema
- 136 **Facial Baroparesis Mimicking Stroke**
DM Krywko, DT Clare, M Orabi
- 139 **An Unlikely Cause of Abdominal Pain**
N Kairys, K Skidmore, J Repanshek, W Satz

Contents continued on page iii



UC Irvine Health





Are You Ready for the Launch of the FOEM Research Network?

Calling residents, students, researchers, program directors, and pharma reps!

The FOEM Research Network is launching this spring! This state-of-the-art, easy to use website connects researchers and research sites for easily accessible multicenter studies! Users can search by research topic, location, and more to help get their finger on the pulse of the most cutting-edge research in EM. Stay tuned for more information on this momentous achievement!



Find us at frn.foem.org

FOEM
FOUNDATION FOR OSTEOPATHIC
EMERGENCY • MEDICINE

Clinical Practice and Cases in Emergency Medicine

In Collaboration with the *Western Journal of Emergency Medicine*

Rick A. McPheeters, DO, Editor-in-Chief
Kern Medical

Manish Amin, DO, Associate Editor
Kern Medical

Mark I. Langdorf, MD, MHPE, Associate Editor
University of California, Irvine School of Medicine

Shadi Lahham, MD, MS, Associate Editor
University of California, Irvine School of Medicine

Shahram Lotfipour, MD, MPH, Managing Associate Editor
University of California, Irvine School of Medicine

Editorial Board

Amin A. Kazzi, MD, MAAEM
*The American University of Beirut,
Beirut, Lebanon*

Anwar Al-Awadhi, MD
*Mubarak Al-Kabeer Hospital,
Jabriya, Kuwait*

Arif A. Cevik, MD
*United Arab Emirates University
College of Medicine and Health
Sciences, Al Ain, United Arab Emirates*

Abhinandan A. Desai, MD
*University of Bombay Grant Medical
College, Bombay, India*

Bandr Mzahim, MD
*King Fahad Medical City, Riyadh,
Saudi Arabia*

Barry E. Brenner, MD, MPH
Case Western Reserve University

Brent King, MD, MMM
University of Texas, Houston

Daniel J. Dire, MD
*University of Texas Health Sciences
Center San Antonio*

David F.M. Brown, MD
*Massachusetts General Hospital/
Harvard Medical School*

Edward Michelson, MD
*Texas Tech University
Edward Panacek, MD, MPH
University of South Alabama*

Erik D. Barton, MD, MBA
*Icahn School of Medicine, Mount
Sinai, New York*

Francesco Dellacorte, MD
*Azienda Ospedaliera Universitaria
"Maggiore della Carità," Novara, Italy*

Francis Counselman, MD
Eastern Virginia Medical School

Gayle Galleta, MD
*Sorlandet Sykehus HF, Akershus
Universitetssykehus, Lorenskog, Norway*

Jacob (Kobi) Peleg, PhD, MPH
Tel-Aviv University, Tel-Aviv, Israel

Jonathan Olshaker, MD
Boston University

Katsuhiko Kanemaru, MD
*University of Miyazaki Hospital,
Miyazaki, Japan*

Khrongwong Musikatavorn, MD
*King Chulalongkorn Memorial
Hospital, Chulalongkorn University,
Bangkok, Thailand*

Leslie Zun, MD, MBA
Chicago Medical School

Linda S. Murphy, MLIS
*University of California, Irvine School
of Medicine Librarian*

Nadeem Qureshi, MD
*St. Louis University, USA
Emirates Society of Emergency
Medicine, United Arab Emirates*

Niels K. Rathlev, MD
Tufts University School of Medicine

Pablo Aguilera Fuenzalida, MD
*Pontificia Universidad Catolica de Chile,
Región Metropolitana, Chile*

Peter A. Bell, DO, MBA
*Liberty University
College of Osteopathic Medicine*

Peter Sokolove, MD
University of California, San Francisco

Robert M. Rodriguez, MD
University of California, San Francisco

Robert Suter, DO, MHA
UT Southwestern Medical Center

Robert W. Derlet, MD
University of California, Davis

Rosidah Ibrahim, MD
*Hospital Serdang, Selangor,
Malaysia*

Samuel J. Stratton, MD, MPH
Orange County, CA, EMS Agency

Scott Rudkin, MD, MBA
University of California, Irvine

Scott Zeller, MD
University of California, Riverside

Steven Gabaeff, MD
Clinical Forensic Medicine

Steven H. Lim, MD
*Changi General Hospital, Simei,
Singapore*

Terry Mulligan, DO, MPH, FIFEM
*ACEP Ambassador to the
Netherlands Society of Emergency
Physicians*

Vijay Gautam, MBBS
*University of London, London,
England*

Wirachin Hoonpongsimanont, MD,
MSBATS
*Siriraj Hospital, Mahidol University,
Bangkok, Thailand*

Advisory Board

Amal Khalil, MBA
UC Irvine Health SOM

Elena Lopez-Gusman
*California ACEP
American College of Emergency
Physicians*

Janice Wachtler, BAE, CBA
*American College of Osteopathic
Emergency Physicians*

John B. Christensen, MD
California Chapter Division of AAEM

Lori Winston, MD
*California ACEP
American College of Emergency
Physicians
Kaweah Delta Healthcare District*

Mark I. Langdorf, MD, MHPE
UC Irvine Health SOM

Nicholas T. Sawyer, MD, MBA
*California ACEP
American College of Emergency
Physicians
University of California, Davis*

Peter A. Bell, DO, MBA
*American College of Osteopathic
Emergency Physicians
Liberty University, College of
Osteopathic Medicine*

Robert Suter, DO, MHA
*American College of Osteopathic
Emergency Physicians
UT Southwestern Medical Center*

Shahram Lotfipour, MD, MPH
UC Irvine Health SOM

Trevor Mills, MD, MPH
*California Chapter Division of AAEM
LSU Medical Center*

Editorial Staff

Ahdilah Haswary, BS
Editorial Director

Jimmy To, BS
Associate Editorial Director

Tushank Chadha, BS
Marketing Director

Nancy G. Hernandez, BA
Publishing Director

Tracy Nguyen, BS
Associate Publishing Director

June Casey, BA
Copy Editor

Alissa Fiorentino, BA
WestJEM Staff Liaison

Clinical Practice and Cases in Emergency Medicine

In Collaboration with the *Western Journal of Emergency Medicine*

This open access publication would not be possible without the generous and continual financial support of our society sponsors, department and chapter subscribers.

Professional Society Sponsors

AMERICAN COLLEGE OF OSTEOPATHIC EMERGENCY PHYSICIANS
CALIFORNIA ACEP

CALIFORNIA CHAPTER DIVISION OF
AMERICAN ACADEMY OF EMERGENCY MEDICINE

Academic Department of Emergency Medicine Subscriber

Albany Medical College Albany, NY	INTEGRIS Health Oklahoma City, OK	Robert Wood Johnson University Hospital New Brunswick, NJ	University of Florida, Jacksonville Jacksonville, FL
American University of Beirut Beirut, Lebanon	Kaweah Delta Health Care District Visalia, CA	Rush University Medical Center Chicago, IL	University of Illinois at Chicago Chicago, IL
Arrowhead Regional Medical Center Colton, CA	Kennedy University Hospitals Turnersville, NJ	Southern Illinois University Carbondale, IL	University of Illinois College of Medicine Peoria, IL
Augusta University Augusta GA	Kern Medical Bakersfield, CA	St. Luke's University Health Network Bethlehem, PA	University of Iowa Iowa City, IA
Baystate Medical Center Springfield, MA	Lakeland HealthCare St. Joseph, MI	Stanford/Kaiser Emergency Medicine Residency Program Stanford, CA	University of Louisville Louisville, KY
Beaumont Hospital Royal Oak, MI	Lehigh Valley Hospital and Health Network Allentown, PA	Staten Island University Hospital Staten Island, NY	University of Maryland Baltimore, MD
Beth Israel Deaconess Medical Center Boston, MA	Loma Linda University Medical Center Loma Linda, CA	SUNY Upstate Medical University Syracuse, NY	University of Michigan Ann Arbor, MI
Boston Medical Center Boston, MA	Louisiana State University Health Sciences Center New Orleans, LA	Temple University Philadelphia, PA	University of Missouri, Columbia Columbia, MO
Brigham and Women's Hospital Boston, MA	Madigan Army Medical Center Tacoma, WA	Texas Tech University Health Sciences Center El Paso, TX	University of Nebraska Medical Center Omaha, NE
Brown University Providence, RI	Maimonides Medical Center Brooklyn, NY	University of Alabama, Birmingham Birmingham, AL	University of South Alabama Mobile, AL
Carl R. Darnall Army Medical Center Fort Hood, TX	Maricopa Medical Center Phoenix, AZ	University of Arkansas for Medical Sciences Little Rock, AR	University of Southern California/Keck School of Medicine Los Angeles, CA
Conemaugh Memorial Medical Center Johnstown, PA	Massachusetts General Hospital Boston, MA	University of California, Davis Medical Center Sacramento, CA	University of Tennessee, Memphis Memphis, TN
Desert Regional Medical Center Palm Springs, CA	Mayo Clinic College of Medicine Rochester, MN	University of California Irvine Orange, CA	University of Texas, Houston Houston, TX
Doctors Hospital/Ohio Health Columbus, OH	Mt. Sinai Medical Center Miami Beach, FL	University of California, Los Angeles Los Angeles, CA	University of Texas Health San Antonio, TX
Eastern Virginia Medical School Norfolk, VA	North Shore University Hospital Manhasset, NY	University of California, San Diego La Jolla, CA	University of Warwick Library Coventry, United Kingdom
Einstein Healthcare Network Philadelphia, PA	Northwestern Medical Group Chicago, IL	University of California, San Francisco San Francisco, CA	University of Washington Seattle, WA
Emory University Atlanta, GA	Ohio State University Medical Center Columbus, OH	UCSF Fresno Center Fresno, CA	University of Wisconsin Hospitals and Clinics Madison, WI
Genesys Regional Medical Center Grand Blanc, Michigan	Ohio Valley Medical Center Wheeling, WV	University of Chicago, Chicago, IL	Wake Forest University Winston-Salem, NC
Hartford Hospital Hartford, CT	Oregon Health and Science University Portland, OR	University of Colorado, Denver Denver, CO	Wright State University Dayton, OH
Hennepin County Medical Center Minneapolis, MN	Penn State Milton S. Hershey Medical Center Hershey, PA	University of Florida Gainesville, FL	
Henry Ford Hospital Detroit, MI	Presence Resurrection Medical Center Chicago, IL		

State Chapter Subscriber

ARIZONA CHAPTER DIVISION OF THE
AMERICAN ACADEMY OF EMERGENCY MEDICINE
CALIFORNIA CHAPTER DIVISION OF THE
AMERICAN ACADEMY OF EMERGENCY MEDICINE
FLORIDA CHAPTER DIVISION OF THE
AMERICAN ACADEMY OF EMERGENCY MEDICINE

GREAT LAKES CHAPTER DIVISION OF THE
AMERICAN ACADEMY OF EMERGENCY MEDICINE
TENNESSEE CHAPTER DIVISION OF THE
AMERICAN ACADEMY OF EMERGENCY MEDICINE

UNIFORMED SERVICES CHAPTER DIVISION OF THE
AMERICAN ACADEMY OF EMERGENCY MEDICINE
VIRGINIA CHAPTER DIVISION OF THE
AMERICAN ACADEMY OF EMERGENCY MEDICINE

International Society Partners

EMERGENCY MEDICINE ASSOCIATION OF TURKEY
LEBANESE ACADEMY OF EMERGENCY MEDICINE
MEDITERRANEAN SOCIETY OF EMERGENCY MEDICINE

NORWEGIAN SOCIETY FOR EMERGENCY MEDICINE
SOCIEDAD ARGENTINA DE EMERGENCIAS

SOCIEDAD CHILENO MEDICINA URGENCIA
THAI ASSOCIATION FOR EMERGENCY MEDICINE

To become a *WestJEM* departmental sponsor, waive article processing fee, receive print and copies for all faculty and electronic for faculty/residents, and free CME and faculty/fellow position advertisement space, please go to <http://westjem.com/subscribe> or contact:

Alissa Fiorentino
WestJEM Staff Liaison
Phone: 1-800-884-2236
Email: sales@westjem.org

Clinical Practice and Cases in Emergency Medicine

In Collaboration with the *Western Journal of Emergency Medicine*

JOURNAL FOCUS

Clinical Practice and Cases in Emergency Medicine (CPC-EM) is an internationally recognized journal affiliated with the MEDLINE-indexed *Western Journal of Emergency Medicine* (WestJEM). It will offer the latest in patient care case reports, images in the field of emergency medicine and state of the art clinicopathological cases. CPC-EM is fully open-access, peer reviewed, well indexed and available anywhere with an internet connection. CPC-EM encourages submissions from junior authors, established faculty, and residents of established and developing emergency medicine programs throughout the world.

Table of Contents *continued*

- 143 Ultrasound-guided Placement of a Foley Catheter Using a Hydrophilic Guide Wire**
R Joseph, M Huber, B Leeson, K Leeson
- 147 Scurvy: Dietary Discretion in a Developed Country**
ME Perry, N Page, DE Manthey, JM Zavitz
- 151 Spontaneous Spinal Epidural Hematoma from Rivaroxaban**
C Goldfine, C Glazer, RM Ratzan
- 155 Clozapine Intoxication Mimicking Acute Stroke**
JA Lebin, JD Villarreal, BC Chen, MK Hall
- 158 Takotsubo Cardiomyopathy in the Emergency Department: A FOCUS Heart Breaker**
K Meigh, M Caja, M Sharon, A Tadros, S Dragan, D Henkel, J Minardi

Images in Emergency Medicine

- 163 Hyperkalemia Brugada Sign: When Catheterization Lab Is Not the Answer**
RM Kukkamalla, E Katz
- 165 Man with Total Knee Arthroplasty Now Unable to Extend the Joint**
M Barden, JKA Kasarjian
- 167 Vascular Occlusion after Hyaluronic Acid Filler Injection**
S Grzybinski, E Temin
- 169 Adult Male with Traumatic Eye Pain and Swelling**
M Leshner, R Gibbons, T Costantino
- 171 An Unusual Cause of Acute Urinary Retention**
AJ Smith, P Blackburn
- 173 An Unexpected Cause of Persistent Coughing**
M Myers, J Cohen
- 175 Adolescent with Stroke-like Symptoms**
JC Mazzei, S Louka, R Gopaul, L Taylor
- 177 Temporary Tracheal Compression by Dilated Functionally Normal Esophagus**
T Sengoku, T Sonoo, K Kira, Y Takahashi, H Hashimoto, K Nakamura
- 179 Atypical Presentation of Hand, Foot, and Mouth Disease in an Adult**
DN Lipe, S Affleck

Policies for peer review, author instructions, conflicts of interest and human and animal subjects protections can be found online at www.cpcem.org.

52-Year-Old Jehovah's Witness Female with Weakness

Lindsay A. Weiner, MD*

George Willis, MD†

Zachary D.W. Dezman, MD, MS, MS†

Laura J. Bontempo, MD, MEd†

*University of Maryland Medical Center, Baltimore, Maryland

†University of Maryland School of Medicine, Department of Emergency Medicine, Baltimore, Maryland

Section Editor: Rick A. McPheeters, DO

Submission history: Submitted January 22, 2018; Revision received March 19, 2018; Accepted March 21, 2018

Electronically published April 13, 2018

Full text available through open access at http://escholarship.org/uc/uciem_cpccm

DOI: 10.5811/cpcem.2018.3.37699

[Clin Pract Cases Emerg Med. 2018;2(2):103-108.]

CASE PRESENTATION

A 52-year-old woman came to the emergency department (ED) for hemodialysis (HD) due to end-stage renal disease (ESRD). She had spent the preceding several weeks in an outside hospital being treated for pneumonia and bacteremia with daptomycin. She subsequently left against medical advice (AMA) after having her dialysis access catheter removed. She presented to our ED because she needed HD vascular access placement and re-initiation of dialysis treatments. Her medical history included chronic kidney disease secondary to hypertensive nephrosclerosis, anemia, hypertension, deep venous thromboses (DVT), systemic lupus erythematosus, and a seizure disorder of unknown etiology.

The patient, a Jehovah's Witness, refused blood transfusions; therefore, her anemia was being treated with intravenous (IV) administration of iron, epoetin alfa, and folate. Other medications included nifedipine, clonidine, metoprolol, sevelamer, and prednisone. She was allergic to amoxicillin, azithromycin, hydralazine, labetalol, linezolid, morphine, and vancomycin. She reported previous IV heroin use many years earlier and previous cigarette smoking. She denied alcohol use or any current drug or tobacco use.

Upon arrival, she was alert and in no acute distress with a fever of 38.3° Celsius, heart rate of 87 beats per minute (bpm), blood pressure of 110/65 millimeters mercury (mmHg), respiratory rate of 17 breaths per minute, and pulse oximetry of 99% while breathing room air. She weighed 80 kilograms and was 5 feet 6 inches tall. Her head was normocephalic and atraumatic with moist mucous membranes. Pupils were anicteric, equal, round, and reactive to light and accommodation. The neck was supple and without lymphadenopathy or tenderness. Her lungs had coarse breath sounds with mild bibasilar crackles but no wheezes or rhonchi. There were no retractions or increased work of breathing. Her heart was of regular rate and rhythm without murmurs, rubs, or gallops. Her abdomen was soft with normal bowel sounds and without distention, tenderness, rebound, or guarding.

There was no costovertebral angle tenderness. The lower extremities had 1+ pitting edema, 2+ dorsalis pedis pulses, and were without tenderness or deformity. The patient had normal strength and muscle tone throughout all extremities with intact sensation. Old fistulas were present in the left and right upper extremities without palpable thrills. She was alert and oriented to person, place, and time.

The patient's initial laboratory values are shown in Table 1. These were significant for a slight leukocytosis, anemia to 5.3 g/dL, thrombocytopenia, hyperkalemia, and an elevated creatinine of 11.9 mg/dL. Her initial electrocardiogram (ECG) showed a sinus tachycardia with T-wave inversions in leads I and V6 (Image 1). This was unchanged from a prior ECG. The patient was admitted to the medicine team and was

Table 1. Initial laboratory results for patient presenting for hemodialysis due to end-stage renal disease.

	Values
Complete blood cell count	
White blood cell count	12.4 K/mcl
Hemoglobin	5.3 g/dL
Hematocrit	15.8%
Platelets	133 K/mcl
Basic metabolic panel	
Sodium	135 mmol/L
Potassium	5.8 mmol/L
Chloride	99 mmol/L
Bicarbonate	27 mmol/L
Blood urea nitrogen	56 mg/dL
Creatinine	11.9 mg/dL
Glucose	189 mg/dL
Calcium	7.2 mg/dL

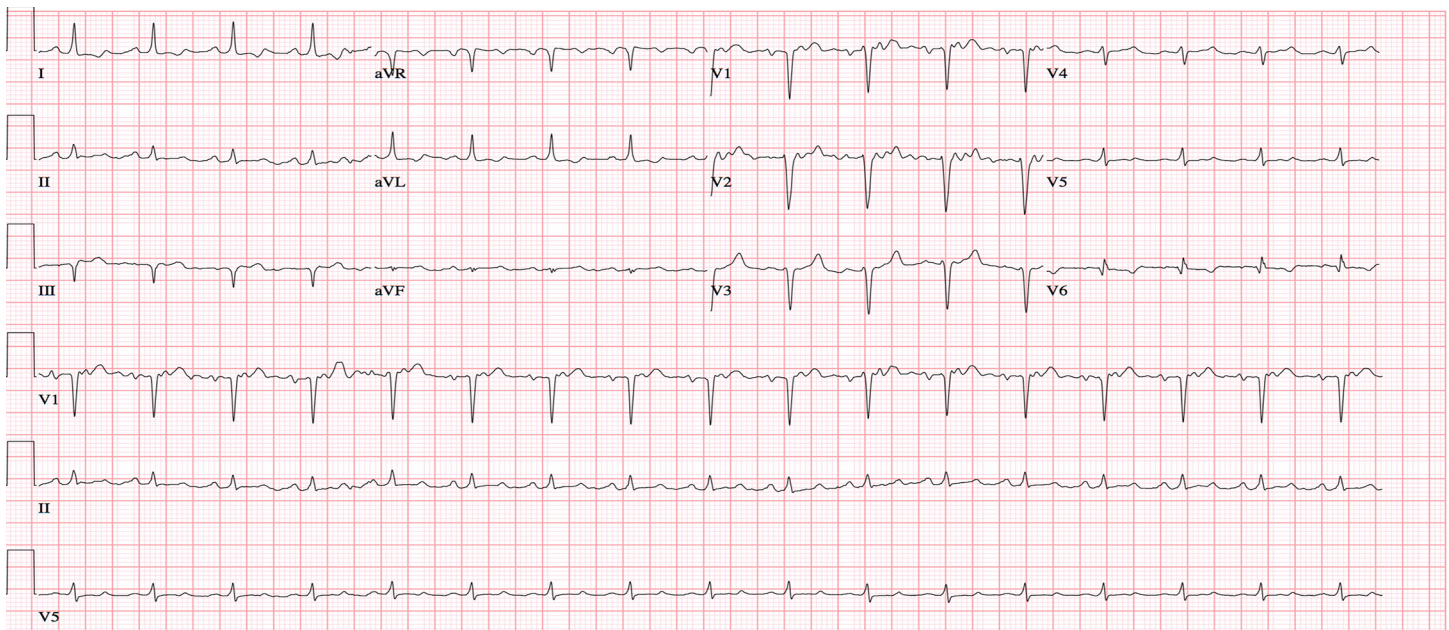


Image 1. Initial electrocardiogram obtained in the emergency department of a Jehovah's Witness dialysis patient with serum potassium of 5.8.

started on daptomycin. While awaiting bed placement, a non-tunneled left femoral dialysis catheter was inserted by the medical intensive care unit (ICU) fellow for initiation of HD. Placement was confirmed by the easy drawback of blood from all ports. During the consent process for catheter placement, it was documented that the patient stated she “would rather die than receive blood transfusions.” Following catheter placement, an attempt was made to start HD, but she became hypotensive and complained of weakness almost immediately. Her vital signs during the initial HD attempt were a blood pressure of 85/56 mmHg with a heart rate of 105 bpm.

Because the patient was symptomatic and hypotensive during HD, continuous renal replacement therapy (CRRT) was initiated. Shortly afterward, she became hypotensive, unresponsive, and had a tonic clonic seizure. Vital signs at that time were a heart rate of 113 bpm, blood pressure 75/48 mmHg, respiratory rate of 20 breaths per minute, and oxygen saturation of 78% on room air. A brief, repeat physical exam showed the patient was unresponsive to painful stimuli and her pupils were equal and reactive. She was given 4 mg of lorazepam and intubated for airway protection. A right arterial femoral line and a right femoral triple lumen venous central line were placed. A chest radiograph confirmed endotracheal tube placement (Image 2). CRRT was halted but the patient remained in shock despite bolus infusions of crystalloid, so vasopressors were started. She was receiving escalating doses of vasopressors when repeat laboratory values indicated a hemoglobin of 1.6 g/dL (Table 2).

Shortly thereafter she went into cardiac arrest with a rhythm of pulseless electrical activity (PEA). Return of

spontaneous circulation was achieved after six minutes of cardiopulmonary resuscitation. Increased abdominal distention was noted during the resuscitation; therefore, a pressure-sensing urinary catheter was introduced. Her peak airway and bladder pressures were measured at greater than 60 cmH₂O and 50 mmHg, respectively. Surgery was then consulted. A massive transfusion protocol was initiated after her next of kin agreed to allow the transfusion of blood products. A focused assessment with sonography for trauma (FAST) was performed, showing free fluid in Morrison's pouch. As resuscitative measures were continued, an additional study was obtained and a diagnosis was made.

CASE DISCUSSION

This case presented with a unique and circuitous sequence of events that spiraled very quickly in an unfortunate direction. When presented with patients who have vague or minimal complaints, it is incumbent on providers to search for clues to assist in making the diagnosis. Therefore, I began by searching for the clues in this case.

The patient presented with a chief complaint of needing dialysis. She had recently been admitted at another facility for pneumonia and bacteremia and had her HD catheter removed due to suspicion for line sepsis. She signed out AMA from this facility after receiving daptomycin. It is unknown how long she had been without HD or if she finished her course of antibiotics prior to leaving. However, she is essentially asymptomatic.

Her past medical history is notable for seizures as well as DVTs and anemia. There is no mention of any anticoagulant

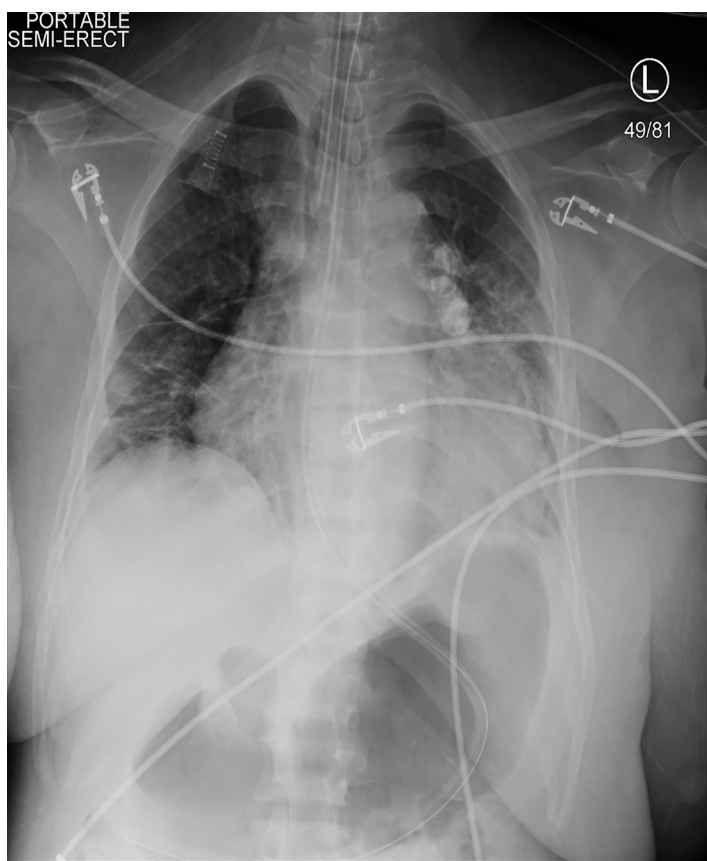


Image 2. Post-intubation chest radiograph (posteroanterior view) showing proper endotracheal and nasogastric tube placement

or antiepileptic medications, which indicates she either did not remember the names of her medications or she was not taking any. Of note, she is a Jehovah's Witness and therefore received alternate therapies for her anemia, including iron, folate, and epogen.

Her physical exam reveals her to be febrile but with otherwise stable vital signs. I would expect this considering that she had left the other facility and likely didn't finish her antibiotic course for her pneumonia and bacteremia. Other possibilities include an infection resistant to the antibiotic or a newly-acquired nosocomial infection from her previous hospital stay. She has some coarse breath sounds and bibasilar crackles on her lung exam, which corroborates her pneumonia history. The pneumonia is most likely the source of her fever as well as the bacteremia, which may not present with symptoms.

Her laboratory studies revealed some pertinent findings. She was anemic as well as hyperkalemic. She was also hypocalcemic and hyperphosphatemic. She had some mild uremia as well. Most of these findings would be somewhat expected in an ESRD patient. The anemia may be the result of kidney disease. Other possibilities on the differential diagnosis for anemia include hemorrhage, iron deficiency, and folate deficiency. She does not complain of any blood loss nor do we

Table 2. Repeat laboratory values.

	Values (prior value)
Complete blood cell count	
White blood cell count	13.4 K/mcl (12.4 K/mcl)
Hemoglobin	1.6 g/dL (5.3 g/dL)
Hematocrit	5.7% (15.8%)
Platelets	167 K/mcl (133K/mcl)
Complete metabolic panel	
Sodium	131 mmol/L
Potassium	6.7 mmol/L
Chloride	99 mmol/L
Bicarbonate	14 mmol/L
Blood urea nitrogen	56 mg/dL
Creatinine	11.9 mg/dL
Glucose	169 mg/dL
Alanine aminotransferase	23 u/L
Aspartate aminotransferase	31 u/L
Alkaline phosphatase	145 u/L
Total bilirubin	0.4 mg/dL
Total protein	5.8 g/dL
Albumin	3.2 g/dL
Lactate	15 u/L
Arterial blood gas	
pH	7.23
PCO ₂	28 mmHg
PO ₂	214 mmHg

have the red blood cell indices such as the mean corpuscular volume to be able to make these alternative diagnoses at this point. Her hyperkalemia is most likely from her lack of HD. Her hyperphosphatemia is also most likely from lack of HD; however, daptomycin can cause hyperphosphatemia as well.

While waiting for bed placement, she has HD started during which she begins complaining of feeling weak and is noted to become hypotensive and tachycardic. She then has CRRT initiated and remains hypotensive, becomes hypoxic, unresponsive and has a tonic-clonic seizure requiring intubation and vasopressor initiation. Exam shows equal and reactive pupils in a patient unresponsive to painful stimuli. Laboratory studies reveal a profoundly worsening anemia, worsening hyperkalemia, and interval development of a lactic acidosis. She then goes into a PEA arrest and, after successful return of spontaneous circulation, has blood transfused. However, she is still hypotensive and hypoxic despite intubation. She also has a distended abdomen and peak airway pressures greater than 60 cmH₂O. A FAST exam reveals free fluid in Morrison's pouch.

Such a profound status change after a therapeutic intervention requires serious thought. Let's start with the hypotension and tachycardia during HD and subsequent CRRT. Hypotension during HD is certainly possible with higher flow rates. However, CRRT has much slower flow rates and hypotension is less frequent when CRRT is used. So why is this person in shock requiring vasopressors after initiation of HD?

When approaching patients with shock, the mnemonic SHOCK (septic/spinal; hypovolemic; obstructive; cardiogenic; anaphylactic – K as in lactic) comes to my mind. Sepsis is certainly possible, given her history of bacteremia. However, it is less likely to be the cause of such a profound decompensation, especially with an acute onset in the setting of initiating HD. Hypovolemic or hemorrhagic shock is another possibility. She does have risk factors for both as she may be on anticoagulation with her history of DVT, as well as possibly having uremic platelet malfunction. This will need to be investigated further. Obstructive shock as in pulmonary embolism or tamponade is another possibility. She certainly has risk factors for this with her history of DVT and unknown anticoagulation status. She is also hypoxic, which is not explained by the pneumonia because her original saturations were above 95%. She could also have developed tamponade from uremic pericarditis, although this is less likely given that her blood urea nitrogen (BUN) is not significantly elevated and she had no complaints of pericarditis symptoms. Another possible cause of hemodynamic collapse leading to obstructive shock is an air embolism from the new HD catheter and subsequent initiation of HD through it. Because this is possible, we need to tease this out a little more as well.

Cardiogenic shock is less likely as she is unlikely to have developed a painless myocardial infarction so severe that she went into cardiogenic shock. Anaphylactic and endocrine issues are other possible causes of shock. However, there were no medications administered or any mention of rash or airway compromise to suggest anaphylaxis as a cause. Endocrine shock should be considered as she is on prednisone, making adrenal insufficiency a possible cause. The hyperkalemia and hyponatremia that you would expect with adrenal insufficiency are present; however, there is no mention of noncompliance or vomiting of the steroids, making this possibility less likely.

Seizure during HD is another entity present in this case. She has a history of seizures, and no antiepileptic is on her medication list. So, her seizure could certainly be from noncompliance. Uremic encephalopathy can present as seizures at any point; however, the BUN is only slightly elevated, making this unlikely. Dialysis disequilibrium syndrome is another cause of seizure during HD. However,

it usually occurs during the very first HD session and is associated with a rapid drop in BUN. This patient has been on HD for some time and the BUN is not markedly elevated, making this diagnosis unlikely. Lastly, decreased perfusion to the brain from hypotension during HD can induce seizures. The patient became hypotensive during HD, which can happen due to higher flow rates. She was then placed on CRRT, which uses a slower flow rate and has a much lower incidence of hypotension; however, she became more hypotensive. This suggests that there most likely is some other reason for the hypotension rather than simply the HD.

She also has free fluid on her FAST exam and now has a distended abdomen. Coupled with the profoundly worsening anemia, I have to assume she is bleeding into her abdomen. There is nothing other than hemorrhage and hemolysis that could explain such a profound drop in her hemoglobin, and there is no evidence to be suspicious of hemolysis in her history, physical exam, or ancillary studies.

The patient is also experiencing elevated airway pressures on the ventilator. There are several reasons why her airway pressures could be elevated; but in the setting of a distended abdomen and hypotension, abdominal compartment syndrome (ACS) comes to the forefront of my differential diagnoses. Therefore, I have to assume this is a relatively brisk bleed as she has dropped her hemoglobin significantly, gone into PEA arrest, improved with blood transfusions, and is requiring multiple vasopressors to maintain her blood pressure. But why is she bleeding in her abdomen? She has not experienced any trauma to her abdomen unless it happened during the seizure in the hospital; however, if this had been the case I would assume that this history would have been given. She certainly could have experienced some sort of aortic catastrophe such as a ruptured abdominal aortic aneurysm, but it would be very odd for this to have happened during HD.

Now I had to take a step back and view the diagnostic clues as a whole and put these puzzle pieces together. In taking this whole patient presentation into view, one common theme arises in just about every aspect of her sequence of events. Hemorrhage. Anemia? Hemorrhage. Her anemia worsens? Definitely hemorrhage. Hypotension? Hemorrhage. Seizure? Hypoperfusion coming from hypotension coming from hemorrhage. Hypoxia? Profound anemia, which comes from hemorrhage. ACS? Hemorrhage. Lactic acidosis? Hypotension and anemia from hemorrhage.

Now we just have to figure out where this hemorrhage is coming from. When the patient first presented she appeared remarkably stable. She didn't have any complaints and her vital signs, other than her fever, were within normal limits. She had a HD catheter placed without any mention of complication. She begins HD and her blood pressure drops, her heart rate increases, and she becomes symptomatic nearly immediately. I could easily blame HD as the cause; however, her providers initiate CRRT and her hypotension worsens,

making HD less likely to be the cause. Therefore, something has happened prior to the initiation of HD, as she was stable up until HD began. The only thing that happened prior to the initiation of HD was the placement of the HD catheter. There is no mention of any complications or of significant blood loss during the placement. However, it is the only event between the patient being stable and being unstable.

If there was no mention of an obvious complication, what could have happened? Remember that the presumed source of the bleeding is in the abdomen. The HD catheter was placed in the groin, which is not far from the abdomen and retroperitoneal space. If the provider placing the line penetrated the other side of the vessel wall, he/she could easily have placed the HD catheter so that its tip is in the retroperitoneum. Were that the case, the patient would extravasate blood into the retroperitoneal space causing hypotension, decreased perfusion, lactic acidosis, and profound anemia. Once the retroperitoneal space filled up, there would be increased intra-abdominal pressure leading eventually to ACS. A review of the literature reveals a case report of this type of complication.¹

Therefore, the diagnostic study I would perform is a computed tomography (CT) angiogram of the abdomen and pelvis. This would show where the HD catheter was placed and examine the retroperitoneum for signs of active bleeding.

CASE OUTCOME

The diagnostic study was a CT angiogram of the abdomen and pelvis. The left femoral HD catheter had punctured the patient's left common iliac vein and formed a right-sided retroperitoneal hematoma. The surgical team assessed the patient and performed a temporizing bedside laparotomy to treat her acute ACS. This revealed a large, right-sided retroperitoneal hematoma and a large amount of ascites. The patient's hemodynamics stabilized after this procedure and she was able to come off all vasopressors. She was then transported directly to the operating room with the vascular surgery team for an emergent repair of her left common iliac vein.

She continued to receive multiple blood transfusions during the repair. Afterward she was transferred to the surgical ICU with an open abdomen that was subsequently repaired. The patient woke up completely neurologically intact and was discharged home five weeks after her injury.

RESIDENT DISCUSSION

ACS is the end point of a spectrum that begins with intra-abdominal hypertension (IAH) and ends when the intra-abdominal pressure exceeds 20 mmHg and is accompanied by end organ dysfunction.² Normal abdominal pressure, even in critically ill patients, should be <12 mmHg. IAH, which can be graded in stages, is defined as a pressure of 12-25 mmHg without the presence of organ dysfunction.

There are several distinct types of ACS. Primary ACS occurs in trauma or surgical catastrophes that result in a large hemorrhagic event, as in the presented case.³ Secondary ACS occurs when ICU patients are aggressively resuscitated with large volumes of crystalloids.^{4,5} Less common secondary causes include large, space-occupying lesions, bowel or retroperitoneal edema, and pancreatitis. Secondary ACS is insidious and commonly is diagnosed after a delay, further complicating an already high mortality.^{4,5}

The lethality of ACS is due to compromised organ perfusion and later organ failure. In the kidneys, decreased renal perfusion leads to congestion and oliguria, while increasing compartment pressure causes direct compression of the organ.^{6,7} Increased splanchnic vascular resistance results in bowel edema, translocation of gut bacteria, hyperlactemia, and sepsis.^{6,7} Cardiac preload may be decreased due to compression of the inferior vena cava causing decreased cardiac output, while right ventricular afterload increases.⁷ Oxygenation is impaired as the diaphragm is pushed cephalad and functional residual capacity decreases.⁷ Intracranial pressure also rises as a result of jugular venous compression impairing venous return. Clinically, the patient will present with hypotension, hypoxia, acute kidney injury, altered mental status, seizures, or unresponsiveness; eventually, the patient experiences total cardiovascular collapse.⁶⁻⁸

The gold standard for diagnosis of ACS is measurement of bladder pressure indirectly with a urinary catheter.⁹ To measure an accurate pressure, the patient must be in the supine position and the measurement taken at end expiration, with the transducer zeroed and in line with the iliac crest. This measurement has been shown to correlate with directly measured intra-abdominal pressure.¹⁰ Measurement of bladder pressures every 4-6 hours is adequate in critically ill patients at risk of developing ACS.

The mainstay of treatment for ACS is decompressive laparotomy, usually requiring leaving the patient with an open abdomen post-operatively.¹¹ Other secondary temporizing measures include sedation and analgesia, neuromuscular paralysis, decompression of the bowel contents with a naso- or endogastric tube, diuretics, and CRRT.^{11,12}

The mortality of ACS remains high despite medical intervention. While decompressive laparotomy effectively immediately reduces intra-abdominal pressure, this procedure is associated with multiple medical comorbidities with a mortality that still remains up to 50%.¹³ This may be due to the fact that at the time of decompressive laparotomy, patients are critically ill and the procedure is considered a last resort.

A second major issue for discussion in this case is the ethical dilemma faced by the providers caring for this critically ill patient whose religious beliefs were in opposition to the standard treatment (blood product transfusion) for her disease. The patient had initial documentation in her

chart of the physician-patient conversation during which she stated her conscious refusal of blood products. However, she did not have written, signed documentation of blood product-transfusion refusal in the chart. While the patient was unconscious and in extremis, her husband, who is not a practicing Jehovah's Witness, reversed her decision in an attempt to save her life. Where does this decision fall in the balance of autonomy vs. the power of the next of kin to decide what medical interventions a patient should receive? What happens when the next of kin makes a decision that is against the patient's choice? In life-or-death situations with ethical dilemmas, where quick decision-making will decide patient outcome, how can this burden be placed on loved ones?

The ethical dilemma, therefore, lies in the idea that while transfusion violates the value of autonomy, it simultaneously fulfills the ethical concept of beneficence. In general, patient personal directives should take precedence over any decisions made by the medical proxy. However, the decision of the family to transfuse on behalf of the unconscious patient, as seen in the current case, is legally appropriate even though it violates the patient's autonomy.

The ethics committee was consulted after the patient had already received a massive transfusion of blood products and was continuing to receive further red blood cell transfusions. The committee recommended that the patient no longer receive blood product transfusions despite next-of-kin consent. The patient woke up completely neurologically intact and was informed of the blood transfusions. She decided that in the future she would only accept blood bank plasma and family-donated red blood cells during an acute event. The patient was discharged home five weeks after her iatrogenic injury.

FINAL DIAGNOSIS

Iatrogenic left common iliac vein perforation with resulting abdominal compartment syndrome.

KEY TEACHING POINTS

1. ACS occurs when the intra-abdominal pressure is above 20 mmHg and end organ damage is present.
2. Primary ACS is caused by trauma or surgery, but be mindful of secondary ACS seen in massive resuscitation, especially in ICUs.
3. The gold standard of ACS diagnosis is a measured bladder pressure.
4. Treatment is a laparotomy as well as temporizing measures such as evacuation of bowel contents and/or sedation and paralysis.

Documented patient informed consent and/or Institutional Review Board approval has been obtained and filed for publication of this case report.

Address for Correspondence: Laura J. Bontempo, MD, MEd, University of Maryland, Department of Emergency Medicine, 110 S Paca Street, 6th Floor, Suite 200, Baltimore, MD 21201. Email: Lbontempo@em.umaryland.edu.

Conflicts of Interest: By the CPC-EM article submission agreement, all authors are required to disclose all affiliations, funding sources and financial or management relationships that could be perceived as potential sources of bias. The authors disclosed none.

Copyright: © 2018 Weiner et al. This is an open access article distributed in accordance with the terms of the Creative Commons Attribution (CC BY 4.0) License. See: <http://creativecommons.org/licenses/by/4.0/>

REFERENCES

1. Pafitanis G, Spyridon K, Theodorakopoulou E, et al. A case report of abdominal compartment syndrome caused by malposition of a femoral venous catheter. *Int J Surg Case Rep.* 2015;12:84-6.
2. Maluso P, Olson J, Sarani B. Abdominal compartment hypertension and abdominal compartment syndrome. *Crit Care Clin.* 2016;32(2):213-22.
3. Morken J, West MA. Abdominal compartment syndrome in the intensive care unit. *Curr Opin Crit Care.* 2001;7(4):268-74.
4. Biffi WL, Moore EE, Burch JM, et al. Secondary abdominal compartment syndrome is a highly lethal event. *Am J Surg.* 2001;182(6):645-8.
5. Burrows R, Edington J, Robbs JV. A wolf in wolf's clothing: the abdominal compartment syndrome. *S Afr Med J.* 1995;85(1):46-8.
6. Caldwell CB, Ricotta JJ. Changes in visceral blood flow with elevated intraabdominal pressure. *J Surg Res.* 1987;43(1):14-20.
7. Balogh Z, McKinley BA, Cox Jr. CS, et al. Abdominal compartment syndrome: the cause or effect of postinjury multiple organ failure. *Shock.* 2003;20(6):483-92.
8. Vidal MG, Ruiz Weisser J, Gonzalez F, et al. Incidence and clinical effects of intra-abdominal hypertension in critically ill patients. *Crit Care Med.* 2008;36(6):1823-31.
9. Kron IL, Harman PK, Nolan SP. The measurement of intra-abdominal pressure as a criterion for abdominal re-exploration. *Ann Surg.* 1984;199(1):28-30.
10. Saggi BH, Sugerman HJ, Ivatury RR, et al. Abdominal compartment syndrome. *J Trauma.* 1998;45(3):597-609.
11. Kirpatrick AW, Roberts DJ, De Waele JD, et al. Intra-abdominal hypertension and the abdominal compartment syndrome: updated consensus definitions and clinical practice guidelines from the World Society of the Abdominal Compartment Syndrome. *Intensive Care Med.* 2013;39(7):1190-206.
12. Ouellet JF, Leppaniemi A, Ball CG, et al. Alternatives to formal abdominal decompression. *Am Surg.* 2011;77(SI):S51-7.
13. De Waele JJ, Hoste EA, Malbrain ML. Decompressive laparotomy for abdominal compartment syndrome—a critical analysis. *Crit Care.* 2006;10(2):R51.

Emergency Physicians: Beware of the Consent Standard of Care

Gregory P. Moore, MD, JD*
Aaron G. Matlock, MD†
John L. Kiley, MD‡
Katherine D. Percy, DO§

*Madigan Army Medical Center, Department of Emergency Medicine, Tacoma, Washington
†Brooke Army Medical Center, Department of Emergency Medicine, San Antonio, Texas
‡Brooke Army Medical Center, Department of Internal Medicine, San Antonio, Texas
§Tripler Army Medical Center, Department of Emergency Medicine, Honolulu, Hawaii

Section Editor: Rick A. McPheeters, DO

Submission history: Submitted February 1, 2018; Revision received February 1, 2018; Accepted February 1, 2018

Electronically published April 5, 2018

Full text available through open access at http://escholarship.org/uc/uciem_cpem

DOI: 10.5811/cpem.2018.1.37822

Many emergency physicians view informed consent as a necessary component of treatments or procedures to be performed on their patients. When such procedures are necessary, often there is a discussion of risks, benefits and alternatives with forms signed to validate the discussion. Two Wisconsin emergency department medical-legal cases have expanded liability of the duty of informed consent. These cases have focused on withholding medication and diagnostic tests. [Clin Pract Cases Emerg Med. 2018;2(2):109-111.]

INTRODUCTION

We present two Wisconsin cases that illustrate a frequent trend of litigation in medical malpractice across the nation. When a bad medical outcome occurs, plaintiff attorneys will bring suit for both medical malpractice and lack of informed consent. The informed consent malpractice will allege that the patient was not given information about available tests, treatments, or admission to the hospital. This gives the plaintiffs two lines of attack and possible recovery. It is not enough in all cases to provide the standard of care medically.

CASE 1: *Jandre v Physicians Insurance Co of Wisconsin*

Mr. Thomas Jandre, a 48-year-old male, was brought to a Wisconsin emergency department (ED) by his co-workers. While traveling to a jobsite, coffee he was drinking had come out of his nose, and he developed slurred speech, left-sided facial droop, dizziness and unsteadiness with leg weakness. On presentation, the findings were noted by co-workers and an ED nurse. The patient was then evaluated by the emergency physician (EP). After the history and physical (which included auscultation of the carotid arteries for bruits), a computed tomography of the patient's head was obtained and interpreted by a radiologist as normal. The EP elected not to obtain a carotid artery ultrasound and diagnosed Mr. Jandre with Bell's palsy. The EP prescribed medications and discharged the patient with instructions to see a neurologist for follow-up care.

Three days later, a family physician agreed that Mr. Jandre had Bell's palsy that was resolving. Eleven days after the initial ED visit, Mr. Jandre suffered an ischemic stroke that left him physically and cognitively impaired. A carotid ultrasound revealed a 95% occlusion of the right internal carotid artery. The Jandres filed a lawsuit alleging two offenses. The first was that the EP negligently diagnosed Jandre with Bell's palsy, and the second was that the EP "breached her duty to inform" the patient of an additional test (a carotid ultrasound) that was available to assist in the evaluation of a potential ischemic stroke.

With regard to the first offense, the jury was educated about the "reasonable doctor" standard of care, in which the physician can be found negligent if they "failed to use the degree of care, skill, and judgment which reasonable emergency room physicians would exercise given the state of medical knowledge." There was evidence that the EP used acceptable methods for diagnosis and treatment, which the jury considered reasonable, and the EP was found to be non-negligent with respect to misdiagnosis. There was no contention of this verdict by the Jandres.

The second offense alleged that the EP was negligent with respect to her duty to inform the patient of the possibility of an additional diagnostic procedure. This brought into question the "reasonable patient standard," which states that "a doctor must provide the patient with the information a reasonable person in the patient's position would regard as significant when deciding to accept or reject a diagnostic procedure." The patient's family felt that the EP had not told them that the

patient had an atypical presentation of Bell's palsy, that the symptoms could also be consistent with an acute ischemic stroke, that she had used a less-reliable method to rule out carotid pathology (auscultation rather than ultrasound).

In both the original jury trial and at appeal, it was decided that the physician was not negligent in her medical care, but was separately negligent in her duty to disclose. The co-defendant (Physicians Insurance Co. of Wisconsin) independently appealed the case to the Supreme Court of Wisconsin with the following question: "Is there a bright-line rule that once a physician makes a non-negligent final diagnosis, there is no duty to inform the patient about diagnostic tests for conditions unrelated to the condition that was included in the final diagnosis?" The defendants argued that a reasonable patient would not need information regarding tests and treatment options unrelated to the diagnosed condition. They noted inconsistencies between the first ruling and the second allegation and argued that they could not be held liable for a duty to inform when the physician was not found negligent in her care or diagnosis. Additionally, the defendants argued that they were supported by two prior court rulings that stated duty to inform applies to treatment, not diagnostic tests. They contended that the duty to inform only applied after reaching a final diagnosis and not during the diagnostic process.

In response, the Jandres argued that a reasonable patient would have wanted to know if an additional non-invasive imaging modality could more accurately assess the patient's carotid arteries. Additionally, they argued that a jury can apply different standards of care for each offense without them being contradictory. The court remanded the case back to a jury decision solely on the lack of informed consent offense. The jury decided that the EP was negligent with respect to duty to inform and awarded damages of approximately \$1.853 million.¹

CASE 2: *Mayo v Jaffe*

Ascaris Mayo, a 53-year-old female, went to the ED of Columbia St. Mary's Hospital in Milwaukee complaining of abdominal pain and a high fever. She was seen by the EP and a physician's assistant; at trial they admitted that they had "included infection in the differential diagnosis" and that Mayo "met the criteria for Systemic Inflammatory Response Syndrome," according to court records. Ms. Mayo wasn't told about the diagnosis or available treatment, such as antibiotics. Instead, she was told to consult with her gynecologist about her history of uterine fibroids, court records show. Her condition worsened and she went to another ED the next day, where she was diagnosed with Group A sepsis. Mayo developed multi-organ system failure and went into a coma.

While in the hospital all of her extremities became gangrenous and required amputation. Mayo and her husband sued both providers along with Infinity Health Care Inc., ProAssurance Wisconsin Insurance Company and the Wisconsin Injured Patients and Families Compensation Fund,

for medical malpractice and failure to provide proper informed consent. The jury found that neither provider was negligent but that both failed to provide Mayo with proper informed consent about her diagnosis and treatment choices. The jury awarded \$25.3 million.²

DISCUSSION

Dr. Percy

The 1972 landmark case of *Canterbury v Spence* defined informed consent and established *failure to inform* as a distinct area of medical negligence, separate from actual care provided. *Canterbury v Spence* stated that it is the duty of the physician to disclose all information that a reasonable person would deem important to make an informed decision irrespective of whether they would comply with the care suggested for them. This court established that informed consent requires a discussion including inherent and potential hazards, benefits, and alternatives that a reasonable person of average intelligence would want before making a decision about their care. Also required is discussion of risk vs. benefit, expected outcome without care, and incidence of injury, harm, death and disability, along with all information that if provided could change the patient's mind about proceeding with care.³

Dr. Moore

When juries and courts have a lawsuit, there are two possible standards that can be applied: A) "reasonable patient" standard of care or, B) "reasonable physician" standard of care. At the time of these trials in Wisconsin, the patient-centered standard of care was in effect and the law for consent was "what a reasonable person in the patient's position would want to know."⁴ Due to outcry from these verdicts, the Wisconsin law was changed to the "reasonable physician standard." The new law "requires disclosure only of information that a reasonable physician in the same or similar medical specialty would know and disclose under the circumstances."⁵ Each state adopts one or the other, or in some cases their own unique standard. This is accomplished by either legislation, or individual case decision in the state courts. About half of the states follow the patient-centered standard and about half follow the physician-centered standard.⁶ It is harder for a plaintiff to succeed in a lawsuit successfully if the physician standard is in effect.

Dr. Matlock

It is evident that in many medical-legal cases, there can be a claim for both negligence and lack of informed consent. These are distinct and separate issues. The elements that must be proven to successfully litigate a claim of lack of informed consent are 1), "the physician did not present the risks and benefits of the proposed treatment and or alternative treatments; 2) with full information, the patient would have declined the treatment; and 3) the treatment, even though appropriate and carried out skillfully, was a substantial factor causing the patient's injuries."^{7,8}

Dr. Kiley

These types of cases are not isolated to Wisconsin. This legal argument has been made recently in a Louisiana trial case as well. In *Coulon v Creel*, a patient with a stroke, not treated with tissue plasminogen activator (tPA), sued in a similar double-pronged argument. They claimed both medical malpractice and secondly for malpractice with regard to informed consent. At trial the jury awarded Mr. Coulon \$150,000 in damages, specifically noting the lack of documented discussion of tPA being withheld. It seems evident that the jury, when determining the relatively small size of the award, was not convinced that tPA should have been definitely administered. They were unwilling to provide for future medical care. However, the jury seemed willing to provide some compensation for unequivocal lack of documentation of a disputed informed disclosure. The amount of the award was appealed. A higher court upheld the jury award and did not allow for increased damages.^{9,10}

CONCLUSION

Review of the defining medical-legal cases and precedents may both confuse and frustrate well-intentioned physicians who aspire to have clear guidelines and precisely defined duties. With regard to informed consent, the duty to inform can appear cloudy and nebulous. The cases reviewed here reveal that when a provider is in doubt as to whether to disclose information, it may be optimal to err on the side of discussion rather than to withhold information. While this may be cumbersome, in general, courts have not allowed time constraints as sufficient to excuse this duty. It is also important to clearly document that information has been shared and discussed (as illustrated by the Coulon case above).

Take-home Points:

1. The duty to disclose (informed consent) of an EP extends to areas beyond procedures and includes patient disposition, and test ordering.
2. It behooves EPs to have open discussions and disclosure in situations where a reasonable patient would desire more information and consider this shared decision-making in critical test-ordering and dispositions.
3. Failure to do so may increase liability.

Shared decision-making /informed consent discussions should be documented to increase medical-legal protection.

Documented patient informed consent and/or Institutional Review Board approval has been obtained and filed for publication of this case report.

Address for Correspondence: Gregory P. Moore, MD, JD, Madigan Army Medical Center, Department of Emergency Medicine, 1507 Nisqually St., Steilacoom, WA 98388. Email: gmoore4408@aol.com.

Conflicts of Interest: By the *CPC-EM* article submission agreement, all authors are required to disclose all affiliations, funding sources and financial or management relationships that could be perceived as potential sources of bias. The authors disclosed none. The opinions and assertions of the authors reflect their personal positions and do not reflect those of the US Army or government.

Copyright: © 2018 Moore et al. This is an open access article distributed in accordance with the terms of the Creative Commons Attribution ([CC BY 4.0](http://creativecommons.org/licenses/by/4.0/)) License. See: <http://creativecommons.org/licenses/by/4.0/>

REFERENCES

1. *Jandre v Physician's Insurance Company of Wisconsin and Bullis*, 2012 WI 39, Case No. 2008AP1972 (Wisconsin Supreme Court)
2. *Ascaris Mayo et al v The Wisconsin Injured Patients and Families Compensation Fund et al*. Wisconsin Circuit Court, Milwaukee County Case No. 2012CV006272
3. *Canterbury v Spence*, 409 U.S. 1064 93 S. Ct. 560 34 L. Ed. 2d 518 1972 U.S.
4. *Jandre*, 340 Wis 2d at 51-52
5. Wis. Stat. §448.30 (2014)
6. King JS, Moulton BW. Rethinking informed consent: the case for shared medical decision making. *Am J Law Med* 2006;32:429–501.
7. *Johnson v. Kokemoor*, 199 Wis. 2d 632 545 N.W.2d 495 (1996). at 632.
8. J Thomas A. Moore, *Informed Consent Part 2*, *NYLJ*, October 3, 1995, at 3, col 3.
9. *Coulon v. Creel*. Jefferson (LA) Parish Court Case No. 664-424.
10. *Coulon v. Creel et al.*, No. 13-CA-835, (La. Ct. App., 5th Cir. May 14, 2014).

Latest Considerations in Diagnosis and Treatment of Appendicitis During Pregnancy

Shahram Lotfipour, MD, MPH*

Max Jason, BS*

Vincent J. Liu, BS†

Mohammad Helmy, MD‡

Wirachin Hoonpongsimanont, MD, MS*

C. Eric McCoy, MD, MPH*

Bharath Chakravarthy, MD, MPH*

*University of California, Irvine, Department of Emergency Medicine, Orange, California

†Taipei Medical University, College of Medicine, Taipei, Taiwan

‡University of California, Irvine, Department of Radiological Sciences, Orange, California

Section Editor: Rick A. McPheeters, DO

Submission history: Submitted August 26, 2017; Revision received August 26, 2017; Accepted January 19, 2018

Electronically published March 14, 2018

Full text available through open access at http://escholarship.org/uc/uciem_cpem

DOI: 10.5811/cpcem.2018.1.36218

Pregnancy can obscure signs and symptoms of acute appendicitis, making diagnosis challenging. Furthermore, avoiding radiation-based imaging due to fetal risk limits the diagnostic options clinicians have. Once appendicitis has been diagnosed, performing appendectomies has been the more commonly accepted course of action, but conservative, nonsurgical approaches are now being considered. This report describes the latest recommendations from different fields and organizations for the diagnosis and treatment of appendicitis during pregnancy. [Clin Pract Cases Emerg Med. 2018;2(2):112-115.]

INTRODUCTION

Appendicitis among pregnant women is the most common cause of non-gynecological or obstetric-related emergency surgeries.¹ Appendicitis occurs in 0.05% to 0.07% of pregnancies with the highest frequency of cases occurring during the second trimester of pregnancy.² Pregnant women are more likely to experience perforation of the appendix, with rates as high as 55%, compared with 4% - 19% in the general population.² During pregnancy, symptoms of appendicitis may appear seemingly normal and anatomical changes may obscure classic signs, thereby confounding the diagnosis of appendicitis.¹ In addition to detection challenges, incorrect diagnoses may result in negative appendectomies, putting fetuses at unnecessary risk of spontaneous abortions and premature deliveries.³

When a non-pregnant patient displays symptoms indicative of appendicitis, transabdominal sonography and computed tomography (CT) are typically the imaging modalities of choice. Ultrasound (US) serves as a quick and readily available initial tool but may be inconclusive due to factors such as operator skill, patient physique, and intrinsic resolution. In contrast, CT has a sensitivity of 91% and specificity of 90% in diagnosing appendicitis.⁴ Although CT outperforms US in

accuracy, in order to reduce fetal risk of complications due to radiation exposure, radiologists' preferences are shifting toward low-dose CT and, predominantly, magnetic resonance imaging (MRI) when an initial US is non-diagnostic.^{5,6} It is not uncommon that MRI would not be available in an ED, or have limited availability during the night, which would necessitate an early decision for patient transfer to obtain higher level-of-care diagnostic studies.

In terms of treatment, performing an appendectomy is the current treatment of choice. Recent research explores a conservative, non-operative, antibiotic treatment approach as an option, but this practice is not widely accepted and may lead to recurrent appendicitis.⁷ We describe considerations in the diagnosis and treatment of suspected appendicitis in a pregnant woman with a history of lupus, kidney disease, and hypertension. We also describe her care in respect to the latest guidelines associated with management of acute appendicitis during pregnancy. Because the symptoms of appendicitis can be similar to those of pregnancy, diagnosis can be challenging given the need to avoid radiation. This report details up-to-date information regarding maternal treatment recommendations. We address the diagnostic and treatment challenges clinicians face with such a patient presentation.

CASE REPORT

A 23-year-old female at a gestational age of 13 weeks and three days presented to the emergency department (ED) with acute abdominal pain and dyspnea. The patient awakened at 5:00 am with sudden epigastric pain that intensified and became more diffuse by the time she presented at 8:33 am. The patient had a history of lupus with associated stage I kidney disease and hypertension. She intermittently took steroids for lupus flares but had no history of corresponding bowel or abdominal symptoms.

A physical exam showed that the patient had a temperature of 36.7° Celsius, heart rate of 93 beats per minute, blood pressure of 123/93 millimeters of mercury, respiratory rate of 18 breaths per minute, and a blood oxygen saturation of 100%. The patient was in mild distress due to pain, which had increased from 6/10 to 8/10 since its onset. She denied similar pain during her single previous pregnancy. She had two episodes of emesis with light yellow vomitus since she woke up. The patient exhibited normal bowel sounds, no tenderness at McBurney's point, no suprapubic tenderness, and no costovertebral angle tenderness. She described pain around her umbilicus, which she believed to be different in character and location from her lupus flares, which are often characterized by migraines and nausea.

US imaging was performed on the right lower quadrant but the appendix was not visualized. US did successfully confirm a live intrauterine pregnancy. A transvaginal exam of the pelvis showed normal ovaries, and fetal biometry measurements were consistent with dates. After morphine administration, the patient's pain decreased and became localized in the right lower quadrant. A surgeon was then consulted and recommended MRI of the abdomen and pelvis without contrast to evaluate the appendix. The MRI of the abdomen showed borderline appendicitis with stranding, minor wall thickening, free fluid, but no abscess (images 1-2). The patient was diagnosed with acute appendicitis and was admitted to the surgical service. The surgical team successfully performed a laparoscopic appendectomy and she was discharged the following day. The pathological report confirmed the initial diagnosis of acute appendicitis after microscopy of the appendix.

DISCUSSION

Appendicitis manifests with similar symptoms as those of pregnancy; though rare, it affects approximately one in 1,500 pregnancies. It is the most common cause of emergency non-gynecologic and non-obstetrical surgery in pregnant women.⁸ Appendicitis is difficult to identify in pregnant patients due to the patient characteristics that obscure otherwise-classic signs or symptoms. Major symptoms include vomiting, anorexia, nausea, pyrexia, tachycardia, and lower right quadrant pain.⁹ The appendix may shift upwards during pregnancy and patients may experience pain in the right upper quadrant or right flank.⁸

CPC-EM Capsule

What do we already know about this clinical entity?

Appendicitis is the most common cause of non-gynecological or obstetric-related emergency surgeries.

What makes this presentation of disease reportable?

This presentation is reportable given the prevalence of appendicitis and the degree of vigilance required to ensure proper diagnosis and treatment.

What is the major learning point?

Magnetic resonance imaging is the latest recommended diagnostic imaging modality. Appendectomies remain the preferred therapy over non-operative approaches.

How might this improve emergency medicine practice?

Increasing awareness of the possibility of appendicitis among the pregnant population in which symptoms can be obscured, could improve emergency medicine practice.

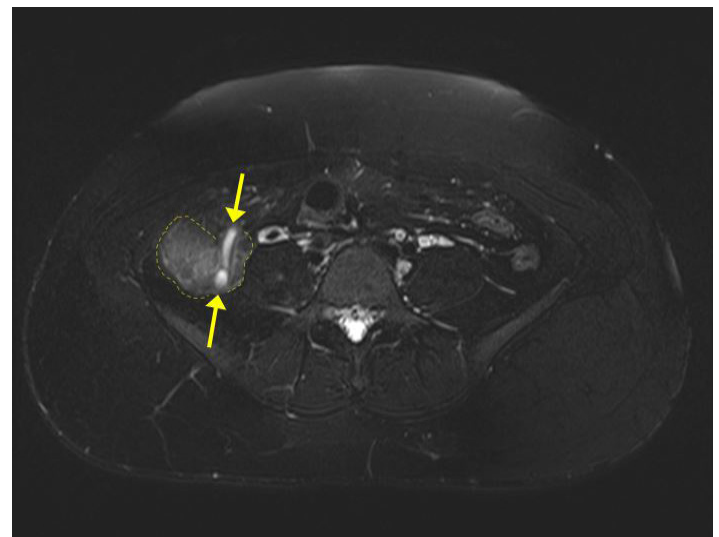


Image 1. Axial T2-weighted magnetic resonance image demonstrates a dilated appendix (demarcated by yellow arrows) with increased signal of surrounding fat indicating inflammation (outlined by dashed yellow lines).

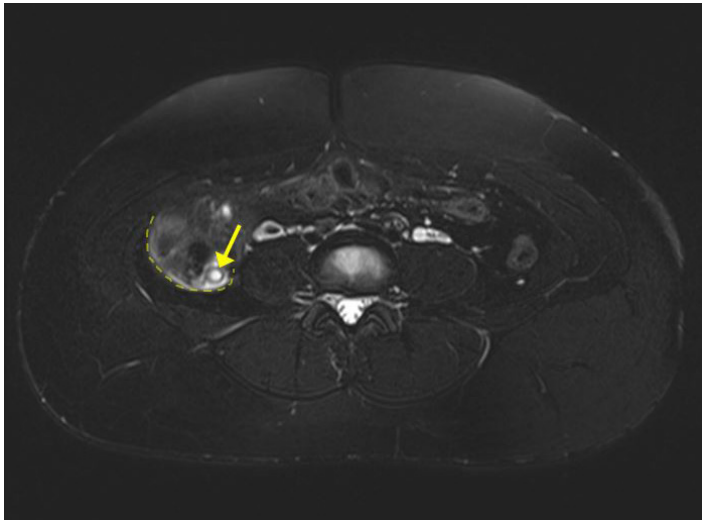


Image 2. Axial T2-weighted magnetic resonance image demonstrates a dilated appendiceal base (yellow arrow) measuring up to 1 cm in diameter with mural thickening, periappendiceal fluid, and increased signal of surrounding fat indicating inflammation (outlined by dashed yellow line).

Physical exam techniques conventionally used in diagnosis, such as Rovsing's and psoas signs, are ineffective in the case of pregnant patients.¹⁰ In addition, leukocytosis is not a reliable metric for pregnant patients as it occurs physiologically during pregnancy.^{9,10} Pyuria is observed in 10%-20% of patients and may be concurrent with asymptomatic or symptomatic bacteriuria found in the pregnant population.¹¹ It is important to consider other gastrointestinal, obstetric, and gynecological diagnoses that present with similar symptoms. Non-imaging scoring systems are useful diagnostic tools to stratify patients with suspected appendicitis. The Alvarado score is one that has been validated and a score cut-off of five can be useful in ruling out the diagnosis of appendicitis.^{12,13}

For non-pregnant patients, CT has been demonstrated to be the most accurate method for diagnosis. Contrast-enhanced CTs have diagnostic accuracy ranging from 91%-95% with specificity of 90%-95%. Unfortunately, a standard CT exposes a pregnant woman and her fetus to undesired radiation. In the case of a pregnant patient, the American College of Radiology recommends initial imaging using US, which offers 67%-86% sensitivity and 76%-88% specificity when imaging non-pregnant patients.⁶ Use of US is often operator-dependent, and identification of appendicitis in pregnant women can easily be hampered by bowel gas and obesity.¹⁴ For patients in their late second or third trimester, it is recommended that they be placed in the left posterior oblique or left lateral decubitus position to allow displacement of the enlarged uterus and facilitate use of graded compression techniques.¹⁵

In a retrospective study of pregnant patients, US was found to be effective in visualizing the appendix only in 7%

of cases with 18% sensitivity and 99% specificity.¹⁶ If an US diagnosis of acute appendicitis is indeterminate in a pregnant patient, MRI should be used. MRI visualizes the appendix with 100% sensitivity and 98% specificity.¹⁶ MRI does not emit ionizing radiation and has no known adverse effects on either the mother or fetus.^{17,18} Other studies have shown that MRI has a positive predictive value of 90.4% and negative predictive value of 99.5%, if the appendix can be identified.⁶ MRI is the current gold standard for accurately diagnosing appendicitis in pregnant patients after an inconclusive US.⁶

Pregnancy adds an additional layer of treatment challenges when addressing appendicitis. Accurate diagnoses are important for pregnant women exhibiting abdominal pain because of possible complications stemming from either a delayed or negative appendectomy. False positive diagnoses and subsequent surgeries put pregnant women at unnecessary risk. A large retrospective study demonstrated evidence of a fetal loss rate of 4% and early delivery rate of 10% for negative appendectomies.³ Given the risks associated with delayed diagnosis, the current practice when acute appendicitis is highly suspected is to perform an immediate appendectomy because any delay in surgery could lead to a ruptured appendix and increased fetal mortality.¹¹

Though conservative treatment of appendicitis with antibiotics has recently gained attention as an alternative treatment option, Salminen et al. were unable to demonstrate non-inferiority compared to appendectomies among patients 18-60 years old with uncomplicated acute appendicitis.¹⁹ A nonsurgical approach may reduce complication rates, but efficacy of surgery is currently still significantly higher.²⁰ Therefore, currently both open and laparoscopic appendectomies are considered appropriate surgical techniques; however, some studies have shown that laparoscopic interventions should not be performed in the third trimester.²¹

CONCLUSION

When a pregnant patient arrives at the ED with symptoms indicative of appendicitis, ultrasound is recommended as the first line of diagnosis. However, due to the difficulty in viewing the appendix in a pregnant patient using ultrasound, MRI is the best tool for diagnosis. MRI does not present the same radiation risk to the fetus as CT and provides comparable diagnostic power. It is not uncommon that MRI would not be available in an ED, or have limited availability during the night, which would necessitate an early decision for patient transfer to obtain higher level-of-care diagnostic studies. It is important to quickly ascertain a correct diagnosis as delayed appendectomies can lead to ruptures and subsequently higher fetal mortality rates. Standard of care after acute appendicitis is diagnosed in a pregnant patient is surgical consultation for an emergency appendectomy, as efficacy and safety of non-operative management with antibiotics in pregnant patients remains to be elucidated.

Documented patient informed consent and/or Institutional Review Board approval has been obtained and filed for publication of this case report.

Address for Correspondence: Shahram Lotfipour, MD, MPH, University of California, Irvine, Department of Emergency Medicine, 333 City Boulevard West, Suite 640, Route 128-01, Orange, CA 92868. Email: shl@uci.edu.

Conflicts of Interest: By the CPC-EM article submission agreement, all authors are required to disclose all affiliations, funding sources and financial or management relationships that could be perceived as potential sources of bias. The authors disclosed none.

Copyright: © 2018 Lotfipour et al. This is an open access article distributed in accordance with the terms of the Creative Commons Attribution (CC BY 4.0) License. See: <http://creativecommons.org/licenses/by/4.0/>

REFERENCES

- Andersen B, Nielsen T. Appendicitis in pregnancy: diagnosis, management and complications. *Acta Obstet Gynecol Scand.* 1999;78(9):758-62.
- Pastore PA, Loomis DM, Sauret J. Appendicitis in pregnancy. *J Am Board Fam Med.* 2006;19(6):621-6.
- McGory ML, Zingmond DS, Tillou A, et al. Negative appendectomy in pregnant women Is associated with a substantial risk of fetal loss. *J Am Coll Surg.* 2007;205(4):534-40.
- van Randen A, Bipat S, Zwinderman AH, et al. Acute appendicitis: meta-analysis of diagnostic performance of CT and graded compression US related to prevalence of disease. *Radiology.* 2008;249(1):97-106.
- Hansen W, Moshiri M, Paladin A, et al. Evolving practice patterns in imaging pregnant patients with acute abdominal and pelvic conditions. *Curr Probl Diagn Radiol.* 2017;46(1):10-6.
- Smith M, Katz D, Lalani T, et al. ACR Appropriateness Criteria® Right Lower Quadrant Pain—suspected appendicitis. *Ultrasound Q.* 2015;31(2):85-91.
- Society for Surgery of the Alimentary Tract. 2017. Available at: <http://ssat.com/guidelines/Appendicitis.cgi>. Accessed on July 12, 2017.
- Mourad J, Elliott JP, Erickson L, et al. Appendicitis in pregnancy: New information that contradicts long-held clinical beliefs. *Am J Obstet Gynecol.* 2000;182(5):1027-9.
- Cappell MS, Friedel D. Abdominal pain during pregnancy. *Gastroenterol Clin North Am.* 2003;32(1):1-58.
- Al-Mulhim AA. Acute appendicitis in pregnancy. A review of 52 cases. *Int Surg.* 1996;81:295-7.
- Augustin G. Acute abdomen during pregnancy. *Switzerland: Springer International Pu.* 2016:11-7.
- Ohle, R, O'Reilly F, O'Brien KK, et al. The Alvarado Score for predicting acute appendicitis: a systemic review. *BMC Med.* 2011;9:139.
- Memom ZA, Irfan S, Ftima K, et al. Acute appendicitis: diagnostic accuracy of Alvarado scoring system. *Asian J Surg.* 2013;36(4):144-9.
- Hien N, Le K, Le C, et al. Concurrent ruptured ectopic pregnancy and appendicitis. *J Am Board Fam Med.* 2005;18(1):63-6.
- Lim HK, Bae SH, Seo GS. Diagnosis of acute appendicitis in pregnant women: value of sonography. *Am J Roentgenol.* 1992;159:539-42.
- Konrad J, Grand D, Lourenco A. MRI: first-line imaging modality for pregnant patients with suspected appendicitis. *Abdominal Imaging.* 2015;40(8):3359-64.
- Bulas D, Egloff A. Benefits and risks of MRI in pregnancy. *Semin Perinatol.* 2013;37(5):301-4.
- De Wilde J, Rivers AW, Price DL. A review of the current use of magnetic resonance imaging in pregnancy and safety implications for the fetus. *Prog Biophys Mol Biol.* 2005;87(2-3):335-53.
- Salminen P, Paajanen H, Rautio T, et al. Antibiotic therapy vs appendectomy for treatment of uncomplicated acute appendicitis. *JAMA.* 2015;313(23):2340-8.
- Ansaloni L, Catena F, Coccolini F, et al. Surgery versus conservative antibiotic treatment in acute appendicitis: a systematic review and meta-analysis of randomized controlled trials. *Dig Surg.* 2011;28(3):210-21.
- Malangoni M. Gastrointestinal surgery and pregnancy. *Gastroenterol Clin North Am.* 2003;32(1):181-200.

Intra-abdominal Rupture of a Live Cervical Pregnancy with Placenta Accreta but Without Vaginal Bleeding

Asma Tariq, MD
Maria O'Rourke, MD
Steven J. Carstens, DO
Vicken Y. Totten, MD

Kaweah Delta Health Care District, Department of Emergency Medicine, Visalia, California

Section Editor: Rick A. McPheeters, DO

Submission history: Submitted August 10, 2017; Revision received September 22, 2017; Accepted October 2, 2017

Electronically published March 14, 2018

Full text available through open access at http://escholarship.org/uc/uciem_cpccem

DOI: 10.5811/cpcem.2017.10.32029

We describe an unusual ruptured ectopic pregnancy. The unique features of the case include abdominal pain without vaginal bleeding; cervical implantation and a placenta accreta; and the late presentation at 16 weeks of gestation without prior symptoms. Both the initial point-of-care ultrasound and the formal ultrasound were interpreted as showing an intrauterine pregnancy. The clinical presentation was misleading; the correct diagnosis was made by magnetic resonance imaging. We show the ultrasonic images. We discuss cervical ectopic pregnancies, their diagnosis and management. The woman survived but required emergency hysterectomy and many units of blood. [Clin Pract Cases Emerg Med. 2018;2(2):116-120.]

INTRODUCTION

We report an unusual case of a ruptured live cervical ectopic pregnancy, which presented without vaginal bleeding. Unrecognized rupture of an ectopic pregnancy can be catastrophic; the most common presentation is vaginal bleeding. Cervical pregnancies are especially prone to visible bleeding, yet our patient presented with abdominal pain alone. Unique features of this case included the presentation without vaginal bleeding; a live fetus of 16 weeks gestation (second trimester) and both a point-of-care ultrasound (POCUS) and a formal ultrasound that were interpreted as demonstrating a live fetus at 16 weeks; and a definitive diagnosis suggested by magnetic resonance imaging (MRI), which disputed the ultrasonic findings. This combination of circumstances is exceedingly rare: no other case has been reported in which MRI was definitive, yet the possibility must be kept in mind by emergency physicians. We describe the incidence and predisposing factors for cervical pregnancy and discuss diagnostic modalities and treatment options.

CASE REPORT

A 21-year-old-female presented to the emergency department (ED) with sudden onset abdominal pain and vomiting that started one hour prior to arrival in the ED. The pain was diffuse but worse in the epigastrium and the right lower quadrant (RLQ);

it radiated into the chest and neck. She reported dysuria and a subjective fever, but denied vaginal bleeding. Her last menstrual period was two months prior. She denied current pregnancy or previous sexually transmitted diseases. Just over a year earlier, she had delivered a single, live-term infant by Cesarean section. She denied recent dietary changes or history of gallstones.

On presentation, the patient was in moderate distress and was alert and cooperative. Initial vital signs were pulse 65 beats/minute; respiratory rate 24 breaths/minute; and blood pressure of 111/50 millimeters of mercury. She was afebrile. Oxygen saturation was 99%. Cardiac and lung examinations were normal. The abdominal exam revealed diffuse tenderness to palpation with involuntary guarding and rebound in the right upper quadrant (RUQ), left upper quadrant (LUQ), and the RLQ. She refused a pelvic exam due to discomfort, and preferred to lie on her right side.

The differential diagnosis of peritonitis in this patient included acute pancreatitis, perforated peptic ulcer, appendicitis or cholecystitis with perforation, ovarian cyst rupture and vascular catastrophe including ectopic pregnancy. Her urine pregnancy test was positive, changing the differential diagnosis. The quantitative human chorionic gonadotropin (HCG) level was within the discriminatory zone at 31239 mIU/ml; lipase was negative; initial complete blood count (CBC) revealed a white cell count of $19.25 \times 10^9/L$ and hemoglobin of 11.6 g/dl.

Two large-bore intravenous (IV) lines were placed, and fluids given. A POCUS in the ED showed what appeared to be a live intrauterine pregnancy, with a large amount of free fluid around the spleen. There was also free fluid in the RUQ and RLQ. A formal ultrasonographic examination was interpreted as showing a 16-week, live, intrauterine pregnancy with an anterior placenta, as well as a large amount of free fluid around the spleen and in the RLQ (Image 1 and 2.)

Therefore, the differential changed to an acute abdomen in the setting of what was presumed to be a live intrauterine pregnancy. Both an obstetrician and a general surgeon were emergently consulted. The differential diagnosis now included appendicitis, a ruptured ovarian cyst, or possibly a ruptured cervical ectopic pregnancy, in spite of an ultrasound read as intrauterine pregnancy. The consultants requested a MRI scan for clarification. The patient was deemed stable enough to delay operation, so this was done.

The MRI of the abdomen and pelvis was interpreted as revealing a low fetal implantation near the cervix concerning for cervical ectopic pregnancy. The majority of the uterine body was seen well above the location of the fetus. An irregularity of the anterior right aspect of the cervix suggested possible extra-uterine placental extension. The free fluid throughout the abdomen demonstrated an increased T1 signal (T1 is an MRI sequence wherein degraded blood and sub-acute hemorrhage produce a signal of increased intensity), further suggesting that the cervical pregnancy had ruptured into the abdomen rather than bleeding vaginally.

That the intra-abdominal fluid was an acute, large volume, intra-abdominal blood loss was supported by a drop in hemoglobin over a few hours from 11.6 g/dl at presentation to 9.7 g/dl. Therefore, three units of packed red blood cells (PRBCs) were prepared and transfusion started. The obstetrician promptly took the patient to the operating room.

Prior to operating, the possibility of emergent hysterectomy was raised with the patient in the event that hemorrhage could not otherwise be controlled. She agreed. Under anesthesia, the cervix was found to be closed. There was a normal vaginal mucosa and no transvaginal bleeding. On bimanual exam the uterus was noted to be very soft. The exploratory laparotomy revealed a ruptured cervical pregnancy with a placenta accreta protruding out of the right uterine wall and bleeding heavily.

The fetus and placenta were removed via a classic vertical uterine incision. Unfortunately, it was not possible to control hemorrhage at the site of the placenta accreta extrusion. The cervix and uterine tissues were very thin and friable. A hysterectomy was performed to stop the ongoing blood loss. At the end of the operation, the patient's hemoglobin had dropped to 6.4g/dl. The patient received an additional two units PRBCs and did well post-operatively. Her hospital course was unremarkable and she was discharged home on post-operative day three.

CPC-EM Capsule

What do we already know about this clinical entity?

Ectopic pregnancies should always be considered in women of childbearing age who have abdominal pain, even without vaginal bleeding. Ectopic pregnancies can implant anywhere.

What makes this presentation of disease reportable?

Several features of this case are unique: placenta accreta with cervical pregnancy bleeding only intraabdominally and 2 ultrasounds reported as IUPs. MRI was diagnostic.

What is the major learning point?

Ultrasound, even transvaginal, may be misleading. When the clinical situation warrants it, consider MRI.

How might this improve emergency medicine practice?

MRI is rarely needed to localize a pregnancy, but is a modality to keep in mind. Also warn such a patient of the possibility of hysterectomy.

DISCUSSION

Cervical pregnancy is a rare and dangerous form of ectopic pregnancy that results from implantation of the zygote below the internal os. Cervical pregnancies have an incidence of approximately 1:9,000 of all pregnancies¹ and account for 0.15% of all ectopic pregnancies.² Risk factors for cervical implantation include a prior history of cervical dilatation, uterine curettage, or Cesarean section.^{3,4} Cervical ectopic pregnancies may also be more prevalent after assisted reproduction, occurring in an estimated 0.1% of in vitro fertilizations.^{5,6}

Like all other ectopic pregnancies, cervical pregnancies have the potential for massive hemorrhage causing death. Mortality rates in the earliest reported cases were 40% to 45%. However, since 1954 no maternal deaths as a result of cervical pregnancy have been documented in the medical literature.⁷⁻¹⁰ This reduction in mortality is partly attributable to earlier (ultrasonic) recognition, and also to aggressive resuscitation, newer transfusion therapies and improved surgical techniques.

Vaginal bleeding is the most common presenting symptom of cervical pregnancy.¹¹ Unexpectedly, our patient had no

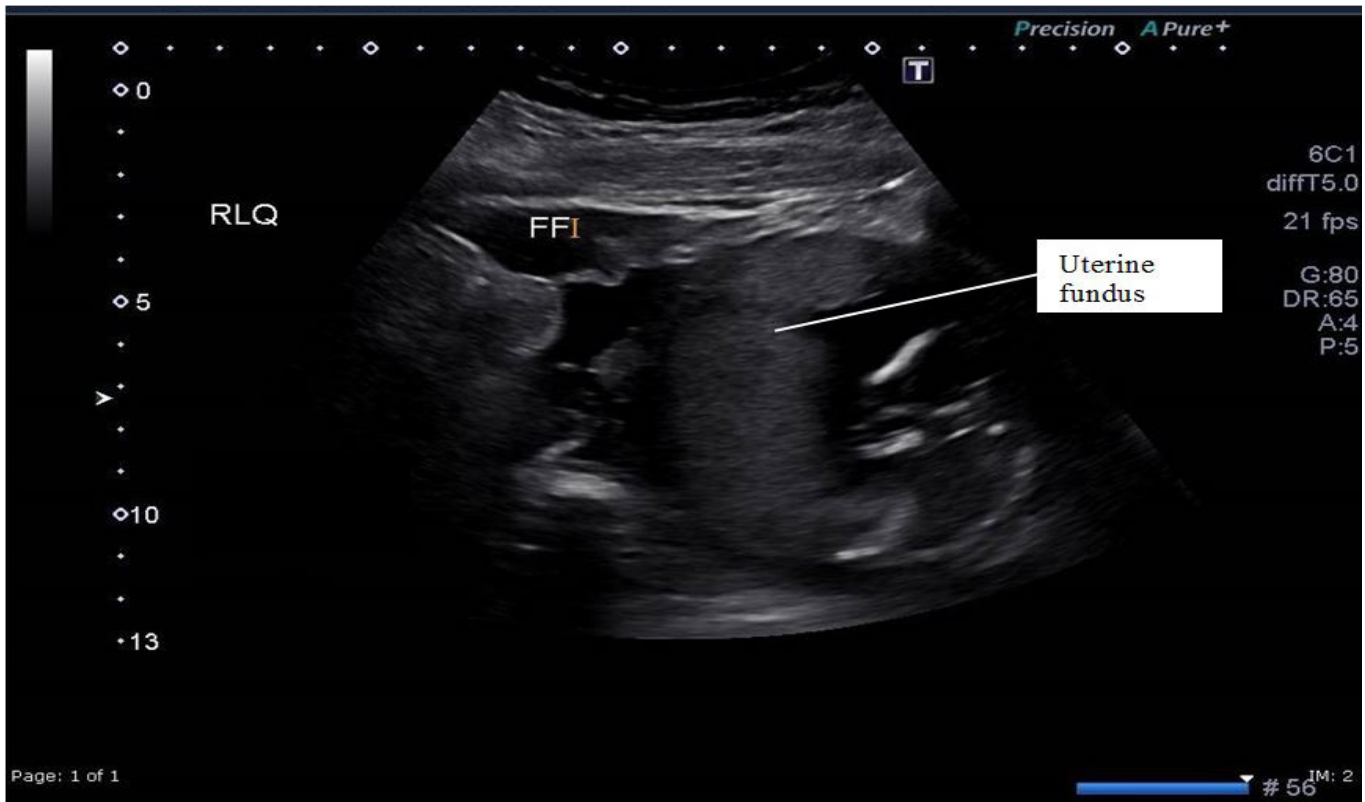

Image 1. Sagittal view of the uterus showing viable intrauterine pregnancy at 16 weeks and a large amount of free fluid (FF).

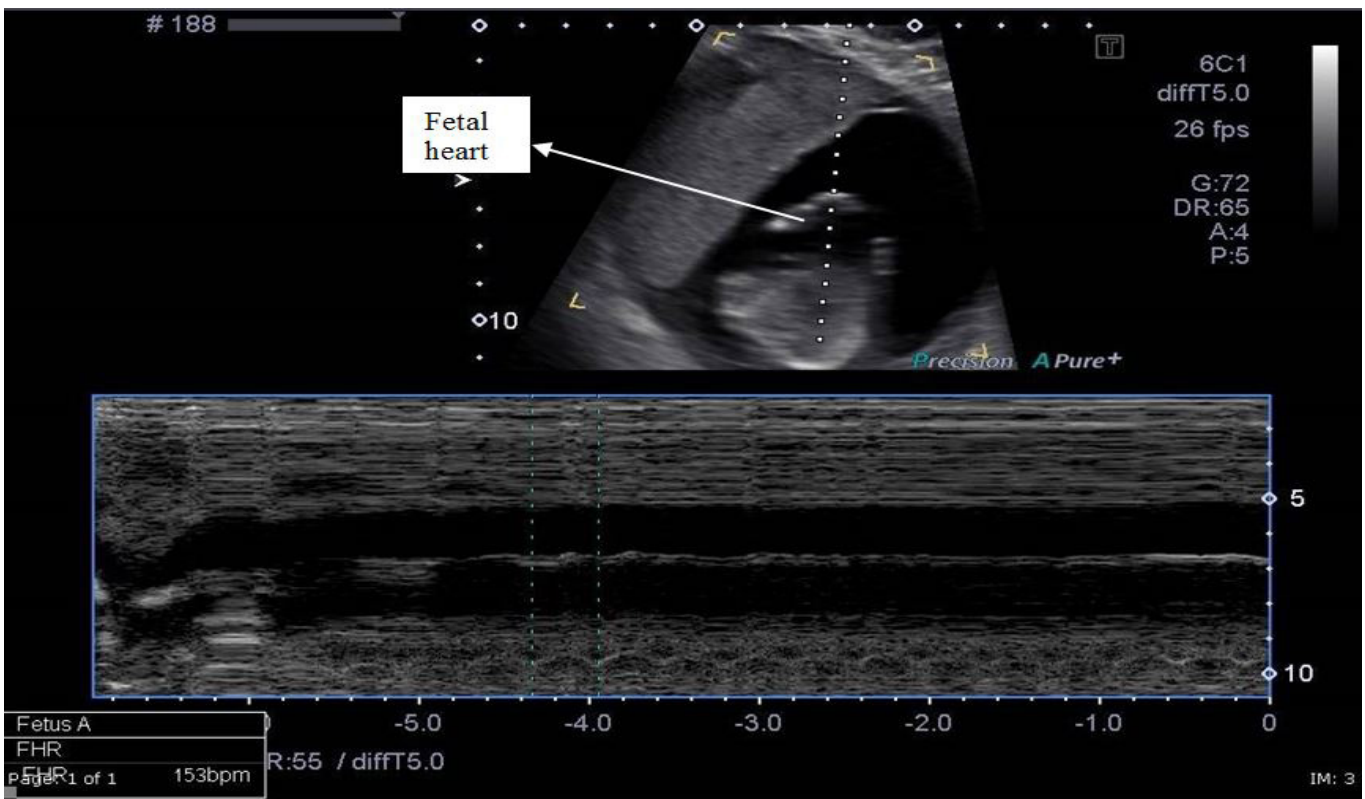


Image 2. M-mode through the fetal heart demonstrating a rate of 153 beats / minute in cervical ectopic pregnancy.

vaginal bleeding. Other clinical criteria of cervical pregnancy involve closed internal os, partially open external os, products of conception confined within the endocervix, and a softened and disproportionately enlarged cervix.¹²⁻¹⁴ Early clinical suspicion and recognition of cervical ectopic pregnancy is critical to decreasing potentially fatal hemorrhage. Timely detection also allows an attempt at conservative management strategies.

The methods used to diagnose cervical ectopic pregnancy have changed over time. In the past, cervical ectopic pregnancy was diagnosed intra-operatively in the presence of extensive hemorrhage at the time of uterine curettage.

The advent of transvaginal ultrasound has greatly enhanced diagnostic options. However, as our case reported, sometimes even transvaginal ultrasound is insufficient to make the diagnosis. Together with a clinical suspicion, rapid assays of serum HCG, and advanced imaging (in our case, MRI), the diagnosis of cervical ectopic pregnancy can be made much earlier than was historically possible.³⁻¹⁶

There are strict sonographic criteria for the diagnosis of cervical ectopic pregnancy.^{2,13,17} The criteria are as follows: (1) intra-cervical localization of the ectopic gestation; (2) closed internal os; (3) trophoblastic invasion in the endocervical tissue; (4) empty uterine cavity; (5) hourglass-shaped uterus; (6) intra-cervical peritrophoblastic blood flow; and (7) diffuse amorphous intrauterine echoes.

Even with the widespread availability of ultrasound, clinical recognition of cervical ectopic pregnancy remains difficult. Ultrasonic diagnosis is correct in 82% of cases.^{1,8} Culdocentesis is now rarely used for the diagnosis of ectopic pregnancy. It has largely been replaced by ultrasonic imaging of free fluid in the cul de sac (pouch of Douglas). However, in those facilities lacking ultrasound, or if the clinical presentation is confusing, aspirating non-clotting blood from the pouch of Douglas may provide useful information and influence the choice of therapy. Blood aspirated from the pouch of Douglas that does not clot on standing is suggestive of an ectopic pregnancy.^{19,20} In our patient, the MRI clinched the diagnosis of ruptured cervical pregnancy; culdocentesis was not performed.

Initial evaluation after a physical examination should include a CBC, blood type and screen, and a quantitative β -hCG measurement followed by transvaginal ultrasound. This can help determine the approximate gestational age and guide the physician in choosing the appropriate therapy. Conservative management is the therapy of choice when the diagnosis is early and before complications arise.

The choice of surgical management vs. medical treatment of cervical pregnancies is dictated by the length of the gestation and the hemodynamic stability of the patient. The main goal of conservative therapy is to preserve the patient's reproductive capability.²¹ Medical management of ectopic pregnancies usually includes a cytotoxic agent such as methotrexate, and is most effective when the conceptus is small. Pregnancies of greater than six weeks duration generally require induction of fetal death

(usually with potassium chloride) or high-dose and prolonged methotrexate therapy¹⁵

Surgical options that preserve fertility have been tried. Cerclage is not currently recommended. Suction curettage can be performed with subsequent Foley catheter placement in the cervix to tamponade bleeding. Uterine artery embolization can minimize intraoperative bleeding.

Historically, hysterectomy was often the only treatment option, which stopped the profuse hemorrhage that accompanies attempts at removal of a cervical pregnancy. Even today, surgery is chosen either as a last resort when medical management fails, or in emergency situations when a woman, usually previously undiagnosed, presents with life-threatening acute hemorrhage.¹⁵ A cervical pregnancy that is undetected until the second or third trimester usually requires a hysterectomy.¹¹ This was unfortunately the case in our patient, who had an undiagnosed, second-trimester, cervical pregnancy that was already ruptured at presentation. Because of her ongoing hemorrhage, conservative measures were not an option for her; she needed a total hysterectomy to control the hemorrhage.

CONCLUSION

In summary, cervical pregnancy is a rare but potentially fatal form of ectopic pregnancy. An emergency physician must be aware of the possibility, and combine a high index of suspicion with clinical and radiological findings to make an accurate and timely diagnosis of cervical pregnancy. Ultrasound is the most important diagnostic tool in early detection of cervical pregnancy, although MRI can be useful if ultrasound is not definitive. Though medical management is preferred, its success depends directly on how early the diagnosis is made. Failure of conservative management may necessitate more aggressive surgical intervention and even a total hysterectomy to control the hemorrhage.

Documented patient informed consent and/or Institutional Review Board approval has been obtained and filed for publication of this case report.

Address for Correspondence: Asma Tariq, MD, Kaweah Delta Health Care District, Department of Emergency Medicine, 400 W. Mineral King, Visalia, CA 939291-6263. Email: dr.asmatariq@gmail.com.

Conflicts of Interest: By the CPC-EM article submission agreement, all authors are required to disclose all affiliations, funding sources and financial or management relationships that could be perceived as potential sources of bias. The authors disclosed none.

Copyright: © 2018 Tariq et al. This is an open access article distributed in accordance with the terms of the Creative Commons Attribution (CC BY 4.0) License. See: <http://creativecommons.org/licenses/by/4.0/>

REFERENCES

1. Samal S, Ghose S, Pallavee et al. Successful management of live cervical ectopic pregnancy. a case report. *J Clin Diagn Res.* 2015 Dec;9(12):QD03-4.
2. Hafner T, Ivkovic IE, Serman A, et al. Modification of conservative treatment of heterotopic cervical pregnancy by Foley catheter balloon fixation with cerclage sutures at the level of the external cervical os: a case report. *J Med Case Rep.* 2010;16;(4):212.
3. Vela G, Tulandi T. Cervical pregnancy: the importance of early diagnosis and treatment. *J Minim Invasive Gynecol.* 2007;14(4):1-4
4. Verma U, Goharkhay N. Conservative management of cervical ectopic pregnancy. *Fertil Steril.* 2009;91(3):671-4.
5. Ginsburg ES, Frates MC, Rein MS, et al Early diagnosis and treatment of cervical pregnancy in an in vitro fertilization program. *Fertil Steril.* 1994;61:(5):966-9.
6. Karande VC, Flood JT, Heard N, et al. Analysis of ectopic pregnancies resulting from in-vitro fertilization and embryo transfer. *Hum Reprod* 1991;6.(3):46-449.
7. Marcovici I, Rosenzweig BA, Brill AI, et al. Cervical pregnancy: case reports and a current literature review. *Obstet Gynecol Surv.* 1994;49(1):49-55.
8. Studdiford WE. Cervical pregnancy: a partial review of the literature and a report of two probable cases. *Am J Obstet Gynecol.* 1945;49:169.
9. Rubin I. Cervical pregnancy. *Surg Gynecol Obstet.* 1911;13:625-33.
10. Parente JT, Ou CS, Levy J, et al. Cervical pregnancy analysis: a review and report of five cases. *Obstet Gynecol.* 1983;62:79-82.
11. Boyko TR1, O'Brien JF. Cervical pregnancy: a case report. *Ann Emerg Med.* 2001;38(2):177-80.
12. Yankowitz J, Leake J, Huggins G, et al. Cervical ectopic pregnancy: review of the literature and report of a case treated by single-dose methotrexate therapy. *Obstet Gynecol Surg.* 1990;45:405-44.
13. Poon KF, Chan LKC, Tan HK, et al. Cervical ectopic pregnancy—a case report. *Singapore Med J.* 1997;38:27-8.
14. Sepulveda WH, Vinals F, Donetch G, et al. Cervical pregnancy: a case report. *Arch Gynecol Obstet.* 1993;252(3):155-7.
15. Cunningham FG, Gant NF, Leveno KJ, et al. Section IX: reproductive success and failure pp.853-936 In *Williams Obstetrics*, 21st Edition, McGraw-Hill Medical Publishing Division, 2001.
16. Kirk E, Condous G, Haider Z, et al. The conservative management of cervical ectopic pregnancies. *Ultrasound Obstet Gynecol.* 2006;27(4):430-7.
17. Kobayashi M, Hellman LM, Fillist LP. Ultrasound: an aid in the diagnosis of ectopic pregnancy. *Am J Obstet Gynecol.* 1969;103(8):1131-40.
18. Rosenzweig J, Birkhahn RH. Cervical ectopic pregnancy case report: findings for the bedside sonographer. *J Emerg Med.* 2009;36(1):34-6.
19. Potdar N, Konje JC. "Ectopic pregnancy." Chapter 25 (pp 363-Line 381) in *Gynaecology*, 4th Edition, 2011, Elsevier Limited.
20. Nelson AL, Gambone JC. "Ectopic pregnancy." Chapter 24, pg 304-313 in *Hacker & Moore's Essentials Of Obstetrics & Gynecology*, Sixth Edition.
21. Acosta DA. Cervical pregnancy—a forgotten entity in family practice. *J Am Board Fam Pract.* 1997;10(4):290-5.

Trigeminal Trophic Syndrome Leading to Orbital Cellulitis

Linda B. Thompson, MD
Stephen L. Powell, MD

University of Alabama School of Medicine, Department of Emergency Medicine,
Birmingham, Alabama

Section Editor: Shadi Lahham, MD

Submission history: Submitted October 2, 2017; Revision received December 21, 2017; Accepted January 19, 2018

Electronically published March 14, 2018

Full text available through open access at http://escholarship.org/uc/uciem_cpchem

DOI: 10.5811/cpchem.2018.1.36622

Trigeminal trophic syndrome is a rare condition that develops from trigeminal nerve damage causing dysesthesias that result in self-mutilation. Facial and nasal destruction develops from self-destructive behavior (repetitive picking or scratching) secondary to the altered skin sensation created by the damaged trigeminal nerve. Early recognition of this condition is crucial to the prevention of the detrimental complications of facial ulceration and nasal tissue necrosis that can lead to corneal ulcerations, full-thickness eyelid defect, and canthal lesions. This case demonstrates a previously unreported complication: orbital cellulitis. [Clin Pract Cases Emerg Med.2018;2(2):121-124.]

INTRODUCTION

Trigeminal trophic syndrome (TTS) is a rare condition that develops from trigeminal nerve damage causing dysesthesias that result in self-mutilation.^{1,2,3} The nerve insult is frequently a result of surgery with subsequent anesthesia along the maxillary nerve branch of the trigeminal nerve (V_2), but has also been reported in cases of alcohol injection of the trigeminal nerve used to treat trigeminal neuralgia, cerebral meningioma resection, cerebrovascular accidents, and herpes zoster ophthalmicus.^{1,2,3,4} This trigeminal neuropathy causes dysaesthetic skin and subsequently leads to compulsive pruritic sensations, self-mutilation, and eventual tissue necrosis.^{1,2,3,4} Case reports cite a characteristic “crescent”-shaped area of the nose lacking cartilage,^{1,2,3,5} or “persistent facial ulceration... with alar nasi involvement being a key feature.”⁴ Patients with TTS often have psychiatric comorbidities such as anxiety, obsessive-compulsive disorder (OCD), or mood dysfunction.¹ Treatment is centered on preventing self-destruction with patient education and counseling.^{2,3,4} Reconstruction is typically unsuccessful due to further compulsive irritation.^{4,6,7} Though not previously described, our case demonstrates that orbital cellulitis can complicate TTS.

CASE REPORT

A 75-year-old female with history of Type II diabetes presented to the emergency department (ED) with “double vision and right eye redness” for several weeks with isolated right eyelid swelling for one week. She had recently seen her ophthalmologist

who noted the swelling and ordered magnetic resonance imaging (MRI), which showed inflammation extending from the right paranasal sinuses into the orbit. She was sent to the ED with concern for an infectious process such as mucormycosis. She had never had nasal, septal, or sinus surgery; however, she did have a remote history of trigeminal neuralgia treated with neurectomy 30 years prior. In the five years prior to this presentation, she had experienced facial paresthesias and pruritus managed by compulsive manipulation of her face, nose and sinuses with cotton tip applicators and fingers.

On physical exam, the patient was nontoxic with normal vital signs: temperature 98.1° F, heart rate 94 beats per minute, respiratory rate 18 breaths/min, blood pressure 121/72 mm/Hg. Visual acuity in each eye was 20/20 without visual aids. She was noted to have right eye proptosis, periorbital edema and erythema, in addition to right medial gaze palsy. She had erosive necrosis with complete destruction of the right ala nasi and grossly patent right nasal aperture. While the right inferior turbinate appeared normal, the right middle turbinate was scarred with extensive right septal scarring and scabbing (Image 1).

The patient’s laboratory testing revealed a white blood cell count 8.7 10^3 /cmm and serum glucose 216 mg/dl. Axial computed tomography (CT) (Image 2) showed dehiscence of the inferomedial right orbital wall with soft tissue density and stranding extending into the medial retro-orbital fat posterior to the orbital apex resulting in proptosis of the right eye. The right optic nerve sheath appeared thickened. The right nare was partially absent giving the appearance of a chronic wound or

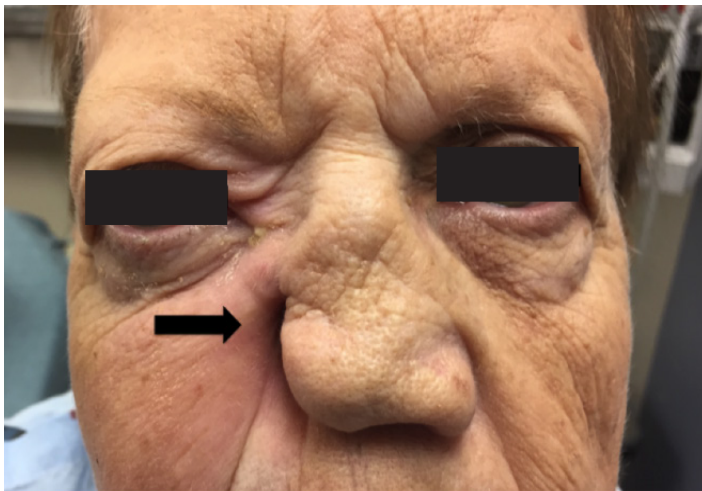


Image 1. Right ala nasi erosive necrosis (arrow) with right orbital cellulitis and ptosis.

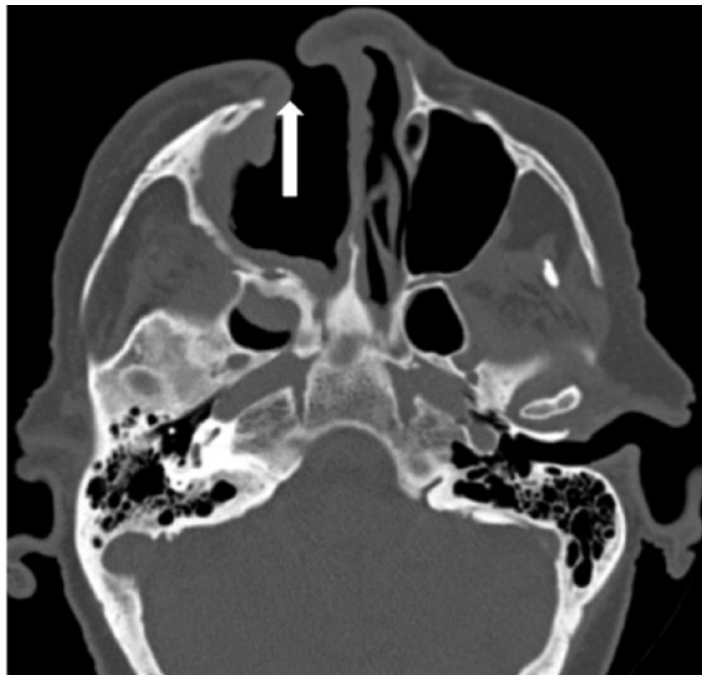


Image 2. Axial computed tomography demonstrating anterior maxillary wall sinus erosion (arrow).

previous sinus surgery. Underlying encephalomalacia of the right temporal lobe from previous right neurectomy was also noted.

The patient was admitted with the diagnosis of orbital cellulitis and treated with parenteral vancomycin and piperacillin-tazobactam. Otolaryngology, ophthalmology, and psychiatry were consulted. Fiber optic endoscopy demonstrated extensive paranasal sinus destruction, with friable mucosa. The tissue destruction seen on CT and

CPC-EM Capsule

What do we already know about this clinical entity?

Trigeminal trophic syndrome (TTS) is a condition that follows trigeminal nerve damage resulting in compulsive pruritic sensations, self-mutilation, and eventual tissue necrosis.

What makes this presentation of disease reportable?

Orbital cellulitis resulting from TTS has not been reported in the literature; clinicians should be made aware of this potential serious complication.

What is the major learning point?

Early detection of TTS and recognition that treatment involves medical and psychiatric therapy is necessary to prevent devastating and disfiguring complications.

How might this improve emergency medicine practice?

Recognition of this disease and the potential serious complications will lead to the early, multidisciplinary management approach necessary for successful treatment, thus improving outcomes.

subsequent MRI was initially concerning for other serious infections, such as mucormycosis or malignancy; however, frozen pathology showed no evidence of an invasive fungal infection or malignant transformation. Other possible etiologies such as the autoimmune disorders Wegener's granulomatosis or granulomatous polyangiitis were considered.

The required rheumatologic work up to evaluate for these potential causes would include the following: antinuclear antibody; C-reactive protein; erythrocyte sedimentation rate; and anti-neutrophil cytoplasmic antibodies. These lab tests were abandoned when the sinus culture was positive for *Staphylococcus aureus*, and the patient rapidly improved with the appropriate intravenous antibiotics. Psychiatric consultation determined that the patient had a component of an unrecognized OCD. The combination of ongoing facial paresthesia in the V₂ division of the trigeminal nerve resulting from the previous trigeminal neuralgia surgery and the newly diagnosed OCD provided the diagnosis of TTS leading to the orbital cellulitis.

The patient was ultimately discharged on a course of oral amoxicillin-clavulanic acid and daily fluoxetine to address her previously undiagnosed obsessive-compulsive behavior. In a four-month clinic follow-up, the right ala nasi still appeared necrotic with the right nasal aperture still being widely patent. There was no overt evidence of active infection. The patient did not complain of any visual compromise and no visual acuity was obtained. The patient reported medication non-compliance and continued repetitive manual manipulation of her nose. She refused any further treatment.

DISCUSSION

TTS is a rare condition that develops due to self-destructive behavior coupled with a damaged trigeminal nerve. The damaged trigeminal nerve most commonly is the result of trigeminal surgical ablation or alcohol injection for treatment of trigeminal neuralgia; however, it has been reported with cerebral meningioma resection, cerebrovascular accidents, herpes zoster ophthalmicus, vertebrobasilar insufficiency, acoustic neuroma, post-encephalitic parkinsonism, syringobulbia, meningioma, astrocytoma, Hansen's disease, and trauma.^{1,2,3,4} The insulted trigeminal nerve leads to altered skin sensation such as numbness, tingling, and a pricking sensation in its dermatome.^{1,2,3,4} This altered skin sensation leads to self-induced trauma resulting in tissue destruction manifest as facial ulcerations and/or nasal cartilage destruction. The ala of the nose is a common location for tissue destruction given this area is a "subjectively intense focus of dysaesthesia due to the disparity in innervation at the junction of the trigeminal nerve branches: the ophthalmic nerve branch (V₁) and the maxillary nerve branch (V₂)."⁴

The differential diagnosis of patients with facial or nasal ulcerations can be extensive. Herpetic ulceration and other infectious diseases such as syphilis, yaws, leprosy, trigeminal neuritis, deep fungi, mycobacteria, rhinoscleroma, and leishmaniasis are among the possible infectious etiologies.² Carcinoma, pyoderma gangrenosum and Wegener's granulomatosis are also considerations.² Though rare, TTS should also be included as a possible diagnosis.

The time period from trigeminal nerve injury to onset of the ulcer can be from weeks to several years, with a mean of 1-2 years.² One review article indicates, "the neurotropic ulcerations may manifest weeks to years after the nerve damage, with up to a 20-year latency" with concerning complications including corneal ulcerations, canthal lesions and full thickness, upper eyelid defect.⁴ The management of TTS can be challenging. Patient education and counseling are a cornerstone of treatment.⁴ Occlusive dressings, topical lubricants, antibiotics, and surgical interventions may be considered; however, surgical interventions frequently fail if the physical manipulation of the skin is not controlled.⁴

Though not previously described, our case demonstrates that orbital cellulitis can also complicate TTS. In this case, the patient admitted to routine manual nose picking and repeatedly

using a cotton swab to manipulate her nose for 4-5 years before presentation. This obsessive behavior led to the right alar necrosis and sinus erosion, an unlikely but direct etiology of the orbital cellulitis. Her history of diabetes most likely contributed to the severity of her infection. The management of this patient involved treating the orbital cellulitis with intravenous vancomycin and piperacillin-tazobactam. In an attempt to control her obsessive skin manipulation, she was started on fluoxetine. Sadly, the patient chose to discontinue her fluoxetine and return to self-mutilation, refusing any further attempts to improve her condition.

CONCLUSION

This case demonstrates a previously undescribed complication of trigeminal nerve injury in a patient with OCD. Trigeminal trophic syndrome is an important consideration when caring for patients with facial ulcerations and/or nasal destructive lesions who have a history of trigeminal nerve injury, even with a 30-year latency. Patients with psychiatric disorders and trigeminal neuralgia requiring surgical intervention, require pre-surgical counseling, extra vigilance in post-surgical follow-up, and consideration of appropriate psychiatric medications to prevent the complications of this syndrome.

Documented patient informed consent and/or Institutional Review Board approval has been obtained and filed for publication of this case report.

Address for Correspondence: Linda B. Thompson, MD, University of Alabama School of Medicine, 619 South 19th Street, OHB 251 Birmingham, AL 35249. Email: lbthompson@uabmc.edu.

Conflicts of Interest: By the CPC-EM article submission agreement, all authors are required to disclose all affiliations, funding sources and financial or management relationships that could be perceived as potential sources of bias. The authors disclosed none.

Copyright: © 2018 Thompson et al. This is an open access article distributed in accordance with the terms of the Creative Commons Attribution (CC BY 4.0) License. See: <http://creativecommons.org/licenses/by/4.0/>

REFERENCES

1. Finlay A. Trigeminal trophic syndrome. *Arch Derma.* 1979;115(9):1118.
2. Dicken CH. Trigeminal trophic syndrome. *Mayo Clin Proc.* 1997;72(6):543-5.
3. Rashid RM, Kahchemoune A. Trigeminal trophic syndrome. *J Eur Acad Derm Venereol.* 2007;21(6):725-31.
4. McVeigh K, Adams M, Harrad R, et al. Periocular manifestations of trigeminal trophic syndrome: A case series and literature review.

- Orbit.* 2017;37(1):32-5.
5. Lane JE, Deliduka S. Self-induced nasal ulceration from trigeminal trophic syndrome. *Cutis.* 2008;81(5):419-20.
 6. Uysal PI, Artuz RF, Yalcin BA. A rare case of trigeminal trophic syndrome with an extensive scalp, forehead, and upper eyelid ulceration in a patient with undiagnosed Alzheimer disease. *Dermatol Online J.* 2015;21(8). pii: 13030/qt32w4x4p5.
 7. Monrad SU, Terrell JE, Aronoff DM. The trigeminal trophic syndrome: an usual cause of nasal ulceration. *J Am Acad Dermatol.* 2004;50(6):949-52.

Papilledema: Point-of-Care Ultrasound Diagnosis in the Emergency Department

Joseph R. Sinnott, BS
Mohammad R. Mohebbi, MD
Timothy Koboldt, MD

University of Missouri School of Medicine, Department of Emergency Medicine,
Columbia, Missouri

Section Editor: Rick A. McPheeters, DO

Submission history: Submitted September 11, 2017; Revision received January 17, 2018; Accepted January 10, 2018

Electronically published March 14, 2018

Full text available through open access at http://escholarship.org/uc/uciem_cpem

DOI: 10.5811/cpcem.2018.1.36369

Point-of-care ultrasound (POCUS) has the potential to diagnose papilledema, a sign of increased intracranial pressure, through optic disc elevation as well as optic nerve sheath diameter measurements. Idiopathic intracranial hypertension (IIH) is a syndrome resulting in increased intracranial pressure. We present a case of IIH where the emergency physician diagnosed papilledema by POCUS via presence of both optic disc elevation and a widened optic nerve sheath diameter. [Clin Pract Cases Emerg Med.2018;2(2):125-127.]

INTRODUCTION

Idiopathic intracranial hypertension (IIH) is a syndrome of elevated intracranial pressure of unknown etiology that typically presents in females of childbearing age.² IIH is a diagnosis of exclusion and thus requires a thorough investigation into other potential causes of increased intracranial pressure.² Neurodiagnostic studies are often unremarkable aside from indicating increased cerebrospinal fluid pressure on lumbar puncture.² Papilledema and loss of visual function are potential signs and symptoms, respectively, of IIH.² Misdiagnosis and/or improper treatment of IIH can lead to optic atrophy and irreversible visual loss.² In this report we describe a case of IIH that presented with headache and vision changes. The presence of both optic disc elevation and widened optic nerve sheath diameter in the setting of IIH are testament to the novelty of this case. Papilledema was visualized by point-of-care ultrasound (POCUS).

CASE REPORT

A 27-year-old African-American female with a past medical history of obesity (body mass index: 39) presented to the emergency department (ED) with complaints of headache and vision changes. The patient reported an approximate two-week history of what she described as a throbbing bitemporal headache. She noted partial relief of her headache with alternating courses of acetaminophen and ibuprofen every four hours. Additionally,

she developed intermittent painless vision changes one week prior to the ED visit. She reported that her vision would transiently go dark bilaterally upon opening her eyes. These episodes would self-resolve after approximately one minute. One day prior to her ED visit, the patient endorsed complete painless loss of vision in her left eye, after what she described as a black screen coming over her field of vision while driving. She had no associated symptoms of eye pain, trauma, fevers, neck stiffness, numbness, tingling, weakness, or facial droop.

The patient's vital signs on presentation included temperature 36.7° Celsius, blood pressure 124/78, heart rate 70 beats per minute, and oxygen saturation of 98% on room air. On ophthalmologic examination, pupils were equal and extraocular movements were intact. The patient exhibited 20/20 visual acuity in the right eye. Visual acuity in the left eye revealed loss of peripheral vision and minimal light perception centrally. There was also an afferent pupillary defect of the left eye on swinging light reflex. Fundoscopy in the ED was limited by photophobia, and the optic discs could not be well visualized on undilated examination. Pressure in the left eye and right eye were measured at 23.95 millimeter of mercury (mmHg) and 24.90 mmHg via tonopen, respectively. Non-contrast head computerized tomography (CT) revealed a hyperdense lesion within the posterior sella, which was unchanged from 17 months prior. Otherwise, CT revealed no acute intracranial findings.

In addition to performing a head CT, point-of-care ultrasound (POCUS) was performed in the ED. POCUS of the left eye revealed elevation of the optic disc into the vitreous cavity, consistent with papilledema (Image; Video).³ Ultrasound also revealed an enlarged optic nerve sheath diameter of 7.4 millimeters (mm) (Image). Concern for papilledema prompted emergent ophthalmology and neurology consultation for further assessment. Ophthalmology assessment revealed Grade 3-4 optic disc edema bilaterally, with probable optic neuropathy of the left eye secondary to optic disc edema.

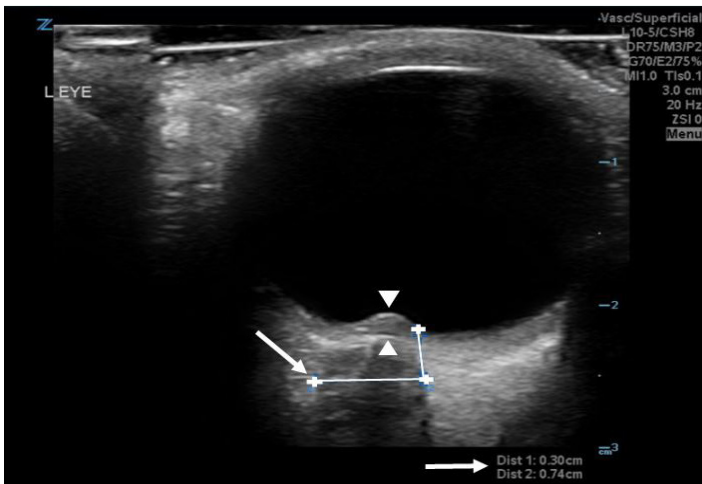


Image. Left ocular ultrasound demonstrating optic disc elevation into the vitreous cavity (white arrow heads), as well as optic nerve sheath diameter measurements (white arrows)

The patient was admitted to neurology for further workup and management. Magnetic resonance imaging (MRI) of the brain obtained upon admission revealed no acute findings or masses that could account for increased intracranial pressure. MRI did demonstrate a posterior pituitary adenoma measuring 10 x 8 mm, but it was not compressing on the optic chiasm or optic nerves. MRI of the brain and sella pre- and post-gadolinium confirmed a pituitary lesion that was unchanged in size dating back to 17 months prior. Laboratory tests assessing pituitary function, including thyroid-stimulating hormone, free thyroxine, and prolactin, resulted within normal limits. CT venogram of the brain was also completed upon admission. Results revealed a hypoplastic right transverse sinus without evidence of sinus thrombosis.

Of importance, lumbar puncture revealed an increased opening pressure of 51 cm H₂O, with a closing pressure of eight cm H₂O. Lack of space-occupying lesions on imaging with associated increased opening pressure on lumbar puncture suggested a diagnosis of IIH.² The patient's headache improved following a large-volume lumbar puncture;

CPC-EM Capsule

What do we already know about this clinical entity?

Idiopathic intracranial hypertension is a syndrome resulting in increased intracranial pressure. Papilledema can be visualized via point-of-care ultrasound (POCUS).

What makes this presentation of disease reportable?

This case was significant for presence of both optic disc elevation and widened optic nerve sheath diameter in a patient with idiopathic intracranial hypertension who presented with headache and vision changes.

What is the major learning point?

Diagnosis of papilledema by POCUS was an effective adjunct in the eventual diagnosis and management of idiopathic intracranial hypertension.

How might this improve emergency medicine practice?

POCUS has the potential to diagnose papilledema in those suspected of having increased intracranial pressure.

however, she continued to have visual field defects in the left eye. The patient was started on acetazolamide 500 milligrams every six hours. Neurosurgery was consulted, and she underwent ventriculoperitoneal shunt placement. Her headache subsequently resolved, with modest improvement in her vision.

She was discharged home seven days after admission, with scheduled follow-up appointments with neurosurgery, neurology, and ophthalmology. Upon follow-up with ophthalmology, there was noted improvement of papilledema in both eyes, but with clinical evidence of optic neuropathy and optic nerve atrophy in the left eye.

DISCUSSION

IIH is a syndrome that results in elevated intracranial pressure. The incidence of this syndrome is more common in women who are obese and of childbearing age.² Additionally, it is a diagnosis of exclusion; thus, other etiologies of increased intracranial pressure must be eliminated via history, physical exam, and neurodiagnostic studies.²

Symptoms of IIH in order of decreasing frequency include headache, transient visual disturbances, tinnitus, photophobia, retrobulbar pain, and visual loss.² Headache, commonly described as pulsatile, is commonly the presenting symptom, as was the case in this patient.² Visual disturbances can include monocular or binocular transient episodes of blurred vision.² These transient episodes of visual disturbance are postulated to be secondary to temporary ischemia of the optic nerve due to increased intracranial pressure.² Similarly, our patient initially had complaints of transient visual field obscuration bilaterally. However, it is postulated that these transient visual field changes are not associated with poor visual field outcomes.² Papilledema is a manifestation of increased intracranial pressure in those with IIH.² Papilledema in cases of IIH is typically bilateral, but can be unilateral.² Papilledema can result in permanent vision loss and optic atrophy if not diagnosed and treated in a timely manner.²

The patient's case demonstrated the use of POCUS for early diagnosis of papilledema at bedside. The presence of optic disc elevation and enlarged optic nerve thickness, in the setting of IIH, points to the novelty of this case. Prior studies have illustrated that optic disc elevation, with a minimum disc height of 0.6 mm, obtained via ultrasound can be 82% sensitive and 76% specific for papilledema.³ Disc height via ultrasound can be acquired by measuring the distance between the anterior peak of the disc and its intersection to the posterior surface of the globe. Optic nerve sheath diameter measurements obtained via ultrasonography can also be a simple and sensitive indicator of increased intracranial pressure.⁴

Using invasive intracranial monitoring as a reference standard, previous studies have revealed that an optic nerve sheath diameter of greater than five mm, measured three mm posterior to the orbit, can be a sensitive (88%) and specific (93%) marker for elevated intracranial pressure of greater than 20 cm H₂O.^{5,6} POCUS for our patient demonstrated a left optic nerve sheath diameter of 7.4 mm, measured three mm posterior to the orbit, suggesting increased intracranial pressure (Image). This was confirmed by lumbar puncture upon admission, which revealed an opening pressure of 51 cm H₂O.

Evidence of papilledema on ultrasound and elevated opening pressure on lumbar puncture, with unremarkable imaging studies, led to the diagnosis of IIH. This was further supported by improvement of the patient's headache and visual changes following appropriate treatment with acetazolamide, large volume cerebrospinal fluid drainage, and ventriculoperitoneal shunt placement. However, the patient suffered from residual visual field deficits in the left eye secondary to papilledema and optic nerve atrophy. This points towards the need for early detection of papilledema, potentially via ocular ultrasonography, in order to initiate timely consultations and treatment regimens.

CONCLUSION

Emergency physicians may find potential benefit in the use of POCUS to diagnose papilledema in those patients suspected of having increased intracranial pressure. Optic disc elevation of greater than 0.6 mm, in addition to optic nerve sheath diameter of greater than five mm, have been shown to be correlated with papilledema.^{3,5,6} Visualization of papilledema by POCUS in the ED may serve as an effective adjunct or alternative to traditional fundoscopic examinations in the diagnosis and management of IIH.

Video. Left ocular ultrasound demonstrating optic disc elevation (white arrow).

Documented patient informed consent and/or Institutional Review Board approval has been obtained and filed for publication of this case report.

Address for Correspondence: Timothy Koboldt, MD, 1 Hospital Drive M566, School of Medicine, Department of Emergency Medicine, Columbia, MO 65212. E-mail: koboldt@health.missouri.edu.

Conflicts of Interest: By the CPC-EM article submission agreement, all authors are required to disclose all affiliations, funding sources and financial or management relationships that could be perceived as potential sources of bias. The authors disclosed none.

Copyright: © 2018 Sinnott et al. This is an open access article distributed in accordance with the terms of the Creative Commons Attribution (CC BY 4.0) License. See: <http://creativecommons.org/licenses/by/4.0/>

REFERENCES

1. Wall M. Idiopathic intracranial hypertension. *Neurol Clin.* 2010;28(3):593-617.
2. Thurtell MJ, Wall M. Idiopathic intracranial hypertension (pseudotumor cerebri): recognition, treatment, and ongoing management. *Curr Treat Options Neurol.* 2013;15(2):1-12.
3. Teismann N, Lenaghan P, Nolan R, et al. Point-of-care ocular ultrasound to detect optic disc swelling. *Acad Emerg Med.* 2013;20(9):920-5.
4. Williams P. Optic Nerve sheath diameter as a bedside assessment for elevated intracranial pressure. *Case Rep Crit Care.* 2017;2017:3978934.
5. Stone MB. Ultrasound diagnosis of papilledema and increased intracranial pressure in pseudotumor cerebri. *Am J Emerg Med.* 2009;27(3):376.e1-376.e2.
6. Kimberly HH, Shah S, Marill K, et al. Correlation of optic nerve sheath diameter with direct measurement of intracranial pressure. *Acad Emerg Med.* 2008;15(2):201-4.

Significant Lactic Acidosis from Albuterol

Maxwell Hockstein, MD
Deborah Diercks, MD

University of Texas Southwestern, Department of Emergency Medicine, Dallas, Texas

Section Editor: Rick A. McPheeters, DO

Submission history: Submitted August 19, 2017; Revision received December 22, 2017; Accepted January 10, 2018

Electronically published March 14, 2018

Full text available through open access at http://escholarship.org/uc/uciem_cpccem

DOI: 10.5811/cpcem.2018.1.36024

Lactic acidosis is a clinical entity that demands rapid assessment and treatment to prevent significant morbidity and mortality. With increased lactate use across many clinical scenarios, lactate values themselves cannot be interpreted apart from their appropriate clinical picture. The significance of Type B lactic acidosis is likely understated in the emergency department (ED). Given the mortality that sepsis confers, a serum lactate is an important screening study. That said, it is with extreme caution that we should interpret and react to the resultant elevated value. We report a patient with a significant lactic acidosis. Though he had a high lactate value, he did not require aggressive resuscitation. A different classification scheme for lactic acidosis that focuses on the bifurcation of the “dangerous” and “not dangerous” causes of lactic acidosis may be of benefit. In addition, this case is demonstrative of the potential overuse of lactates in the ED. [Clin Pract Cases Emerg Med.2018;2(2):128-131.]

INTRODUCTION

Given that increased lactate values (either capillary or true vascular sampling with values greater than 2mmol/L) are unequivocally associated with higher likelihoods of in-hospital mortality across many clinical scenarios (including both medical and traumatic disease), emergency physicians globally are being faced with attributing a lactate value to either a potentially devastating or not-devastating etiology. While different schematics have been presented to classify lactic acidosis, the “Type A” and “Type B” classification scheme is likely insufficient as it does not answer the question “sick or not sick?”

CASE REPORT

We report the case of a 50-year-old male who presented to the emergency department (ED) complaining of dyspnea. The patient had a known history of asthma and felt that his symptoms were typical of his exacerbations. He noted a cough with yellow sputum but denied fevers or any pain. He also reported a history of tension headaches and hyperlipidemia; his medical history was negative for diabetes, seizures, or strokes. He had no prior surgeries. He reported taking amitriptyline 10mg as needed for headaches and was also on atorvastatin 40mg daily. He had no

allergies to medications. He denied any and all alcohol intake and he was not clinically intoxicated.

The triage vital signs were as follow: blood pressure 139/105 mmHg, temperature 35.7°C (96.3°F), heart rate 104 beats per minute, oxygen saturation 94% on room air, and respiratory rate 20 breaths per minute. A chest radiograph did not reveal any acute abnormalities. The patient received a single dose of 15mg of albuterol, 1500mcg of ipratropium, and 60mg of prednisone shortly after his ED arrival. He remained somewhat dyspneic after this initial treatment and was given an additional 10mg of albuterol two hours later. Given that the patient required one additional treatment, the decision was made to transfer him to the observation unit for further monitoring.

As part of the admission process to the observation unit, a basic metabolic panel was ordered, which showed a sodium of 139 mmol/L, potassium of 3.2 mmol/L, chloride of 100 mmol/L, bicarbonate of 18 mmol/L, and an anion gap of 24 mmol/L. The creatinine was 0.91 mg/dL. The aspartate aminotransferase was 16 units/liter and the alanine transaminase was 22 units/liter. The white blood cell count was $7.19 \times 10^9/L$. The admitting team then ordered a lactate to address the anion gap, which resulted at 9.6 mmol/L with a corresponding pH from the venous blood gas of 7.31 and a partial pressure of carbon dioxide of 34 mmHg. The

lactate was repeated one hour later and resulted at 10.3 mmol/L. A standard urine drug screen, examining for amphetamines, benzodiazapines, cannabinoids, cocaine metabolites, opiates, and phencyclidine, was negative. The patient's symptoms had improved and he remained otherwise asymptomatic.

The conundrum we faced was to determine not only whether this was a Type A or Type B lactic acidosis but also its precipitant. Given the lack of toxic appearance, hypotension, and altered mental status it was strongly felt that Type A lactic acidosis was not the culprit. The patient was admitted to our medicine service and observed. Additional albuterol treatments were withheld and the serum lactate value cleared to 1.1 mmol/L approximately 24 hours later. The patient was discharged from the hospital without incident.

DISCUSSION

Since Huckabee's landmark paper in 1961, which identified a group of patients with fatal lactic acidosis, lactate has been used as a test to screen for acute metabolic mismatch.¹ Lactate is produced when pyruvate is not converted to acetyl coenzyme A (CoA) during glycolysis in the setting of normal (aerobic) cellular respiration. Contrary to popular belief, when lactate is formed from pyruvate the product exists as an anion, not with the attached proton.² Therefore, it is not lactate itself that causes acidosis; rather, it is a surrogate marker for an increase in the number of protons accumulating in the failing hydrolysis of adenosine triphosphate. Type A lactic acidosis is defined by the presence of shock (hypoperfusion of any tissue). Type B lactic acidosis is a term that describes any lactic acidosis not due to hypoperfusion. Therefore, the causes for Type B lactic acidosis are more varied than those for Type A lactic acidosis.

Type A Lactic Acidosis

Clinical scenarios such as cardiac arrest, sepsis, and mesenteric ischemia are associated with severe lactic acidosis and with poor outcomes. Given the profound mortality of septic shock, checking serum lactates has been encouraged since the publication of "Surviving Sepsis"³ in 2012 and has been used as a screening tool for serious illness in many additional settings. In general, patients with Type A lactic acidosis require restoration of perfusion, with fluid resuscitation and/or vasopressors. In addition to these clinical pictures, seizures may cause a Type A lactic acidosis; however, our patient did not seize.⁴ He displayed no concerns for a Type A lactic acidosis, and we were directed to consider an additional precipitant.

Type B Lactic Acidosis

Clinical entities such as drugs (therapeutic or otherwise), inborn errors of metabolism, malabsorption syndrome (responsible for elevated levels of D-Lactate, as opposed to L-Lactate) are responsible for Type B lactic acidosis. Germaine to the patient in question, the treatment team was

CPC-EM Capsule

What do we already know about this clinical entity?

Lactic acidosis has many etiologies but can be divided into Type A from hypoperfusion (e.g., sepsis) and Type B from other causes (e.g., medications such as albuterol).

What makes this presentation of disease reportable?

This lactic acid value is significantly higher than previously reported values attributed solely to albuterol in an otherwise-healthy patient.

What is the major learning point?

Though potentially indicative of serious disease, increased lactate values can also indicate a metabolic derangement not necessarily requiring resuscitation.

How might this improve emergency medicine practice?

This case demonstrates that lactic acid values should be interpreted (and treated) in the appropriate clinical context.

initially perplexed as to what caused this lactate value. Causes of Type B lactic acidosis may be bifurcated as a disorder of either increased production of lactate or a decreased clearance of lactate.⁵ Increased production of lactate occurs when the rate of glycolysis increases: catecholamines, diminished pyruvate dehydrogenase activity (congenital or thiamine deficiency), malignancy, and oxidative insufficiencies (cyanide toxicity). Decreased lactate clearance occurs in hepatic enzyme inhibition, mitochondrial defects, and renal disease.

Increased Lactate Production

Catecholaminergic stimulation of the beta-2 receptor upregulates cyclic adenosine monophosphate, which in turn activates protein kinase A (PKA). PKA activation enhances glycogenolysis and yields glucose, a substrate for glycolysis. The acceleration of this process with exogenous catecholamines results in hyperlactatemia.⁶ In addition, a urine toxicology screen was checked to address sympathomimetics as they may cause an increased lactate. However, no drugs of abuse were detected. Our patient had received albuterol; however, this

degree of lactate elevation from albuterol has only seldom been referenced in the literature, especially in such a well-appearing patient. Mean elevations of serum lactate after one hour of albuterol (10mg) administration in healthy volunteers have been reported to be 0.77.⁷ In known asthmatics, the mean lactate level after at least 10mg of albuterol treatment has been reported in two studies to escalate 2.94 mmol/L from normal baselines.^{8,9} Lactate levels in asthmatics are of particular concern because hyperlactatemia may inhibit the bronchodilatory response and that the accompanying acidosis may worsen respiratory effort.⁸

Thiamine is a cofactor in the pyruvate dehydrogenase (PDH) complex and therefore a deficiency of thiamine would decrease the activity of PDH. Decreased PDH activity would increase lactate concentrations by not catalyzing the conversion from pyruvate to acetyl-CoA. In addition to patients who chronically drink ethanol or who have beri beri, those receiving parenteral nutrition also are at risk for thiamine deficiency.¹⁰

The mechanisms for malignancy-driven Type B lactic acidosis are varied. The most common explanation lies in the fact that cancer cells possess high glycolytic activity, an observation termed “the Warburg effect,” initially described in 1924.¹¹ This increased rate of glycolysis, as described earlier, increases serum lactate values.

D-lactate, the isomer of L-lactate, is produced mainly in patients with short-gut syndrome where colonic bacteria are exposed to larger quantities of luminal carbohydrates.⁴ D-Lactate may also be observed with propylene glycol ingestion; it has the potential to cross the blood-brain barrier and cause neurologic sequelae such as encephalopathy (slurred speech, ataxia, hallucinations, somnolence), which can last from hours to days.¹²

One of the most well-known side effects of 3-hydroxy-3-methyl-glutaryl CoA reductase inhibitors (statins) is myopathy. Infrequently, statins have been associated with increased serum lactate values of similar cardinalities. Lactic acidosis attributable to a statin is an uncommon event; rather, it is often associated with concomitant metabolic derangements.^{13,14} The proposed mechanism by which statins may contribute to lactic acidosis is a depletion of ubiquinone (also known as CoQ10 (an important cofactor for the electron transport chain)). However, concrete evidence of a mechanism is lacking.

Decreased Lactate Clearance

The liver is responsible for the majority (70-75%) of lactate clearance^{5,10} with the remainder eliminated by the kidneys. In patients with hepatic disease or hepatic injury (e.g., ischemic hepatitis) lactate may be elevated. However, a primary insult, which would elevate the lactate in the first place, must be considered. In septic patients without septic shock, the oxygen delivery to tissues is generally increased; therefore, increased lactate levels in this subset of patients are likely due to decreased clearance rather than increased production.⁵

CONCLUSION

The significance of Type B lactic acidosis is likely understated in the ED. Given the mortality that sepsis confers, a serum lactate is an important screening study. That said, it is with extreme caution that we should interpret and react to the resultant value. This patient, though he had a high lactate value, likely did not require aggressive resuscitation. A more rigorous classification scheme for lactic acidosis might be of clinical benefit. Emergency physicians should be aware that lactate values may be dramatically elevated for several reasons, only one of them being albuterol.

Documented patient informed consent and/or Institutional Review Board approval has been obtained and filed for publication of this case report.

Address for Correspondence: Maxwell Hockstein, MD, University of Texas Southwestern, Department of Emergency Medicine, 5323 Harry Hines Blvd., Dallas, TX. Email: max.hockstein@gmail.com.

Conflicts of Interest: By the CPC-EM article submission agreement, all authors are required to disclose all affiliations, funding sources and financial or management relationships that could be perceived as potential sources of bias. The authors disclosed none.

Copyright: © 2018 Hockstein. This is an open access article distributed in accordance with the terms of the Creative Commons Attribution (CC BY 4.0) License. See: <http://creativecommons.org/licenses/by/4.0/>

REFERENCES

1. Huckabee WE. Abnormal resting blood lactate. *Am J Med.* 1961;30:840-8.
2. Mizock BA. Controversies in lactic acidosis. *JAMA.* 1987;258(4):497-501.
3. Rivers E, Nguyen B, Havstad S, et al. Early Goal-Directed Therapy in the Treatment of Severe Sepsis and Septic Shock. *N Engl J Med.* 2001; 345:1368-77.
4. Anderson LW, Mackenhauer J, Roberts JC, et al. Etiology and therapeutic approach to elevated lactate. *Mayo Clin Proc.* 2013;88(10):1127-40.
5. Phipers Barrie, Pierce JM. Lactate physiology in health and disease. *Contin Education in Anaesthesiology, Critical Care, & Pain.* 2006, pp. 128-132.
6. Barth E, Albusizies G, Baumgart K, et al. Glucose metabolism and catecholamines. *Crit Care Med.* 2007;35(9 Suppl):S508-18.

7. Zitek T, Cleveland N, Rahbar A, et al. Effect of nebulized albuterol on serum lactate and potassium in healthy subjects. *Acad Emerg Med*. 2016;23(6):718-21.
8. Rodrigo GJ, Rodrigo C. Elevated plasma lactate level associated with high dose inhaled albuterol therapy in acute severe asthma. *Emerg Med J*. 2005;22(6):404-8.
9. Lewis LM, Ferguson I, House SL, et al. Albuterol administration is commonly associated with increases in serum lactate in patients with asthma treated for acute exacerbation of asthma. *Chest*. 2014;145(1):53-9.
10. Kraut JA, Madias NE. Lactic Acidosis. *N Eng J Med*. 2014;371(24):2309-19 .
11. Vander Heiden MG, Cantley LC, Thompson CB. Understanding the Warburg effect: The metabolic requirements. *Science*. 2009;324(5930):1029-33.
12. Uribarri J, Oh MS, Carroll HJ. D-lactic acidosis. A review of clinical presentation, biochemical features, and pathophysiologic mechanisms. *Medicine (Baltimore)*. 1998;77(2):73-82.
13. Goli AK, Goli SA, Byrd RP Jr, et al. Simvastatin-induced lactic acidosis: A rare adverse reaction? *Clin Pharmacol Ther*. 2002;72(4):461-4.
14. Neale R, Reynolds TM, Saweirs W. Statin precipitated lactic acidosis? *J Clin Pathol*. 2004;57(9):989-90.

Diagnosis of Hand Infections in Intravenous Drug Users by Ultrasound and Water Bath: A Case Series

John DeAngelis, MD, RDMS*†
Erika St. James, MD, RDMS*
Penelope C. Lema, MD, RDMS*

*University at Buffalo Jacobs School of Medicine and Biomedical Sciences,
Department of Emergency Medicine, Buffalo, New York

†Cambridge Health Alliance, Department of Emergency Medicine, Cambridge,
Massachusetts

Section Editor: Rick A. McPheeters, DO

Submission history: Submitted August 31, 2017; Revision received December 21, 2017; Accepted January 10, 2018

Electronically published March 14, 2018

Full text available through open access at http://escholarship.org/uc/uciem_cpem

DOI: 10.5811/cpcem.2018.1.36283

We present three cases of hand injury by intravenous drug users in which point-of-care ultrasound, using a specific water bath technique, was able to quickly and efficiently delineate severity of injury. This technique benefited these patients by allowing a painless assessment of their injury for soft tissue injury vs. abscess formation and allowed providers to determine at the bedside whether these patients required immediate surgical intervention. [Clin Pract Cases Emerg Med.2018;2(2):132-135.]

INTRODUCTION

It can be difficult to determine the severity of a hand infection. While deep space infections, tenosynovitis, and necrotizing fasciitis of the hand can cause significant morbidity and in some cases mortality if untreated with surgery or intravenous (IV) antibiotics, superficial infections can often be treated with oral antibiotics on an outpatient basis.¹ The most common cause of acute hand infections is direct inoculation followed by neglect of the wound, such as may be encountered in IV substance abuse.^{1,2} Hand infections are often associated with severe pain that can limit patient cooperation and a thorough physical examination.

The use of ultrasound with a water bath is well tolerated and has been described as a technique to improve the resolution of superficial structures.³ The recent opioid epidemic in the United States will likely contribute to an increased presentation of soft tissue complications due to IV injections.⁴ Patients at high risk for long-term morbidity secondary to hand infection are repeatedly injecting narcotics into the dorsal hand under unsterile conditions. We present three cases from a county emergency department (ED) in which the water bath ultrasound technique was used to help differentiate superficial injuries from serious hand infections. This technique was performed at the bedside and well tolerated by patients who were unable to tolerate a thorough physical examination due to extreme discomfort or pain.

CASE REPORT

Case 1

A 23-year-old female with a history of IV drug use presented to our ED with complaint of a swollen left hand. She had injected heroin into her left hand one week prior. Her exam was notable for a swollen, warm, extremely tender dorsal left hand. The patient's discomfort with palpation of the hand limited the physical examination. The patient was unable to extend her fingers due to pain.

Her hand was placed in a warm water bath at the bedside. A point-of-care ultrasound (POCUS) evaluation of her hand was performed by an emergency physician (EP) using a Zonare Z.One Ultra 10MHz linear transducer (Mountain View, CA). A large fluid collection was noted along the extensor tendon sheaths of the second to fifth digits with surrounding cobblestoning of the soft tissue (Image 1). These ultrasound findings raised the suspicion of extensor tenosynovitis, and we consulted the orthopedic service. A bedside incision and drainage performed by the orthopedic resident revealed purulent discharge. The patient was emergently sent to the operating room. Intraoperatively, it was confirmed that she had extensor tenosynovitis with dorsal extensor compartment syndrome. The wound culture resulted in Group A β -hemolytic streptococcus.

Case 2

A 47-year-old female with a history of IV drug use was transferred to our ED with complaint of a swollen right hand.

She had injected heroin into her right hand one day prior. Her exam was notable for swelling of the dorsum of her right hand associated with warmth and extreme tenderness with any movement of the digits. The patient had a limited physical examination due to pain. Her hand was placed in a warm water bath at the bedside. An EP then performed a POCUS evaluation of her hand with a Zonare Z.One Ultra 10MHz linear transducer (Mountain View, CA). The ultrasound image revealed diffuse cobblestoning and fluid within the soft tissue with no abscess or discrete fluid collection (Image 2). Orthopedic consult was obtained. The patient was diagnosed with an extravasation injury due to infiltration of the vein and she was discharged home on oral antibiotics.

CASE 3

A 24-year-old male with a history of IV drug use presented to our ED with complaint of a swollen left hand, fever and chills. The patient had injected cocaine into his left hand three days prior to evaluation. His exam was notable for diffuse swelling and tenderness to the volar and dorsal aspects of his hand. He was in extreme pain, which limited the physical examination.

The patient's hand was placed in a warm water bath at the bedside. A POCUS evaluation of the patient's hand was performed by an EP with a Sonosite M-Turbo 10MHz linear transducer (Bothell, WA). The ultrasound revealed extensive, soft tissue swelling with small areas of fluid collection and air artifacts concerning for necrotizing fasciitis (Image 3a). The orthopedic service was consulted. Further radiographic evaluation confirmed the ultrasound finding of subcutaneous air (Image 3b). The patient went to the operating room with orthopedics for incision and drainage. Intraoperatively, he was confirmed with necrotizing fasciitis and compartment syndrome of the hand. Blood and wound cultures resulted in *Bacteroides pyogenes* and streptococcal species.

DISCUSSION

The use of ultrasound to diagnose acute finger or hand infections in the emergency setting has been previously described by Blavais et al.³ They also incorporated the use of a water bath to improve image quality of superficial structures. We employed this technique successfully in these three cases to help identify and risk-stratify patients with hand infections related to substance abuse injection. With heroin abuse on the rise in the U.S., healthcare providers will likely see increasing rates of hand infection secondary to IV drug use.⁴ These infections will typically be in the dorsum of the hand due to the availability of venous access in that area. Because the dorsal hand is the most common site of hand infections, non-sterile injections and re-use of needles are likely to result in a prime environment for infections of the hand, deep space, and tendons therein.² These infections often cause exquisite

CPC-EM Capsule

What do we already know about this clinical entity?

Hand injuries secondary to injection drug use and the water bath technique have both been previously described in the literature.

What makes this presentation of disease reportable?

The combination of the water bath technique with this type of injury is an easy application of ultrasound technology, which directly aids in diagnosis and is readily available in most departments.

What is the major learning point?

Use of point-of-care ultrasound in the emergency department (ED) for prompt diagnosis of hand injuries requiring admission is relatively easy and effective. The use of a water bath helps with patient comfort and may improve image quality.

How might this improve emergency medicine practice?

This technique is easily employed in most EDs and will aid in making treatment plans. It has the potential to become a regular part of emergency practice for injuries of this type.

pain and swelling, which can limit examination of the affected area and lead to unidentified abscess or necrotizing fasciitis.

CONCLUSION

Ultrasound has been shown to be useful in the diagnosis of necrotizing fasciitis and infections of the hand.^{5,6,7} The addition of a water bath at bedside is an easy intervention to improve patient comfort and imaging.³ In these cases we were able to separate two patients who needed urgent surgical intervention and IV antibiotics from another who had a more superficial extravasation injury and could be discharged home with outpatient therapy. This intervention was quick and well tolerated by the patients. The one patient with superficial injury was able to go home without an unnecessary observational stay, while the case of necrotizing fasciitis was identified almost immediately and brought to the operating room in a very timely fashion. As more patients present to the ED with hand infections related to substance abuse, POCUS with addition of the water

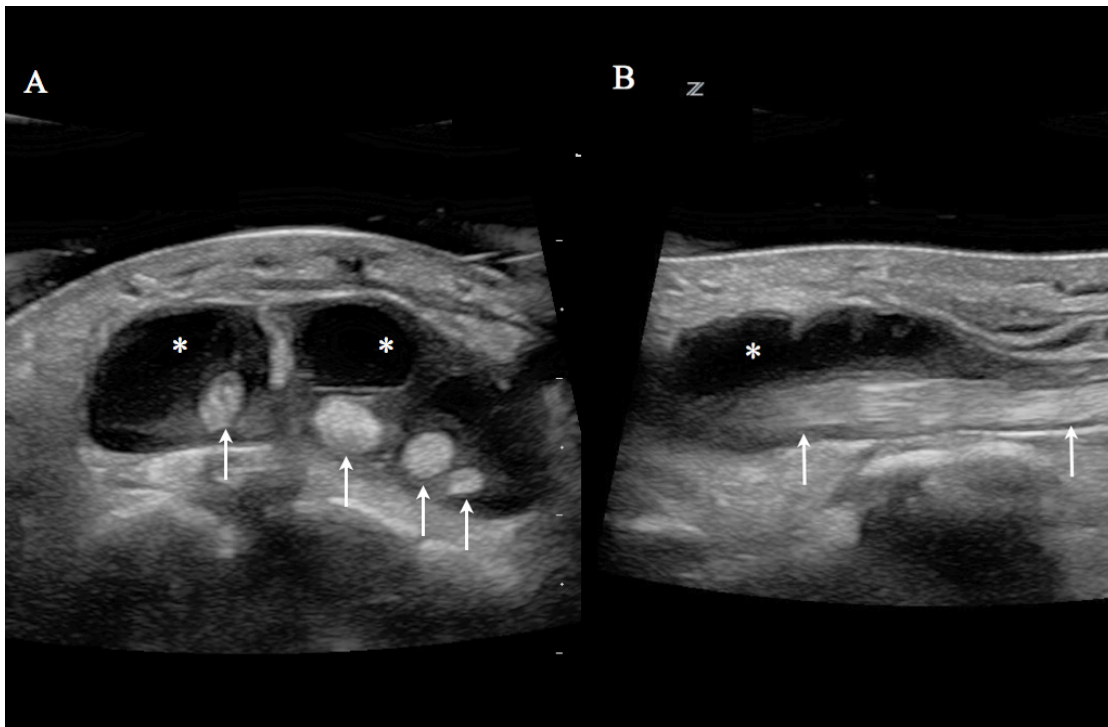


Image 1. Ultrasound with water bath of a patient with extensor tenosynovitis of the hand due to intravenous drug use. (A) Transverse view of the left hand with fluid collection (asterisk) surrounding the dorsum of the second to fifth digit extensor tendons (arrows). (B) Longitudinal view of the third-digit extensor tendon. Fluid collection (asterisk) surrounding the tendon (arrows).

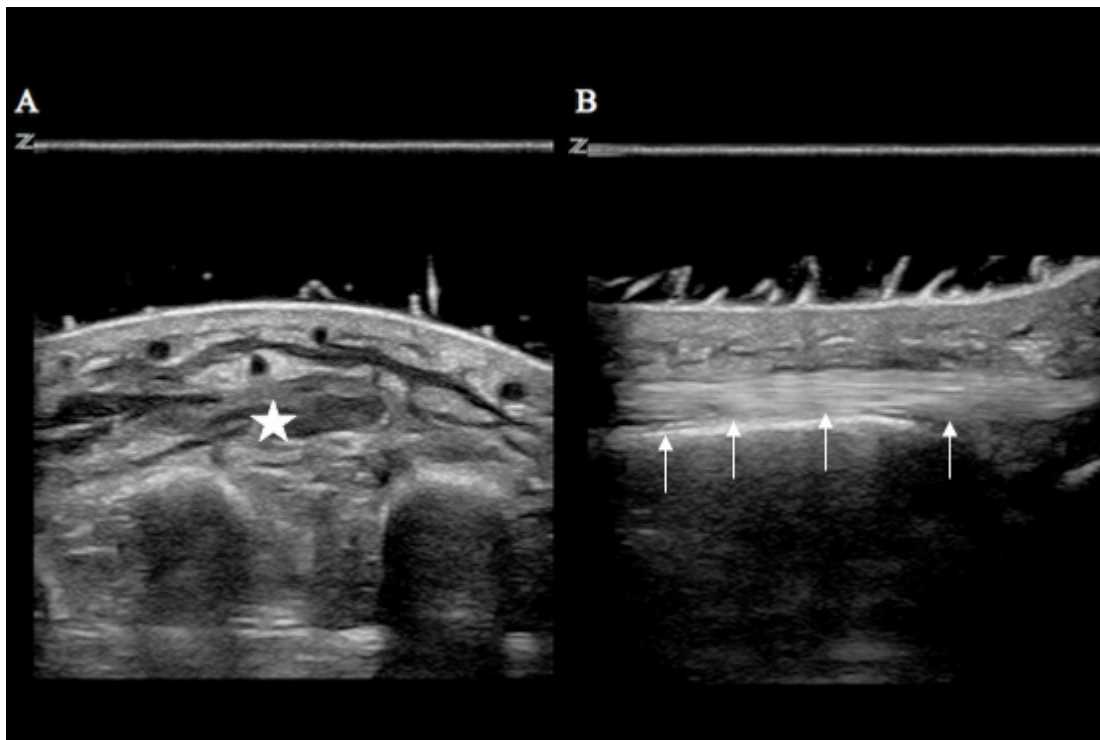


Image 2. Ultrasound with water bath of a patient's hand with infiltration of the vein due to intravenous cocaine injection. (A) Transverse view of the right hand with fluid and cobblestoning within the soft tissue (star) without a discrete abscess or fluid collection. (B) Longitudinal view of the right hand extensor tendon (arrows) without a discrete fluid collection.

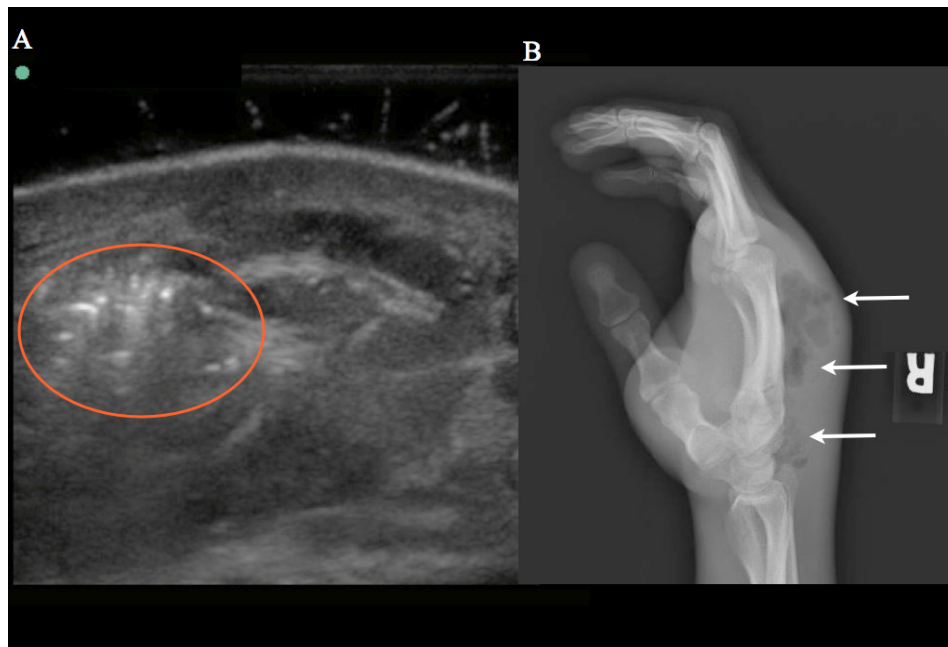


Image 3. Ultrasound with water bath and radiograph of a patient with necrotizing fasciitis of the hand due to intravenous drug use. (A) Transverse ultrasound view of the right hand with echogenic air (red circle) within the soft tissue. (B) Lateral radiography of the right hand with extensive soft tissue swelling and air within the dorsum of the hand (arrows).

bath may be a valuable diagnostic adjunct for rapid differentiation of soft tissue infections of the hand so that they can be appropriately diagnosed and treated in a timely manner.

Documented patient informed consent and/or Institutional Review Board approval has been obtained and filed for publication of this case report.

Address for Correspondence: John DeAngelis, MD, RDMS
Cambridge Hospital, Department of Emergency Medicine, 1493
Cambridge St, Cambridge, MA 02139. Email: deangelisjg@gmail.com.

Conflicts of Interest: By the CPC-EM article submission agreement, all authors are required to disclose all affiliations, funding sources and financial or management relationships that could be perceived as potential sources of bias. The authors disclosed none.

Copyright: © 2018 DeAngelis. This is an open access article distributed in accordance with the terms of the Creative Commons Attribution (CC BY 4.0) License. See: <http://creativecommons.org/licenses/by/4.0/>

REFERENCES

1. Patel DB, Emmanuel NB, Stevanovic MV, et al. Hand infections: anatomy, types and spread of infection, imaging findings, and treatment options. *Radiographics*. 2014;34(7):1968-86.
2. Osterman M, Draeger R, Stern P. Acute hand infections. *J Hand Surg Am*. 2014;39(8):1628-35; quiz 1635.
3. Blaivas M, Lyon M, Brannam L, et al. Water bath evaluation technique for emergency ultrasound of painful superficial structures. *Am J Emerg Med*. 2004;22(7):589-93.
4. Kolodny A, Courtwright DT, Hwang CS, et al. The prescription opioid and heroin crisis: a public health approach to an epidemic of addiction. *Annu Rev Public Health*. 2015;36:559-74.
5. Oelze L, Wu S, Carnell J. Emergency ultrasonography for the early diagnosis of necrotizing fasciitis: a case series from the ED. *Am J Emerg Med*. 2013;31(3):632 e5-7.
6. Wronski M, Slodkowski M, Cebulski W, et al. Necrotizing fasciitis: early sonographic diagnosis. *J Clin Ultrasound*. 2011;39(4):236-9.
7. Gottlieb J, Mailhot T, Chilstrom M. Point-of-Care ultrasound diagnosis of deep space hand infection. *J Emerg Med*. 2016;50(3):458-61.
8. Wilkerson RG, Kim HK, Windsor TA, et al. The opioid epidemic in the United States. *Emerg Med Clin North Am*. 2016;34(2):e1-e23.

Facial Baroparesis Mimicking Stroke

Diann M. Krywko, MD*
D. Tyler Clare, MD*
Mohamad Orabi, MD†

*Medical University of South Carolina, Department of Emergency Medicine, Charleston, South Carolina
†Medical University of South Carolina, Department of Neurology, Charleston, South Carolina

Section Editor: Rick A. McPheeters, DO

Submission history: Submitted September 21, 2017; Revision received February 10, 2018; Accepted January 10, 2018

Electronically published March 14, 2018

Full text available through open access at http://escholarship.org/uc/uciem_cpem

DOI: 10.5811/cpcem.2018.1.36488

We report a case of a 55-year-old male who experienced unilateral facial muscle paralysis upon ascent to altitude on a commercial airline flight, with resolution of symptoms shortly after descent. The etiology was determined to be facial nerve barotrauma, or facial baroparesis, which is a known but rarely reported complication of scuba diving, with even fewer cases reported related to aviation. The history and proposed pathogenesis of this unique disease process are described. [Clin Pract Cases Emerg Med.2018;2(2):136-138.]

INTRODUCTION

Facial baroparesis is a seventh cranial nerve palsy caused by transient hypoxemia of the facial nerve secondary to increased pressure in the middle ear cavity. It has classically been reported in divers, with isolated cases reported in the aviation literature.^{1,2,3,4} The facial nerve travels through the tympanic segment of the facial canal. It is in this segment of its complicated anatomical course that the nerve is thought to be affected by increased pressure. This temporary, ischemic neuropraxia may be relieved by equalizing the pressure in the middle ear, through the nasopharynx via the eustachian tube. We report a case of baroparesis involving a previously healthy 55-year-old male who experienced a transient facial nerve palsy while traveling on commercial aircraft.

CASE REPORT

A 55-year-old Caucasian male flying between New York City and Miami noticed an increased sensation of pressure in his ears upon ascent, which he was unable to equalize using typical techniques (Valsalva, yawning, chewing gum). At maximum elevation, he experienced a tingling sensation on the left side of his tongue, left-sided facial numbness, dysarthria and a generalized headache. He noticed left-sided facial drooping when looking at his reflection in a mirror. The flight attendant was notified and a mid-air emergency was called. Two orthopedic physician passengers responded and evaluated the patient. Their exam

noted left upper and lower facial droop along with dysarthria. Vital signs including blood pressure were within normal limits. Forty-five minutes after symptom onset, an emergency landing was initiated. Upon descent, the patient reported that the pressure sensation started to decrease in his left ear, and suddenly his left ear “popped,” leading to near-complete resolution of symptoms. Repeat exam noted improvement of facial asymmetry. The patient was transported by ambulance to the emergency department (ED) for further evaluation.

In the ED he reported a history of nasal congestion and cough for three weeks prior to the flight. His social history was negative for tobacco or drug use, with social alcohol use reported. Current medications included an unknown antibiotic and Flonase. His physical exam showed the following vital signs: blood pressure 152/88 millimeters of mercury, heart rate 70 beats per minute, temperature 36.9° Celsius, respiratory rate 14 breaths per minute, oxygen saturation 99% on room air. Examination of his head, eyes, ears, nose and throat was unremarkable. Neurologic examination revealed an alert and oriented male in no distress, normal orientation, attention and language. Cranial nerves II-XII were intact, though there was a question of slight left upper-lip asymmetry as described by the emergency physician. His motor, sensation, coordination, and reflexes were all normal. The National Institutes of Health Stroke Scale was zero.

Secondary to the possible asymmetry, the stroke team

was activated by the ED. Imaging was obtained including a non-contrasted computed axial tomography (CT) of his head, a CT angiogram of the head and neck, and magnetic resonance imaging with and without contrast of his head and neck. All imaging was normal. Laboratory results showed white blood cell count 10.9×10^3 per microliter, hemoglobin 15.1 millimole per liter (mm/L), platelets $278 \times 10^9/L$, sodium 141 mm/L, potassium 4.4 mm/L, glucose 94 milligram per decaliter (mg/dL), blood urea nitrogen 17 mg/dL, creatinine 0.9 mg/dL, calcium 9.3 mg/dL and normal liver function tests. A lipid panel showed low-density lipoproteins of 124 mg/dL, otherwise normal.

The patient was admitted to the stroke service for overnight observation. With a negative work-up and return to his baseline, his symptoms were ultimately attributed to facial baroparesis. The dysarthria, a poorly localized neurological deficit, was attributed to the facial muscle weakness. The patient was discharged with recommendations for nasal decongestant use prior to boarding future flights, as well as aspirin and a cholesterol-lowering agent, and follow-up for blood pressure monitoring.

DISCUSSION

The pathophysiology behind facial baroparesis can be easily explained by the nerve's anatomical course (Figure 1). The facial nerve exits the brainstem at the pontomedullary junction and traverses the cerebellopontine angle prior to entering the petrous portion of the temporal bone via the internal auditory meatus. It then travels through the facial canal, which is subdivided into three segments: the labyrinthine segment – giving off a branch to the greater petrosal nerve; the tympanic segment; and the mastoid segment – giving off branches to the stapedius and chorda tympani. The nerve then exits the skull via the stylomastoid foramen, traverses the parotid gland, and separates into five terminal branches that innervate the nerves of facial expression.⁵

The most widely accepted mechanism of facial nerve baroparesis is an ischemic neuropraxia occurring at the tympanic segment of the facial nerve. The tympanic portion of the facial canal traverses the middle ear cavity just medial to the incus. Here the facial nerve and middle ear are separated by only a thin layer of bone. In one study, spontaneous dehiscence of the tympanic portion of the canal was observed on CT in up to 55% of normal adults, resulting in direct communication between the facial nerve and the middle ear cavity.⁶

The middle ear is an enclosed, air-filled space. With an intact tympanic membrane, the only mechanism of pressure equalization is through the nasopharynx via the eustachian tube. With even a mild degree in eustachian tube dysfunction, it can be difficult to equalize the pressures in the middle ear with the outside environment. At a cruising

CPC-EM Capsule

What do we already know about this clinical entity?

Facial baroparesis, first reported in divers, is a seventh cranial nerve palsy caused by transient hypoxemia of the facial nerve secondary to increased pressure in the middle ear cavity.

What makes this presentation of disease reportable?

The incidence is unknown and only 23 cases have been reported in the available literature.⁸

What is the major learning point?

Facial baroparesis is an under recognized condition potentially mimicking stroke, Bell's Palsy, air embolism, or Type II decompression sickness.

How might this improve emergency medicine practice?

Entity awareness may result in less unnecessary testing, decreased long term ischemic nerve damage, and a reduction of inappropriate revocation of diving and/or aviation licenses.

altitude of 35,000 feet, the decrease in cabin pressure is estimated to be as high as 266 centimeters of water, a pressure that can easily overcome capillary hydrostatic pressure.⁷ It is thought that this increase in middle ear pressure is transmitted directly to the tympanic portion of the facial nerve, resulting in a temporary, ischemic neuropraxia. In our case, as in similar reported cases, all symptoms resolved shortly after equalization of middle ear and ambient pressures.^{1,2,3,4}

CONCLUSION

Facial baroparesis is thought to be caused by transient ischemia of seventh cranial nerve. Though uncommon, emergency physicians must consider this diagnosis when facial nerve complaints occur. Eliciting an accurate history, typically involving diving or flying, will lend itself to an accurate diagnosis. Symptoms should resolve upon equalization of middle ear and ambient pressures.

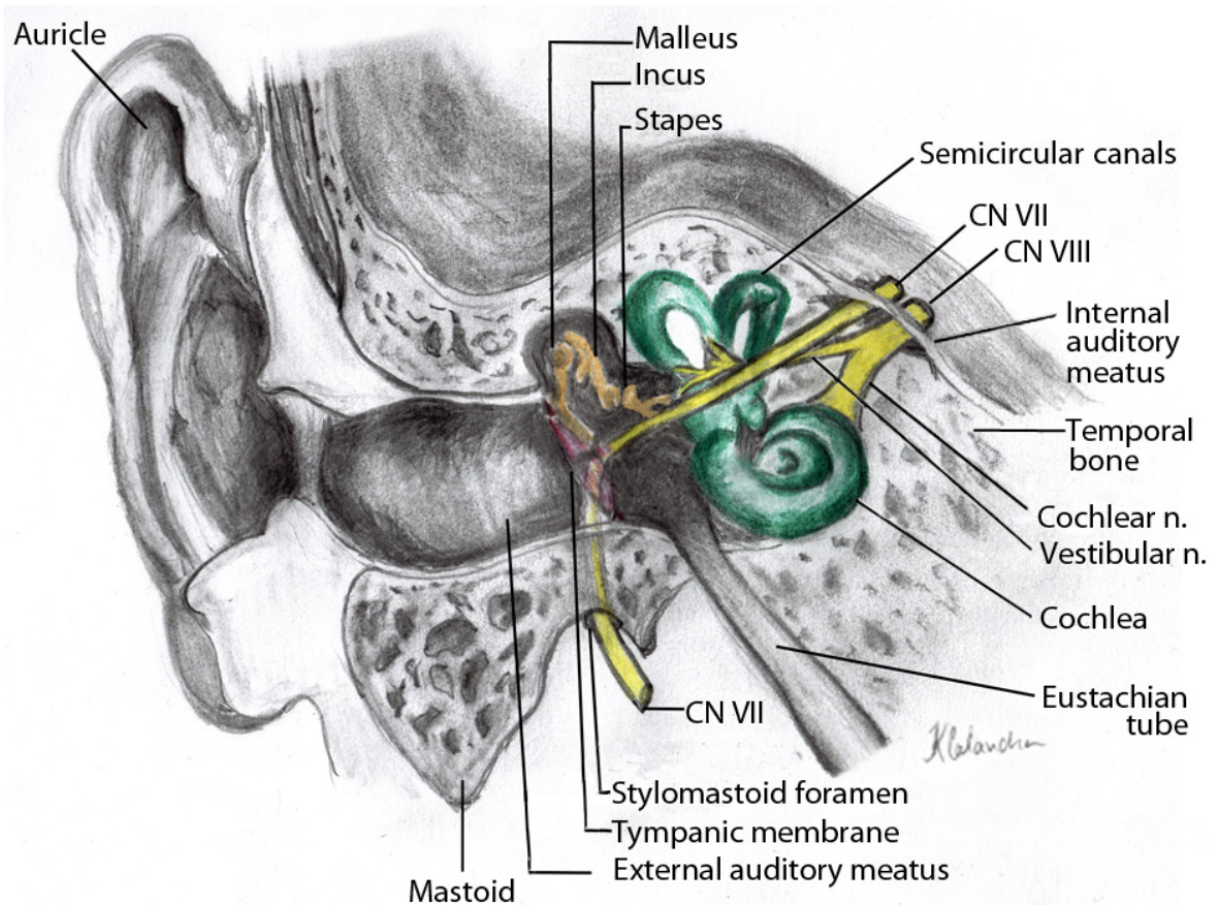


Image. Anatomical course of the facial nerve through the facial canal, from entry via internal auditory meatus to exit at stylomastoid foramen. Illustrated by Kristin Calandra, PAC, MSPAS.

Documented patient informed consent and/or Institutional Review Board approval has been obtained and filed for publication of this case report.

Address for Correspondence: Diann M. Krywko, MD, Director of Wellness and Professional Development, Department of Emergency Medicine, 1880 Hall Point Rd. Mount Pleasant, South Carolina 29466. Email: krywko@musc.edu.

Conflicts of Interest: By the CPC-EM article submission agreement, all authors are required to disclose all affiliations, funding sources and financial or management relationships that could be perceived as potential sources of bias. The authors disclosed none.

Copyright: © 2018 Krywko et al. This is an open access article distributed in accordance with the terms of the Creative Commons Attribution (CC BY 4.0) License. See: <http://creativecommons.org/licenses/by/4.0/>

REFERENCES

1. Bennett DR, Liske E. Transient facial paralysis during ascent to altitude. *Neurology*. 1967;17(2):194-8.
2. Eidsvik S, Molvaer OI. Facial baroparesis: a report of five cases. *Undersea Biomed Res*. 1985;12(4):459-63.
3. Kamide D, Matsunobu T, Shiotani A. Facial baroparesis caused by scuba diving. *Case Rep Otolaryngol*. 2012;2012:329536.
4. Kumar, A. Alternobaric vertigo: A case report. *Ind J Aerospace Med*. 2000;44(2):64-7.
5. Myckatyn T, Mackinnon S. A review of facial nerve anatomy. *Semin Plast Surg*. 2004;18(1):5-12.
6. Baxter, A. Dehiscence of the fallopian canal. An anatomical study. *J Laryngol Otol*. 1971;85(6):587-94.
7. Motamed M, Pau H, Narula A. Recurrent facial nerve palsy on flying. *J Laryngol Otol*. 2000;114(9):704-5.
8. Molvaer OI, Eidsvik S. Facial baroparesis: a review. *Undersea Biomed Res*. 1987;14(3):277-95.

An Unlikely Cause of Abdominal Pain

Norah Kairys, MD
Keegan Skidmore, MD
Jennifer Repanshek, MD
Wayne Satz, MD

Temple University Hospital, Department of Emergency Medicine, Philadelphia, Pennsylvania

Section Editor: Rick A. McPheeters, DO

Submission history: Submitted November 17, 2017; Revision received February 11, 2018; Accepted February 11, 2018

Electronically published March 14, 2018

Full text available through open access at http://escholarship.org/uc/uciem_cpccem

DOI: 10.5811/cpcem.2018.2.37073

Cecal bascule is a rare subtype of cecal volvulus where the cecum folds anterior to the ascending colon causing intestinal obstruction. It is a challenging diagnosis to make in the emergency department, as the mobile nature of the cecum leads to a great deal of variation in its clinical presentation. Our discussion of a 78-year-old female who presented with abdominal pain and was found to have a cecal bascule requiring right hemicolectomy, demonstrates how emergency physicians must expand their differential diagnosis for patients reporting signs of intestinal obstruction. Though cecal bascule does not present often, the need for early surgical intervention necessitates a high level of clinical suspicion to prevent life-threatening complications. [Clin Pract Cases Emerg Med. 2018;2(2):139-142.]

INTRODUCTION

Most cases of large bowel obstruction worldwide are caused by malignancy, with diverticular disease and volvulus causing the small remainder of obstructions.¹ Of the cases of intestinal volvulus, the sigmoid is the most commonly affected portion of the colon.² Cecal volvulus accounts for less than 1% of all large bowel obstructions, and a cecal bascule is estimated to occur in only 10% of these cases of cecal volvulus.¹

A review of 561 patients with cecal volvulus demonstrated that this condition commonly presents with symptoms of bowel obstruction – abdominal pain, constipation, nausea and vomiting.³ Physical exam may reveal abdominal distension, hyperperistalsis, peritoneal signs, an abdominal mass and/or absent bowel sounds.³ However, patients with a cecal bascule may only have intermittent signs of obstruction due to periodic flipping of the cecum back into its anatomical position.¹ Many cases of cecal bascule presenting to the emergency department (ED) are missed on initial presentation due to this phenomenon of periodic obstruction. This subtype is thought to strangulate less often as its mesentery is infrequently twisted, but it can still progress to cause intestinal ischemia if not adequately addressed.¹

CASE REPORT

A 78-year-old female with recent placement of a percutaneous endoscopic gastrostomy (PEG) presented to the ED with a chief complaint of abdominal pain over the prior two days. The patient stated that the pain had begun at her PEG-tube site after putting pressure on the area when climbing out of a car the day before. The pain was intermittent and cramping in nature – lasting a few minutes before subsiding and becoming more severe over the previous 24 hours. At the time of presentation, the patient was complaining of some abdominal distension but denied any nausea, vomiting, constipation, or obstipation.

On exam, her vital signs were mildly abnormal, but did not demonstrate a patient who was hemodynamically unstable. Her respiratory rate was slightly elevated at 20 breaths per minute, her heart rate was 97 beats per minute, she had a pulse oximeter reading of 94% on room air, and she was afebrile. The patient's blood pressure was also within the normal range at 115/85 millimeters of mercury. On physical examination, the patient's abdomen was soft but distended, and diffusely tender to palpation.

While awaiting the results of her bloodwork, she had one episode of non-bloody bilious emesis in the ED. She was found to have a serum potassium level of 2.9 mEq/L, chloride

of 95 mEq/L, bicarbonate of 36 mEq/L, and a pH of 7.49. Interestingly, her white blood cell count was $6.2 \times 10^9/L$. Her chest radiography demonstrated elevation of the left hemi-diaphragm and left lower lobe consolidation (Image 1).

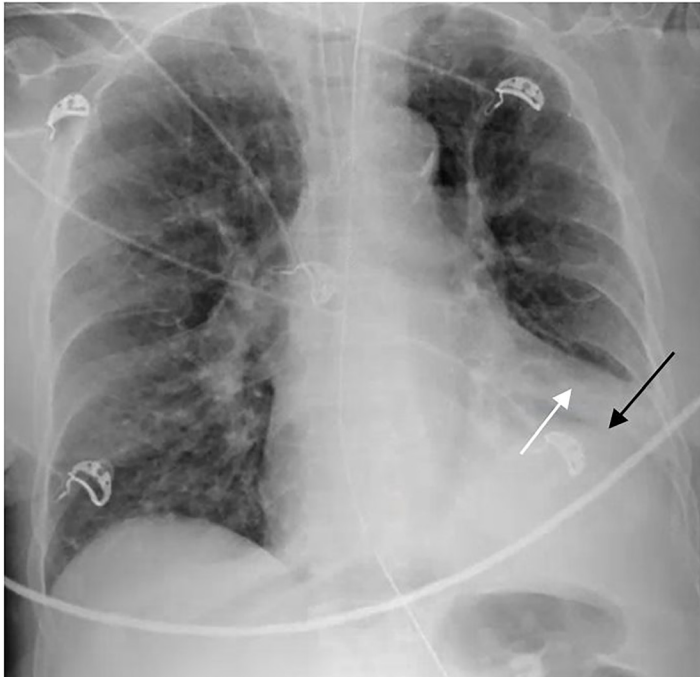


Image 1. Posterior-anterior radiograph of the chest demonstrating elevation of left hemi-diaphragm (black arrow) and left lower lobe consolidation (white arrow).

A computed tomography (CT) of her abdomen and pelvis led to the diagnosis of a cecal bascule, and general surgery was consulted (Images 2 and 3). The patient received a right hemicolectomy and ileostomy that evening and was admitted to the surgical intensive care unit following the procedure.

DISCUSSION

Cecal volvulus has been described as a cause of intestinal obstruction since first noted in 1837 by Rokitsky.⁴ Failure of fixation of the cecum in the right lower quadrant during embryogenesis can predispose an individual to formation of a volvulus.¹ The cecal bascule, which is far less common, was defined by Weinstein in 1938 as a subtype of cecal volvulus accounting for less than 10% of all cases.⁵

Cecal bascule, caused by the cecum folding anterior to the ascending colon, leads to intestinal obstruction.⁶ This anterior folding causes inflammatory adhesions to form between the original anterior wall and the ascending colon.⁴ This in turn leads to a flap valve occlusion that prevents cecal emptying.

CPC-EM Capsule

What do we already know about this clinical entity?

Cecal bascule is a rare type of bowel obstruction that requires early surgical intervention to prevent life-threatening complications.

What makes this presentation of disease reportable?

Our case demonstrates how a cecal bascule could potentially present in the ED and the necessary work-up required to make this important diagnosis.

What is the major learning point?

With its varied presentations and intermittent symptoms, a cecal bascule is a difficult diagnosis that requires a high level of clinical suspicion.

How might this improve emergency medicine practice?

By understanding the unique clinical presentation of a cecal bascule, emergency physicians will be more apt to make the diagnosis and intervene accordingly.

⁴ Distension of the cecum then occurs proximal to this outlet obstruction. If there is a competent ileocecal valve, there is no retrograde decompression of the cecum into the small bowel, and this leads to subsequent gaseous and fluid distension.⁴

Cecal volvulus most commonly occurs in young women during the postpartum period when the cecum is displaced upward by the uterus, or in elderly hospitalized patients secondary to reduced intestinal mobility.⁶ Chronic constipation, high fiber consumption, and prolonged immobilization are thought to be risk factors for this condition.^{7,8} The presence of adhesions, most commonly from previous abdominal surgery, can also contribute to the formation of points of fixation that can act as rotation axes.⁶

Even though there is no torsion of the mesentery in a cecal bascule, cecal distension can still cause venous and capillary constriction leading to ischemic changes that can progress to gangrene.⁹ Hence, early surgical decompression must be a priority in the management of these patients. Though of critical importance, there is no set standard on how decompression

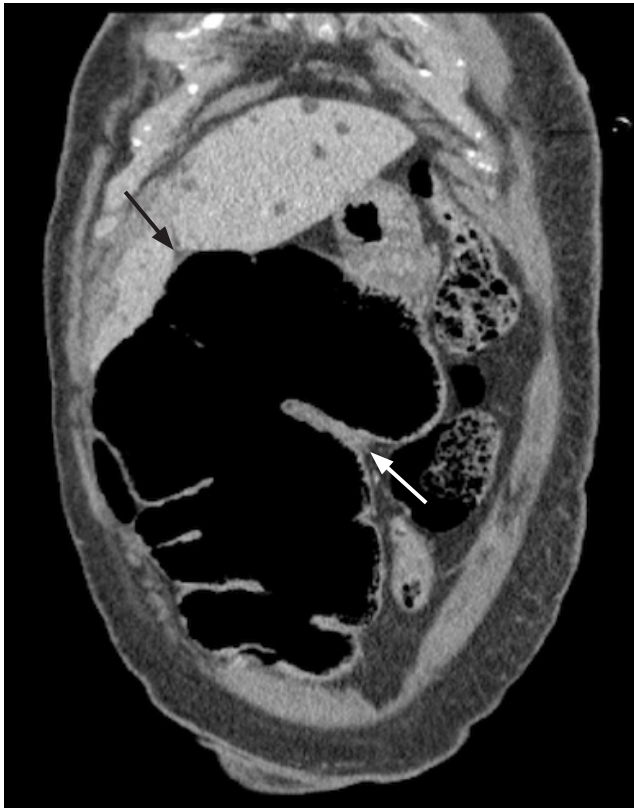

Image 2. Computed tomography coronal image demonstrating marked gaseous distension of the distal cecum, which is flipped cephalad extending into the mid to right upper quadrant (black arrow). Comma sign (white arrow) refers to comma-shaped thickening of the root of the sigmoid mesocolon.

is achieved. It can take numerous forms including colectomy, cecopexy, cecopexy supplemented by cecostomy, or cecectomy.¹⁰

Cecal bascule is a difficult condition to diagnose; thus, a high index of clinical suspicion must be maintained. Clinical manifestations include nausea, vomiting and continuous abdominal pain with exacerbation of pain during peristaltic movement.⁶ Unfortunately, there is no discussion in the literature concerning how long these exacerbations last or whether patients are ever completely symptom-free. On exam, these patients will have a distended tympanic abdomen.⁹ As vascular compromise progresses, these patients may begin to demonstrate signs of peritoneal irritation.¹¹

Laboratory results are neither sensitive nor specific, but practitioners typically find a leukocytosis and potentially hyperkalemia, azotemia or anemia in more severe cases.¹⁰ In our patient the lack of these findings likely portended to her having presented early in the disease course, and her hypokalemia and alkalosis resulted from her being relatively volume depleted -- not from vomiting as is the usual case, but from being unable to use her PEG-tube as it was causing her discomfort.

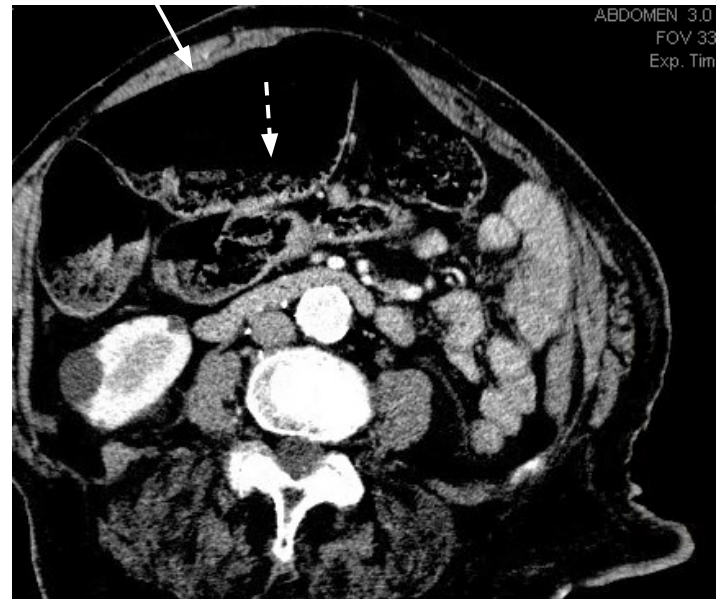


Image 3. Computed tomography axial image demonstrating gaseous distension of the cecum (solid white arrow) with visualized air-fluid levels within the bowel (dashed white arrow).

Abdominal radiography may illustrate air-fluid levels with dilation of small-bowel loops and a predominate distension of the cecum that is displaced anteromedial to the transverse colon.¹² Computed tomography (CT) is the preferred imaging technique to confirm a cecal bascule.⁹ Radiological signs on CT may include a coffee bean or comma sign seen on axial imaging.⁶ CT also enables visualization of the obstruction site, and the presence of wall thickening, mesenteric fat trabeculation, intestinal pneumatosis, or free fluid within the pelvis that can indicate imminent bowel ischemia.⁶

Diagnostic colonoscopy is not recommended as it may increase the risk of perforation.⁶ Right hemicolectomy with ileotransverse anastomosis is the preferred surgical technique as it carries the lowest risk of recurrence and a lower rate of morbidity and mortality when compared to detorsion alone, detorsion with cecopexy, and cecostomy.^{6,13} If anastomosis is not possible, an ileostomy should be performed.⁶

The purpose of this case report is to remind emergency physicians to expand their differential diagnosis to include the less-common causes of abdominal pain, such as cecal bascule, especially in postpartum women and the elderly. Cecal bascule is a rare cause of intestinal obstruction and is a uniquely challenging diagnosis due to the intermittent nature of its presentation. The periodic cephalad folding of the cecum allows variation in clinical signs and imaging findings depending on the positioning of the cecum at that specific point in time. Therefore, this diagnosis must remain on the differential of any patient reporting signs of intestinal obstruction even if not clinically evident at that moment.

CONCLUSION

Cecal bascule is a rare cause of bowel obstruction where there is anterior displacement of the cecum over the ascending colon. Making this diagnosis is especially difficult due to the relatively non-specific constellation of symptoms that may or may not include distension, abdominal pain, tenderness to palpation, nausea, vomiting, hyperperistalsis and absent bowel sounds. A high level of clinical suspicion and early surgical intervention are essential in preventing the devastating complications of bowel ischemia and gangrene.

Documented patient informed consent and/or Institutional Review Board approval has been obtained and filed for publication of this case report.

Address for Correspondence: Norah Kairys, MD, Temple University Hospital, Department of Emergency Medicine, 1229 South Street, Apartment C, Philadelphia, PA 19147. Email: norahkairys@gmail.com.

Conflicts of Interest: By the CPC-EM article submission agreement, all authors are required to disclose all affiliations, funding sources and financial or management relationships that could be perceived as potential sources of bias. The authors disclosed none.

Copyright: © 2018 Kairys et al. This is an open access article distributed in accordance with the terms of the Creative Commons Attribution (CC BY 4.0) License. See: <http://creativecommons.org/licenses/by/4.0/>

REFERENCES

1. Ramsingh J, Hodnett R, Coyle T, et al. Bascule caecal volvulus: A rare cause of intestinal obstruction. *J Surg Case Rep.* 2014;2014(4).
2. Habre J, Sautot-Vial N, Marcotte C, et al. Caecal volvulus. *Am J Surg.* 2008;196(5):e48-9.
3. Rabinovici R, Simansky DA, Kaplan O, et al. Cecal volvulus. *Dis Colon Rectum.* 1990;33(9):765-9.
4. Bobroff LM, Messinger NH, Subbarao K, et al. The cecal bascule. *Am J Roentgenol Radium Ther Nucl Med.* 1972;115(2):249-52.
5. Weinstein M. Volvulus of the cecum and ascending colon. *Ann Surg.* 1938;107(2):248-59.
6. Ruiz de la HA, Ortega-Domene P, Fuenmayor-Valera ML, et al. Caecal bascule, an unusual cause of intestinal obstruction. *Cirugia y Cirujanos (English Edition).* 2016;84(6):513-7.
7. Tejler G, Jiborn H. Volvulus of the cecum: report of 26 cases and review of the literature. *Dis Colon Rectum.* 1988;31(6):445-9.
8. O'Mara CS, Wilson TH Jr, Stonesifer GL, Stonesifer GL, et al. Cecal volvulus: analysis of 50 patients with long-term follow-up. *Ann Surg.* 1979;189(6):724-31.
9. Shah N, Patel H, Patel V, et al. Cecal bascule after colonoscopy- case report and review of literature. *NAJMS.* 2016;8(3):143-5.
10. Lung BE, Yelika SB, Murthy AS, et al. Cecal bascule: a systematic review of the literature. *Tech Coloproctol.* 2017.
11. Pousada L. Cecal bascule: An overlooked diagnosis in the elderly. *J Am Geriatr Soc.* 1992;40(1):65-7.
12. Fisher JK. Computed tomographic diagnosis of volvulus in intestinal malrotation. *Radiology.* 1981;140(1):145-6.
13. Weiss BD. Cecal volvulus: A diagnostic and therapeutic challenge. *Postgrad Med.* 1982;72(2):189-94.

Ultrasound-guided Placement of a Foley Catheter Using a Hydrophilic Guide Wire

Ryan Joseph, DO
Mark Huber, MD
Ben Leeson, MD
Kimberly Leeson, MD

Texas A&M University, Department of Emergency Medicine, Corpus Christi, Texas

Section Editor: Rick A. McPheeters, DO

Submission history: Submitted November 14, 2017; Revision received December 13, 2017; Accepted December 20, 2017

Electronically published March 14, 2018

Full text available through open access at http://escholarship.org/uc/uciem_cpsem

DOI: 10.5811/cpsem.2017.12.37045

Acute urinary retention is a common problem in the emergency department. Patients can present in significant distress, necessitating the placement of a urinary catheter. Foley catheter placement can be difficult to accomplish depending on the etiology of the retention and the degree of the obstruction. In the case presented here, we used ultrasound guidance, a guidewire, and a Foley catheter to successfully relieve a patient's urinary retention after multiple failed attempts. [Clin Pract Cases Emerg Med.2018;2(2):143-146.]

INTRODUCTION

There are many causes of acute urinary retention including medications, neurologic disorders, and bladder outlet obstruction. We will focus here on mechanical, or anatomic, bladder outlet obstruction, which in and of itself has many different etiologies, including, meatal stenosis, urethral stricture, bladder neck stricture, and benign prostatic hypertrophy.¹ Typically, obstructive symptoms include hesitancy, a sensation of incomplete bladder emptying, diminished urinary stream, and post-void urinary dribbling.² The treatment of choice for bladder outlet obstruction is urethral catheterization, and this has traditionally been accomplished using a 16 or 18 French Foley catheter.³ If this fails, the next step would be to use a 16 French coude tip catheter, or Tiemann catheter. This is a semi-rigid catheter with a curved tip to help facilitate passage through the bladder neck in the presence of obstruction from an enlarged prostate gland.⁴ In a 2011 American Urologic Association update, Villaneuva and Hemstreet stated that after two failed attempts using the aforementioned techniques they would consider using a hydrophilic guidewire to facilitate catheterization.³

In the case presented here we used ultrasound (US) to guide the placement of a hydrophilic guidewire into the bladder and subsequently guide the catheter over the guidewire and into the bladder. We ultimately confirmed the placement of the catheter using US. To the best of our

knowledge, there have been no previous studies or case reports in the emergency medicine (EM) literature related to the use of a guidewire for the placement of a transurethral catheter under US guidance.

CASE REPORT

An 82-year-old male with a history of benign prostatic hypertrophy (BPH) and urinary retention with prior placement of a suprapubic catheter presented with a chief complaint of worsening abdominal pain and distension. The previous suprapubic catheter had been removed by an outside facility five days prior to presentation. On arrival to the emergency department (ED) he was complaining of 7/10 lower abdominal pain and the inability to urinate. The rest of the review of systems was negative and the only pertinent past medical or surgical history was BPH. He denied any substance abuse and denied taking any medications besides anti-hypertensives. On exam, the patient appeared very uncomfortable, had a mildly distended bladder, and significant suprapubic tenderness with no rebound or guarding. A bladder scan was performed at bedside, which revealed 560 milliliters of urine. After a failed attempt to place a 14 French Foley catheter the nurse attempted to catheterize the patient with a coude tip catheter. This procedure was also unsuccessful and the patient reported increased pain and discomfort.

We chose to place a 16 French Foley catheter over a guidewire using the Blitz technique (Image 1).⁵ A portable US machine, the SonoSite X-Porte with the curvilinear probe (model C60xp with a bandwidth of 5-2MHz) was used during the placement of a guidewire, the ZIPwire™ Hydrophilic Guidewire (Boston Scientific) through the urethra into the bladder with real-time direct visualization. After confirmation of the guidewire in the bladder on US (Image 2), we advanced the catheter over the guidewire, using the Seldinger technique. Using US again, we watched the Foley catheter enter the bladder (Image 3) and the balloon inflate in the appropriate location. The guidewire was removed and 700 milliliters of clear yellow urine was obtained in the collection bag. The patient’s discomfort resolved and he was discharged to home with the catheter in place and a urology appointment for follow-up.

DISCUSSION

As emergency physicians (EP) we commonly encounter urinary retention. In two large cohort studies of men in the United States age 40 to 83 years old, the overall incidence was 4.5 to 6.8 per 1,000 men per year. The incidence dramatically increases with age so that a man in his seventies has a 10% chance and a man in his eighties has a more than 30% chance of having an episode of acute urinary retention.^{6,7} The treatment of urinary retention is transurethral catheterization. Current EM teaching does not offer much guidance for managing difficult catheterizations, and urology consultation is recommended when a

CPC-EM CAPSULE

What do we already know about this clinical entity?
Urologists have been using hydrophilic guidewires in cases of difficult catheter placement for many years. These tools are not commonly used by emergency physicians (EP).

What makes this presentation of disease reportable?
Difficult urinary catheterization is a common occurrence in the emergency department. Hydrophilic guidewire use with ultrasound confirmation has not been reported.

What is the major learning point?
By using a guidewire and point-of-care ultrasound, the EP can safely place a Foley catheter in cases of difficult urinary catheterization.

How might this improve emergency medicine practice?
Urinary retention is common and it is important for EPs to have various tools at their disposal to achieve successful catheterization.

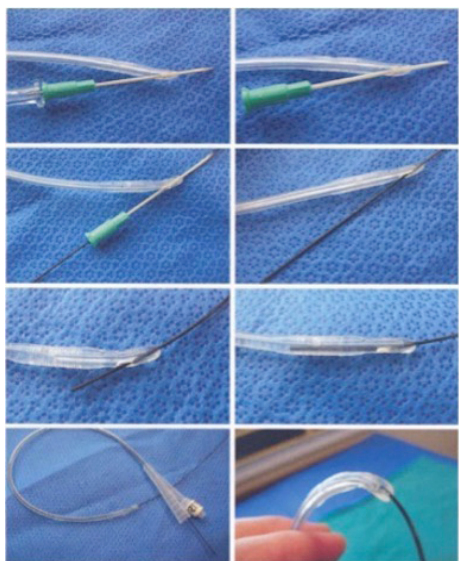


Image 1. Blitz technique.⁷ Using an 18 gauge angiocatheter, puncture a small hole at the tip of the urinary catheter. Then thread the guidewire through the side hole that was already present on the catheter and the hole that was just created at the tip of the urinary catheter. (Used kindly with permission from Dr. Villanueva.)

transurethral catheter does not provide adequate bladder drainage. Knowledge of this topic remains sparse in both EM and nursing specialties, and recommendations are seldom supported by evidence-based research.⁸

Urinary catheterization may be associated with complications such as traumatic insertion, creation of false tracts, urethral trauma, clogging of the catheter, and accidental or intentional

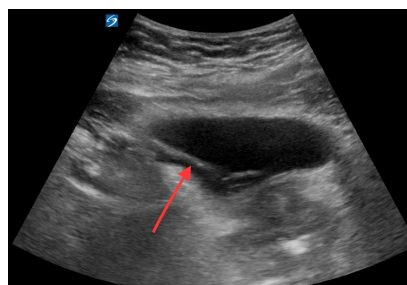


Image 2. A transabdominal ultrasound image of the urinary bladder in transverse view demonstrating a hyperechoic line (red arrow) representing the guidewire entering the bladder.

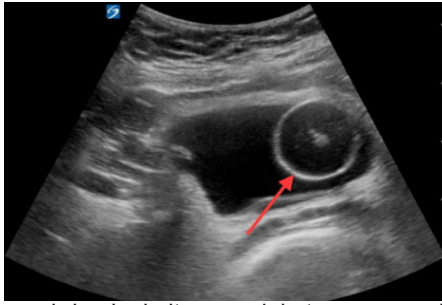


Image 3. Transabdominal ultrasound, in transverse, demonstrating a Foley catheter with balloon inflated (red arrow) in the right side of the urinary bladder

removal of a urinary catheter with the balloon inflated.³ The most common injury sites are the posterior and bulbous urethra, and the most frequently reported injuries are false passages created by forceful catheterization, as well as mucosal and submucosal tissue tears caused by balloon inflation in an improper position in the urethra.^{3,9} These complications may ensue even in consultation with experienced urologists. No matter what the cause, urinary catheterization is an inherently uncomfortable procedure. Multiple attempts can result in significant patient distress, as well as bleeding, urethral trauma and increased healthcare costs to both the patient and the hospital.

Chavez et al. performed a retrospective chart review from 1998 to 2007, which looked at the costs of a traumatic urethral catheterization. The authors found that of 221,045 patients who underwent urethral catheterization, 3,101 (1.4%) were traumatic. The incidences of urinary tract infection, cystitis and septicemia two weeks after catheter induced urethral injury were 12.72%, 3.45% and 1.9% with estimated costs of \$11,052, \$482 and \$48,935, respectively.¹⁰

The description of guidewire use during catheterization was first published in 1989 by SJ Krikler, yet urologists had been using this technique for years.¹¹ The first attempts were performed using cystoscopy to insert the guidewire.¹² Since then, urologists have been using hydrophilic guidewires without the assistance of a cystoscope to place catheters in situations where other attempts were unsuccessful or resulted in trauma.^{3, 13-16} The technique is performed by blindly inserting the guidewire approximately half of the total length of the guidewire (150 centimeters). The Foley catheter is prepared using the Blitz technique (Image 1). Using this technique, the clinician punctures a hole at the tip of the Foley catheter using an 18-gauge needle. He then threads the Foley catheter over the guidewire using the hole created at the tip. The Foley catheter can then be advanced over the guidewire until it reaches the bladder. The guidewire can then be removed; urine returned from the catheter confirms proper position.¹³

Freid et al. examined the safety and efficacy of this blind introduction of a guidewire into the bladder and reported success in 19 of 20 attempts and no complications associated

with the procedure.¹⁶ One of the major disadvantages and potential complications of attempting to introduce a guidewire into the bladder is the potential for misplacement.³ This can potentially be alleviated by confirming placement of the guidewire into the bladder using US guidance. A hydrophilic guidewire ranges in diameter from 0.018 to 0.038 inches in diameter with a soft, flexible tip that ranges from 3-15 centimeters in length. The total length of the guidewire is usually 150 centimeters. The shaft of the wire is rigid and constructed in two layers, an inner core and an outer coating made up of a hydrophilic polymer, most commonly polytetrafluoroethylene. The hydrophilic coating provides the low-friction characteristics necessary to navigate strictures or a hypertrophied prostate gland.

A number of EPs use point-of-care ultrasound to guide or confirm correct placement of a urinary catheter,¹⁷ but performing the Blitz technique under US guidance has not been described in the EM literature. This is a useful technique for any EP to have in his repertoire and will most certainly decrease delays in catheter placement, traumatic catheter insertions, urethral trauma, and late-night consults to the urologist for patients presenting to the ED with urinary retention.

CONCLUSION

Physicians should be aware of the risks and common pitfalls associated with transurethral catheterization. They should also be familiar with the procedure described above in which we were able to successfully place a Foley catheter using ultrasound for guidewire placement in a patient with multiple previous failed attempts. By using this technique we hope that EPs can successfully place a difficult Foley catheter, thus avoiding a consult to the urologist for placement.

Documented patient informed consent and/or Institutional Review Board approval has been obtained and filed for publication of this case report.

Address for Correspondence: Ryan Joseph, DO, Texas A&M University, Department of Emergency Medicine, 600 Elizabeth St. 9B, Corpus Christi, TX 78404. Email: Rjosep4@gmail.com. Twitter: @docjoseph08.

Conflicts of Interest: By the CPC-EM article submission agreement, all authors are required to disclose all affiliations, funding sources and financial or management relationships that could be perceived as potential sources of bias. The authors disclosed none.

Copyright: © 2018 Joseph et al. This is an open access article distributed in accordance with the terms of the Creative Commons Attribution (CC BY 4.0) License. See: <http://creativecommons.org/licenses/by/4.0/>

REFERENCES

1. Tintinalli J, Kelen GD, Stapczynski S. *Emergency Medicine: A Comprehensive Study Guide*. 6th ed. 2004:619-20.
2. Dmochowski RR. Bladder Outlet Obstruction: etiology and evaluation. *Rev Urology*. 2005;7(Supp 6):S3-S13.
3. Villanueva C, Hemstreet G. Difficult catheterization: tricks of the trade. *AUA Update Series*. 2011;30:41-8.
4. Designs-indwelling catheters. *Uro Today*. 2013. Available at: <https://www.urotoday.com/urinary-catheters-home/indwelling-catheters/description/designs.html>. March 17, 2017.
5. Blitz BF. A simple method using hydrophilic guide wires for the difficult urethral catheterization. *Urology*. 1995;46(1):99-100.
6. Meigs JB, Barry MJ, Giovannucci E, et al. Incidence rates and risk factors for acute urinary retention: the health professionals followup study. *J Urol*. 1999;162(2):376-82.
7. Jacobsen SJ, Jacobson DJ, Girman CJ, et al. Natural history of prostatism: risk factors for acute urinary retention. *J Urol*. 1997;158(2):481-7.
8. Willette PA, Coffield S. Current trends in the management of difficult urinary catheterizations. *West J Emerg Med*. 2012;13(6):472-8.
9. Daneshgari F, Krugman M, Bahn A, et al. Evidence-based multidisciplinary practice: improving the safety and standards of male bladder catheterization. *Medsurg Nurs*. 2002;11(5):236-41, 46.
10. Chavez A, Rajab M, Kuykendall S et al: Incidence of Foley catheter-related urethral injury in a tertiary referral center. Presented at AUA SCS meeting, Scottsdale, Arizona, October 14-17, 2009.
11. Krikler SJ. Flexible urethroscopy: use in difficult male catheterisation. *Ann R Coll Surg Engl*. 1989;71(1):3.
12. Beagler M, Grasso M 3rd, Loisesides P. Inability to pass a urethral catheter: the bedside role of the flexible cystoscope. *Urology*. 1994;44(2):268-70.
13. Zammit PA, German K. The difficult urethral catheterization: use of a hydrophilic guidewire. *BJU Int*. 2004;93(6):883-4.
14. Jeong SH, Park SJ, Kim YH. Efficacy of urethral catheterisation with a hydrophilic guidewire in patients with urethral trauma for treating acute urinary bladder retention after failed attempt at blind catheterisation. *Euro Radiol*. 2012;22(4):758-64.
15. Ghaffary C, Yohannes A, Villanueva C, et al. A practical approach to difficult urinary catheterizations. *Curr Urol Rep*. 2013;14(6):565-79.
16. Freid RM, Smith AD. The Glidewire Technique for Overcoming Urethral Obstruction. *J Urol*. 1996;156(1):164-5.
17. Kameda T, Murata Y, Fujita M, et al. Transabdominal ultrasound-guided urethral catheterization with transrectal pressure. *J Emerg Med*. 2014;46(2):215-9.

Scurvy: Dietary Discretion in a Developed Country

Megan E. Perry*
Nathan Page, MD†
David E. Manthey, MD†
Joshua M. Zavitz, DO†

*Wake Forest School of Medicine, Winston-Salem, North Carolina
†Wake Forest School of Medicine, Department of Emergency Medicine, Winston-Salem, North Carolina

Section Editor: Manish Amin, DO

Submission history: Submitted October 23, 2017; Revision received January 3, 2018; Accepted January 19, 2018

Electronically published March 14, 2018

Full text available through open access at http://escholarship.org/uc/uciem_cpccem

DOI: 10.5811/cpcem.2018.1.36860

Although the causes have changed, scurvy (vitamin C deficiency) is still diagnosed in developed countries. We report a case of an 18-year-old female who presented to our emergency department with thrombocytopenia, sinus tachycardia, hypotension, fatigue, gingival hyperplasia, knee effusion, petechiae and ecchymosis in lower extremities. The differential diagnosis included hematologic abnormalities, infectious etiologies, vasculitis and vitamin deficiency. A brief dietary history was performed revealing poor fruit and vegetable intake, thus increasing our suspicion for vitamin C deficiency. This experience illustrates the importance of a dietary history and reminds us to keep scurvy in the differential diagnosis. [Clin Pract Cases Emerg Med. 2018;2(2):147-150.]

INTRODUCTION

Vitamin C deficiency, commonly known as scurvy, was originally a disease of sailors, related to extended periods of time on a ship with no access to fresh fruit or vegetables.¹ Dr. Lind of the Royal Navy in 1747 identified citrus fruit as a treatment for scurvy. It is also documented historically during times of famine, where those same sources of vitamin C were inaccessible to the population.² Although the presentation remains the same, the risk factors of developing scurvy today have changed. The rare cases seen in the present day are often observed in populations that frequent the emergency department (ED) and include those with poor nutritional intake related to mental illness, alcohol abuse, isolation and extremely restricted diets.² If untreated, scurvy, although easily remedied, can be fatal. Thus, a dietary history is necessary to identify those at risk for vitamin C deficiency for timely diagnosis.

This case describes a young female who presented to the ED with fatigue, dyspnea, gingival bleeding, scattered ecchymoses, knee swelling and petechiae. A dietary history revealed a limited intake of only specific foods raising a concern for vitamin deficiency. Other diagnostic considerations included coagulopathies, immune-mediated disorders, trauma, vasculitis, liver disease and malignancy. The clinical picture along with a low ascorbic acid (vitamin C) level confirmed the diagnosis of scurvy. This case highlights the importance of a

wide differential and a dietary history, which can lead to quick resolution of a potentially fatal disease.

CASE REPORT

An 18-year-old woman presented to the ED as instructed by her primary care physician for a laboratory abnormality of low platelets with specific concern for idiopathic thrombocytopenic purpura. One month prior to presentation to the ED, the patient noted some shortness of breath on exertion. Three weeks prior to presentation, she developed a rash on her legs, along with bruising, and right knee swelling that made it difficult to ambulate. She also endorsed increased fatigue, weakness, and bleeding from her gingiva. She had been seen several times previously by her primary care physician, but a diagnosis had not yet been discovered. The patient denied any recent trauma, fevers, weight or appetite changes, chest pain, cough, nausea, abdominal pain, constipation, diarrhea, bloody stools, hematuria, or menorrhagia.

Her past medical history was significant for anxiety, depression, asthma and anorexia nervosa (since resolved) and specifically negative for coagulopathies. Her only medications included escitalopram and albuterol inhaler. Family history was noncontributory and specifically negative for coagulopathies, autoimmune disorders and leukemia. Social history was significant for a specific diet consisting of only peanut butter

crackers, strawberry Nutri-Grain bars, and fish sticks. She denied tobacco, alcohol or illicit drug use.

On physical examination, the patient was afebrile, hypotensive to 86/58 mmHg, tachycardic to 112 beats per minute, with a respiratory rate of 15 breaths per minute and an oxygen saturation of 100% on room air. She was pale and thin appearing, in no acute distress. Oral examination was significant for a region of gingival hyperplasia along the left upper gingival line (Image 1), and petechiae beneath the tongue. Cardiovascular exam was significant for a tachycardic rate, but regular rhythm, 2+ peripheral pulses and normal capillary refill. Pulmonary and abdominal exams were within normal limits. Skin exam demonstrated petechiae on the bilateral lower extremities along with scattered ecchymoses (Image 2). The right knee was also swollen and ecchymotic (Image 3) with tenderness along the joint line and decreased range of motion secondary to pain. The remainder of the physical exam was within normal limits.

ED laboratory results were significant for hemoglobin of 10.5 g/dL, a platelet count of 146 x 10³/dL, iron of 32 mcg/dL, C-reactive protein of 34.2 mg/L and negative urine pregnancy test. The remainder of the laboratory studies including complete blood count, coagulation studies, complete metabolic profile, iron profile, urine drug screen, hepatitis panel, and iron profile were all within normal limits. Chest and right knee radiographs were also within normal limits. An arthrocentesis of the right knee joint revealed 600,000 red blood cells and 378 white blood cells. It was negative for crystals and organisms. The patient was admitted to the medicine service for further evaluation with a presumed diagnosis of vitamin C deficiency.

While she was inpatient, laboratory studies demonstrated hematuria, new and worsening anemia and leukopenia, and persistent thrombocytopenia. Anti-nuclear antibody, direct antiglobulin profile, copper and vitamin D were all within normal limits. An ascorbic acid level was <0.1 mg/dL (normal 0.2-1.5 mg/dL). Dermatology believed the patient's presentation to be consistent with vitamin C deficiency; however, she declined confirmatory biopsy of petechial lesions. The patient received vitamin C supplementation. After improvement of all laboratory values, she was discharged home to continue vitamin C and iron supplementation outpatient. Follow-up with the hematologist demonstrated vitamin C compliance and resolution of all symptoms.

DISCUSSION

This non-ill appearing patient presented with tachycardia and borderline low blood pressure, fatigue, petechiae and scattered ecchymosis in lower extremities, gingival hyperplasia, and right knee effusion. The differential included the broad categories of hematologic abnormalities, vitamin deficiencies, trauma, vasculitis, liver disease, infection and malignancy.

Hematologic abnormalities included idiopathic thrombocytopenic purpura, thrombotic thrombocytopenic purpura, hemolytic uremic syndrome, disseminated intravascular

CPC-EM Capsule

What do we already know about this entity?
Scurvy is a disease of vitamin C deficiency secondary to poor nutritional intake causing anemia, fatigue, spontaneous bleeding, joint swelling, and gingival ulceration.

What makes this presentation of disease reportable?
This case was a rare presentation of scurvy in a young female presenting with petechia, purpura and a joint effusion to an emergency department in a developed country.

What is the major learning point?
Scurvy has significant morbidity and is still diagnosed in developed countries today, usually among patients with poor nutrition such as alcoholics, homeless, and those on fad diets.

How might this improve emergency medicine practice?
This reminds emergency providers of the importance of dietary history and to keep scurvy in the differential diagnosis.

coagulation, hemophilia (A, B, C), and drug-induced thrombocytopenia. Vitamin deficiencies included vitamin K, zinc, and vitamin C (scurvy). Infectious causes included meningococemia, Rocky Mountain spotted fever, and septic arthritis. Vasculitis causes included leukocytoclastic vasculitis and Henoch-Schonlein purpura. Idiopathic thrombocytopenic purpura, the original diagnosis of the referring physician, is a disease process of antiplatelet antibodies in which the patient does not appear ill. Although the patient has a decrease in his/her platelet count, all other hematologic parameters are normal. The presentation is one of easy and/or excessive bruising (purpura), petechiae (usually on the lower legs), bleeding from gingiva, blood in urine, and unusually heavy menstrual flow.

Thrombotic thrombocytopenic purpura is caused by clotting in small blood vessels due to endothelial defect. The disease presents with any variation on the pentad of microangiopathic hemolytic anemia, thrombocytopenic purpura, fever, neurologic abnormalities, and renal disease in an ill-appearing patient. The laboratory data should show anemia with schistocytes, mild increase in fibrin degradation products and possible increase in prothrombin time (PT) and partial thromboplastin time (PTT).

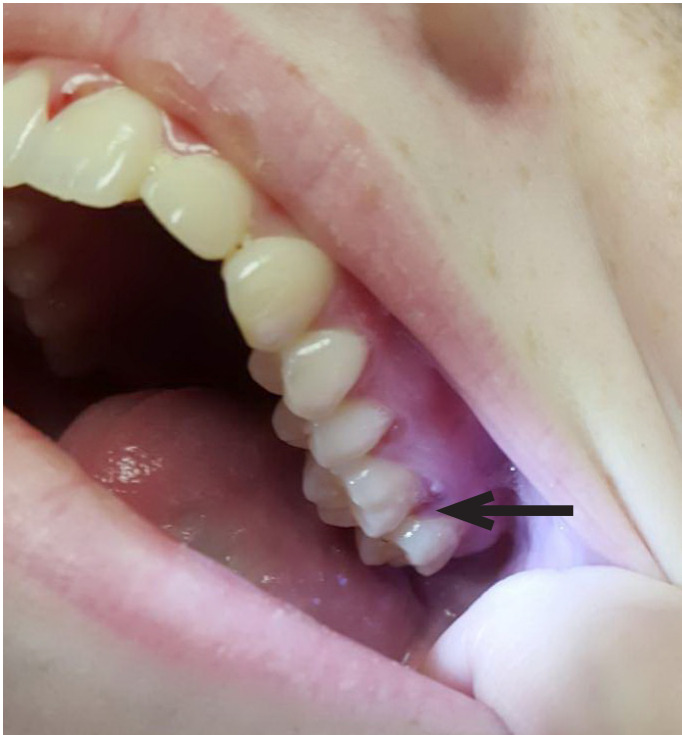

Image 1. Gingival hyperplasia, most prominent in the patient's left upper gum line (arrow), is a typical sign of scurvy.

Disseminated intravascular coagulation (DIC) is a diverse entity due to thrombin excess caused by systemic activation of blood coagulation that presents with clotting disorders. Accelerated fibrinolysis due to the clot formation may also actually cause severe bleeding. The patient will present ill appearing, most commonly from the underlying disorder that triggered the DIC. DIC will cause thrombosis, embolism, organ dysfunction (due to clotting) and bleeding. This severe consumptive coagulopathy will present with anemia, thrombocytopenia, elevated fibrin degradation factors, and elevated PT/PTT.

Leukemia can present in a multitude of ways, depending on the type of leukemia, but common symptoms include fatigue, loss of weight, swollen lymph nodes, easy bruising/bruising, petechiae, and bone pain. Hemophilia presents as bruising, excessive bleeding after cuts, pain and swelling in joints, blood in stool. This would be unusual as the patient was female, had no prior bleeding issues, and had no family history. Women with hemophilia are most commonly asymptomatic simple carriers. Hemophilia C occurs in both sexes, with mild symptoms, caused by insufficient clotting factor XI. Vasculitis (microangiopathic, leukocytoclastic, drug induced) often presents with fatigue, fever, arthralgias and weight loss. The patient may present with sensory or motor deficits, vascular abnormalities, palpable purpura or petechiae. The diagnosis is based on a combination of involved organ systems, the size of

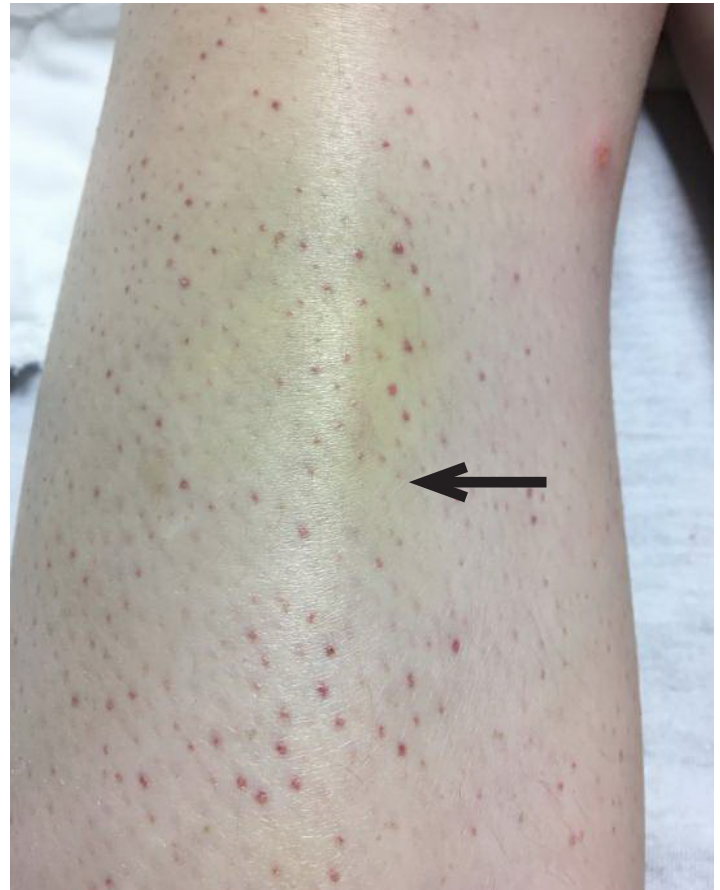


Image 2. Petechiae, which classically circumscribe the hair follicles, and healing ecchymosis noted on the patient's bilateral lower extremities (arrow).

vessels affected, and characteristics of testing results.

Scurvy (vitamin C deficiency) presents with anemia, fatigue, spontaneous bleeding (bruising and petechiae), joint swelling (hemarthrosis), ulceration of the gingiva with gingival hyperplasia, and eventual loss of teeth. Modern cases of vitamin C deficiency are rare but usually found in alcoholic patients, isolated elderly patients, malabsorption syndromes, and people who voluntarily restrict their type of food intake. In addition to poor nutritional intake, alcoholic patients develop vitamin C deficiency secondary to increased excretion of vitamin C in the urine.³ The recommended daily allowance of vitamin C is 60 mg/day. Scurvy develops in approximately four weeks in those who consume less than 10 mg/day. Daily requirements increase for patients who are pregnant (70 mg/day) and during lactation (90-95 mg/day), or patients who smoke, are on hemodialysis, or have trauma/infection.²

We rely on exogenous vitamin C from various foods in our diet, such as fresh fruits and vegetables (oranges, lemons, limes, potatoes, broccoli, spinach, red peppers, etc.). Fresh meat contains vitamin C; however, it is destroyed when the meat is cooked.⁴ Vitamin C is a vital required cofactor for

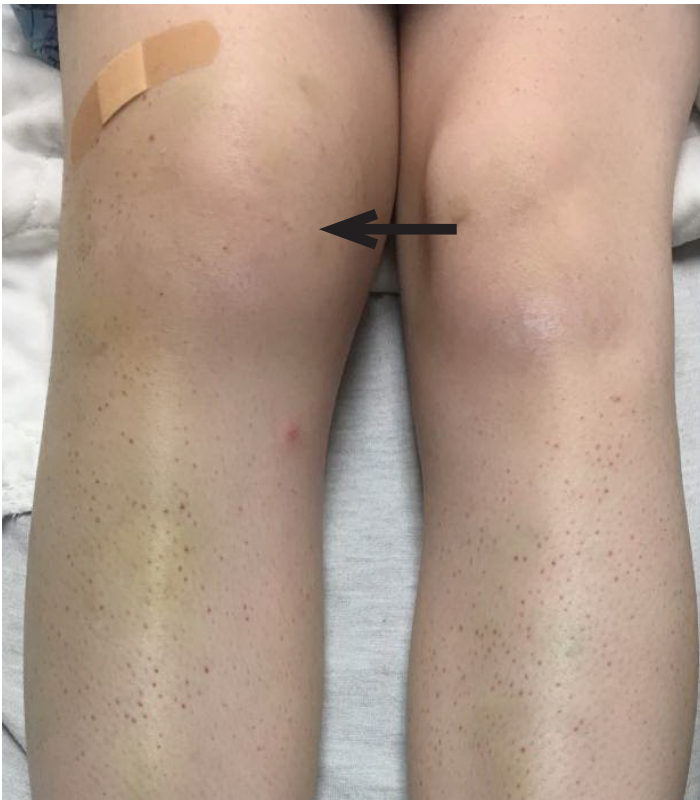


Image 3. Joint effusion noted in the right knee (arrow), which when explored by arthrocentesis was revealed to be a hemarthrosis.

collagen biosynthesis and plays an important role in carnitine biosynthesis, production of noradrenaline, metabolism of cholesterol, iron absorption, antioxidant activity, corticosteroid synthesis, and various drug-metabolizing systems. Most symptoms of vitamin C deficiency can be attributed to impaired formation of mature connective tissue, such as bleeding in the skin (ecchymosis, perifollicular hemorrhages, petechiae), joints, pericardium, adrenal glands, and peritoneal cavity, as well as inflamed and bleeding gingiva.⁵ In children, bone growth is impaired with a deficiency of vitamin C and can be associated with bleeding into the periosteum and sub-periosteum.⁶

Scurvy progresses in four stages. The first stage is characterized by muscle pain and fatigue. The second stage shows gingival swelling with associated easy bleeding. The third stage reveals ulcerative gingivitis, non-palpable purpura and petechiae, and ulcers. The fourth stage is identified by multiple organ failure.² The treatment of vitamin C deficiency is simply supplementation of vitamin C. While a standardized treatment protocol is not established, multiple sources recommend one g/day of vitamin C for the first two to three days followed by 500 mg/d for the next week.^{2,7} It is then suggested that 100 mg/d should be taken for one to three months. Systemic symptoms (fatigue, pain, anorexia, confusion) should improve within 24 hours of treatment. Bleeding and associated collagen defects (ecchymosis, petechiae, gingival bleeding and hyperplasia,

perifollicular hemorrhage) should begin improving within one to two weeks. One should anticipate approximately three months until complete recovery with regular vitamin C supplementation.⁷

CONCLUSION

Scurvy is often taught as a historical disease and is rare in modern society. In this case, a primary care physician had left it off the differential diagnosis. Presentation of patients with petechiae and purpura is not uncommon in the emergency department and we need to keep scurvy on the differential. This case also highlights the importance of taking detailed histories (in this case of diet) to help increase or decrease the likelihood of a disease.

Documented patient informed consent and/or Institutional Review Board approval has been obtained and filed for publication of this case report.

Address for Correspondence: Joshua M. Zavitz, MD, Wake Forest School of Medicine, Department of Emergency Medicine, 1 Medical Center Blvd., Winston-Salem, NC 27157. Email: jzavitz@wakehealth.edu.

Conflicts of Interest: By the CPC-EM article submission agreement, all authors are required to disclose all affiliations, funding sources and financial or management relationships that could be perceived as potential sources of bias. The authors disclosed none.

Copyright: © 2018 Perry et al. This is an open access article distributed in accordance with the terms of the Creative Commons Attribution (CC BY 4.0) License. See: <http://creativecommons.org/licenses/by/4.0/>.

REFERENCES

1. Velandia B, Centor RM, McConnell V, et al. Scurvy is still present in developed countries. *J Gen Intern Med.* 2008;23(8):1281-4.
2. Pimental L. Scurvy: Historical review and current diagnostic approach. *Am J Emerg Med.* 2003;21(4):328-32.
3. Faizallah R, Morris AI, Krasner N, et al. Alcohol enhances vitamin C excretion in the urine. *Alcohol.* 1986;21(1):81-4.
4. Allgaier RL, Vallabh K, Lahri S. Scurvy: A difficult diagnosis with a simple cure. *Af J Emerg Med.* 2012;2:20-3.
5. Russell RM, Suter PM. Vitamin and trace mineral deficiency and excess. In: Kasper D, Fauci A, Hauser S, et al. *Harrison's Principles of Internal Medicine, 19e.* New York, NY: McGraw-Hill; 2014.
6. Hafez D, Saint S, Griauzde J, et al. Clinical problem-solving. A deficient diagnosis. *N Engl J Med.* 2016;374(14):1369-74.
7. Léger D. Scurvy: Reemergence of nutritional deficiencies. *Can Fam Physician.* 2008;54(10):1403-6.

Spontaneous Spinal Epidural Hematoma from Rivaroxaban

Charlotte Goldfine, MD
Catherine Glazer, MD
Richard M. Ratzan, MD

University of Connecticut School of Medicine, Hartford Hospital, Department of Emergency Medicine, Hartford, Connecticut

Section Editor: Rick A. McPheeters, DO

Submission history: Submitted November 20, 2017; Revision received February 21, 2018; Accepted February 27, 2018

Electronically published April 5, 2018

Full text available through open access at http://escholarship.org/uc/uciem_cpccm

DOI: 10.5811/cpcem.2018.2.37096

Spontaneous spinal epidural hematoma (SSEH) is a rare diagnosis. One known risk factor is anti-coagulation medication. We present a case of SSEH in a 74-year-old male on rivaroxaban therapy who clinically presented with an intermittently resolving and then worsening neurological exam. Due to the extremely high morbidity and mortality associated with this diagnosis, it is important to be aware of the various presentations and adverse effects related to novel anticoagulation. [Clin Pract Cases Emerg Med.2018;2(2):151-154.]

INTRODUCTION

Spinal epidural hematomas are a rare event. The estimated incidence is 0.1 per 100,000 per year with a frequency accounting for less than 1% of spinal epidural space-occupying lesions.¹ Spinal epidural hematomas are classified based on their etiology, with trauma being the most common cause.² Other etiologies that have been described include invasive spinal procedures such as lumbar puncture and myelography, arteriovenous malformations, bleeding disorders, pregnancy, and spinal manipulation.^{3,4}

Even more rarely, spinal epidural hematomas can occur spontaneously. Cases have been reported with coughing, stretching, and even playing the trombone.^{4,6} In most cases (40-60%) the cause is idiopathic, with no clear inciting factor or underlying etiology.⁷ When a cause can be found it tends to be related to a minimal amount of trauma or physical effort that would not be expected to cause significant bleeding.⁸ Most cases occur in the fourth or fifth decade of life.⁹ There have also been reports of spontaneous spinal epidural hematomas (SSEH) occurring in pediatric patients in whom the disease can be more difficult to diagnose and more neurologically devastating.¹⁰

There is no clear consensus on whether the pathophysiology of the hemorrhage is arterial or venous.¹¹ Several risk factors leading to SSEH have been identified.¹² One of the leading risk factors is the use of anticoagulation medications, second only to idiopathic causes.¹³ The most commonly associated anticoagulant medication resulting in SSEH is warfarin.¹³ There have only been four previously documented cases of SSEH on Xa inhibitors.¹⁴⁻¹⁷

Spinal epidural hematomas typically present clinically as a cord compression syndrome. The most common presenting complaint is the acute onset of neck or back pain with associated neurological deficit such as weakness of the extremities.^{3, 18} The symptoms vary depending on the location of the hematoma, resulting in a variety of presentations.³ There have been reports of SSEH mimicking stroke and acute coronary syndrome.^{1,19} In most cases, the symptoms persist until the hematoma is surgically evacuated, although spontaneous resolution – completely or partially - is not rare.²⁰ In our patient the neurological symptoms transiently improved and then worsened again throughout his course. The best imaging modality to appropriately identify SSEH is magnetic resonance imaging (MRI). If not appropriately diagnosed and treated, the cord compression can lead to permanent disability such as persistent weakness and even paraplegia. Early treatment is associated with improved outcomes, and therefore it is an important syndrome to recognize in emergency medicine.¹⁹

CASE REPORT

A 74-year-old man on rivaroxaban for paroxysmal atrial fibrillation presented with the gradual onset of neck pain. The pain started while he was walking in the woods and was associated with progressive weakness and numbness from the clavicles downward. He was able to walk back to his cabin, but upon arrival he was unable to maintain his balance and fell forward striking his head. He denied any loss of consciousness. He was unable to move for about 45 minutes. Emergency

medical services was called and they noted the patient to be completely paralyzed with fecal incontinence. He also had shortness of breath. During his transport to the emergency department (ED) he started to regain strength and feeling in his arms and legs and improvement of his shortness of breath. He denied any recent fevers, upper respiratory infection, rash or tick bites. All other review of systems was negative. Past medical history was significant for hypertension, atrial fibrillation, and coronary artery disease.

On initial examination, the patient was alert and oriented to person, place, and time. Temperature was 92.0 degrees Fahrenheit tympanic, pulse 56 beats per minute, respiratory rate 20 breaths per minute, blood pressure 122/56 mmHg, oxygen saturation 100% on four liters nasal cannula. Lungs were clear to auscultation bilaterally without wheezes, rhonchi, or rales. Heart was regular rate and rhythm, without any murmurs. Abdomen was soft, non-tender, non-distended with normal bowel sounds. Back had no evidence of trauma or deformity, non-tender to palpation. On extremity exam he had 4/5 strength in all extremities. After 20 minutes in the ED, he developed flaccid paralysis of all extremities with 0/5 strength. His voice also became softer and he developed shortness of breath. After five minutes he was able to wiggle his left toes. Over the next hour he slowly regained strength in his right lower extremity and his voice returned to normal. After another 40 minutes the patient was able to move his right upper and lower extremity and wiggle his toes on his left lower extremity. He was still unable to move his left upper extremity.

A computed tomography angiography (CTA) of the chest, abdomen, and pelvis was performed and did not show any evidence of aortic dissection. MRI of the cervical spine showed a prominent epidural hematoma, primarily dorsal, that extended from the foramen magnum down to cervical vertebra C7 and contributed to severe mass effect on the thecal sac (Image). Findings were the worst at C2-C3, where the hematoma measured 7-8 mm in width with compression of the cervical spinal cord and associated cord signal abnormality. In retrospect, findings were also visible on the preceding CTA. Patient was taken emergently to surgery for evacuation of the hematoma.

DISCUSSION

There have only been four other cases of SSEH formation while on rivaroxaban¹⁴⁻¹⁷ with an additional two cases of SSEH formation.^{21, 22} Rivaroxaban is an oral anticoagulant medication that works as a direct factor Xa inhibitor.²³ Oral anticoagulation medications are increasingly being used for stroke prevention in non-valvular atrial fibrillation and deep vein thrombosis, as they overcome some of the difficulties when using the older standard medications that are more complex to administer or require closer monitoring.²³ There is no specific antidote for rivaroxaban; therefore, nonspecific reversal agents such as fresh frozen plasma or a four-factor prothrombin complex concentrate are used in severe, life-threatening cases where reversal is necessary.^{24, 25}

CPC-EM Capsule

What do we already know about this clinical entity?

Spontaneous spinal epidural hematoma (SSEH) is a rare diagnosis. There are several risk factors, including anticoagulation medications. Typically the disease presents as a cord compression syndrome.

What makes this presentation of disease reportable?

This case was interesting in that the neurological symptoms were waxing and waning. There have also been few cases reported of SSEH on rivaroxaban.

What is the major learning point?

While SSEH will usually present as a cord compression syndrome, it is important to consider this diagnosis in patients on rivaroxaban or other novel anticoagulation medications with an atypical presentation.

How might this improve emergency medicine practice?

Due to the extremely high morbidity and mortality associated with this diagnosis, it is important to be aware of the various presentations and adverse effects related to novel anticoagulation.

This case was interesting in that the neurological exam was waxing and waning, rather than a clear neurological deficit as one would expect from a compression syndrome. In other cases of SSEH caused by novel anticoagulants, two resolved spontaneously without the need for surgery, whereas the third and fourth required surgical intervention.¹⁴⁻¹⁷

As the use of new anti-coagulant medications such as rivaroxaban increases, there will likely be an increase in adverse events and new complications. SSEH may be one of them. The varied presentations and lack of clear inciting factor make SSEHs difficult to diagnose in the ED. While this is a rare diagnosis, anticoagulation medication is a known risk factor. Given the increased morbidity and mortality associated with this diagnosis and the use of new anticoagulation medications, it is important to be aware of these unusual presentations of SSEHS.

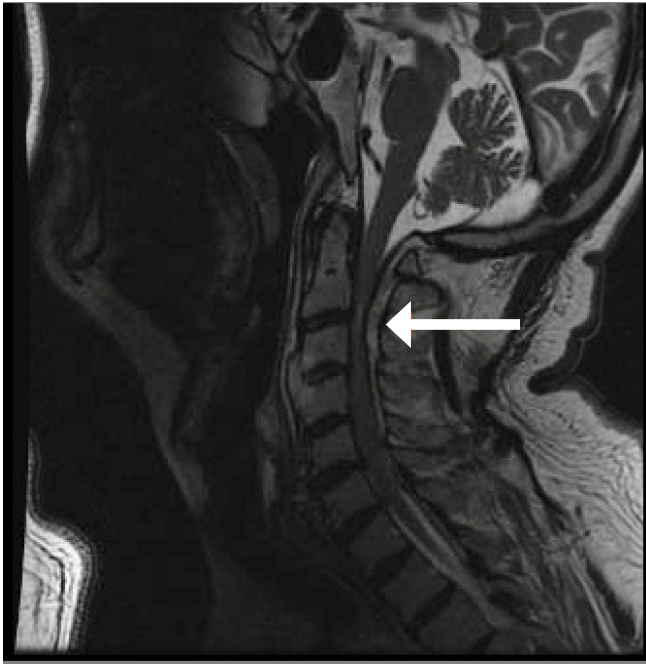

Image. Magnetic resonance imaging (T2 weighted) in sagittal view demonstrating spontaneous spinal epidural hematoma from the foramen magnum to cervical spine level 7 as indicated by the arrow.

CONCLUSION

Spontaneous spinal epidural hematomas are a rare but serious diagnosis. Knowing the risk factors associated with this serious illness is important to recognize in emergency medicine. As new anticoagulant medications such as rivaroxaban are becoming more widely used, adverse effects from these medications will likely become more prevalent, and SSEH is likely one of them.

Documented patient informed consent and/or Institutional Review Board approval has been obtained and filed for publication of this case report.

Address for Correspondence: Charlotte Goldfine, MD, Hartford Hospital, University of Connecticut School of Medicine, Department of Emergency Medicine, 80 Seymour Street, Conklin Building Room 141, Hartford, CT 06102. Email: goldfine@uchc.edu.

Conflicts of Interest: By the CPC-EM article submission agreement, all authors are required to disclose all affiliations, funding sources and financial or management relationships that could be perceived as potential sources of bias. The authors disclosed none.

Copyright: © 2018 Goldfine et al. This is an open access article distributed in accordance with the terms of the Creative Commons Attribution (CC BY 4.0) License. See: <http://creativecommons.org/licenses/by/4.0/>

REFERENCES

1. Akimoto T, Yamada T, Shinoda S, et al. Spontaneous spinal epidural hematoma as a potentially important stroke mimic. *J Cent Nerv Syst Dis.* 2014;6:15-20.
2. Messerer M, Dubourg J, Diabira S, et al. Spinal epidural hematoma: not always an obvious diagnosis. *Eur J Emerg Med.* 2012;19(1):2-8.
3. Groen RJ, Ponsen H. The spontaneous spinal epidural hematoma. A study of the etiology. *J Neurol Sci.* 1990;98(2-3):121-38.
4. Abe T, Nagamine Y, Ishimatsu S, et al. Spinal epidural hematoma after stretch exercise: a case report. *Am J Emerg Med.* 2009;27(7):902.e1-2.
5. Dinsmore AJ, Leonard RB, Manthey D. Spontaneous spinal epidural hematoma: a case report. *J Emerg Med.* 2005;28(4):423-6.
6. David S, Salluzzo RF, Bartfield JM, et al. Spontaneous cervicothoracic epidural hematoma following prolonged valsalva secondary to trumpet playing. *Am J Emerg Med.* 1997;15(1):73-5.
7. Aksay E, Kiyani S, Yuruktumen A, et al. A rare diagnosis in emergency department: spontaneous spinal epidural hematoma. *Am J Emerg Med.* 2008;26(7):835.e3-5.
8. Wittebol MC, van Veelen CW. Spontaneous spinal epidural haematoma. Etiological considerations. *Clin Neurol Neurosurg.* 1984;86(4):265-70.
9. Liu Z, Jiao Q, Xu J, et al. Spontaneous spinal epidural hematoma: analysis of 23 cases. *Surg Neurol.* 2008;69(3):253-60.
10. Babayev R, Ekşi MŞ. Spontaneous thoracic epidural hematoma: a case report and literature review. *Childs Nerv Syst.* 2016;32(1):181-7.
11. Aycan A, Ozdemir S, Arslan H, et al. Idiopathic thoracic spontaneous spinal epidural hematoma. *Case Rep Surg.* 2016;2016:5430708.
12. Beatty RM, Winston KR. Spontaneous cervical epidural hematoma. A consideration of etiology. *J Neurosurg.* 1984;61(1):143-8.
13. Kreppel D, Antoniadis G, Seeling W. Spinal hematoma: a literature survey with meta-analysis of 613 patients. *Neurosurg Rev.* 2003;26(1):1-49.
14. Jaeger M, Jeanneret B, Schaeren S. Spontaneous spinal epidural haematoma during factor Xa inhibitor treatment (rivaroxaban). *Eur Spine J.* 2012;21 Suppl 4:S433-5.
15. Radcliff KE, Ong A, Parvizi J, et al. Rivaroxaban-induced epidural hematoma and cauda equina syndrome after total knee arthroplasty: a case report. *Orthop Surg.* 2014;6(1):69-71.
16. Ozel O, Demircay E, Kircelli A, et al. Atypical presentation of an epidural hematoma in a patient receiving rivaroxaban after total hip arthroplasty. *Orthopedics.* 2016;39(3):e558-60.
17. Ismael R, Zaghriani E, Hitti E. Spontaneous spinal epidural hematoma in a patient on rivaroxaban: case report and literature review. *J Emerg Med.* 2017;53(4): 536-9.
18. Yu JX, Liu J, He C, et al. Spontaneous spinal epidural hematoma: a study of 55 cases focused on the etiology and treatment strategy. *World Neurosurg.* 2017;98:546-54.
19. Mohammed N, Shahid M, Haque M, et al. Spontaneous spinal epidural haematoma mimicking acute coronary syndrome. *Quant Imaging Med Surg.* 2015;5(6):925-7.

20. Fedor M, Kim ES, Ding K, et al. Spontaneous spinal epidural hematoma: a retrospective study on prognostic factors and review of the literature. *Korean J Spine*. 2011;8(4):272-82.
21. Castillo JM, Afanador HF, Manjarrez E, et al. Non-traumatic spontaneous spinal subdural hematoma in a patient with non-valvular atrial fibrillation during treatment with rivaroxaban. *Am J Case Rep*. 2015;16:377-81.
22. Dargazanli C, Lonjon N, Gras-Combe G. Nontraumatic spinal subdural hematoma complicating direct factor Xa inhibitor treatment (rivaroxaban): a challenging management. *Eur Spine J*. 2016;25 Suppl 1:100-3.
23. EINSTEIN Investigators., Bauersachs R, Berkowitz SD, Brenner B, et al. Oral rivaroxaban for symptomatic venous thromboembolism. *N Engl J Med*. 2010;363(26):2499-510.
24. Eerenberg ES, Kamphuisen PW, Sijpkens MK, et al. Reversal of rivaroxaban and dabigatran by prothrombin complex concentrate: a randomized, placebo-controlled, crossover study in healthy subjects. *Circulation*. 2011;124(14):1573-9.
25. Weitz JI. Reversal of direct oral anticoagulants: current status and future directions. *Semin Respir Crit Care Med*. 2017;38(1):40-50.

Clozapine Intoxication Mimicking Acute Stroke

Jacob A. Lebin, MD*

Joshua D. Villarreal, PharmD[†]

Betty C. Chen, MD*

M. Kennedy Hall, MD, MHS*

*University of Washington, Department of Emergency Medicine, Seattle, Washington

[†]University of Washington, Department of Pharmacy, Seattle, Washington

Section Editor: Shadi Lahham, MD, MS

Submission history: Submitted October 11, 2017; Revision received December 31, 2017; Accepted January 19, 2018

Electronically published April 5, 2018

Full text available through open access at http://escholarship.org/uc/uciem_cpchem

DOI: 10.5811/cpchem.2018.1.36734

Clozapine is an atypical antipsychotic drug prescribed for treatment-resistant schizophrenia. The risk of adverse hematologic, cardiovascular, and neurologic effects has tempered its use, and reports of overdoses remain rare. We report a case of accidental acute clozapine intoxication in a clozapine-naïve patient, who presented with symptoms mimicking acute stroke and later developed status epilepticus. Clozapine intoxication is a rare presentation in the emergency department with potential for iatrogenic harm if not correctly identified. [Clin Pract Cases Emerg Med.2018;2(2):155-157.]

INTRODUCTION

Clozapine is an atypical antipsychotic drug used for treatment-resistant schizophrenia and is the prototypical agent of the tricyclic dibenzodiazepine class. Atypical antipsychotics are effective in controlling the positive (hallucinations, delusions) and negative (flat affect, anhedonia) symptoms of schizophrenia with fewer extrapyramidal side effects compared to typical antipsychotics.¹ In addition to affinity for the dopamine (D₂) receptor, the unique clinical and side-effect profile of clozapine is mediated through mixed antagonism at muscarinic, histamine, alpha-adrenergic, gamma-aminobutyric acid, and serotonin receptors.

Despite its clinical superiority in comparison to other atypical antipsychotics, clozapine remains a second-line agent due to its side-effect profile.¹ At standard doses, clozapine has been known to cause agranulocytosis, sedation, and hypersalivation.² At toxic doses, clozapine has been reported to cause encephalopathy, dysarthria, and ataxia.³ Previously published reports of clozapine overdose have mainly been characterized by large-dose ingestions in patients who are attempting suicide and are already maintained on clozapine.^{3,4} There are few reported cases describing acute clozapine intoxication in clozapine-naïve patients with relatively small exposures.⁵

We report a case of a clozapine-naïve man who presented to the emergency department (ED) with dysarthria and ataxia, initially thought to be due to an acute ischemic stroke, but ultimately determined to be due to acute clozapine intoxication. Although uncommon, clozapine intoxication should be

considered for patients who present with acute onset of neurologic symptoms and possible clozapine exposure.

CASE REPORT

A 66-year-old man with a history of hypertension and hyperlipidemia was brought to the ED for altered mental status. The patient's wife reported that two hours prior to arrival, he had ingested two glasses of wine and took a nap. Prior to napping the wife noted no unusual symptoms. Upon awaking, he was noted to have dysarthria and discoordination of his extremities and was brought to the ED. His wife reported that his home medications included bupropion, dutasteride, lisinopril, and tolterodine.

His vital signs were blood pressure 115/78 millimeters mercury, heart rate 83 beats per minute, respiratory rate 16 breaths per minute, temperature 36.8° Celsius, and oxygen saturation of 95% on room air. On exam, the patient was noted to have waxing and waning alertness, but he could intermittently answer questions and follow commands. His pupils were reactive, sluggish, and with horizontal and vertical nystagmus. His face was symmetric and his tongue was midline. His speech was dysarthric. He was unable to follow commands for strength testing, but he was moving all extremities without appreciable asymmetry. He had bilateral dysmetria on finger-to-nose and heel-to-shin testing. He had truncal ataxia in the seated position. His mental status and ataxia progressively worsened during his ED stay of approximately 1.5 hours.

Given the acute onset of symptoms, an institutional stroke alert was activated and a head computed tomography angiogram

was obtained, which was negative for hemorrhage or other abnormality. Laboratory values, including complete blood count, chemistry panel, coagulation panel, and urinalysis were within normal limits. His blood alcohol level was 57 mg/dL. Electrocardiogram showed normal sinus rhythm with a QRS of 108 ms and a QTc of 497 ms. A dose of naloxone 0.4 milligrams was trialed without improvement in patient's somnolence. He was evaluated by the neurology consultant team and determined to have a National Institute of Health Stroke Scale of 11. Given concern for a posterior circulation stroke, tissue plasminogen activator was administered for thrombolysis. The patient was subsequently intubated for airway protection due to increasing somnolence and admitted to the intensive care unit (ICU).

While intubated in the ICU, the patient developed status epilepticus, characterized by three periods of generalized tonic clonic activity, each lasting approximately five minutes. He received multiple doses of benzodiazepine and phenytoin, in addition to the propofol infusion for sedation, resulting in cessation of seizure activity. Subsequent electroencephalogram did not demonstrate ongoing seizure activity, and the patient did not have an additional seizure during the hospital course while maintained on phenytoin.

Magnetic resonance imaging of the brain did not show evidence of acute stroke. Comprehensive urine drug screen by gas chromatography and mass spectrometry was positive for clozapine and clozapine metabolites, in addition to caffeine and bupropion, a home medication. No drugs of abuse or other medications were detected. However, the patient had never been prescribed clozapine. In discussion with his wife, it was learned that the patient's family member takes clozapine for a psychiatric condition. The patient manages the family member's medication and they frequently take their respective medications at the same time. It was concluded that the patient must have mistaken the family member's medication for his and accidentally ingested the family member's usual dose of 200 mg of clozapine, hours prior to his presentation. The patient was extubated on hospital day three and discharged with a normal neurologic exam and no further seizure activity on hospital day five.

DISCUSSION

We present a case of acute clozapine intoxication in a clozapine-naïve patient. This case illustrates the features of clozapine toxicity and highlights that clozapine ingestions can lead to severe intoxications in naïve patients.

To our knowledge, this case represents one of the few reported clozapine overdoses in a clozapine-naïve patient.⁵ Patients beginning treatment with clozapine are usually started on 12.5mg daily with up-titration to daily doses of 300 to 600 mg. With our patient taking an acute ingestion of 200 mg, this case illustrates a severe intoxication at the lower end of usual therapeutic dosing. It has been postulated that tolerance may develop with prolonged clozapine treatment, resulting in more severe intoxications in those patients who have not been exposed

CPC-EM Capsule

What do we already know about this clinical entity?

Clozapine is an atypical antipsychotic drug used for treatment-resistant schizophrenia. Reported cases of intoxication are frequently characterized by large-dose ingestions.

What makes this presentation of disease reportable?

This case illustrates a severe clozapine intoxication from standard dosing in a clozapine-naïve patient and was characterized by stroke-like symptoms and status epilepticus.

What is the major learning point?

Clozapine intoxication is a rare presentation to the emergency department. Emergency physicians (EP) should be familiar with the medication and its presentation in overdose.

How might this improve emergency medicine practice?

EPs should maintain a broad differential for stroke-like symptoms, including medications, and recognize the signs of clozapine intoxication.

to clozapine previously.⁵ In a retrospective case study of poison center reports, clozapine doses as low as 100mg were found to have resulted in severe intoxication, but clozapine pretreatment information was limited.³ It is important for providers to recognize that severe intoxications can occur even at standard clozapine doses.

The symptoms of acute clozapine intoxication presented here are consistent with those reported previously in the literature. Central nervous system depression, sometimes severe (Glasgow Coma Scale less than 7), is the most frequently observed symptom and is likely mediated through antagonism of the histamine H₁ receptor.³ Patients also frequently present with dysarthria, bradykinesia, and ataxia. Due to clozapine's partial antagonism at the muscarinic receptor, poisoned patients can present with symptoms of an anticholinergic toxidrome, such as tachycardia, altered mental status, and coma. Consistent with this case, patients over the age of 50 are at increased risk for severe intoxication.³

This case represents one of the few reported clozapine intoxications complicated by status epilepticus.³ Clozapine is

known to lower the seizure threshold, possibly through antagonism of the gamma-aminobutyric acid receptor, and seizures have been reported during treatment and in overdose previously.⁶ However, reports of status epilepticus remain rare in the literature. It is likely that the patient was at higher risk for seizure activity given his use of bupropion, and thus had a lower seizure threshold prior to his presentation. An alcohol-withdrawal seizure was thought to be less likely as the patient did not have a history of heavy alcohol use or alcohol withdrawal, nor did he demonstrate symptoms consistent with alcohol withdrawal. It is also possible that the patient's abnormal movements were the result of a dystonic reaction, but this would be unusual given the relative low affinity for D₂ antagonism of clozapine as compared to typical antipsychotics.

Stroke mimics are common in the ED and account for up to 30% of suspected stroke presentations.⁹ Medications are a rare etiology of stroke mimic, which has only been described previously in case reports of methyl iodine and prochlorperazine.^{10,11} Presentations that mimic posterior circulation strokes are particularly challenging as the symptoms of posterior circulation stroke, such as ataxia, dizziness, and dysarthria, are shared with many alternative etiologies.¹² Given the need for rapid decision-making in acute ischemic stroke, misdiagnosis and inappropriate treatment with thrombolytic therapy have become increasing common. Fortunately, the incidence of symptomatic intracranial hemorrhage in patients who received thrombolytic therapy for a stroke mimic remains low (0.5%).⁹ Our patient did not experience any adverse effects from the administration of tissue plasminogen activator.

Primary management of acute clozapine overdose is supportive care. Providers should be prepared to provide airway management given the frequency of somnolence and coma. Hypotension refractory to fluids may be present due to alpha-adrenergic blockade, and vasopressor support may be necessary.⁵ Quantitative clozapine levels require gas or liquid chromatography and are rarely available during early management.⁴ Therefore, the diagnosis of acute clozapine intoxication relies heavily on supportive collateral history of clozapine exposure, which can be challenging to obtain unless solicited.

CONCLUSION

Acute clozapine intoxication is a rare presentation to the ED and is characterized by encephalopathy, dysarthria, and ataxia. Clozapine-naïve patients may be at higher risk for severe intoxication from standard dosing regimens.

Documented patient informed consent and/or Institutional Review Board approval has been obtained and filed for publication of this case report.

Address for Correspondence: Jacob A Lebin, MD, University of Washington, Harborview Medical Center, Department of Emergency Medicine, 325 Ninth Avenue Seattle, WA 98104-2499. Email: lebin@uw.edu.

Conflicts of Interest: By the CPC-EM article submission agreement, all authors are required to disclose all affiliations, funding sources and financial or management relationships that could be perceived as potential sources of bias. The authors disclosed none.

Copyright: © 2018 Lebin et al. This is an open access article distributed in accordance with the terms of the Creative Commons Attribution (CC BY 4.0) License. See: <http://creativecommons.org/licenses/by/4.0/>

REFERENCES

1. Kinon BJ, Lieberman JA. Mechanisms of action of atypical antipsychotic drugs: a critical analysis. *Psychopharmacology (Berl)*. 1996;124(1-2):2-34.
2. Welber MR, Nevins S. Clozapine overdose, a case report. *J Emerg Med*. 1995;13(2):199-202.
3. Krämer I, Rauber-Lüthy C, Kupferschmidt H, et al. Minimal dose for severe poisoning and influencing factors in acute human clozapine intoxication: a 13-year retrospective study. *Clin Neuropharmacol*. 2010;33(5):230-4.
4. Thomas L, Pollak PT. Delayed recovery associated with persistent serum concentrations after clozapine overdose. *J Emerg Med*. 2003;25(1):61-6.
5. West S, Jeffery-Smith A, Brownlee W, et al. Covert clozapine overdose: clozapine toxicity in a naive patient. *Aust N Z J Psychiatry*. 2013;47(12):1208-9.
6. Varma S, Bishara D, Besag FMC, et al. Clozapine-related EEG changes and seizures: dose and plasma-level relationships. *Ther Adv Psychopharmacol*. 2011;1(2):47-66.
7. Mady S, Wax P, Wang D, et al. Pediatric clozapine intoxication. *Am J Emerg Med*. 1996;14(5):462-3.
8. Kamis GZ, Ayhan Y, Basar K, et al. A case of clozapine intoxication presenting with atypical NMS symptoms. *Int J Neuropsychopharmacol*. 2014;17(5):819-21.
9. Liberman AL, Prabhakaran S. Stroke chameleons and stroke mimics in the emergency department. *Curr Neurol Neurosci Rep*. 2017;17(2).
10. Nair J, Chatterjee K. Methyl iodide poisoning presenting as a mimic of acute stroke: a case report. *J Med Case Rep*. 2010;4:177.
11. Coralic Z, Kim AS, Vinson DR. Prochlorperazine-induced hemidystonia mimicking acute stroke. *West J Emerg Med*. 2015;16(4):572-4.
12. Arch AE, Weisman DC, Coca S, et al. Missed ischemic stroke diagnosis in the emergency department by emergency medicine and neurology services. *Stroke*. 2016;47(3):668-73.

Takotsubo Cardiomyopathy in the Emergency Department: A FOCUS Heart Breaker

Kristin Meigh, BS*
Madison Caja, BS*
Melinda Sharon, MPH†
Allison Tadros, MD†
Shane Dragan, MD†
David Henkel, MD†
Joseph Minardi, MD†‡

*West Virginia University School of Medicine, Morgantown, West Virginia
†West Virginia University, Department of Emergency Medicine, Morgantown, West Virginia
‡West Virginia University, Department of Medical Education, Morgantown, West Virginia

Section Editor: Rick A. McPheeters, DO

Submission history: Submitted December 13, 2017; Revision received February 5, 2018; Accepted February 27, 2018

Electronically published April 5, 2018

Full text available through open access at http://escholarship.org/uc/uciem_cpchem

DOI: 10.5811/cpchem.2018.2.37291

Takotsubo cardiomyopathy (TCM) is an important condition for the emergency physician to consider in patients with cardiovascular symptoms. A 70-year-old woman presented with chest pain and nausea following emotional trauma. She had an elevated troponin and a normal electrocardiogram with no history of previous cardiac disease. Point-of-care focused cardiac ultrasound (FOCUS) showed reduced left ventricular systolic function with mid to apical hypokinesis. Cardiac catheterization revealed clean coronary arteries and confirmed the suspected diagnosis of TCM. Few reports emphasize the importance of FOCUS in the diagnosis and management of TCM in the emergency department. We detail FOCUS findings that assisted with diagnosis of TCM and describe how this quick, noninvasive imaging modality can be used to assess and manage emergent conditions. [Clin Pract Cases Emerg Med. 2018;2(2):158-162.]

INTRODUCTION

Takotsubo cardiomyopathy (TCM) is an important differential consideration for emergency patients with cardiovascular symptoms. Also known as broken heart syndrome or stress-induced cardiomyopathy, this condition typically occurs in elderly women following a stressful psychological or physical event.¹ Patients typically present with symptoms of an acute coronary syndrome or new-onset heart failure, and may show accompanying changes such as elevated troponin level and ST-segment elevation on the 12-lead electrocardiogram (ECG).

Point-of-care focused cardiac ultrasound (FOCUS) is a critical diagnostic tool that should be implemented by emergency physicians (EP) in patients with chest pain and suspected TCM. FOCUS has been previously reported to help diagnose other conditions on the differential such as pulmonary embolism or pericardial tamponade.^{2,3} Other reports that have described the use of FOCUS by EPs for TCM have been less descriptive or have focused on atypical presentations of TCM.^{4,5} In comparison, our case involves a classic presentation of the condition associated

with a high index of suspicion in the emergency department (ED). Our aim was to describe the role of FOCUS in efficiently managing these patients. Using FOCUS to help diagnose TCM and distinguish it from other cardiac emergencies will enable EPs to better recognize and treat this important condition.

CASE REPORT

A 70-year-old woman presented to the ED with chest pain and nausea. The symptoms started after receiving news about a family member's critical illness. The chest pain was described as heavy with radiation to her right upper extremity and was associated with dyspnea. No other symptoms were associated with the chest pain. She had no history of previous cardiac disease. She was a smoker and her past medical history was significant for hyperlipidemia.

Her vital signs were unremarkable, with heart rate of 84 beats per minute, respiratory rate of 18 breaths per minute, blood pressure of 124/84 mmHg, and temperature of 36.7° Celsius. Her physical examination was also unremarkable. Initial ECG

demonstrated normal sinus rhythm. Chest radiograph showed hyperexpanded lungs with chronic obstructive changes but revealed no acute process. FOCUS performed by a general EP without fellowship training or special interest in ultrasound revealed severely reduced left ventricular systolic function with mid to apical hypokinesis and preservation of basal segments (Video). The apical 4-chamber and parasternal long axis FOCUS findings can be observed in Images 1 and 2, respectively.

Takotsubo cardiomyopathy was strongly suspected based on these findings and the patient's presentation. She was treated with aspirin and typical measures for acute coronary syndrome and admitted to the cardiology service. Her troponin returned at 595 ng/L and a subsequent ECG showed lateral T-wave inversions. There were no significant changes in vital signs from time of presentation. She underwent a comprehensive echocardiogram that confirmed the FOCUS findings. Because her troponins continued to rise, she underwent a cardiac catheterization the following day, which revealed clean coronary arteries and supported the diagnosis of TCM. Other than the development of atrial fibrillation, her hospital course was unremarkable and she was discharged a few days later. Follow-up echocardiogram seven weeks later demonstrated normal left ventricular function. She was no longer in atrial fibrillation, and the patient reported her symptoms had resolved.

DISCUSSION

TCM represents approximately 1.2% of troponin-positive acute coronary syndromes.⁶ The term *takotsubo* comes from the Japanese word for "octopus pot," which the appearance of the affected patient's heart resembles,

CPC-EM Capsule

What do we already know about this clinical entity?
Takotsubo cardiomyopathy is a type of stress-induced left ventricular dysfunction that is an important consideration in the differential diagnosis for chest pain.

What makes this presentation of disease reportable?
Unlike previous reports, this is a classic clinical presentation with well demonstrated focused cardiac ultrasound (FOCUS) findings that directed immediate care decisions.

What is the major learning point?
Chest pain after emotional upset with apical ballooning on FOCUS suggests Takotsubo cardiomyopathy, and should give pause to thrombolytics and prompt consideration of alternate care plans.

How might this improve emergency medicine practice?
Recognizing classic findings of Takotsubo cardiomyopathy may alter differentials and prompt alternate care plans, specifically when immediate cardiac catheterization is not available.

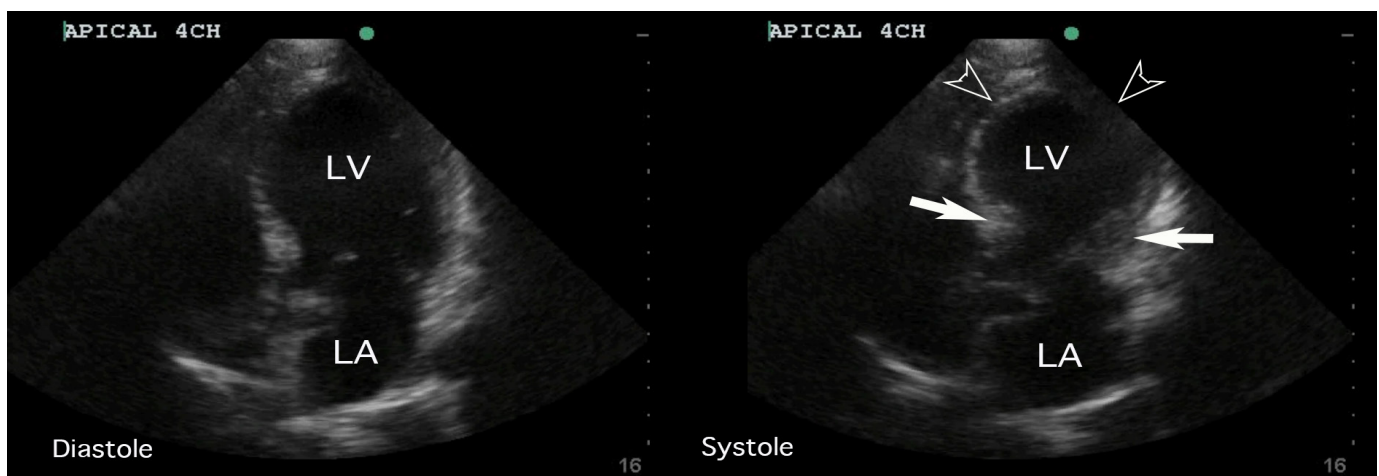


Image 1. This apical 4-chamber view of the heart performed by the emergency physician demonstrates findings of apical ballooning, with systolic mid to apical hypokinesis of the left ventricle (LV). The basal segments near the atrioventricular septum contract appropriately in systole (solid arrows), but the mid to apical segments of the left ventricle show minimal contraction and demonstrate ballooning when systole is compared to diastole (outlined arrowheads). These findings match the description of the classic apical variant of takotsubo cardiomyopathy, which is said to resemble an octopus pot. LA, left atrium.

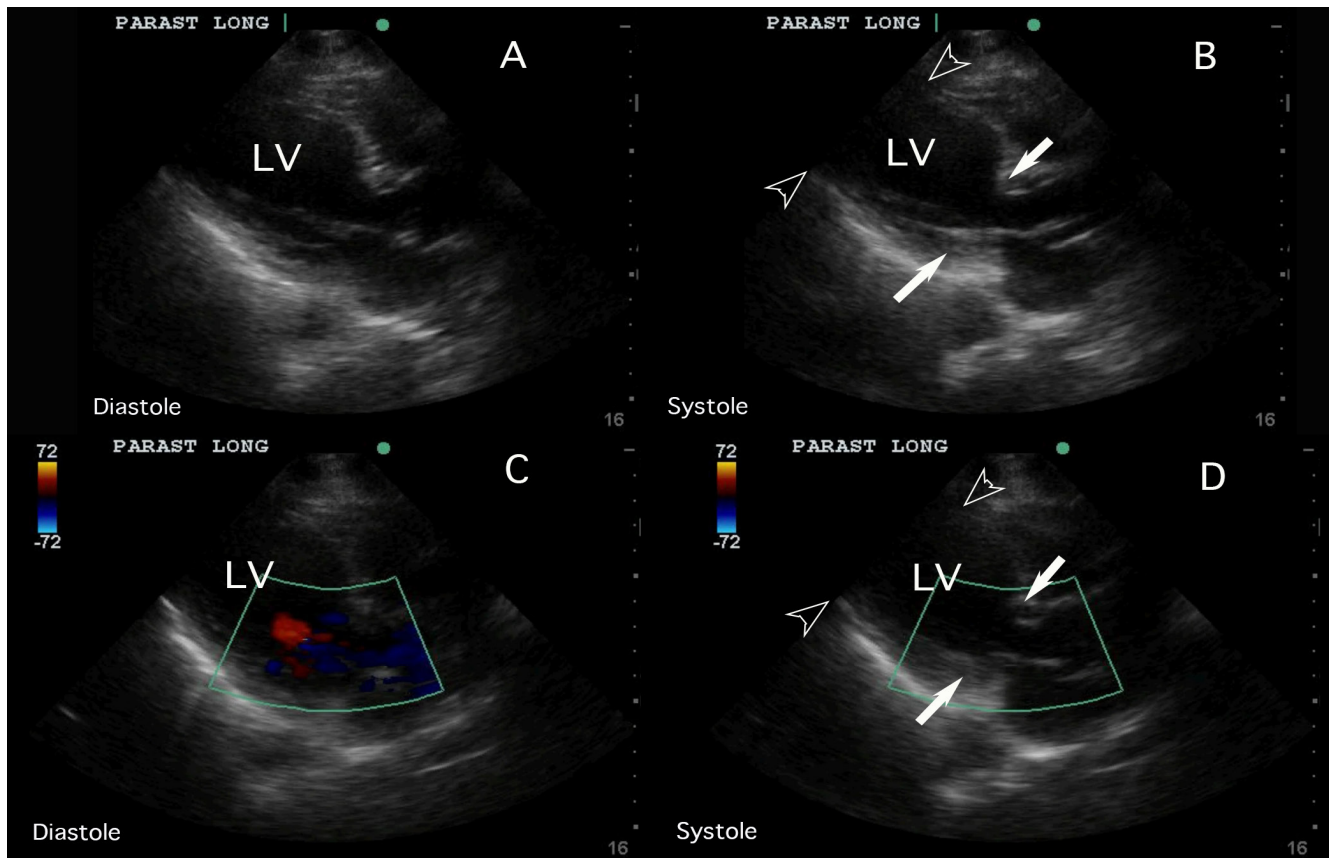


Image 2. These parasternal long-axis views, both with (panels C and D) and without (panels A and B) color, demonstrate the systolic apical ballooning of the left ventricle (LV) with preserved contraction of the basal segments. The apical portions of the interventricular septum and free wall of the left ventricle do not show significant movement when systole (panels B and D) is compared to diastole (panels A and C), indicating impaired contraction of the apical segment (outlined arrowheads). The left ventricular basal segments, however, move closer together in systole (panels B and D) to show preserved contraction of this portion of the heart (solid arrows).

typically showing hypokinesis or ballooning of the apical segments and hyperkinesis of the basal segments.⁷ This description matches the most common form of TCM, known as apical TCM. According to the International Takotsubo Registry (ITR), a rare variant of TCM known as basal or reverse takotsubo, occurs in approximately 2.2% of TCM patients.¹ In this form, the opposite presentation is seen, with hypokinesis of the basal heart and hyperkinesis of the apical segments.¹ Two other variants, focal and midventricular TCM, have also been described.¹

FOCUS assists in identifying the classic findings that may suggest TCM. FOCUS has been proven to be beneficial in diagnosing a myriad of other cardiorespiratory conditions such as atypical pericardial tamponade, pulmonary embolism, endocarditis, intra-cardiac masses, atypical acute coronary syndromes, and more.^{2,3,8,9} Despite the importance of FOCUS in diagnosing other acute cardiac conditions, few reports exist that detail its value in visualizing findings of TCM and subsequently narrowing the differential diagnosis. A recent case study described the

use of FOCUS in an atypical presentation of TCM.⁵

The diagnosis was not readily suspected with the patient's history, as she was a pre-menopausal woman with no recognizable triggering event. An EP performed FOCUS and noted apical ballooning and reduced LVEF. A comprehensive echocardiogram was subsequently performed by cardiology to confirm the findings, and prompt cardiac catheterization confirmed a final diagnosis of TCM. An additional case compared cardiac ultrasonography findings from the ED to cardiac catheterization images to demonstrate apical ballooning in a post-menopausal woman with a significant cardiac history.⁴ In comparison to the previous reports in the literature, our case study focused on a more classic presentation of this disease in the ED where there was a high index of suspicion; it highlights how FOCUS can be used to expedite this diagnosis.

The Mayo Clinic Criteria are typically used for the diagnosis of TCM.¹⁰ All four criteria must be present to correctly diagnose the condition, and are as follows:

- Transient LV systolic dysfunction extending beyond a single coronary artery territory
- Absence of obstructive coronary artery disease on cardiac catheterization
- New ECG abnormalities (ST-elevation or T-wave inversion) or troponin elevation
- Absence of myocarditis or pheochromocytoma.

These criteria are designed in part to assist physicians in distinguishing TCM from other acute cardiac conditions. Coronary angiography (CA) is considered the gold standard for differentiating TCM from acute myocardial infarction (AMI) by ruling out obstructive disease of the coronary arteries. However, FOCUS may be preferred, both before and after CA, due to its increasing availability, rapidity, and effectiveness.¹¹ FOCUS allows for the rapid detection of both apical and alternative forms of TCM, since the site of systolic dysfunction in the left ventricular wall can readily be visualized with this imaging method.

After recognition of wall motion abnormalities on FOCUS, coronary computed tomography angiography (CCTA) may be considered instead of CA to rule out coronary artery disease (CAD), due to the fact that CCTA is noninvasive and has a high negative predictive value for CAD.¹¹ Pairing CCTA with FOCUS could allow for a relatively noninvasive diagnosis of TCM in future patients compared to current standards. While ECG and troponin changes can also assist in this diagnosis, it is difficult to distinguish between TCM and AMI based on these parameters alone; therefore, FOCUS can provide additional useful data to help distinguish these important acute conditions.¹¹ This is especially critical when fibrinolytic therapy is being considered for an AMI, as inappropriate administration of this treatment could lead to unwanted adverse affects.¹²

Understanding of the epidemiology and risk factors associated with TCM can also assist the EP in evaluating these patients. TCM classically presents in post-menopausal females exposed to a physically or emotionally stressful event. However, TCM may also occur in males with a physical trigger, such as an infection, or with no identifiable trigger.^{1,13} While classic apical TCM is more commonly associated with heart failure symptoms like dyspnea and pulmonary edema, reverse TCM typically occurs more frequently in younger patients.^{14,15} Echocardiogram parameters such as left ventricular ejection fraction (LVEF) at the time of diagnosis and follow-up have been found to be similar between reverse TCM and other variants.¹⁴

Compared with an acute coronary syndrome patient, patients with TCM more commonly demonstrated a lower LVEF and a higher incidence of neurological and psychiatric conditions.¹ It is important to be aware of the differences between variants and to differentiate TCM from AMI, so that the diagnosis is not missed. Care must be taken and all

clinical data carefully considered because echocardiographic and clinical findings of TCM may closely mimic those of acute coronary syndrome. It should be emphasized that coronary imaging is required for definitive exclusion of acute coronary syndrome and diagnosis of TCM.

The treatment for TCM patients is debated throughout the literature. Though beta-blockers are typically used for TCM patients due to the widely accepted role of catecholamines in the condition, the International Takotsubo Registry reports that ACE-inhibitors or angiotensin receptor blockers are more associated with improved survival of TCM patients.¹ In addition, the prognosis also varies. Compared to ACS patients, TCM patients were found to have just as many if not more complications such as cardiogenic shock, cardiopulmonary arrest, and even death.¹ Rapid recognition of TCM with FOCUS will help direct appropriate diagnostic workup and may prevent administration of potentially harmful therapy such as fibrinolytic therapy for an AMI. It will also assist in narrowing the differential for other cardiovascular conditions such as pulmonary embolism and pericardial effusions.^{2,3} Maintaining a high index of suspicion for TCM and using FOCUS to recognize wall motion abnormalities may help differentiate this condition from AMI, and will assist EPs in better management of these patients. Future studies could evaluate the utility of echocardiography paired with CCTA or other noninvasive pathways to make this diagnosis in select patients.

CONCLUSION

Takotsubo cardiomyopathy is an important condition for the EP to consider in patients with cardiovascular symptoms. Recognizing the clinical presentation and FOCUS findings may help EPs make a more accurate and timely diagnosis as well as direct immediate management decisions for this important ACS mimic. While this diagnosis may be suspected based on initial ED evaluation including FOCUS, acute ischemia can only be excluded by coronary artery evaluation. Current practice requires invasive coronary angiography rule-out ACS, but a strategy that involves the use of FOCUS combined with CCTA in consultation with an interventional cardiologist may allow a completely noninvasive evaluation and confirmation of diagnosis in select patients.

Video. Echocardiogram parasternal long-axis and apical 4-chamber views, both with and without color, displaying the systolic basal pinch points and apical ballooning. Parasternal short-axis and subxiphoid views show reduced left ventricular systolic function.

Documented patient informed consent and/or Institutional Review Board approval has been obtained and filed for publication of this case report.

Address for Correspondence: Joseph Minardi, MD, West Virginia University, Department of Emergency Medicine, RCBHSC, PO Box 9149 Morgantown, WV 26506. Email: jminardi@hsc.wvu.edu.

Conflicts of Interest: By the CPC-EM article submission agreement, all authors are required to disclose all affiliations, funding sources and financial or management relationships that could be perceived as potential sources of bias. The authors disclosed none.

Copyright: © 2018 Meigh et al. This is an open access article distributed in accordance with the terms of the Creative Commons Attribution (CC BY 4.0) License. See: <http://creativecommons.org/licenses/by/4.0/>

REFERENCES

1. Templin C, Ghadri JR, Diekmann J, et al. Clinical features and outcomes of takotsubo (stress) cardiomyopathy. *N Engl J Med.* 2015;373(10):929-38.
2. Abbasi OZ, Doan TT, Duggal S, Nair SU, Quinn SM. Utilization of bedside ultrasound in the diagnosis and management of massive pulmonary embolism: A case report. *Radiol Case Rep.* 2016;11(4):447-9.
3. Walsh BM, Tobias LA. Low-pressure pericardial tamponade: Case report and review of the literature. *J Emerg Med.* 2017;52(4):516-22.
4. Stanford K, Frasure SE. Adult female with chest pain. *Ann Emerg Med.* 2016;67(3):417, 422.
5. Varghese JG, Jelani QU, Zarich S, Walsh B. The role of early focused cardiac ultrasound in a not-so-typical presentation of takotsubo cardiomyopathy: A case report. *J Emerg Med.* 2017;52(5):e169-e173.
6. Kurowski V, Kaiser A, von Hof K, et al. Apical and midventricular transient left ventricular dysfunction syndrome (tako-tsubo cardiomyopathy): Frequency, mechanisms, and prognosis. *Chest.* 2007;132(3):809-16.
7. Sato H, Tateishi H, Uchida T, et al. "Takotsubo-type cardiomyopathy due to multivessel spasm." In: Kodama K, Haze K, Hon M, editors. *Clinical Aspect of Myocardial Injury: From Ischemia to Heart Failure.* Kagaku Hyoronsha; Tokyo: 1990. Pp56-64. [in Japanese]
8. Yip MF, Walsh BM. Hemorrhagic pericardial cyst diagnosis accelerated by emergency physician echocardiography: A case report. *J Emerg Med.* 2017;52(4):e105-9.
9. Minardi J, Marshall T, Massey G, et al. Focused cardiac ultrasound: Uncommon but critical diagnoses made at the point of care. *J Ultrasound Med.* 2015;34(4):727-36.
10. Prasad A, Lerman A, Rihal CS. Apical ballooning syndrome (Tako-Tsubo or stress cardiomyopathy): A mimic of acute myocardial infarction. *Am Heart J.* 2008;155(3):408-17.
11. Bossone E, Lyon A, Citro R, et al. Takotsubo cardiomyopathy: An integrated multi-imaging approach. *Eur Heart J Cardiovasc Imaging.* 2014;15(4):366-77.
12. Prasad A. Apical ballooning syndrome: An important differential diagnosis of acute myocardial infarction. *Circulation.* 2007;115(5):e56-9.
13. Deshmukh A, Kumar G, Pant S, et al. Prevalence of takotsubo cardiomyopathy in the United States. *Am Heart J.* 2012;164(1):66-71.e1.
14. Song BG, Chun WJ, Park YH, et al. The clinical characteristics, laboratory parameters, electrocardiographic, and echocardiographic findings of reverse or inverted takotsubo cardiomyopathy: Comparison with mid or apical variant. *Clin Cardiol.* 2011;34(11):693-9.
15. Ramaraj R, Movahed MR. Reverse or inverted takotsubo cardiomyopathy (reverse left ventricular apical ballooning syndrome) presents at a younger age compared with the mid or apical variant and is always associated with triggering stress. *Congest Heart Fail.* 2010;16(6):284-6.

Hyperkalemia Brugada Sign: When Catheterization Lab Is Not the Answer

Rene M. Kukkamalla, MD
Eric Katz, MD

Maricopa Medical Center, Department of Emergency Medicine, Phoenix, Arizona

Section Editor: Rick A. McPheeters, DO

Submission history: Submitted November 9, 2017; Revision received January 22, 2018; Accepted January 31, 2018

Electronically published March 14, 2018

Full text available through open access at http://escholarship.org/uc/uciem_cpem

DOI: 10.5811/cpcem.2018.1.36979

[Clin Pract Cases Emerg Med. 2018;2(2):163-164.]

CASE PRESENTATION

The patient was a 61-year-old male who presented to the emergency department (ED) with two days of emesis without abdominal pain. The patient's initial electrocardiogram (EKG) showed normal sinus rhythm with peaked T-waves (Image 1).

Laboratory data were significant for hyperkalemia of 8.8 and new-onset renal failure with a creatinine of 7.2. A repeat EKG was obtained and showed an incomplete right bundle branch with Brugada pattern of ST-segment elevation in leads V1 and V2 (Image 2).

The automated EKG reading was an acute ST-segment elevation myocardial infarction; however, the lack of reciprocal

changes made the ED team discount that. Cardiology was contacted for consultation and concurred, advising that the EKG change was likely secondary to hyperkalemia.

DIAGNOSIS

This case represents hyperkalemia-induced Brugada pattern. Brugada syndrome is a congenital anomaly characterized by abnormalities of the sodium ion channel. It often manifests as a widened QRS-segment on EKG with ST-segment elevation in the right precordial leads. A similar "Brugada pattern" (or "sign") has been seen in the absence of this congenital sodium channel anomaly.

Hyperkalemia has multiple manifestations on EKG

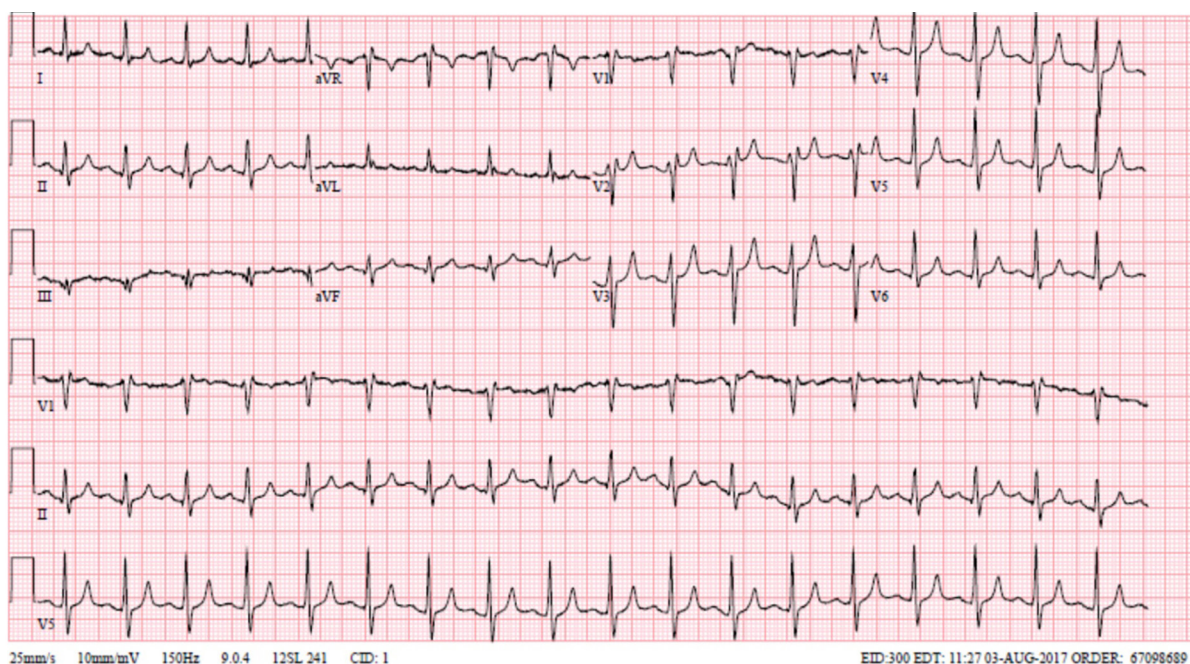


Image 1. Initial electrocardiogram demonstrating peaked T-waves.

including peaked T-waves, QRS-segment prolongation, and sine wave pattern. It is important for emergency physicians to be familiar with less common manifestations as well, one of which includes the hyperkalemia-induced Brugada pattern. This change is reversible and typically resolves with resolution of hyperkalemia, which helps distinguish it from Brugada syndrome. Despite the ST-segment elevations anteriorly, patients with hyperkalemic Brugada sign would not benefit from the catheterization lab as the abnormality is from excess potassium, rather than a structural lesion.

Documented patient informed consent and/or Institutional Review Board approval has been obtained and filed for publication of this case report.

Address for Correspondence: Rene Meghana Kukkamalla, MD, Maricopa Medical Center, Department of Emergency Medicine, 2601 East Roosevelt Street, Phoenix, AZ 85008. Email: meghanakukks@gmail.com.

Conflicts of Interest: By the CPC-EM article submission agreement, all authors are required to disclose all affiliations, funding sources and financial or management relationships that could be perceived as potential sources of bias. The authors disclosed none.

Copyright: © 2018 Kukkamalla et al. This is an open access article distributed in accordance with the terms of the Creative Commons Attribution (CC BY 4.0) License. See: <http://creativecommons.org/licenses/by/4.0/>

CPC-EM Capsule

What do we already know about this clinical entity?

Brugada sign is usually associated with ischemia and sodium channel blockade. That it can be induced by hyperkalemia is less well known.

What is the major impact of the image(s)?

Recognition of hyperkalemic-induced Brugada sign is rare, and can save patients from unnecessary cardiac catheterization. In patients with hyperkalemia, the classic EKG changes are not the only ones to watch for.

How might this improve emergency medicine practice?

Early recognition helps separate two identical EKG presentations with different patient care needs.

REFERENCES

1. Ameen M, Akbar G, Abbas N, et al. Hyperkalemia-induced Brugada phenocopy: a rare ECG manifestation. *Case Rep Cardiol.* 2017;2017:9464728.
2. Kurisu S, Inoue I, Kawagoe T. Brugada-like electrocardiographic pattern due to hyperkalemia. *Clin Cardiol.* 2009;32(7):E23.
3. Littmann L, Monroe MH, Taylor L 3rd, et al. The hyperkalemic Brugada sign. *J Electrocardiol.* 2007;40(1):53-9.

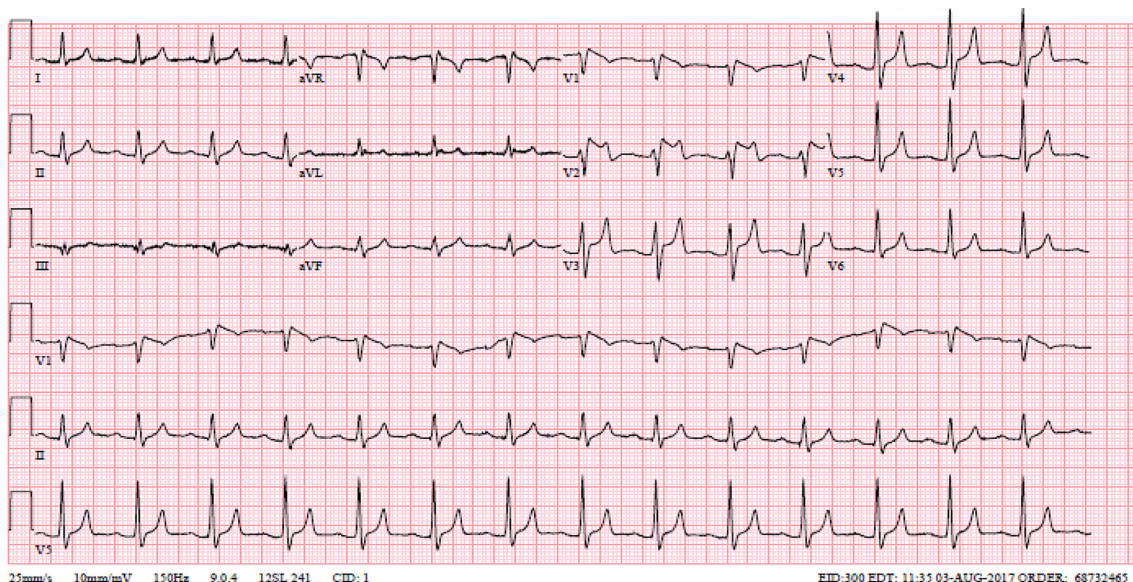


Image 2. Repeat electrocardiogram demonstrating Brugada pattern.

Man with Total Knee Arthroplasty Now Unable to Extend the Joint

Matthias Barden, MD
Julie K. A. Kasarjian, MD, PhD

Eisenhower Medical Center, Department of Emergency Medicine, Rancho Mirage, California

Section Editor: Rick A. McPheeters, DO

Submission history: Submitted October 3, 2017; Revision received January 19, 2018; Accepted February 2, 2018

Electronically published March 14, 2018

Full text available through open access at http://escholarship.org/uc/uciem_cpem

DOI: 10.5811/cpcem.2018.2.36642

[Clin Pract Cases Emerg Med. 2018;2(2):165-166.]

CASE PRESENTATION

A 70-year-old man presented to the emergency department (ED) complaining of inability to extend his left knee. He had been kneeling on the ground pushing a heavy box when he felt a “pop” in the knee. Prior history included remote total knee arthroplasty complicated by instability requiring multiple revisions. On physical exam, the leg was distally neurovascularly intact and his knee was flexed at about 45° with limited range of motion (Image 1). Radiographs were performed; however, imaging was somewhat limited by his decreased mobility and pain (Image 2).

DISCUSSION

Diagnosis: Flexion (cam-jump) dislocation of total knee arthroplasty

Instability of the knee joint after total knee arthroplasty is a somewhat common complication; however, dislocation is

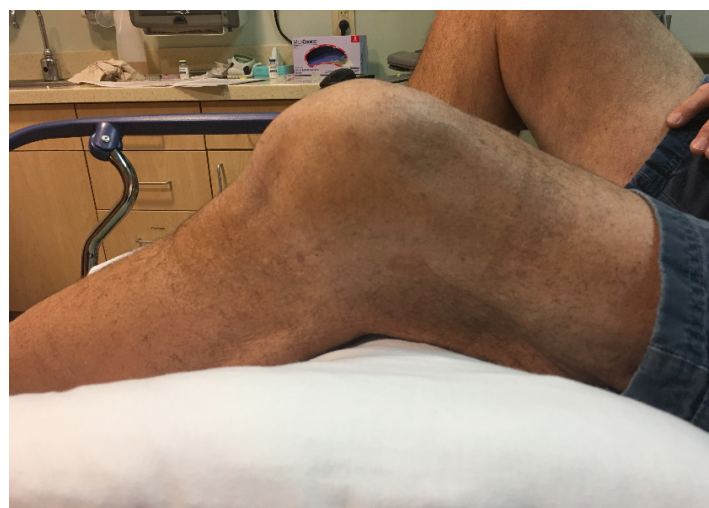

Image 1. Photo of knee showing the position of locked flexion during a cam-jump dislocation of prosthetic knee.

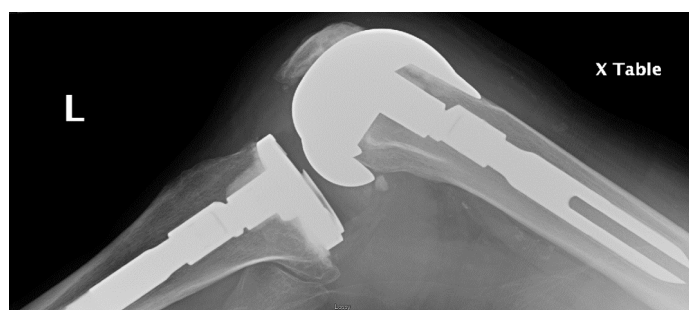

Image 2. Initial lateral radiograph of cam-jump dislocation of prosthetic knee joint. The femoral component is subtly displaced anteriorly versus the tibial component of the prosthesis.

rare and represents the most severe degree of instability.¹ The patient stated that he had “jumped the cam,” which was the term his orthopedist used when he had a similar episode two years previously. With this type of dislocation, hyperflexion of the joint causes the femoral component (“cam”) of the prosthesis to be rotationally translated anteriorly relative to the tibial component (“post”).² The posterior aspect of the femoral component becomes locked in articulation with the tibial component and the patient is unable to extend the joint back into a normal position.

After discussing the case with the orthopedic surgeon, the patient underwent procedural sedation and reduction in the ED. Reduction was accomplished with hyperflexion of the knee to exaggerate the deformity, followed by extension to re-establish the normal articulating position of the prosthetic.³ Post-reduction radiographs were obtained showing normal articulation of the prosthesis components (Image 3). After reduction the patient was able to ambulate without any pain and had full range of motion. The orthopedic surgeon did not recommend splinting or a knee immobilizer, but was very clear that the patient should be given instructions to never kneel again to avoid this rare and painful complication.

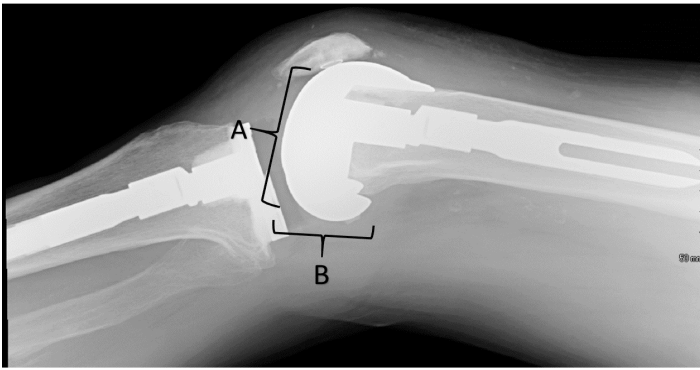


Image 3. Post-reduction radiograph showing proper articulation of the prosthetic components. Prior to the reduction, the posterior aspect of the femoral component (B) articulated with the tibial component. After reduction, the inferior aspect of the femoral component (A) now articulates with the femoral component.

Documented patient informed consent and/or Institutional Review Board approval has been obtained and filled for publication of this case report.

Address for Correspondence: Matthias Barden, MD, Eisenhower Medical Center, Emergency Department, 39000 Bob Hope Drive, Rancho Mirage, CA 92260. Email: mbarden@emc.org.

Conflicts of Interest: By the CPC-EM article submission agreement, all authors are required to disclose all affiliations, funding sources and financial or management relationships that could be perceived as potential sources of bias. The authors disclosed none.

Copyright: © 2018 Barden et al. This is an open access article distributed in accordance with the terms of the Creative Commons Attribution (CC BY 4.0) License. See: <http://creativecommons.org/licenses/by/4.0/>

CPC-EM Capsule

What do we already know about this clinical entity?

Orthopedic literature has described a translational or “cam-jump”-type of dislocation injury to total knee prosthetics, locking the knee in a semi-flexed position.

What is the major impact of the image(s)?

The images and discussion demonstrate the biomechanical mechanism by which the prosthetic becomes locked in this abnormal articulation.

How might this improve emergency medicine practice?

Understanding this mechanism will aid with diagnosis as well as reduction, which can likely be accomplished in the emergency department under procedural sedation.

REFERENCES

1. Sharkey PF, et al. Why are total knee arthroplasties failing today? *Clin Orthop Relat Res.* 2002;(404):7-13.
2. Wang CJ, Wang HE. Dislocation of total knee arthroplasty. A report of 6 cases with 2 patterns of instability, *Acta Orthop Scand.* 1997;68(3):282-5.
3. Arumilli BR, Ferns B, Smith M, et al. Non-traumatic dislocation (cam jump) in a revision knee: A case report. *Cases J.* 2009;2:7001.

Vascular Occlusion after Hyaluronic Acid Filler Injection

Sarah Grzybinski, MS, PA-C
Elizabeth Temin, MD, MPH

Massachusetts General Hospital, Department of Emergency Medicine, Boston, Massachusetts

Section Editor: Rick A. McPheeters, DO

Submission history: Submitted November 27, 2017; Revision received January 29, 2018; Accepted February 2, 2018

Electronically published April 5, 2018

Full text available through open access at http://escholarship.org/uc/uciem_cpccem

DOI: 10.5811/cpcem.2018.2.37149

[Clin Pract Cases Emerg Med. 2018;2(2):167-168.]

CASE PRESENTATION

A 26-year-old female presented to the emergency department (ED) with progressively worsening forehead erythema and discomfort after receiving an injection of hyaluronic acid filler into the glabella at a medical spa the previous day. On arrival to the ED she was afebrile with normal vital signs. Physical examination revealed blanchable erythema extending from the mid-forehead to the nasal

bridge in a linear distribution with early retiform appearance on the nasal sidewalls (Image). The patient denied visual symptoms, and ophthalmic examination was normal. She was diagnosed with vascular occlusion as a result of hyaluronic acid filler injection.

She was treated with an intradermal injection of 490U hyaluronidase (2.45mL of 200U/mL) administered in multiple small injections around the linear erythema. After the injection, a single dose of 2% nitroglycerin paste was applied to the skin for five minutes. She was discharged home on a two-week course of aspirin 325mg daily. The patient had outpatient follow-up one day and four days after her initial presentation. She had complete resolution of symptoms.

DISCUSSION

Vascular occlusion is a rare but potentially detrimental complication of hyaluronic acid filler injections. It results from accidental injection of filler into an artery, or compression of the artery from surrounding filler.¹ Vascular occlusion can rapidly progress to tissue necrosis if not identified and treated quickly. Retinal branch artery occlusion is also a potential complication of filler injections, caused by retrograde arteriolar flow of the filler into the branches of the ophthalmic artery.² It is imperative to ask about visual symptoms and perform a thorough ophthalmic examination in these patients. The treatment of hyaluronic acid-induced vascular occlusion involves intradermal injection of hyaluronidase, a protein enzyme that degrades hyaluronic acid. Patients may also benefit from topical nitroglycerin paste to facilitate vasodilation, although this is controversial. Experts also recommend a short-term aspirin regimen to prevent further clotting and vascular compromise.³

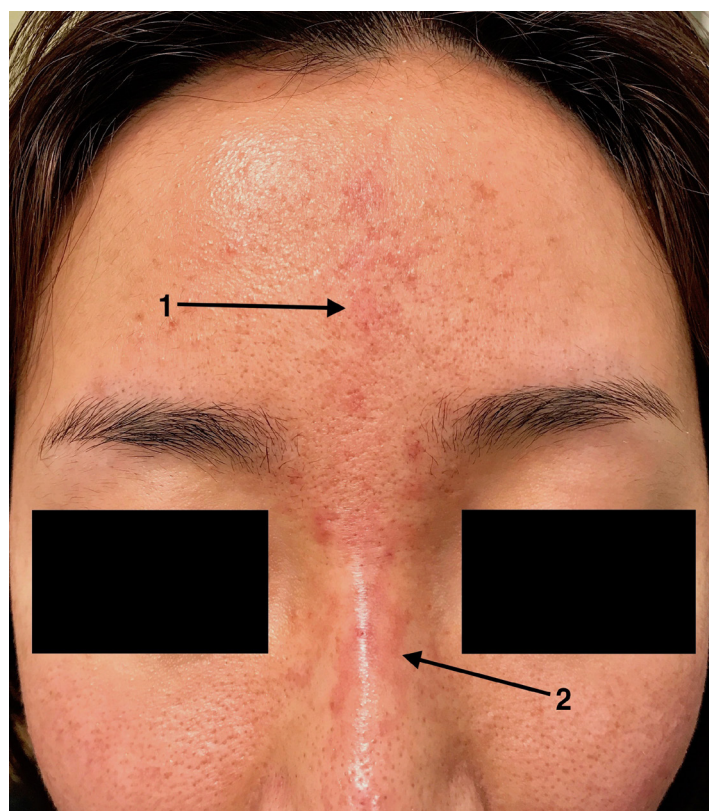

Image. Linear erythema of the forehead (arrow 1) with retiform appearance of the nasal bridge (arrow 2) in a woman after hyaluronic acid filler injection.

Documented patient informed consent and/or Institutional Review Board approval has been obtained and filed for publication of this case report.

Address for Correspondence: Sarah Grzybinski, MS, PA-C, Massachusetts General Hospital, Department of Emergency Medicine, 55 Fruit St, Boston, MA 02114. sgrzybinski@partners.org.

Conflicts of Interest: By the *CPC-EM* article submission agreement, all authors are required to disclose all affiliations, funding sources and financial or management relationships that could be perceived as potential sources of bias. The authors disclosed none.

Copyright: © 2018 Grzybinski et al. This is an open access article distributed in accordance with the terms of the Creative Commons Attribution (CC BY 4.0) License. See: <http://creativecommons.org/licenses/by/4.0/>

REFERENCES

1. Beleznyay K, Humphrey S, Carruthers JD, et al. Vascular compromise from soft tissue augmentation: experience with 12 cases and recommendations for optimal outcomes. *J Clin Aesthetic Dermatol.* 2014;7(9):37-43.
2. Peter S, Mennel S. Retinal branch artery occlusion following injection of hyaluronic acid (Restylane). *Clin Experiment Ophthalmol.* 2006;34(4):363-4.
3. Cohen JL, Biesman BS, Dayan SH, et al. Treatment of hyaluronic acid filler-induced impending necrosis with hyaluronidase: Consensus Recommendations. *Aesthet Surg J.* 2015;35(7):844-9.

CPC-EM Capsule

What do we already know about this clinical entity?

Vascular occlusion is a rare but serious complication of intradermal filler injections that can rapidly lead to tissue necrosis if not identified and treated quickly.

What is the major impact of the image(s)?

As intradermal filler injections are becoming more readily available, it is important to recognize the clinical features of vascular occlusion.

How might this improve emergency medicine practice?

Keep vascular occlusion high on the differential in patients presenting after filler injection. Consider treatment with intradermal hyaluronidase, topical nitroglycerin, and oral aspirin.

Adult Male with Traumatic Eye Pain and Swelling

Marc Leshner, MD
 Ryan Gibbons, MD
 Thomas Costantino, MD

Lewis Katz School of Medicine at Temple University, Department of Emergency
 Medicine, Philadelphia, Pennsylvania

Section Editor: Rick A. McPheeters, DO

Submission history: Submitted October 23, 2017; Revision received February 3, 2018; Accepted February 9, 2018

Electronically published April 5, 2018

Full text available through open access at http://escholarship.org/uc/uciem_cpccem

DOI: 10.5811/cpcem.2018.2.36857

[Clin Pract Cases Emerg Med. 2018;2(2):169-170.]

Case Presentation

A 28-year-old male, presented to the emergency department following assault with a fist to the left eye. The patient complained of pain and blurry vision but denied diplopia. Physical examination was significant for left-sided periorbital ecchymosis with a subconjunctival hemorrhage. Both pupils were equal and reactive to light. Visual acuity was 20/30 in the right eye and 20/20 in the left. Eye and intraocular pressures measured 13 and 17 respectively. No proptosis was observed. Point-of-care ocular ultrasound was performed followed by computed tomography (CT) maxillofacial without contrast (Images 1 and 2 respectively).

Diagnosis

The patient was found to have a left retrobulbar hematoma (RBH) that was diagnosed immediately by performing point-of-care ocular ultrasound. This was confirmed with CT imaging. Image 1 demonstrates a left orbital ultrasound with hypoechoic material within the retrobulbar space suggestive of a RBH.¹ Image 2 illustrates an intraconal hematoma and thickening of the optic nerve complex with proptosis, characteristic of a RBH.²

RBH is a rapidly progressing ocular emergency that can lead to permanent vision loss.³ The accumulation of blood in the retrobulbar space can lead to an orbital compartment syndrome causing compressive ischemia to the optic nerve that can lead to blindness if prompt lateral canthotomy is not performed.⁴ Diagnosis of RBH is challenging, but clinical clues include severe pain, proptosis, vision loss and an afferent pupillary defect.³ Although the condition has not been studied clinically, animal and cadaver research suggests ultrasound has a high sensitivity and specificity for the diagnosis of RBH.^{4,5}

In the case described above, the clinical history was concerning for RBH, and an immediate point-of-care ocular ultrasound confirmed our suspicion. Notably, the patient did not demonstrate evidence of globe rupture, which would be a

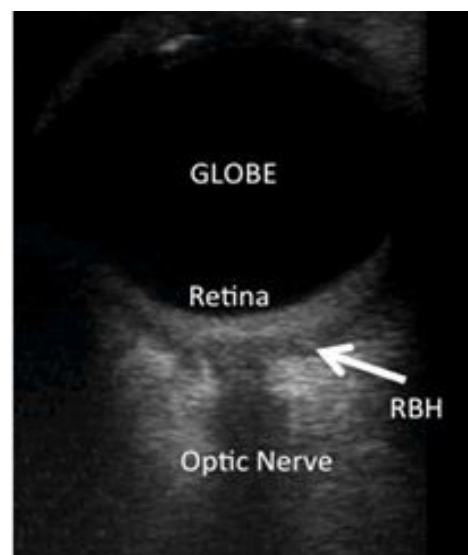


Image 1. Point-of-care ultrasound, transverse view, of the left orbit using a linear probe demonstrating a RBH (arrow). RBH, retrobulbar hematoma.

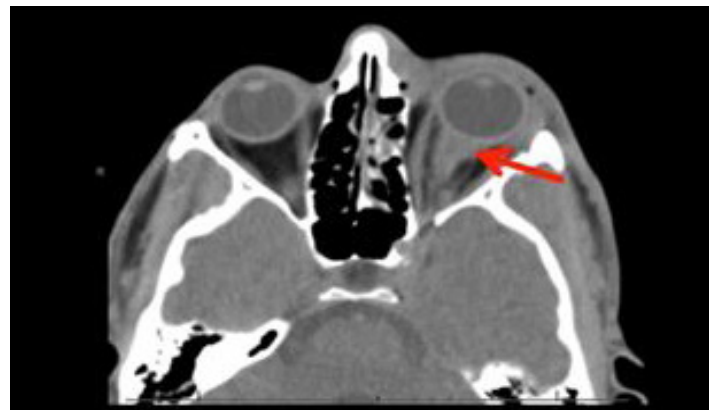


Image 2. Computed tomography maxillofacial without contrast demonstrating an intraconal hematoma (red arrow), thickening of the optic nerve with proptosis

contraindication of ocular ultrasound. An emergent canthotomy was deferred for ophthalmology given the normal intraocular pressure in the left eye. This case highlights that in select patients with suspected RBH, point-of-care ocular ultrasound can expedite the diagnosis without the delay of CT, and thus timely ocular decompression can be performed to prevent vision loss.

Documented patient informed consent and/or Institutional Review Board approval has been obtained and filed for publication of this case report.

Address for Correspondence: Marc Leshner, MD, Temple University Hospital, Department of Emergency Medicine, 10th Floor, Jones Hall 1316 W. Ontario Street Philadelphia, PA 19140. Email: marc.leshner@tuhs.temple.edu.

Conflicts of Interest: By the CPC-EM article submission agreement, all authors are required to disclose all affiliations, funding sources and financial or management relationships that could be perceived as potential sources of bias. The authors disclosed none.

Copyright: © 2018 Leshner et al. This is an open access article distributed in accordance with the terms of the Creative Commons Attribution (CC BY 4.0) License. See: <http://creativecommons.org/licenses/by/4.0/>

CPC-EM Capsule

What do we already know about this clinical entity?

Retrobulbar hematoma (RBH) is a rapidly progressing ocular emergency that is often seen in the setting of ocular trauma. It can lead to permanent vision loss if prompt lateral canthotomy is not performed.

What makes this presentation of disease reportable?

While RBH is a rare clinical entity, emergency physicians need to be comfortable with diagnosing and treating this condition.

What is the major learning point?

Point-of-care ocular ultrasound is a quick and accurate imaging modality to diagnose RBH.

How might this improve emergency medicine practice?

In cases where it is suspected, RBH can be diagnosed via point-of-care ocular ultrasound eliminating the need for unnecessary and time-consuming computed tomography, thus, allowing for more rapid ocular decompression.

REFERENCES

1. Blaivas M. Bedside emergency department ultrasonography in the evaluation of ocular pathology. *Acad Emerg Med.* 2000;7(8):947-50.
2. Cobb SR, Yeakley JW, Lee KF, et al. Computed tomographic evaluation of ocular trauma. *Comput Radiol.* 1985;9(1):1-10.
3. Bailey WK, Kuo PC, Evans LS. Diagnosis and treatment of retrobulbar hemorrhage. *J Oral Maxillofac Surg.* 1993;51(7):780-2.
4. Gerbino G, Ramieri GA, Nasi A. Diagnosis and treatment of retrobulbar haematomas following blunt orbital trauma: a description of eight cases. *Int J Oral Maxillofac Surg.* 2005; 34(2):127-31.
5. Estevez A, Deutch J, Sturmman K, et al. Ultrasonographic evaluation of retrobulbar hematoma in bovine orbits. *Ann Emerg Med.* 2000;36(Supplement 21):4.

An Unusual Cause of Acute Urinary Retention

Adam J. Smith, MD
Paul Blackburn, DO

Maricopa Integrated Health System, Maricopa Medical Center, Emergency Medicine
Residency, Phoenix, Arizona

Section Editor: Rick A. McPheeters, DO

Submission history: Submitted December 8, 2017; Revision received February 16, 2018; Accepted February 28, 2018

Electronically published April 5, 2018

Full text available through open access at http://escholarship.org/uc/uciem_cpccem

DOI: 10.5811/cpcem.2018.2.37247

[Clin Pract Cases Emerg Med. 2018;2(2):171-172.]

CASE PRESENTATION

A 29-year-old female with a past medical history of constipation and anxiety, noted during previous pregnancies, presented with a chief complaint of acute urinary retention. She was not taking any medications and had no prior history of abdominal surgeries. She did report three previously uncomplicated pregnancies. Physical exam was significant for visible, firm suprapubic and right lower abdominal masses. Point-of-care ultrasonography demonstrated one liter of retained urine. An indwelling urinary catheter was inserted. The patient agreed to computed tomography (CT) for further evaluation (Images 1, 2, and 3).

DISCUSSION

Acute Urinary Retention Secondary to Chronic Constipation

CT imaging demonstrated severe idiopathic constipation causing megacolon and displacement of the bladder resulting in outlet obstruction. Acute urinary retention is uncommon in women with a prevalence of 1:100,000 women per year.^{1,2} Differential includes outflow obstruction, neurologic impairment, detrusor muscle weakness, medications (especially anticholinergics), and infection. Obstruction in women is generally secondary to anatomic distortion, including pelvic organ prolapse, pelvic masses, or urethral diverticulum.^{1,3}

Constipation is an atypical cause of acute urinary retention in adults and is rarely mentioned in the literature.⁴ A sigmoid colon diameter of 6.5 cm at the pelvic brim is commonly used as a discriminating point for diagnosing megacolon.⁵ Treatment for severe chronic constipation and fecal impaction typically includes manual disimpaction and enemas, or oral solutions containing polyethylene glycol. Patients should receive Gastroenterology referral for colonic transit and motility studies. A patient may require partial colectomy if conservative medical therapy fails.^{6,7,8,9}

Documented patient informed consent and/or Institutional Review Board approval has been obtained and filed for publication of this case report.

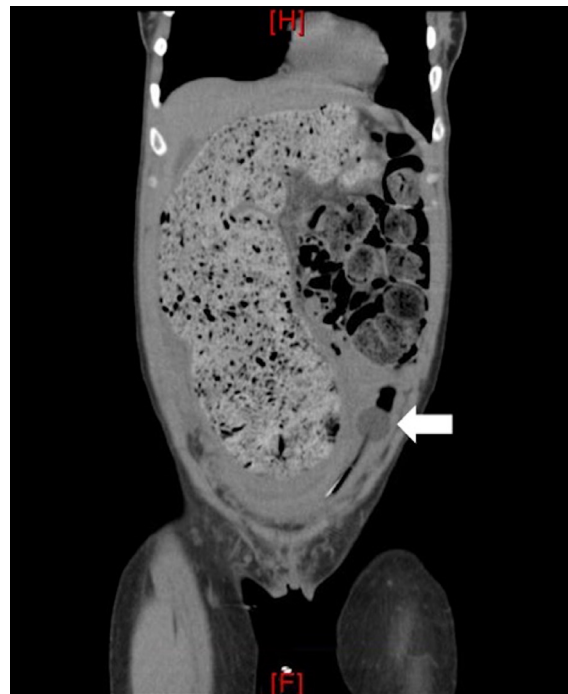


Image 1. Computed tomography of the abdomen in the coronal plane demonstrating significant stool burden with displacement of the bladder to the left as noted by the urinary catheter bulb (arrow).

Address for Correspondence: Adam J. Smith, MD, Maricopa Integrated Health System, Maricopa Medical Center, Department of Emergency Medicine, 2601 E Roosevelt St. Phoenix, AZ 85008. Email: Adam.Smith@MIHS.org.

Conflicts of Interest: By the CPC-EM article submission agreement, all authors are required to disclose all affiliations, funding sources and financial or management relationships that could be perceived as potential sources of bias. The authors disclosed none.

Copyright: © 2018 Smith et al. This is an open access article distributed in accordance with the terms of the Creative Commons Attribution (CC BY 4.0) License. See: <http://creativecommons.org/licenses/by/4.0/>

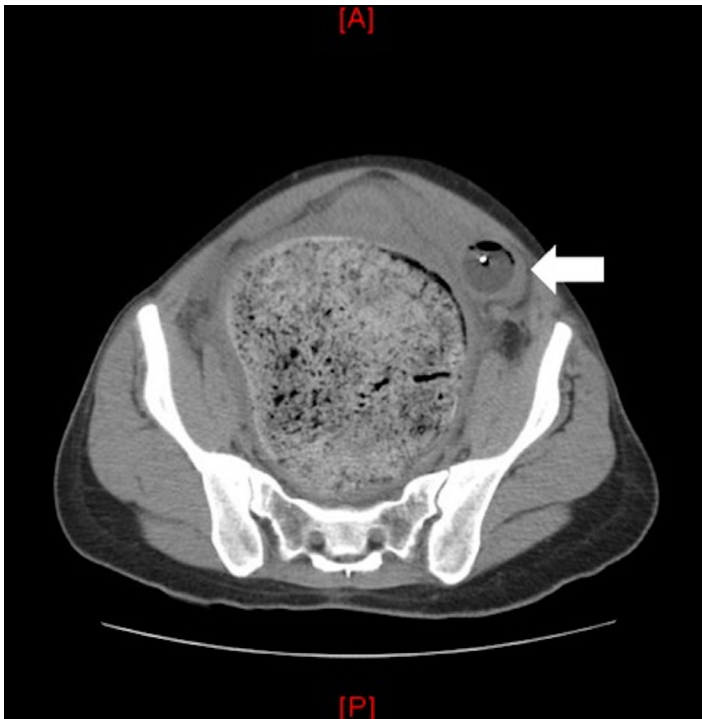


Image 2. Computed tomography of the abdomen in the axial plane demonstrating stool burden causing significant displacement of the bladder as noted by the urinary catheter (arrow).

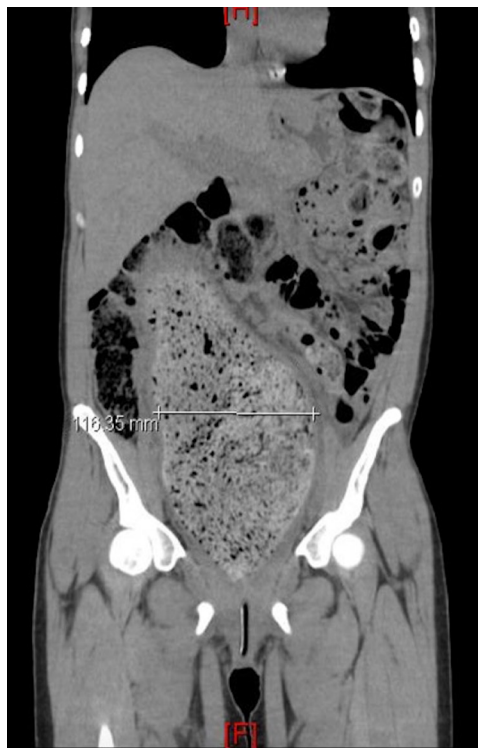

Image 3. Computed tomography of the abdomen in the coronal plane demonstrating a colonic diameter of 116.35 mm at the level of the pelvic brim.

CPC-EM Capsule

What do we already know about this clinical entity?

Acute urinary retention in women is most commonly secondary to anatomic distortion but may also be caused by medications, infection, and neurologic disease.

What is the major impact of the image(s)?
These images highlight the severity of the anatomic distortion that results from severe chronic constipation.

How might this improve emergency medicine practice?

Consider close follow up or admission for surgical and gastroenterology evaluation and to assess for other underlying causes and resolution of obstruction.

REFERENCES

1. Ramsey S, Palmer M. The management of female urinary retention. *Int Urol Nephrol.* 2006;38(3–4):533–5.
2. Klarskov P, Andersen JT, Asmussen CF, et al. Acute urinary retention in women: a prospective study of 18 consecutive cases. *Scand J Urol Nephrol.* 1987;21(1):29–31.
3. Selius BA, Subedi R. Urinary retention in adults: diagnosis and initial management. *Am Fam Physician.* 2008;77(5):643–50.
4. Traslaviña GA, Del Ciampo LA, Ferraz IS. Acute urinary retention in a pre-school girl with constipation. *Rev Paul Pediatr.* 2015;33(4):488–92.
5. Preston DM, Lennard-Jones JE, Thomas BM. Towards a radiologic definition of idiopathic megacolon. *Gastrointest Radiol.* 1985;10(2):167–9.
6. Dipalma JA, Cleveland MV, McGowan J, et al. A randomized, multicenter, placebo-controlled trial of polyethylene glycol laxative for chronic treatment of chronic constipation. *Am J Gastroenterol.* 2007;102(7):1436–41.
7. Brandt LJ, Boley SJ. AGA technical review on intestinal ischemia. *Gastroenterology.* 2000;118(5):954–68.
8. Hernu R, Cour M, Wallet F, Argaud L. Threatening fecal impaction. *J Emerg Med.* 2017;52(1):13–5.
9. Khawaja MR, Akhavan N, Chiorean M. Chronic constipation with megacolon. *J Gen Intern Med.* 2011;26(8):938.

An Unexpected Cause of Persistent Coughing

Melissa Myers, MD
Jared Cohen, MD

San Antonio Military Medical Center, Department of Emergency Medicine, San Antonio, Texas

Section Editor: Rick A. McPheeters, DO

Submission history: Submitted January 3, 2018; Revision received February 21, 2018; Accepted February 27, 2018

Electronically published April 5, 2018

Full text available through open access at http://escholarship.org/uc/uciem_cpccm

DOI: 10.5811/cpcem.2018.2.37443

[Clin Pract Cases Emerg Med. 2018;2(2):173-174.]

CASE PRESENTATION

A 35-year-old, otherwise-healthy male presented to a military emergency department complaining of persistent cough. He had been treated for community-acquired pneumonia three weeks prior to this presentation with a five-day course of azithromycin. His vital signs were stable with no fever, hypoxemia or respiratory distress. His physical exam was unremarkable with no focal lung findings. Chest radiograph (Image 1) was performed and was concerning for consolidation or effusion. Pulmonary point-of-care ultrasound (POCUS) was then performed with results seen in Image 2 and video. POCUS showed a loculated effusion consistent with empyema. Chest computed tomography (Image 3) showed a large, lung abscess. The patient was admitted to the hospital and underwent video-assisted thoracoscopic surgery for evacuation of the lung abscess caused by pan-sensitive *streptococcus pneumoniae*. He ultimately recovered and was discharged without complications.

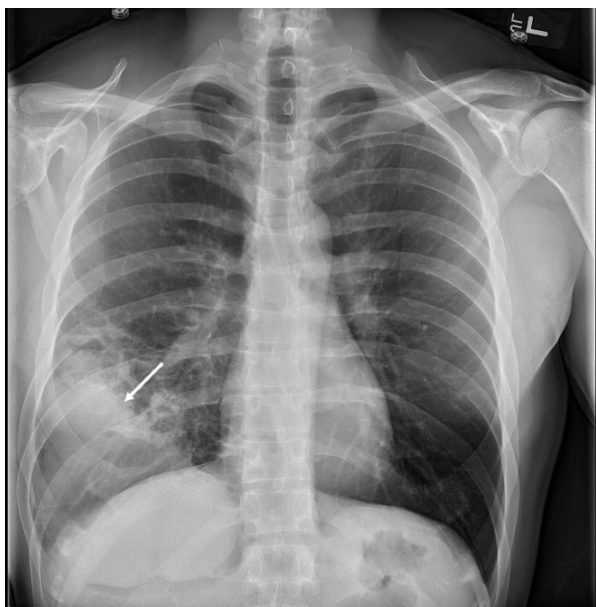


Image 1. Chest radiograph demonstrating a consolidation (arrow).

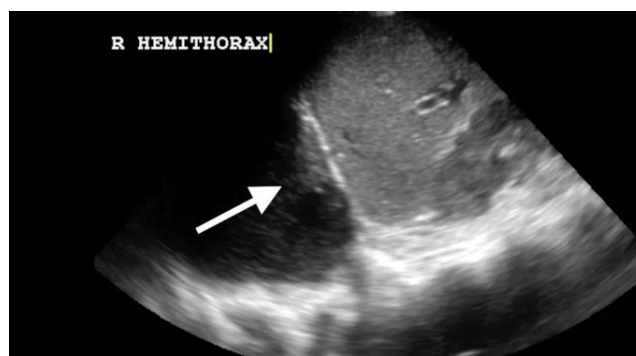

Image 2. Thoracic point-of-care ultrasound using 4-megahertz curvilinear probe, demonstrating an empyema in a coronal view (arrow). See video.

DIAGNOSIS

Pulmonary POCUS can be used at the bedside to diagnose and describe pleural effusions. The exam is performed using a low-frequency probe placed in the posterior axillary line in a longitudinal view. Fluid collections will be visible directly above the diaphragm. Transudates will appear anechoic and simple on ultrasound. A more complex appearance with complex septations or heterogenous appearance indicates the presence of an exudate.¹ Empyema may be further distinguished by a “snow flurry” or “Swiss cheese” appearance.² Sensitivity of lung POCUS for pleural effusion is greater than 95%, compared to a 65% sensitivity for chest radiography.³ POCUS offers a rapid, sensitive method to evaluate for pulmonary pathology. Combining ultrasound findings with history and physical exam can increase physician sensitivity for common diagnoses and improve early diagnosis and treatment.

Video. Thoracic point-of-care ultrasound using 4-megahertz curvilinear probe, demonstrating an empyema in a coronal view (arrow).

Documented patient informed consent and/or Institutional Review Board approval has been obtained and filed for publication of this case report.

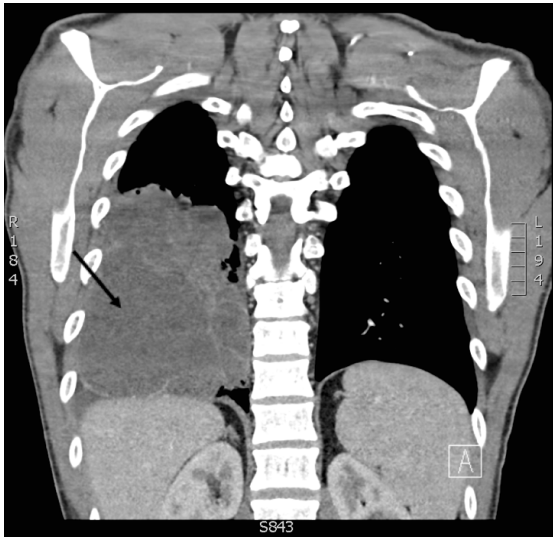


Image 3. Chest computed tomography demonstrating a right-sided pulmonary abscess (arrow).

Address for Correspondence: Melissa Myers, MD, San Antonio Military Medical Center, 3551 Roger Brooke Drive, San Antonio, Texas 78129. Email: Melissa.a.myers60.mil@mail.mil.

Conflicts of Interest: By the CPC-EM article submission agreement, all authors are required to disclose all affiliations, funding sources and financial or management relationships that could be perceived as potential sources of bias. The authors disclosed none. The views expressed herein are those of the authors and do not reflect the policy or position of San Antonio Military Medical Center, the Department of the Army, the Department of the Air Force and the Department of Defense or the U.S. Government.

Copyright: © 2018 Myers et al. This is an open access article distributed in accordance with the terms of the Creative Commons Attribution (CC BY 4.0) License. See: <http://creativecommons.org/licenses/by/4.0/>

CPC-EM Capsule

What do we already know about this clinical entity?

An empyema is a complication of pneumonia where the pleural cavity is filled with a purulent effusion.

What is the major impact of the image(s)?

Pulmonary point-of-care ultrasound can improve the early diagnosis and differentiation of pleural effusions when compared to chest radiography.

How might this improve emergency medicine practice?

Incorporating point-of-care ultrasound early in the management of patients with abnormal lung findings may improve care by improving diagnostic accuracy.

REFERENCES

1. Turner JP, Dankoff J. Thoracic ultrasound. *Emerg Med Clin North Am.* 2012;30(2):451-73.
2. Xirouchaki N, Magkanas E, Vaporidi K, et al. Lung ultrasound in critically ill patients: comparison with bedside chest radiography. *Intensive Care Med.* 2011;37(9):1488-93.
3. Yang PC, Luh KT, Chang DB, et al. Value of sonography in determining the nature of pleural effusion: analysis of 320 cases. *Am J Roentgenol.* 1992;159(1):29-33.

Adolescent with Stroke-like Symptoms

Joseph C. Mazzei, DO
Stephanie Louka, MD
Ravindra Gopaul, MD
Lindsay Taylor, MD

Virginia Commonwealth University, Department of Emergency Medicine, Richmond, Virginia

Section Editor: Rick A. McPheeters, DO

Submission history: Submitted October 26, 2017; Revision received ; Accepted February 28, 2018

Electronically published April 5, 2018

Full text available through open access at http://escholarship.org/uc/uciem_cpccm

DOI: 10.5811/cpcem.2018.2.36886

[Clin Pract Cases Emerg Med. 2018;2(2):175-176.]

CASE PRESENTATION

A 16-year-old male presented to the emergency department (ED) with left-sided weakness. He described having a headache with dizziness for seven days prior to presenting with new onset weakness. The patient was from Central America with no known medical history and was unvaccinated. The examination was significant for flaccid paralysis with decreased sensation in the left upper and lower extremities, plus a left-sided facial droop. The cardiac examination revealed a 2/6 diastolic murmur, loudest at the left sternal border. A point-of-care ultrasound performed in the ED demonstrated a left atrial mass swinging into the left ventricle during diastole (Images 1 and 2).

DISCUSSION

Computed tomography angiography of the head led to a diagnosis of left atrial myxoma with embolism resulting

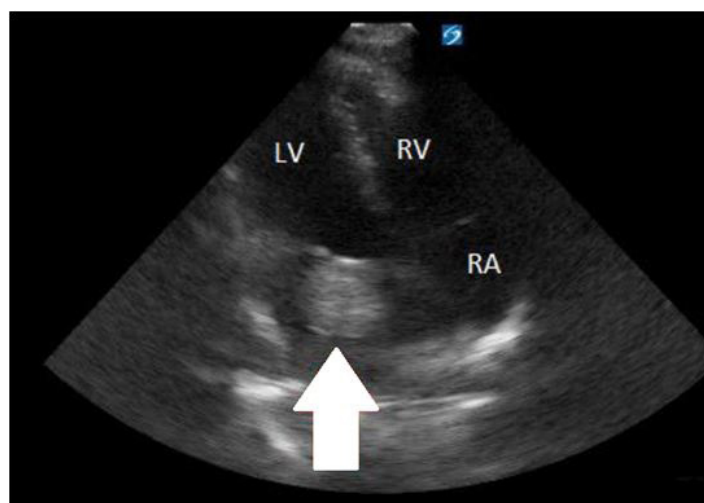


Image 2. Apical four-chamber view of left atrial myxoma (arrow).

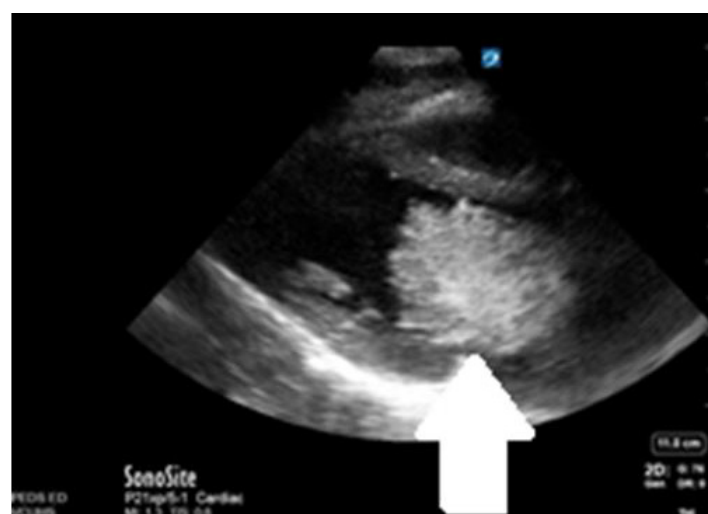


Image 1. Parasternal long-axis view of left atrial myxoma (arrow).

in non-hemorrhagic occlusion of the right middle cerebral artery (Image 3). After initial stabilization, the patient was taken to surgery for removal of a 52mm x 42mm benign, left atrial myxoma. Two months after presentation the patient had regained approximately 70% of his strength and full sensation.

Cardiac tumors are a rare diagnosis, with a reported incidence of 0.01-0.02%.¹ The surface of these tumors is friable, which can lead to embolization in one-third of patients, resulting in devastating neurovascular injury and often sudden death.² Intracardiac tumor diagnosis with transthoracic echocardiogram has a 95.2% detection rate.³ Given the high risk of morbidity and mortality, expeditious diagnosis and surgical resection is considered standard of care. Point-of-care ultrasound, especially with a critically ill patient like ours, has proven to be an invaluable tool in improving both immediate patient care and long-term prognosis.

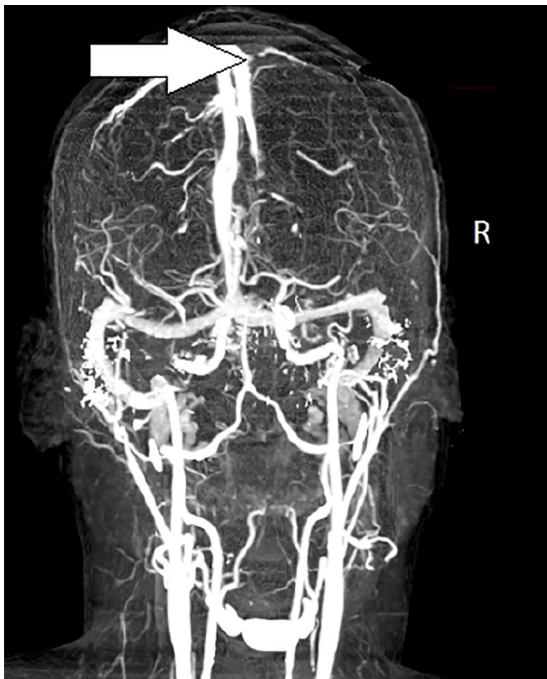

Image 3. Computed tomography angiography head, coronal view demonstrating right middle cerebral artery (R-MCA) filling defect (arrow).

Documented patient informed consent and/or Institutional Review Board approval has been obtained and filed for publication of this case report.

Address for Correspondence: Joseph C. Mazzei, Virginia Commonwealth University, Department of Emergency Medicine, 57 East Clay Street, VA 23219. Email: Joseph.Mazzei@vcuhealth.org.

Conflicts of Interest: By the CPC-EM article submission agreement, all authors are required to disclose all affiliations, funding sources and financial or management relationships that could be perceived as potential sources of bias. The authors disclosed none.

Copyright: © 2018 Mazzei et al. This is an open access article distributed in accordance with the terms of the Creative Commons Attribution (CC BY 4.0) License. See: <http://creativecommons.org/licenses/by/4.0/>

CPC-EM Capsule

What do we already know about this clinical entity?

Cardiac myxoma is a rare, benign tumor of the heart that predisposes patients to embolic phenomena involving cerebral or mesenteric arteries typically requiring surgical repair.

What is the major impact of the images?

Point-of-care ultrasound (POCUS) visualization of a left atrial myxoma, and subsequent computed tomography of a cerebral artery-filling defect, solidified our diagnosis of tissue embolus, which explained the patient's constellation of symptoms and led to timely surgical consultation

How might this improve emergency medicine practice?

This case highlights the utility of POCUS in the emergency department to quickly identify life-threatening ailments that may otherwise go undiagnosed.

REFERENCES

1. MacGowan SW, Sidhu P, Aherne T, et al. Atrial myxoma: national incidence, diagnosis and surgical management. *Ir J Med Sci.* 1993;162(6):223–6.
2. Sarjeant JM, Butany J, Cusimano RJ. Cancer of the heart: epidemiology and management of primary tumors and metastases. *Am J Cardiovasc Drugs.* 2003;3(6):407–21.
3. Engberding R, Daniel WG, Erbel R, et al. Diagnosis of heart tumours by transoesophageal echocardiography: a multicentre study in 154 patients. European Cooperative Study Group. *Eur Heart J.* 1993;14(9):1223–8.

Temporary Tracheal Compression by Dilated Functionally Normal Esophagus

Tatsuki Sengoku, MD
Tomohiro Sonoo, MD
Kei Kira, MD
Yuji Takahashi, MD
Hideki Hashimoto, MD
Kensuke Nakamura, MD, PhD

Hitachi General Hospital, Emergency Medicine and Critical Care Medicine Department,
Jonancho, Hitachi-shi, Ibaraki, Japan

Section Editor: Rick A. McPheeters, DO

Submission history: Submitted January 10, 2018; Revision received March 12, 2018; Accepted March 21, 2018

Electronically published April 18, 2018

Full text available through open access at http://escholarship.org/uc/uciem_cpem

DOI: 10.5811/cpcem.2018.3.37534

[Clin Pract Cases Emerg Med. 2018;2(2):177–178.]

CASE PRESENTATION

An 80-year-old woman with a medical history of diabetes and duodenal cancer presented to our emergency department (ED) complaining of sudden severe dyspnea after vomiting. She was alert and oriented on arrival, but showed tachypnea and poor oxygenation. Inspiratory stridor was evident. A computed tomography (CT) revealed a dilated esophagus with food bolus and intraluminal air compressing the trachea at the level of the sternoclavicular joint (Image 1). Her symptoms improved after 30 minutes of rest and oxygen administration; however, she was admitted for observation. Repeat CT (Image 2) and esophagography (Image 3) were performed six days later and revealed no abnormality or evidence of esophageal dysfunction. The patient's repeat CT, esophagography, and esophagogastroscope revealed no abnormality or evidence of hiatal herniation or esophageal achalasia.

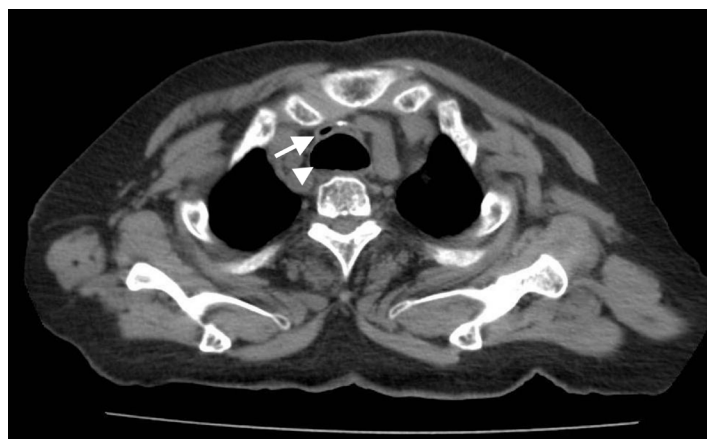

Image 1. Compressed trachea (arrow) by dilated esophagus (arrowhead) at the level of the sternoclavicular joint.

DISCUSSION

This case presented reversible, severe tracheal compression by dilated esophagus with no functional abnormality. Cases of tracheal compression by dilated esophagus with structural diseases such as hiatal herniation¹ or functional diseases such as esophageal achalasia² have been reported. Dyspnea caused by esophageal achalasia is reportedly common in elderly women, who usually recover after treatment for esophageal achalasia.² Unfortunately, functional evaluation of the esophagus is not performed in all cases. Some cases improve without treatment.³ Results obtained in this case suggest that a functionally normal esophagus can sometimes become sufficiently dilated to compress the upper airway, causing severe dyspnea. Spontaneous esophageal dilation is a rare cause of tracheal obstruction, but it is worth considering when no other cause is evident.

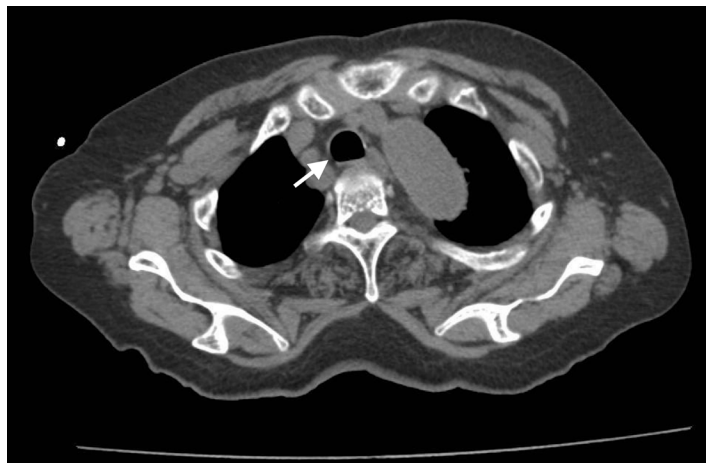

Image 2. Repeated computed tomography with normal trachea (arrow).

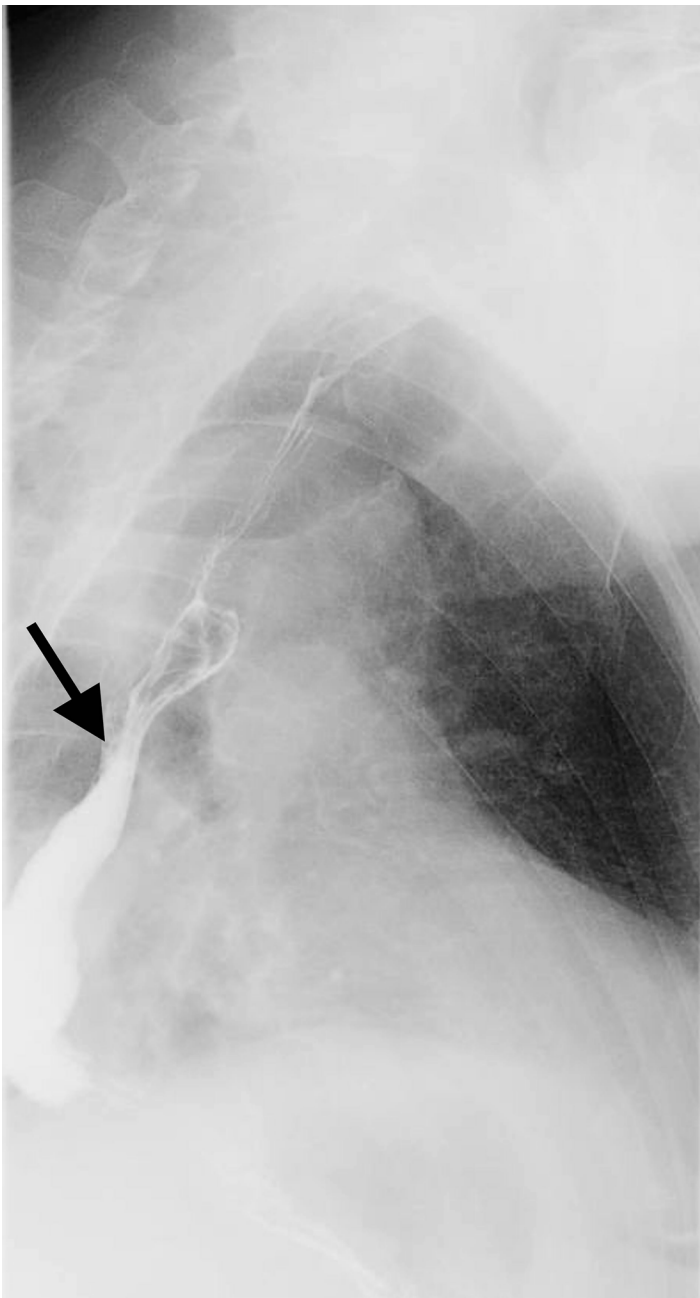


Image 3. Esophagography revealed functionally normal esophagus (arrow).

Documented patient informed consent and/or Institutional Review Board approval has been obtained and filed for publication of this case report.

CPC-EM Capsule

What do we already know about this clinical entity?
Cases of tracheal compression by dilated esophagus with hiatal herniation or esophageal achalasia have been reported.

What is the major impact of the image(s)?
Reversible tracheal compression by dilated functionally normal esophagus was evident on the first CT.

How might this improve emergency medicine practice?
Spontaneous esophageal dilation is rare, but worth considering when we see the ED patients complaining of sudden severe dyspnea.

Address for Correspondence: Tomohiro Sono MD, Hitachi General Hospital, Emergency Medicine and Critical Care Medicine Department, 2-1-1 Jonancho, Hitachi-shi, Ibaraki, Japan, 3170077. Email: tomohiro.sono.st@hitachi.com.

Conflicts of Interest: By the CPC-EM article submission agreement, all authors are required to disclose all affiliations, funding sources and financial or management relationships that could be perceived as potential sources of bias. The authors disclosed none.

Copyright: © 2018 Sengoku et al. This is an open access article distributed in accordance with the terms of the Creative Commons Attribution ([CC BY 4.0](http://creativecommons.org/licenses/by/4.0/)) License. See: <http://creativecommons.org/licenses/by/4.0/>

REFERENCES

1. Miyake Y, Fujimoto T, Ikenaga M, et al. A Case of Large Sliding Hiatal Hernia of the Esophagus Associated with Dyspnea. *J Jpn Clin Surg.* 1997;58(5):1014–7.
2. Hatakeyama J, Takei T, Ito T, et al. Airway obstruction in a patient with achalasia: a case report and a review of the literature. *JAAM.* 2010;21(7):377–82.
3. Westbrook JL. Oesophageal achalasia causing respiratory obstruction. *Anaesthesia.* 1992;47(1):38–40.

Atypical Presentation of Hand, Foot, and Mouth Disease in an Adult

Demis N. Lipe, MD
Susan Affleck, FNP

Martin Army Community Hospital, Department of Emergency Medicine, Fort Benning, Georgia

Section Editor: Rick A. McPheeters, DO

Submission history: Submitted January 20, 2018; Revision received February 28, 2018; Accepted March 7, 2018

Electronically published April 17, 2018

Full text available through open access at http://escholarship.org/uc/uciem_cpccem

DOI: 10.5811/cpcem.2018.3.37686

[Clin Pract Cases Emerg Med. 2018;2(2):179–180.]

CASE PRESENTATION

A 21-year-old, active-duty military male presented to the emergency department (ED) with three days of fever of 103°F, fatigue, rash and sore throat. The rash was especially painful on his hands and feet. The patient's history was significant for having spent a week in a field training exercise in a wooded area. Vital signs were normal. Examination revealed purpuric, maculo-papular lesions and erosions of the feet (Image 1A and 2A) and hands extending onto his forearms (Image 1B). He also had crusted erosions periorally and soft palate petechiae (Image 1C). Additionally, there were crusted lesions on the head extending into the neck and torso (Image 2B and 2C).

Initial workup included a rapid antigen streptococcal test, rapid plasma reagin, Rocky Mountain spotted fever (RMSF), coxsackievirus serologies, complete blood count and coagulation studies. The laboratory testing resulted during his ED stay was normal. The RMSF and coxsackievirus serology results returned within the week. The patient was discharged

from the ED with a presumptive diagnosis of RMSF on a doxycycline regimen.

DIAGNOSIS

The patient was later diagnosed with hand, foot, and mouth disease (HFMD) after serology testing was positive for coxsackievirus A6 (CVA6) and the rest of the workup was normal. HFMD typically occurs in children, and historically adults have been asymptomatic.^{1,2} With a recent increase in emergence of CVA6, several outbreaks have been reported worldwide.¹⁻⁴

Atypical HFMD presents with more variable and severe manifestation such as diffuse rash, purpuric lesions and adult-age predilection.^{1,4} Transmission can occur via respiratory secretions, oral-oral, fecal-oral, or contact with fomites.^{1,2,4} Sharing close living quarters makes military trainees more susceptible to being infected with the virus.¹ Complications, although rare, can include onychomadesis, bacterial skin

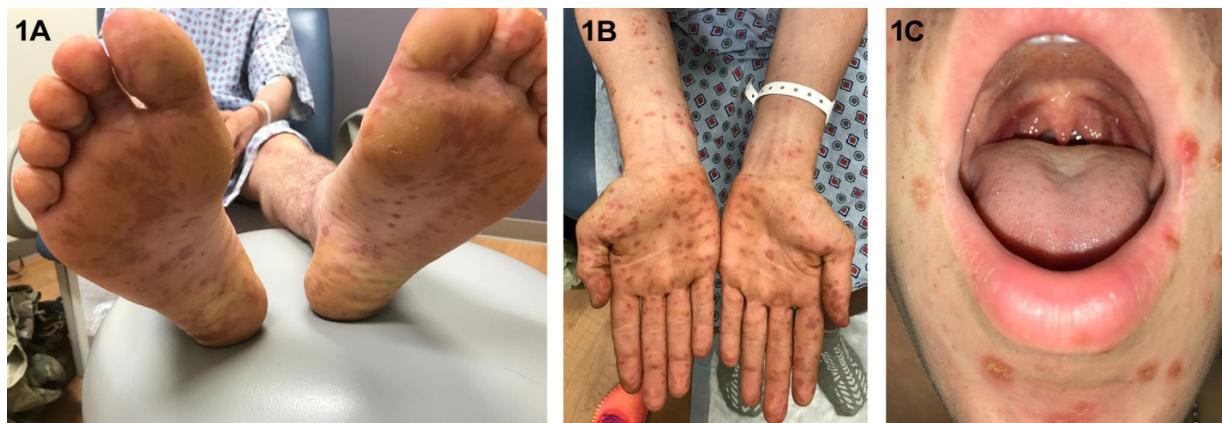

Image 1. Dermatologic manifestation of atypical hand, foot, and mouth disease, illustrating A) ill-defined, erythematous to violaceous lesions on plantar surface of feet; B) discrete, violaceous lesions extending from palmar surface of hands onto the flexor aspects of the upper extremities; and C) perioral, crusted lesions.

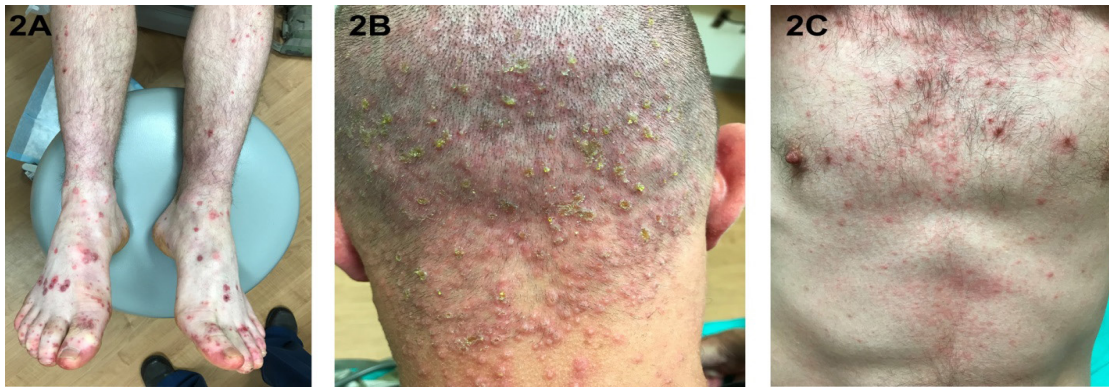


Image 2. Atypical manifestation of hand, foot, and mouth disease demonstrating A) discrete, purpuric and hemorrhagic lesions of the lower extremities; B) grouped papulo-vesicular lesions with superimposed bacterial colonization; and C) extensive involvement of the torso.

superinfection, encephalitis and aseptic meningitis.² The patient continued his doxycycline regimen for the bacterial superinfection and recovered without complications.

Documented patient informed consent and/or Institutional Review Board approval has been obtained and filed for publication of this case report.

Address for Correspondence: Demis N. Lipe, MD, Martin Army Community Hospital, 6600 Van Aalst Blvd., Fort Benning, GA 31905. Email: demis.ros@gmail.com.

Conflicts of Interest: By the CPC-EM article submission agreement, all authors are required to disclose all affiliations, funding sources and financial or management relationships that could be perceived as potential sources of bias. The authors disclosed none. The views expressed in this article are those of the author(s) and do not reflect the official policy of the Department of Army, Department of Defense, or U.S. Government.

Copyright: © 2018 Lipe et al. This is an open access article distributed in accordance with the terms of the Creative Commons Attribution (CC BY 4.0) License. See: <http://creativecommons.org/licenses/by/4.0/>

REFERENCES

1. Banta J, Lenz B, Pawlak M, et al. Notes from the field: outbreak of hand, foot, and mouth disease caused by coxsackievirus A6 among basic military trainees – Texas, 2015. *MMWR Morb Mortal Wkly Rep.* 2016;65(26):678-80.
2. Hand, Foot, and Mouth Disease (HFMD). Centers for Disease Control and Prevention. 2017. Available at: <https://www.cdc.gov/hand-foot-mouth/about/signs-symptoms.html>. Accessed on February 28, 2018.
3. Bian L, Wang Y, Yao X, et al. Coxsackievirus A6: a new emerging

CPC-EM Capsule

What do we already know about this clinical entity?
Hand, foot, and mouth disease (HFMD) is a common viral illness usually affecting infants and children. Common manifestations are fever and vesicular rash on the hands, feet and buttocks, along with oral ulcers. Common causes of typical HFMD are coxsackievirus A16 and enterovirus 71.

What is the major impact of the image(s)?
These images show the atypical dermatological manifestation of HFMD in an adult, which includes purpuric lesions and more diffuse involvement.

How might this improve emergency medicine practice?
Emergency physicians need to recognize the atypical presentation in adults and include it in the differential diagnosis of purpuric rash involving the extremities. HFMD treatment is conservative, unlike syphilis, Rocky Mountain spotted fever and even Henoch-Schonlein purpura.

- pathogen causing hand, foot and mouth disease outbreaks worldwide. *Expert Rev Anti Infect Ther.* 2015;13(9):1061-71.
4. Ramirez-Fort MK, Downing C, Doan HQ, et al. Coxsackievirus A6 associated hand, foot and mouth disease in adults: clinical presentation and review of the literature. *J Clin Virol.* 2014;60(4):381-6.



**Professor Series
Department of Emergency Medicine
& Department of Informatics**

The UC Irvine School of Medicine, Department of Emergency Medicine and the Donald Bren School of Information and Computer Sciences, Department of Informatics are seeking applicants for a split faculty position at the Assistant, Associate, or Full Professor level in the Professor Series (Tenure-Track).

Qualified candidates should possess a Ph.D. degree or equivalent. Interested candidates should have demonstrated capabilities for substantial research, excellent teaching, and professional service. The ideal candidate's research would be focused on developing prediction models on disease outbreaks, bringing together research in areas of Emergency Medicine, Public Health, Informatics, and Computer Science/Engineering, and using big data and machine learning/data mining techniques. The incumbent will be expected to perform research and teaching, as well as university and external service.

The University of California, Irvine is consistently ranked as a top ten public university by U.S. News and World Report, and has been identified by the New York Times as No. 1 among U.S. universities that do the most for low-income students. UC Irvine is located in Orange County, four miles from the Pacific Ocean and 45 miles south of Los Angeles. Irvine is one of the safest communities in the U.S. and offers a very pleasant year-round climate, numerous recreational and cultural opportunities, and one of the highest-ranked public school systems in the nation.

Salary and rank will be commensurate with qualifications and experience.

Application Procedure:

Each application must contain: a cover letter, CV, up to three key publications, statements of research and teaching interests, and 3-5 letters of recommendation. A separate statement that addresses past and/or potential contributions to diversity, equity, and inclusion must also be included.

Interested candidates should apply through UC Irvine's Recruit system located at:

<https://recruit.ap.uci.edu/apply/JPF04455>

The position is for appointment July 1, 2018. The review of applications will begin March 26, 2018.

The University of California, Irvine is an Equal Opportunity/Affirmative Action Employer advancing inclusive excellence. All qualified applicants will receive consideration for employment without regard to race, color, religion, sex, sexual orientation, gender identity, national origin, disability, age, protected veteran status, or other protected categories covered by the UC nondiscrimination policy.

WestJEM Integrating Emergency Care
with Population Health

CPCEM Clinical
Practice
& Cases

Call for Reviewers!

Please send your CV and letter of interest to
editor@westjem.org

CPCEM Clinical
Practice
& Cases

CALL FOR SUBMISSIONS

-Patient Care Case Reports

-Images in Emergency Medicine

Fully open-access, peer reviewed,
well indexed: CPC-EM is available
anywhere with an internet
connection at **CPCEM.org**

***Clinical
Practice and
Cases in
Emergency
Medicine*** is an
internationally
recognized
journal
affiliated with
the MEDLINE-
indexed
***Western
Journal of
Emergency
Medicine***

**CPC-EM encourages submissions from junior authors and
countries with developing emergency medicine programs**

**JOIN
CAL/AAEM!**

*Championing
individual physician rights
and workplace fairness*

BENEFITS

- Western Journal of Emergency Medicine Subscription
- CAL/AAEM News Service email updates
- Discounted AAEM pre-conference fees
- And more!

CAL/AAEM NEWS SERVICE

- Healthcare industry news
- Public policy
- Government issues
- Legal cases and court decisions



In collaboration with our official journal

WestJEM Integrating Emergency Care
with Population Health




FACEBOOK.COM/CALAAEM



FOLLOW US @CALAAEM

[HTTP://WWW.CALAAEM.ORG](http://www.calaaem.org)



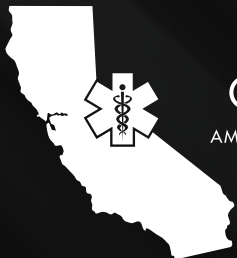ADVANCED >

**RESIDENTS & MED STUDENTS,
THIS ONE'S FOR YOU!**

> CALIFORNIA ACEP'S ANNUAL CONFERENCE 2018

Friday, September 7, 2018

Marriott, Marina Del Rey, CA



CALIFORNIA ACEP
AMERICAN COLLEGE OF EMERGENCY PHYSICIANS

IN PARTNERSHIP WITH

