

UC Davis

Dermatology Online Journal

Title

Phacomatosis cesiomarmorata with hypospadias and phacomatosis cesioflammea with Sturge-Weber syndrome, Klippel-Trenaunay syndrome and aplasia of veins -- case reports with rare associations

Permalink

<https://escholarship.org/uc/item/0r26h8pm>

Journal

Dermatology Online Journal, 21(9)

Authors

Kaur, Tejinder
Sharma, Nidhi
Sethi, Anisha
et al.

Publication Date

2015

DOI

10.5070/D3219028691

Copyright Information

Copyright 2015 by the author(s). This work is made available under the terms of a Creative Commons Attribution-NonCommercial-NoDerivatives License, available at <https://creativecommons.org/licenses/by-nc-nd/4.0/>

Peer reviewed

Case presentation

Phacomatosis cesiomarmorata with hypospadias and phacomatosis cesioflammea with Sturge-Weber syndrome, Klippel-Trenaunay syndrome and aplasia of veins -- case reports with rare associations

Tejinder Kaur, Nidhi Sharma, Anisha Sethi, Shitij Kooner, Harmeet Banger

Dermatology Online Journal 21 (9): 6

Government Medical College, Amritsar, Punjab, India

Correspondence:

Nidhi Sharma
Government Medical College
Amritsar, Punjab, India
drnidhisharma@hotmail.com

Abstract

Phacomatosis pigmentovascularis (PPV) is a rare genodermatosis characterized by the co-existence of an extensive vascular and a pigmentary nevus with or without extracutaneous manifestations. We report two such rare cases. The first is a 3-year-old boy exhibiting a rare association of cutis marmorata telangiectatica congenita with aberrant dermal melanocytosis along with hypospadias and melanosis oculi (traditionally classified as PPV type Vb or phacomatosis cesiomarmorata - Happle's classification). The other patient is a 5-year-old boy with Sturge-Weber syndrome, Klippel-Trenaunay syndrome, aplasia of iliac, femoral, and popliteal veins and congenital heart disease, associated with aberrant dermal melanocytosis and melanosis oculi (also classified as PPV type IIb or phacomatosis cesioflammea). These sporadic cases display a unique constellation of additional, previously unreported systemic associations, which will further expand the clinical spectrum of phacomatosis pigmentovascularis.

Keywords: Epidermal nevus syndrome, cutis marmorata telangiectatica congenita, PPV-II, Mongolian spots, dermal melanocytosis, hypospadias, Sturge-Weber syndrome, Klippel-Trenaunay syndrome, popliteal veins, iliac veins, femoral veins, aplasia, melanosis oculi, PPV-V.

Introduction

Phacomatosis pigmentovascularis (PPV) is a rare sporadic genetic disorder characterized by an unusual combination of extensive vascular nevus with large pigmentary nevus with or without extracutaneous manifestations. The first published case of PPV dates back to 1910, but it was comprehensively described by Ota in 1947 [1]. In 1985, Hasegawa classified it into 4 types according to the associated pigmented nevus. Each type was further sub-divided into two types depending on the presence of cutaneous and extra-cutaneous manifestations [1]. In 2003, Torrelo described a distinct fifth type of PPV, which included cutis marmorata telangiectatica congenita (CMTC) and dermal melanocytosis [2].

Later in 2005, Happle gave a simpler classification of PPV by dividing it into 3 distinct types. Apart from a group of unclassifiable forms, these were descriptively named phacomatosis cesioflammea, phacomatosis spilorozea and phacomatosis cesiomarmorata (Table-1) [1]. A few more than 245 cases of PPV have been reported worldwide to date [3].

Herein, we describe two rare cases of PPV. The first patient was suffering from phacomatosis cesiomarmorata associated with melanosis oculi and hypospadias and the other patient had phacomatosis cesioflammea associated with Sturge-Weber (SW) syndrome, Klippel-Trenaunay (KT) syndrome, aplasia of iliac, femoral, and popliteal veins, and congenital heart disease.

To the best of our knowledge, only six cases of phacomatosis cesiomarmorata and only four cases of CMTC with concurrent hypospadias [4] have been reported so far with no reports of phacomatosis cesiomarmorata associated with hypospadias.

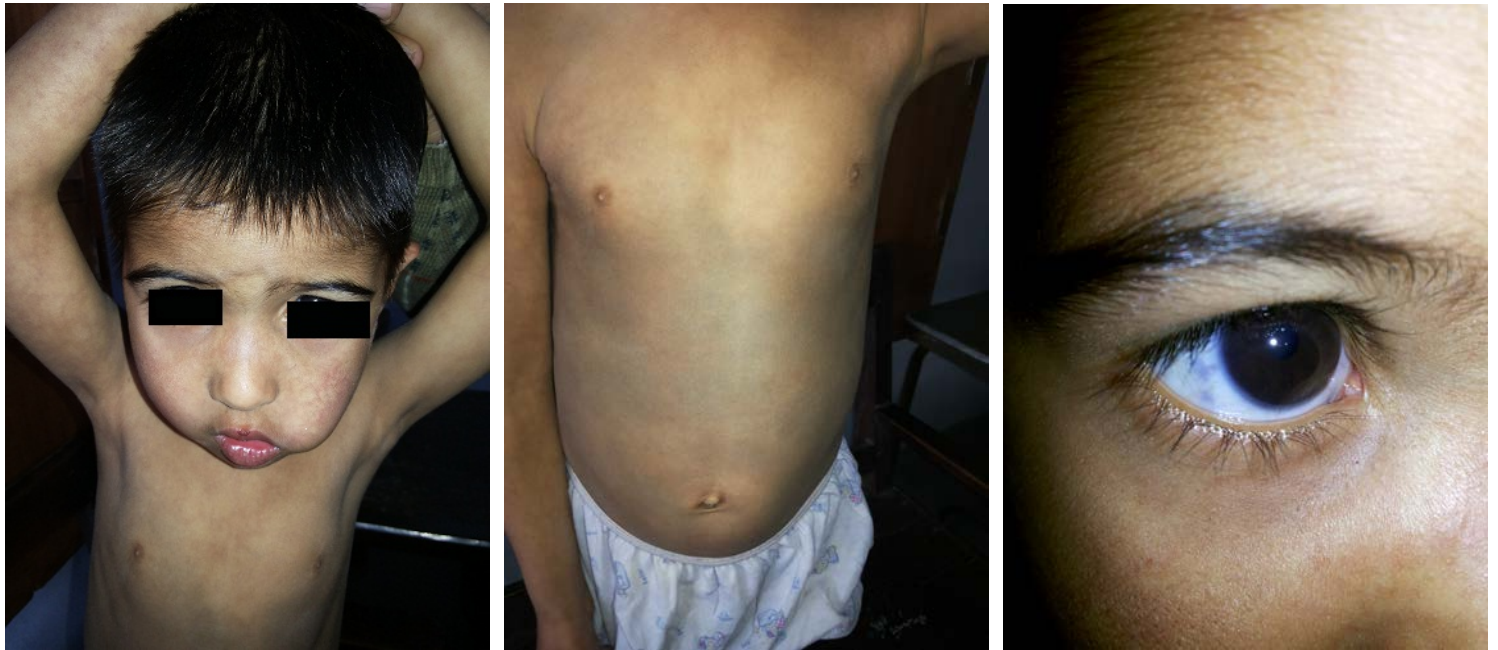Further, only three cases of phacomatosis cesioflammea with hypoplasia of iliac, umbilical, and/or femoral veins have been reported in the world literature but none with aplasia of these veins [16].

Case synopsis

Case 1

A 3-year-old boy was sent for consultation to the department of dermatology for various skin lesions when he was hospitalized for the treatment of hypospadias. He was the second son born out of a non-consanguineous marriage with unremarkable family or personal history. Birth history and developmental milestones were within normal limits.

On muco-cutaneous examination, bilaterally symmetrical reticulated erythematous marble-like macules were present on his face, mainly the cheeks and eyelids, upper arms, and calves (Figure 1). There were also a few well-demarcated large greyish-blue hyperpigmented spots in a patchy pattern without midline separation present over whole of the trunk extending up to the thighs (Figure 2). Anthropometric measurements were symmetrical with no atrophy or hypertrophy of soft tissue. The urethral opening was located ectopically on the ventral surface of glans penis along with a dorsal hooded prepuce (Figure 3).



Figures 1, 2, and 3.

Ocular examination was unremarkable except for the bilateral blue colored scleral pigmentation (Figure 4). The cardiovascular and neurological work-up was within normal limits. Other routine hematological investigations, chest X-ray, ultrasonography of abdomen, and computerized tomography were within normal limits.

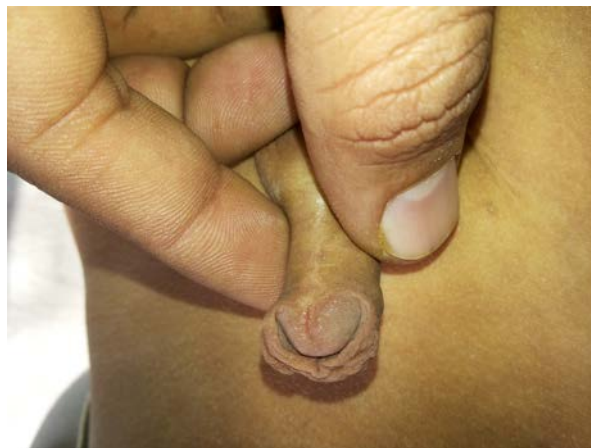

Figure 4.

With all the above muco-cutaneous findings, the clinical diagnosis of phacomatosis cesiomarmorata with melanosis oculi and hypospadias was made.

Case 2

A 5-year-old boy presented to the dermatology clinic with extensive red-colored patches on the left side of face, upper trunk, and limbs intermingled with blue patches over the trunk since birth. The lesions were asymptomatic and remained unchanged over passage of time. His left lower limb was slightly enlarged with prominent vessels present on both the lower limbs. He had his first episode of generalized tonic clonic seizures one month prior to presentation. He was the first child born out of a non-consanguineous marriage. The family, birth, and personal history were not significant and general physical examination was unremarkable. On psychomotor analysis, gross motor, speech, and IQ examinations were within normal limits.

On muco-cutaneous examination, the patient had extensive, irregular, deep red, reticulated macules and patches on the left side of the face along the ophthalmic branch of trigeminal nerve, chest, back, buttocks, penis, scrotum, arms, hands, and left leg (Figure 5). Multiple, ill-defined, large, blue-brownish spots suggestive of dermal melanocytosis in a patchy pattern with no midline demarcation were present over whole of the abdomen, back, and buttocks.

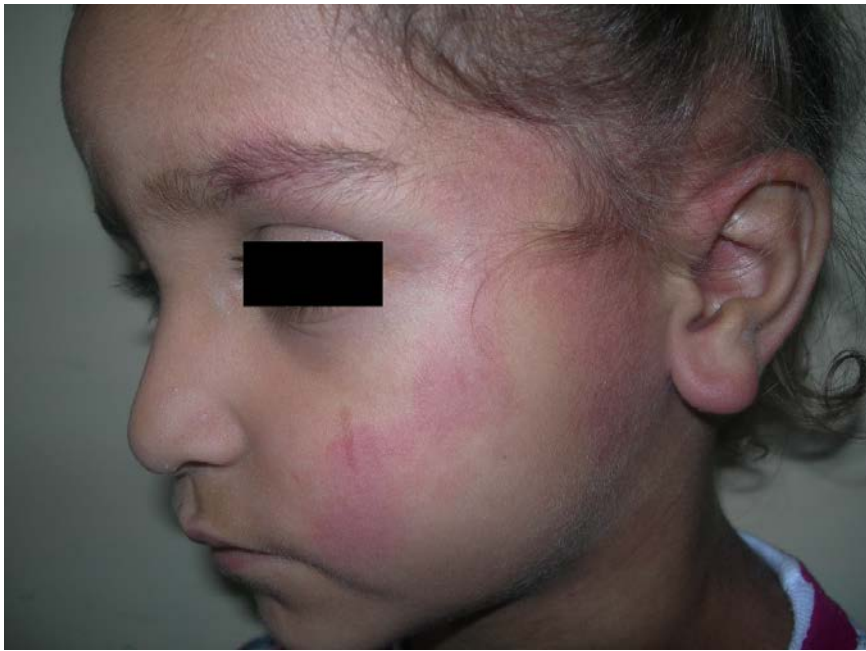
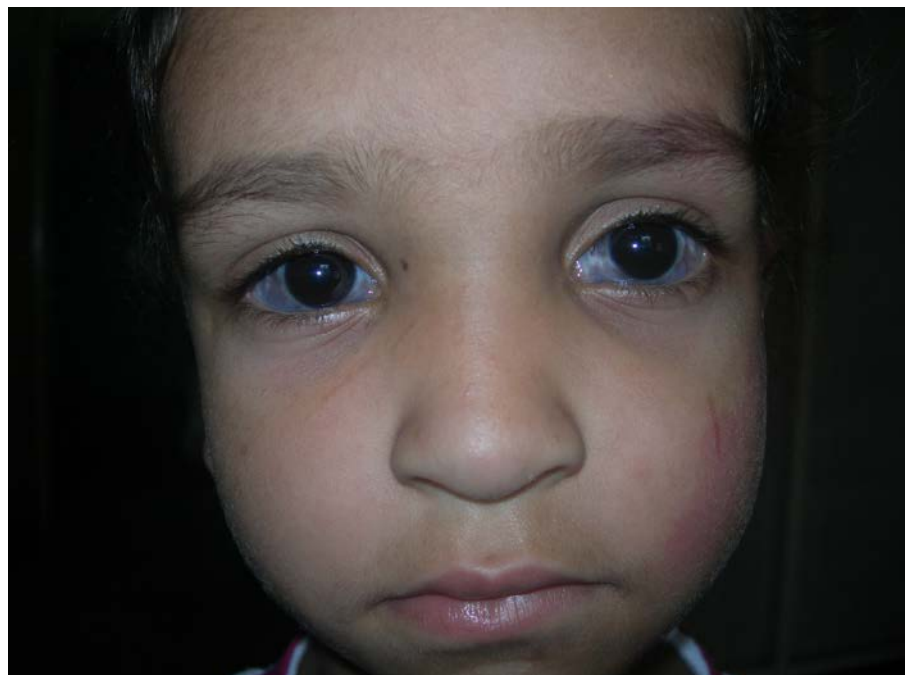
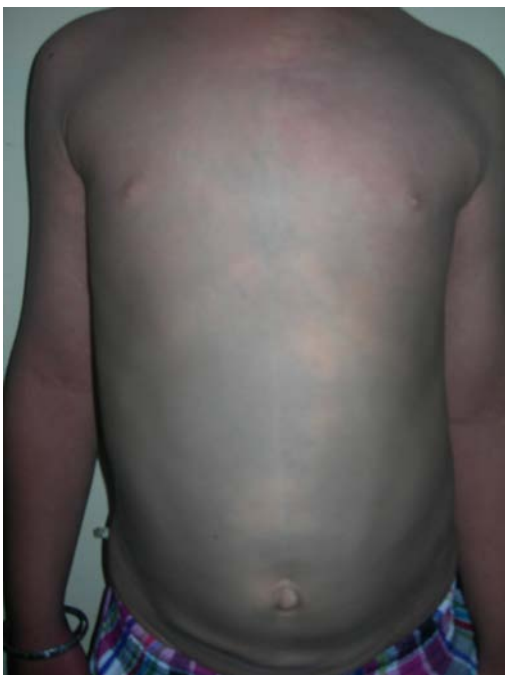Figure 5. Erythematous patches

Ocular examination showed speckled, deep blue pigmentation of the sclera, myopia, and astigmatism (Figure 7). Intraocular pressure was within normal limits. The audiometric evaluation was normal. Anthropometric measurements suggested hypertrophy of the left lower limb by 2 cm and both lower limbs showed a moderate degree of varicosities. A dilated, tortuous superficial vein was seen lying horizontally in the subcutaneous tissue of lower abdomen (Figure 8).



Figures 6,7, and 8. Dermal melanocytosis and scleral pigmentation

Echocardiography exhibited a pin hole-sized secundum atrial septal defect, and a small patent ductus arteriosus between descending aorta and left pulmonary artery. The color doppler of the lower limbs revealed a normal arterial system with an aberrant venous system. There was absence of the left common iliac, left external iliac, and proximal part of left common femoral veins along with right femoral and popliteal vein (Figure 10). An anomalous superficial vein was joining the long saphenous veins of both sides in the subcutaneous tissue of the lower abdomen thereby draining the left veins into the right side. Computerized tomography of the brain showed dystrophic calcification of the parietal lobe. Other routine hematological investigations, chest X-ray, and ultrasonography of abdomen were within normal limits.

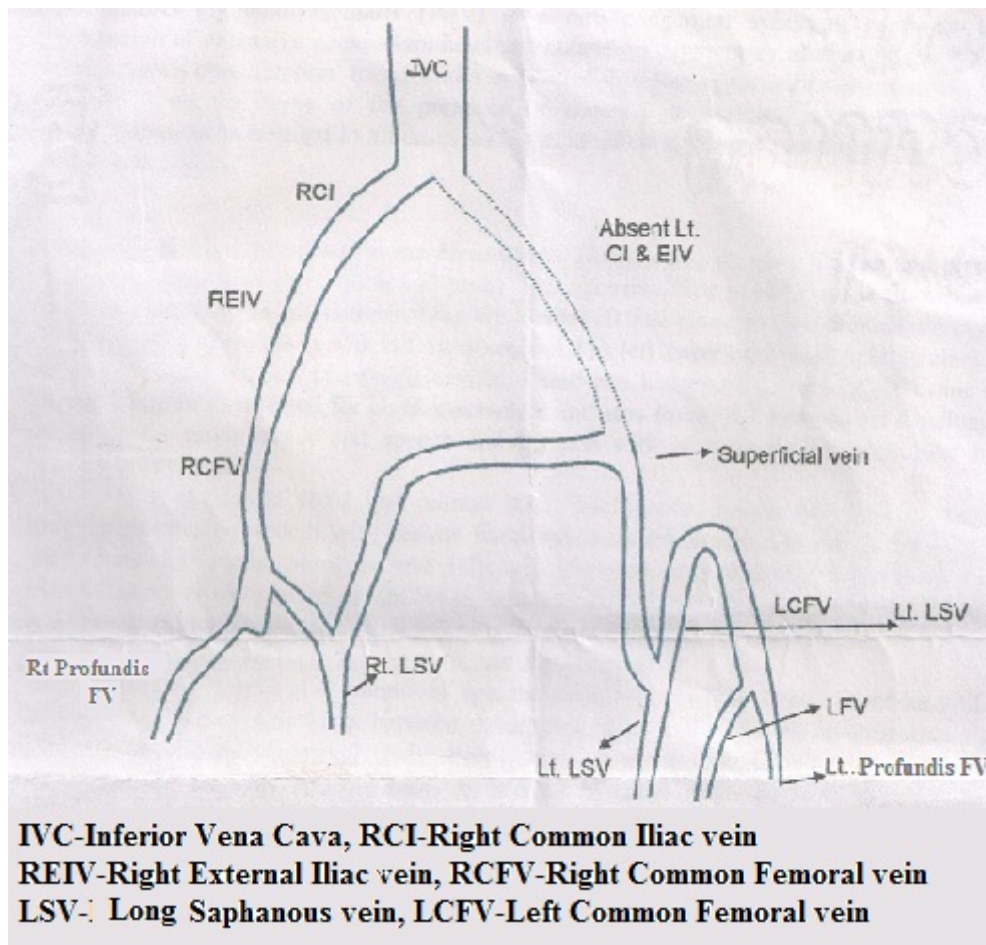


Figure (10)9. caption here

With all these muco-cutaneous findings, the complete diagnosis of phacomatosis cesioflammea or PPV type IIB associated with SW syndrome and KT syndrome along with aplasia of iliac, femoral, and popliteal veins and congenital heart disease was made.

DISCUSSION

The Greek word “phacos” means “nevus.” The term “Phakomatosis” was originally coined by the ophthalmologist Van der Hoeve' in 1920 to describe central nervous system and retinal tumors (phakomas) in diseases like neurofibromatosis, tuberous sclerosis, Sturge-Weber syndrome, and von Hippel-Lindau disease. Later on, the term “phacomatosis” was collectively used for genetically determined diseases of tissues with ectodermal origin i.e. eye, skin, and central nervous system [5].

A retrospective study of PPV in the Mexican pediatric population revealed its estimated prevalence of 1 in 22,000 [6]. Both our case subjects were pre-school boys. On the contrary, in most of the previous case reports and series, a female predominance has been observed. This female preponderance may be a bias created by cosmetic concerns of adolescent and young females because the mean age was 21.4 in one case series [1].

The pathogenesis of PPV remains controversial. Hagegawa considered it to be a developmental disorder of neural crest derived vasomotor nerve cells and melanocytes. Another hypothesis suggests abnormal neural modulation of blood vessels, which may result in malformations associated with PPV. But Happle's theory of non-allelic 'twin-spot phenomenon' (didymosis), a well-known phenomenon in plants and animals to explain the etiopathogenesis of PPV is the most acceptable [3]. According to this hypothesis, the co-occurrence of the two different nevi as seen in PPV is because of non-allelic inheritance of twin spots. The twin spots are two neighboring loci on each partner chromosome of the same homologous pair, which represent two different autosomal recessive mutations. At an early stage of embryogenesis, post-zygotic crossing over and somatic recombination of these twin spots would result in two homozygous daughter cells with information for two types

of nevi and the extra cutaneous anomalies with a mosaic pattern [8]. This hypothesis is yet to be proven at the molecular level in humans.

Happle has described mainly six patterns of cutaneous mosaicism 1. Along lines of Blaschko; 2. Checkerboard appearance; 3. Phylloid pattern; 4. Large patches without midline separation; 5. Laterization pattern and 6. Sash like pattern [9]. In both the patients, the pigmentary nevus (dermal melanocytosis) exhibited as large patches without midline separation (Type 4 mosaicism). Vascular nevus in first case (CMTC) showed a checkerboard mosaicism (Type 2), whereas vascular nevus in second case (nevus flammeus) showed large patches without midline separation (Type 4 mosaicism). These findings are consistent with a case series, which observed the patchy pattern of mosaicism without midline separation as the commonest (79%) pattern of mosaicism [1].

Nevus of Ota and Mongolian spots are the most frequent out of 5 types of congenital dermal melanocytosis, others being nevus of Ito, blue nevus, and nevus spilus [1]. Dermal melanocytosis occurs probably owing to migration failure of fetal melanocytes from the neural crest to the dermal basal layer [3]. Dermal melanocytosis are single or multiple, greyish lesions usually located on the lumbar and gluteal areas. They usually regress spontaneously and disappear completely by 4 to 6 years of age. They are considered aberrant when they are present on ectopic sites i.e. shoulders, extremities and face [3]. Aberrant dermal melanocytoses are observed in close association with other nevi, in the form of didymosis as in both of our cases. Both the patients had persistent, extensive, aberrant bluish patches involving more than half of the body surface area.

Melanosis Oculi is congenital hyperpigmentation of the sclera and episclera produced by an increase in the number and size of melanocytes. Depending on the depth of the melanocytes in the sclera, it can appear brown or bluish spots in a split ink manner [19]. It is the most common ocular abnormality associated with PPV and usually occurs in conjunction with nevus of Ota [1]. But both our cases presented with bilateral melanosis oculi in association with aberrant dermal melanocytosis. Pigmentary glaucoma and malignant melanoma are the most dreaded sequel of melanosis oculi [19]. Long term follow-up of these patients is mandatory.

Case 1 had an extensive CMTC besides dermal melanocytosis and melanosis oculi. CMTC was first described by a Dutch pediatrician Van Lohuizen in 1922. It is a rare cutaneous disorder characterized by a localized or generalized, congenital, persistent cutis marmorata in 'checkerboard' pattern, phlebectasia, telangiectasia, and occasional ulceration and skin atrophy [4]. Its sporadic prevalence is possibly related to a survival of a lethal gene by mosaicism and an exceptional familial occurrence of the trait may be explained by paradominant inheritance [2].

Its association with extensive dermal melanocytosis was first reported by Enjolras and Mulliken in 2000. Torrelo et al in 2003, suggested this to be a distinct subtype of PPV i.e. PPV type V or phacomatosis cesiomarmorata. The Latin word 'caesius': blue-grey, serves as an equivalent to the term "fuscoceruleus" to describe aberrant dermal melanocytosis [5]. Phacomatosis cesiomarmorata has been sparsely reported with only six case reports published in the world literature so far [1, 2, 10, and 11].

Phacomatosis cesioflammea is the most common type of all PPVs (75-87% of all cases) of which nearly half have systemic associations usually involving the central nervous system, skeletal system, and the eye (Table 2) [1]. Prognosis in PPV depends largely on the nature of these extra-cutaneous features [3]. PPV without systemic involvement usually has a benign course and does not warrant treatment.

Case 1 had hypospadias as the associated systemic disease. This is probably the first case report of an association of hypospadias with PPV-V, although hypospadias has been reported to be associated in 4 (7.69%) patients in a series of 52 Israeli males of CMTC, which was 13 times more than the rate of isolated hypospadias in that population [4].

Hypospadias is one of the most frequent congenital anomalies in neonates with an incidence of 2.3 to 29.7 per 10,000 live born infants [4]. It is an embryological defect occurring during urethral development at 8-20 weeks of gestation [4]. It is characterized by an incomplete tabularization of the urethral plate and is classified according to the location of the abnormal urethral meatus namely anterior (glandular and sub coronal), middle (distal penile, mid shaft, and proximal penile), and posterior (penoscrotal, scrotal, and perineal). In a study of 168 cases of hypospadias, the distribution was anterior in 126 (75.0%); middle in 36 (21.4%); and posterior in 6 (3.6%) cases. There were 153 (91.1%) isolated cases and 15 (8.9%) associated with other malformations [12]. Our patient had glandular type of hypospadias.

Both CMTC and hypospadias involve intrauterine malformations. CMTC may be attributed to a developmental failure of the mesodermic vessels in the early embryonic stage [4]. Hereditary transmission may be the other hypothesis of co-occurrence of both CMTC and hypospadias. Hypospadias shows a familial inheritance most likely related to multiple gene factors, the indirect evidence being the familial clustering of hypospadias and an increased risk of hypospadias among twins [12]. Heredity in CMTC has been suggested, but seems unlikely because of the very few reported familial cases [4]. Our patient did not exhibit any familial tendency either for CMTC or hypospadias.

The second case presented with port wine stain, SW syndrome, KT syndrome, aplasia of iliac, femoral, and popliteal veins and congenital heart disease besides dermal melanocytosis and melanosis oculi. SW syndrome is a mesodermal phacomatosis characterized by triad of capillary malformation in the ophthalmic division of trigeminal nerve, ipsilateral leptomeningeal angiomas, and glaucoma [13]. Its frequency is approximately 1 per 50,000 births. Eye involvement is not mandatory for meeting the diagnosis [18]. The presence of nevus flammeus along the distribution of the trigeminal nerve, history of seizures, and atrophy and calcification of the parietal lobe of the brain qualified our case to be SW syndrome.

The concurrence of SW syndrome with KT syndrome has been reported in 40 cases [7]. Individually, both SW syndrome and KT syndrome are the most common extra cutaneous associations of PPV type II. Very rarely, both have been reported together with PPV-II and to date, there are 11 such cases published in the literature.

KT syndrome is characterized by a triad of cutaneous capillary malformation of a limb, soft tissue swelling with or without bone hypertrophy, and congenital varicose veins, along with venous and/or lymphatic malformation. Unilateral lower limbs are frequently involved [14]. Its frequency is approximately 2–5 per 100,000 live births [20]. Widespread port-wine stain over the left leg and hypertrophy of the left lower limb along with moderate varicosities in case 2 fulfilled all the criteria for the diagnosis of KT syndrome.

Venous malformations have been reported in cases of KT syndrome. Kaise et al described a PPV type IIb associated with hypoplastic portal and iliac veins [15], Park et al described a PPV type IIb associated with hypoplasia of the inferior vena cava and the right iliac and femoral veins [16]. Servelle, upon venography and surgical exploration of 559 patients of KT syndrome, demonstrated malformations of the deep veins of the lower limb involving the popliteal vein in 51%; superficial femoral vein, 16%; both popliteal and superficial femoral veins; 29%; iliac veins, 3%; and lower vena cava, 1%. Aplasia was a rarer (8%) form of malformation compared to atresia/hypoplasia (26%) [17].

In the second case of PPV, there was aplasia of the left common iliac, left external iliac, and proximal part of the left common femoral veins along with the right femoral and popliteal vein, which are very rare associations of KT syndrome.

Atrial septal defect, found in our second patient, has been reported in a few case reports of PPV. It may related to defective conotruncal cells which, like melanocytes, are neural crest cell derivatives [3].

Thus, these cases are being reported because they display multiple, rare, previously unreported systemic associations of PPV, which will further expand the clinical spectrum of phacomatosis pigmentovascularis.

References

1. Fernández-Guarino M, Boixeda P, de Las Heras E, Aboin S, García-Millán C, Olasolo PJ. Phacomatosis pigmentovascularis: Clinical findings in 15 patients and review of the literature. *J Am Acad Dermatol*. 2008 Jan; 58(1):88-93. [PMID: 18045734]
2. Torrelo A, Zambrano A, Happle R. Cutis marmorata telangiectatica congenita and extensive mongolian spots: type 5 phacomatosis pigmentovascularis. *Br J Dermatol*. 2003 Feb;148(2): 342-5.[PMID: 12588390]
3. Segatto MM, Schmitt EU, Hagemann LN, da Silva RC, Cattani CAS. Phacomatosis pigmentovascularis type IIa - Case report. *Anais Brasileiros de Dermatologia* 2013; 88(6 Suppl 1):85-88.[PMCID: 3875999]
4. Ben-Amitai D, Merlob P, Metzker A. Cutis marmorata telangiectatica congenita and hypospadias: report of 4 cases. *J Am Acad Dermatol*. 2001 Jul;45(1):131-2.[PMID: 11423849]
5. Goyal T, Varshney A. Phacomatosis cesioflammea: First case report from India. *Indian J Dermatol Venereol Leprol* 2010;76:307.[PMID: 20445318]
6. Vidaurri-de la Cruz H, Tamayo-Sánchez L, Durán-McKinster C, Orozco-Covarrubias Mde L, Ruiz-Maldonado R. Phacomatosis pigmentovascularis II A and II B: clinical findings in 24 patients. *J Dermatol*. 2003 May; 30(5):381-8. Review. [PMID: 12773803]
7. Mandal RK, Ghosh SK, Koley S, Roy AC. Sturge-Weber syndrome in association with Klippel-Trenaunay syndrome and phacomatosis pigmentovascularis type IIb. *Indian J Dermatol Venereol Leprol* 2014; 80: 51-3. [PMID: 24448125]
8. Taheri AR, Nikandish M, Mashayekhi V, Noori SS. Phacomatosis pigmentokeratocica associated with compound melanocytic nevus of the conjunctiva. *Int J Dermatol*. 2011 Aug; 50(8):994-8.[PMID: 21781076]
9. Happle R. Six Archetypical Patterns. In *Mosaicism in Human Skin. Understanding Nevi, Nevoid Skin Disorders, and Cutaneous Neoplasia*. (Happle R eds). 1st edn. Berlin Heidelberg; Springer-Verlag, 2014:45-61.
10. Torrelo A, Zambrano A, Happle R. Large aberrant Mongolian spots coexisting with cutis marmorata telangiectatica congenita (phacomatosis pigmentovascularis type V or phacomatosis cesiomarmorata). *J Eur Acad Dermatol Venereol*. 2006. Mar; 20(3) : 308-10.[PMID:16503893]
11. Larralde M, Santos-Muñoz A, Rodríguez Cáceres M, Ciardiullo A. Phacomatosis pigmentovascularis type Va in a 3-month old. *Pediatr Dermatol*. 2008 Mar-Apr; 25(2):198-200. [PMID: 18429779]
12. Calzolari E, Contiero MR, Roncarati E, Mattiuz PL, Volpato S. Aetiological factors in hypospadias. *J Med Genet*. 1986 Aug; 23(4):333-7.[PMID: 3746833]

13. Theiler M, Wälchli R, Weibel L. Vascular anomalies - a practical approach. *J Dtsch Dermatol Ges.* 2013 May;11(5):397-405. [PMID: 23464752]
14. Garg A, Gupta LK, Khare AK, Kuldeep CM, Mittal A, Mehta S. Phacomatosis cesioflammea with Klippel Trenaunay syndrome: A rare association. *Indian Dermatol Online J.* 2013 Jul;4(3):216-8.[PMID: 23984239]
15. Kaise M, Watanabe A, Kobayashi Y. A case of phacomatosis pigmentovascularis accompanied with esophageal varices due to hypoplasia of the portal veins. *Gastroenterol Jpn.* 1992 Aug; 27(4):546-9.[PMID: 1526436.]
16. Park JG, Roh KY, Lee HJ, Ha SJ, Lee JY, Yun SS, Lim KW, Song KS, Kim JW. Phacomatosis pigmentovascularis IIb with hypoplasia of the inferior vena cava and the right iliac and femoral veins causing recalcitrant stasis leg ulcers. *J Am Acad Dermatol.* 2003 Aug; 49(2 Suppl Case Reports): S167-9.[PMID: 12894112]
17. Servelle M. Klippel and Trénaunay's syndrome. 768 operated cases. *Ann Surg.* 1985 Mar; 201(3):365-73.[PMID: 2983626]
18. Sen S, Bala S, Halder C, Ahar R, Gangopadhyay A. Phacomatosis Pigmentovascularis Presenting with Sturge-Weber Syndrome and Klippel-Trenaunay Syndrome. *Indian Journal of Dermatology.* 2015 Jan-Feb; 60(1): 77–79. [PMID 4318068]
19. Teekhasaene C, Ritch R, Rutnin U, Leelawongs N. Ocular findings in oculodermal melanocytosis. *Arch Ophthalmol.* 1990 Aug; 108(8):1114-20.
20. Sharma D, Lamba S, Pandita A, Shastri S. Klippel–Trénaunay syndrome – A Very Rare and Interesting Syndrome. *Clin Med Insights Circ Respir Pulm Med.* 2015; 9: 1–4. [PMID 4356473]