

UC Davis

Dermatology Online Journal

Title

Asymptomatic disseminated telangiectasias: a rare case of cutaneous collagenous vasculopathy

Permalink

<https://escholarship.org/uc/item/0s39g4tt>

Journal

Dermatology Online Journal, 26(10)

Authors

Lobo, Yolanka
Blake, Tristan
Herat, Asoka

Publication Date

2020

DOI

10.5070/D32610050464

Copyright Information

Copyright 2020 by the author(s). This work is made available under the terms of a Creative Commons Attribution-NonCommercial-NoDerivatives License, available at <https://creativecommons.org/licenses/by-nc-nd/4.0/>

Peer reviewed

Asymptomatic disseminated telangiectasias: a rare case of cutaneous collagenous vasculopathy

Yolanka Lobo BPhysio MBBS, Tristan Blake MPharm MBBS, Asoka Herat MBBS FACD

Affiliations: Department of Dermatology, Mater Hospital Brisbane, Queensland, Australia

Corresponding Author: Dr Yolanka Lobo, Department of Dermatology, Mater Hospital Brisbane, Raymond Terrace, South Brisbane QLD 4101, Australia, Tel: 61-403248432, Email: yolanka_lobo@yahoo.com

Abstract

Cutaneous collagenous vasculopathy (CCV) is a rare idiopathic microangiopathy affecting superficial dermal blood vessels. It is characterized by asymptomatic, disseminated, telangiectatic macules that typically involve the extremities. We report the case of a 58-year-old woman who presented with widespread telangiectasias of three years' duration on the upper extremities and abdomen. Cutaneous collagenous vasculopathy may be underdiagnosed as it is often mistaken for disorders that are morphologically very similar, including generalized essential telangiectasia, hereditary hemorrhagic telangiectasia, and pigmented purpuric dermatosis. The diagnosis of CCV is made histologically and findings feature dilated superficial dermal vessels with thickened walls containing periodic acid-Schiff-positive eosinophilic hyaline material. Effective treatment options for CCV have yet to be established and given its benign disease course, treatment may not be necessary. Pulsed dye laser can be offered to patients for cosmetic improvement but the extent of the disease makes complete lesion clearance challenging in most cases. Given the lesions were asymptomatic our patient declined all offered treatment modalities.

Keywords: cutaneous collagenous vasculopathy, disseminated, microangiopathy, telangiectasia

Introduction

Cutaneous collagenous vasculopathy (CCV) is an uncommon idiopathic microangiopathy affecting

superficial dermal blood vessels. Since its original description in 2000 by Salama and Rosenthal [1], 46 cases of CCV have been reported in the literature. Furthermore, CCV may be underdiagnosed as it is often mistaken for other more common microangiopathies, making it difficult to determine its true frequency in the general population. It is characterized by asymptomatic, disseminated, blanching, telangiectatic macules that typically involve the extremities. The histology of CCV is distinctive, featuring dilated superficial dermal vessels with thickened vessel walls containing periodic acid-Schiff (PAS)-positive eosinophilic hyaline material. Immunohistochemistry reveals an excess of collagen type IV [2]. Cutaneous collagenous vasculopathy most commonly affects middle-aged-to-elderly Caucasian adults with the exception of one reported Japanese patient [3].

Case Synopsis

We report the case of a 58-year-old woman who presented for evaluation of asymptomatic widespread telangiectasias of three years' duration, first appearing on the extensor surfaces of her upper extremities and slowly progressing to involve the abdomen. The face, mucous membranes, and nails were spared. Both personal and family history were negative for telangiectatic, clotting, and bleeding disorders. Her past medical history was significant for smoking, obesity, hypertension, dyslipidemia, type two diabetes mellitus, obstructive sleep apnea, non-alcoholic steatohepatitis, and depression. On examination, there was an eruption consisting of

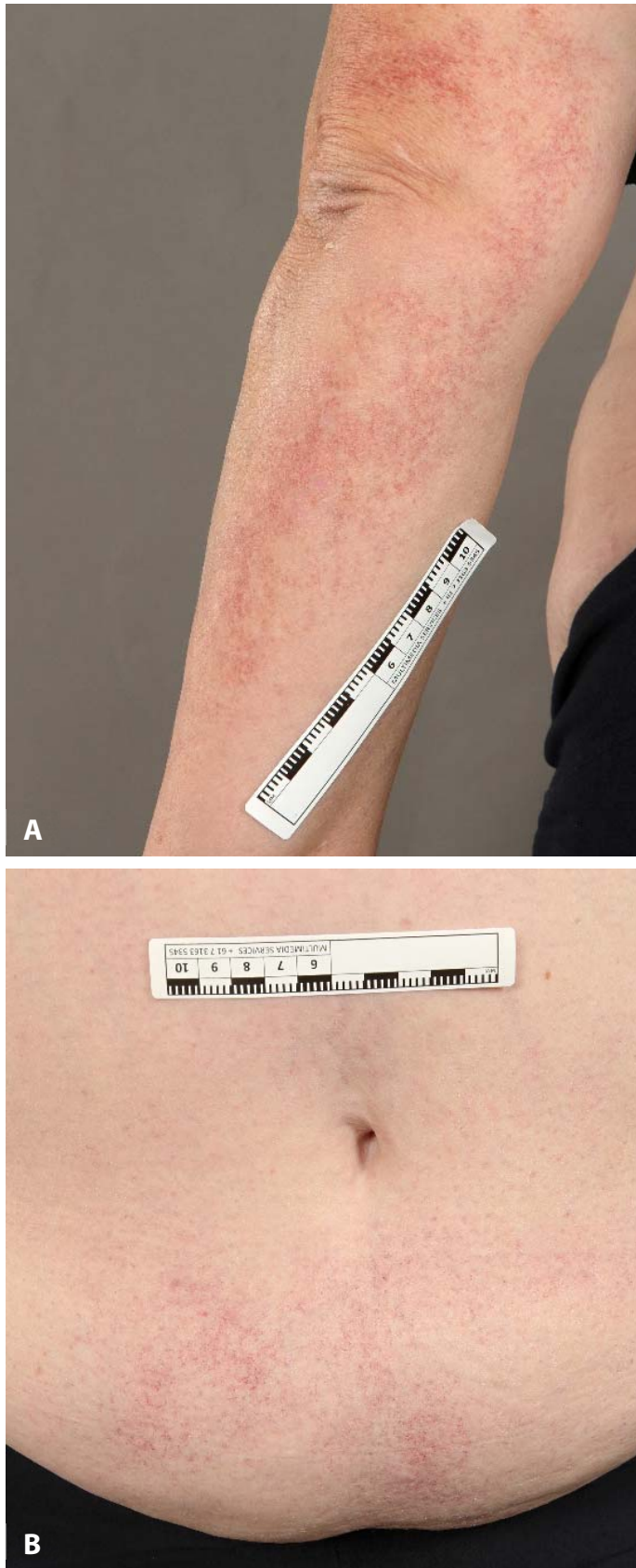

Figure 1. Clinical presentation of cutaneous collagenous vasculopathy. Erythematous, mottled, telangiectatic macules involving **A)** the upper extremities, and **B)** abdomen.

erythematous, mottled, telangiectatic macules on the upper extremities and abdomen (**Figure 1**).

Full blood count and coagulation parameters were unremarkable. Histopathological examination of punch biopsies showed ectasia of the superficial dermal blood vessels with mildly thickened walls containing PAS-positive eosinophilic hyaline material (**Figure 2A, B**). Congo red staining was negative for amyloid deposition (**Figure 2C**). Leukocytoclastic debris, fibrinoid necrosis of vessel walls, and thrombi were absent. Based on clinical and histopathological findings, a diagnosis of CCV was made. Given the lesions were asymptomatic our patient declined all offered treatment modalities including pulsed dye laser.

Case Discussion

The most common comorbidities of patients with CCV are cardiovascular, similar to the ones seen in our patient, including hypertension, diabetes, dyslipidemia, metabolic syndrome, myocardial infarction, venous insufficiency, mitral valve disease, atrial fibrillation, and supraventricular tachycardia [2]. The etiology and pathogenesis of CCV are unclear, though several possible mechanisms have been hypothesized including microangiopathy related to diabetes mellitus and hypertension, skin trauma, and genetic defects that alter collagen production or affect vascular collagen deposition during repair of damaged blood vessels [1,2,4].

Rahnama-Moghadam et al. recently reported a case of a 63-year-old man who developed CCV after coronary artery bypass grafting and was initially misdiagnosed with essential telangiectasia [5]. The authors hypothesized that a history of cardiovascular disease and a systemic stressor such as surgery or possibly a drug exposure may contribute to the development of CCV [5]. Clinically, the most common presentation of CCV is in the form of progressive asymptomatic cutaneous telangiectasias on the lower extremities with gradual progression to the upper extremities and trunk. Most recently, Conde-Ferreiros et al. reported a case of a 68-year-old man who presented with blanchable erythematous papules located on the trunk

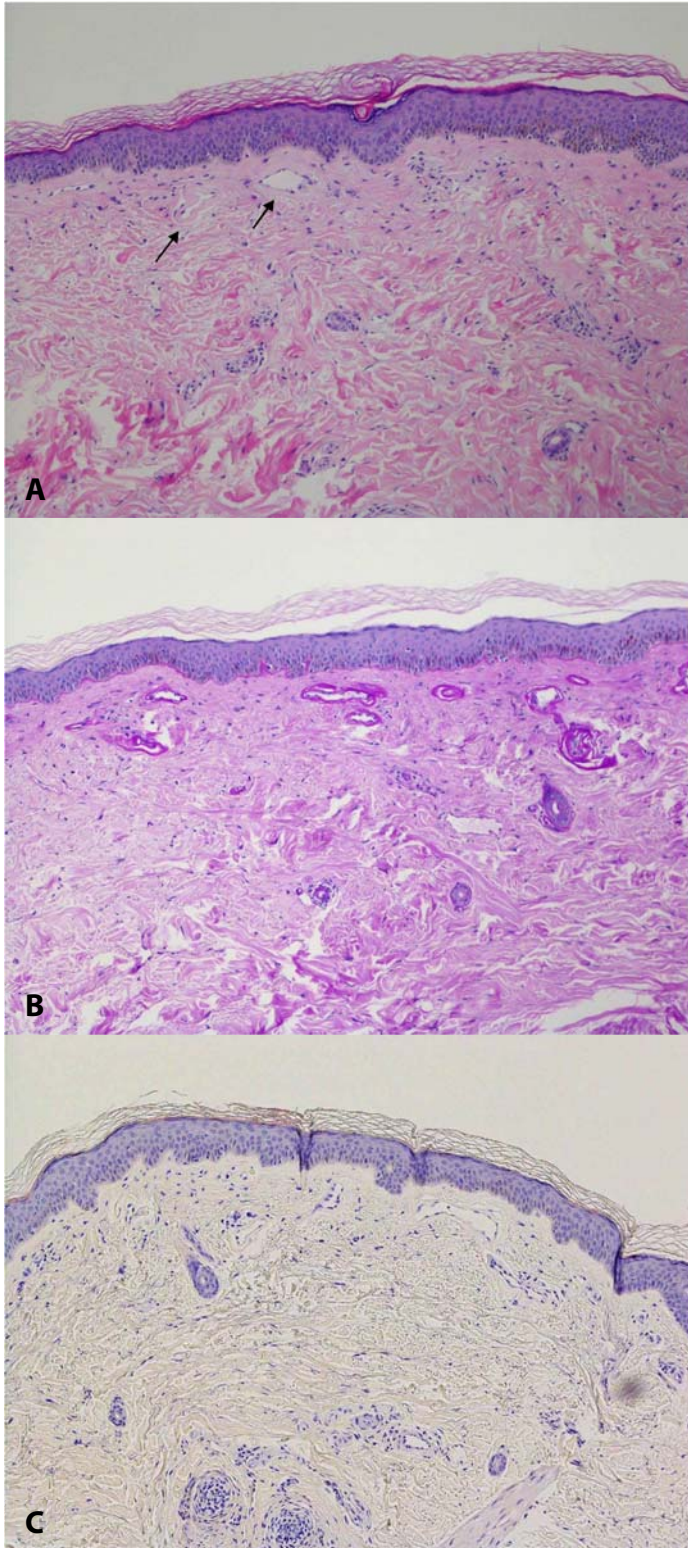


Figure 2. Histopathological examination. Blood vessels of the superficial vascular plexus (arrows) are mildly ectatic with mildly thickened, eosinophilic, hyalinized walls **A)** H&E, 100 \times , which are **B)** periodic acid-Schiff-positive, and **C)** Congo red-negative. There is little-to-no inflammation, red cell extravasates or hemosiderin. Leukocytoclastic debris, fibrinoid necrosis, and thrombi are absent.

alternating with non-blanching minute macules [6]. Based on histopathological findings, a diagnosis of CCV was made. The authors proposed the term “cutaneous papular collagenous vasculopathy” as a new clinical manifestation of this disease [6].

Important disorders presenting as generalized telangiectasias and morphologically very similar to CCV include generalized essential telangiectasia (GET), hereditary hemorrhagic telangiectasia (HHT), hereditary benign telangiectasia, and pigmented purpuric dermatosis. However, the histology of CCV is distinctive, featuring dilated superficial dermal vessels with thickened hyalinized vessel walls which stain positively with PAS. There are other important factors that clinically differentiate these similarly presenting entities. For example, GET often involves the oral or conjunctival mucosa, whereas mucosal involvement is typically not observed in CCV. Patients with HHT can have life-threatening systemic involvement and classically present with epistaxis and gastrointestinal bleeding whereas CCV is limited to the skin [3].

Treatment options for CCV are limited. Pulsed dye laser has been reported as an effective treatment for the telangiectatic lesions in CCV [7]. Other treatment modalities described in the literature include sclerotherapy, intense pulsed light therapy, and compression stockings.

Conclusion

Cutaneous collagenous vasculopathy is an important differential diagnosis of asymptomatic disseminated telangiectasias. It may be underdiagnosed owing to the slow progression and asymptomatic nature of skin lesions; it may also be mistaken for other more common microangiopathies. Clinicians should therefore perform tissue biopsy to ensure an accurate diagnosis. Effective treatment options for CCV have yet to be established and given its benign disease course, treatment may not be necessary. Pulsed dye laser can be offered to patients for cosmetic improvement, but the extent of the disease makes complete lesion clearance challenging in most cases.

Potential conflicts of interest

The authors report no conflicts of interest.

References

1. Salama S, Rosenthal D. Cutaneous collagenous vasculopathy with generalized telangiectasia: an immunohistochemical and ultrastructural study. *J Cutan Pathol.* 2000;27:40-8. [PMID: 10660131].
2. Bondier L, Tardieu M, Leveque P, et al. Cutaneous collagenous vasculopathy: report of two cases presenting as disseminated telangiectasias and review of the literature. *Am J Dermatopathol.* 2017;39:682-8. [PMID: 28609342].
3. Motegi SI, Yasuda M, Yamanaka M, et al. Cutaneous collagenous vasculopathy: Report of first Japanese case and review of the literature. *Australas J Dermatol.* 2017;58:145-9. [PMID: 26820098].
4. Burdick LM, Loshier S, Somach SC, et al. Cutaneous collagenous vasculopathy: a rare cutaneous microangiopathy. *J Cutan Pathol.* 2012;39:741-6. [PMID: 22804092].
5. Rahnema-Moghadam S, Burgin C, Gilbert J, et al. Cutaneous collagenous vasculopathy: development after coronary artery bypass surgery. *Dermatol Online J.* 2018;24. [PMID: 30142740].
6. Conde-Ferreiros A, Roncero-Riesco M, Canueto J, et al. Cutaneous collagenous vasculopathy: papular form. *Dermatol Online J.* 2019;25. [PMID: 31553863].
7. Echeverria B, Sanmartin O, Botella-Estrada R, et al. Cutaneous collagenous vasculopathy successfully treated with pulsed dye laser. *Int J Dermatol.* 2012;51:1359-62. [PMID: 23067086].