

UC Davis

Dermatology Online Journal

Title

Gardner-Diamond syndrome

Permalink

<https://escholarship.org/uc/item/15f65047>

Journal

Dermatology Online Journal, 22(12)

Authors

Park, Joyce H
Yagerman, Sarah
Feng, Hao
et al.

Publication Date

2016

DOI

10.5070/D32212033389

Copyright Information

Copyright 2016 by the author(s). This work is made available under the terms of a Creative Commons Attribution-NonCommercial-NoDerivatives License, available at <https://creativecommons.org/licenses/by-nc-nd/4.0/>

Peer reviewed

Gardner-Diamond syndrome

Joyce H. Park, MD, Sarah Yagerman, MD, Hao Feng, MD, Randie H. Kim, MD, PhD, Shane A. Meehan, MD, Jesse Lewin, MD

Ronald O. Perelman Department of Dermatology, NYU School of Medicine, NYU Langone Medical Center

Abstract

Gardner-Diamond syndrome, which also is known as autoerythrocyte sensitization disorder, is a rare syndrome of inflammatory, edematous papules that evolve into painful ecchymoses on the trunk and lower legs after a period of stress with no prior history of trauma. This syndrome usually occurs in women with a history of psychiatric disorders, the most common one being depression. Although the exact mechanism of injury is not well understood, it is hypothesized that these patients have autoantibodies to phosphatidylserine, which is a phospholipid membrane component in erythrocytes. Treatment for this disorder includes symptomatic therapies and psychotropic medications to treat the underlying psychiatric disorder.

Case Presentation

PATIENT: 27-year-old-woman

DURATION: Five months

DISTRIBUTION: Thighs

HISTORY: A 27-year-old-woman presented to the Emergency Room at Tisch Hospital for evaluation of several, bruise-like lesions on her lower extremities that had been present for four months. The ecchymoses initially appeared as small, pruritic papules that subsequently over two to three days became tender patches that recurred intermittently and became widespread painful bruises on her thighs over the following months. She denied weight loss, fevers, chills, nausea, or shortness of breath. She also denied any recent travel, personal or family history of bleeding disorders or autoimmune diseases, trauma, physical

abuse, and drug abuse. On review of systems, she had intermittent night sweats but otherwise felt generally healthy. She had never had similar lesions on her skin before. She has a history of obsessive-compulsive disorder that was diagnosed in her teenage years, and she takes fluoxetine, folic acid, biotin, and an oral contraceptive. Two punch biopsies were obtained from the left and right anterior thighs, and she was referred to the Skin and Cancer Unit for follow-up. At her follow-up appointment, she was still developing new lesions on her thighs. She was treated with Sarna lotion. Because of her night sweats for six weeks prior to presentation, she was referred to the Hematology Clinic at Bellevue Hospital Center for workup of an underlying malignant condition. She was evaluated there and found not to have an underlying bleeding disorder or malignant condition.

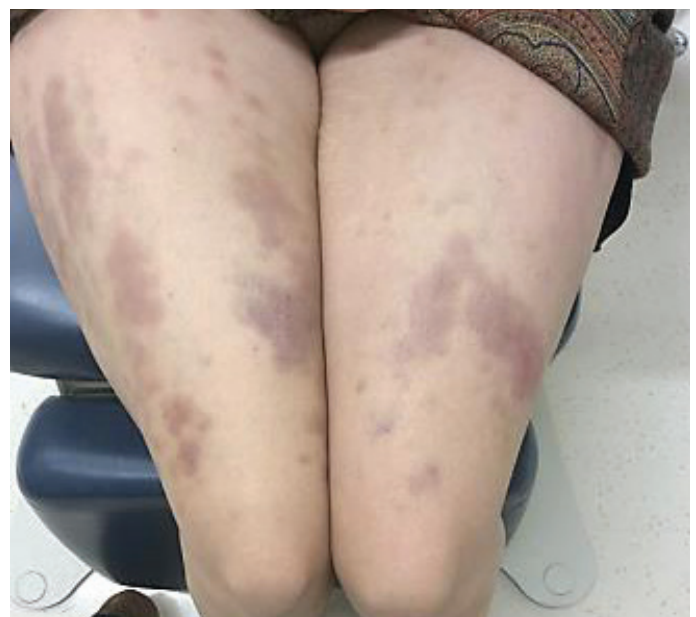

Figure 1. Thighs with multiple, purpuric macules coalescing into plaques with slight yellow-to-orange discoloration surrounding the primary lesions.

PHYSICAL EXAMINATION: On the anterior and posterior thighs, there were multiple, purpuric macules that coalesced into plaques with slight yellow-to-orange discoloration that surrounded the primary lesions (**Figure 1**). The lesions were tender to palpation. No other lesions were noted on the arms, trunk, and lower legs.

LABORATORY DATA: A complete blood count showed a hemoglobin of 12.0 g/dL and a hematocrit of 35.1 g/dL. White-cell and platelet counts as well as the differential analysis were normal. Basic metabolic panel and liver function tests were normal as was prothrombin time and activated partial thromboplastin time. Human immunodeficiency virus was negative. Urinalysis showed a small amount of blood and trace protein. Qualitative urine pregnancy test was negative. Further testing with the hematologist showed a normal von Willebrand factor, iron studies, transferrin saturation, anti-nuclear antibody, erythrocyte sedimentation rate, rheumatoid factor, C-reactive protein, and lactate dehydrogenase.

HISTOPATHOLOGY: Within the mid-dermis, there are aggregates of extravasated erythrocytes and a sparse, interstitial infiltrate with neutrophils (**Figure 2**).

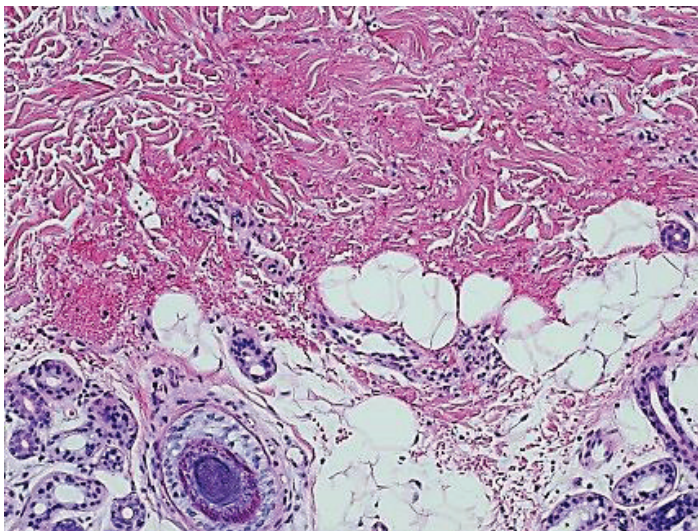


Figure 2. Mid-dermis with aggregates of extravasated erythrocytes and a sparse, interstitial infiltrate with neutrophils.

DIAGNOSIS: Autoerythrocyte sensitization syndrome (Gardner-Diamond syndrome)

Discussion

Gardner-Diamond syndrome, which also is known as autoerythrocyte sensitization syndrome, is a rare condition of the spontaneous development of painful ecchymoses with no known etiology, which occurs most commonly in young women with history of psychiatric disease [1]. This syndrome was described in 1955 in four patients with psychiatric diseases, who developed edematous, erythematous lesions that quickly turned into painful, large ecchymoses with history of very mild trauma. Gardner-Diamond syndrome typically presents after a period of mild mechanical injury, stress, trauma, or physical labor. The lesions initially start as burning, pruritic edematous plaques on the skin [2-3]. Stress is the preceding trigger in 40 to 60% of reported cases. Patients report malaise and fatigue at this time. Over a period of two days, the plaques turn into painful ecchymoses that resolve without treatment over the next seven to ten days. The lesions appear most commonly on the trunk and anterior surface of the legs and may be associated with systemic symptoms, such as fevers, headache, nausea, epigastric pain, and, in one case report, glomerulonephritis. Bleeding tendencies have been noted as well, which include menorrhagia, epistaxis, and gingival bleeding [1, 4, 5]. The majority of patients experience recurrence of lesions for several years, with long remissions in between, and the severity of recurrences is variable. In addition to these skin findings, patients have a history of mood, anxiety, or other psychiatric disorders, which lead some to term the disease psychogenic purpura. Depression appears to be the most common psychiatric abnormality in these patients [6].

The etiology of Gardner-Diamond syndrome currently is unknown. It has been hypothesized that patients with Gardner-Diamond syndrome have autoantibodies to components of erythrocyte stroma, deoxyribonucleic acid, hemoglobin, and phosphatidylserine that are located in the membrane of erythrocytes [1, 7-9]. The latter is the most widely accepted hypothesis today as a study using indirect immunofluorescence demonstrated that more than 50% of all phosphatidylserine on erythrocytes was located on the outermost membrane. In addition, this redistribution of phosphatidylserine was recreated in normal

patient's erythrocytes that were incubated in serum from Gardner-Diamond patients [10]. The mechanism underlying psychiatric disease and autosensitization to erythrocytes remains unknown although a conversion disorder and somatization have been suggested as possible links.

The diagnosis of Gardner-Diamond syndrome is one of exclusion as a thorough hematologic evaluation typically is negative. Diamond and Gardner described a test of injection of one milliliter 80% suspension of the patient's washed erythrocytes into an area of skin that the patient cannot reach with his or her hands. If the patient has Gardner-Diamond syndrome, the injection should induce an erythematous, edematous lesion that turns into ecchymoses after 24 hours [1]. There is no data showing the sensitivity and specificity of this test in case reports. Histopathologic analysis demonstrates extravasated erythrocytes, a lymphohistiocytic infiltrate around the blood vessels, and pigment deposition in macrophages, which are consistent with the histopathologic findings in ecchymoses [11]. The clinical diagnosis is typically based upon cutaneous findings, a history of psychiatric disease, a period of observation to rule out exogenous or self-induced causes of ecchymoses, and an absence of hematologic laboratory abnormalities.

Currently, there is no accepted treatment for Gardner-Diamond although many have been tried. Desmopressin and estrogen have improved menorrhagia and ecchymoses in one patient, who also was found to have a signal transduction defect in her platelets [12]. Other medications tried include antimalarial agents, plasmapheresis, antihistamines, immunosuppressive agents, and various vitamins [13-14]. Symptomatic treatment can improve pruritus and pain, and improvement also has been found in patients treated with medications that target the underlying psychiatric disorder [10, 15].

References

1. Gardner F, Diamond L. Autoerythrocyte sensitization: a form of purpura producing painful bruising following autosensitization to red blood cells in certain women. *Blood* 1955; 10: 675
2. Tainwala R, et al. Perplexing purpura in two females: rare case of autoerythrocyte sensitization syndrome. *Indian Dermatol Online*

- J 2013; 4: 305
3. Hällström T, et al. Mental symptoms and personality structure in autoerythrocyte sensitization syndrome. *Br J Psychiatry* 1969; 115: 1269
4. McIntosh RM, et al. Nephropathy associated with Gardner-Diamond syndrome: autologous erythrocyte antigen-antibody immune-complex disease. *N Engl J Med* 1977; 296: 1265
5. McDuffie FC, McGuire FL. Clinical and psychological patterns in autoerythrocyte sensitivity. *Ann Intern Med* 1965; 63: 255
6. Ratnoff OD. Psychogenic purpura (autoerythrocyte sensitization): an unsolved dilemma. *Am J Med.* 1989; 87: 16
7. Kremer WB, et al. Recurrent ecchymoses and cutaneous hypereactivity to hemoglobin: a form of autoerythrocyte sensitization. *Blood* 1967; 30: 62
8. Little AS, Bell HE. Painful subcutaneous hemorrhages of the extremities with unusual reaction to injected deoxyribonucleic acid. *Ann Intern Med*, 1964; 60: 886
9. Gottlieb AJ. Autoerythrocyte and DNS – sensitivity. In: William WJ, et al, eds. *Haematology*, 4th edn. McGraw-Hill: New York, 1990: 1441
10. Strunecká A, et al. Transbilayer redistribution of phosphatidylserine in erythrocytes of a patient with autoerythrocyte sensitization syndrome (psychogenic purpura). *Folia Haematol Int Mag Klin Morph Blutforsch* 1990; 117: 829
11. Vun YY, Muir J. Periodic painful purpura: fact or factitious? *Australas J Dermatol* 2004; 45: 58
12. Puetz J, Fete T. Platelet function disorder in Gardner-Diamond syndrome: a case report and review of the literature. *J Pediatr Hematol Oncol* 2005; 27: 323
13. Hamblin TJ, et al. Plasmapheresis and a placebo procedure in autoerythrocyte sensitization. *Br Med J* 1981; 283: 1575
14. Barba A, et al. Gardner-Diamond syndrome. *Dermatologica* 1983; 167: 314
15. Anderson JE, et al. Autoerythrocyte sensitization (psychogenic purpura): a case report and review of the literature. *Pediatr Emerg Care* 1999; 15: 47