

UC Davis

Dermatology Online Journal

Title

Apremilast for treatment of recurrent erythema multiforme

Permalink

<https://escholarship.org/uc/item/15s432gx>

Journal

Dermatology Online Journal, 23(1)

Authors

Chen, Tinley
Levitt, Jacob
Geller, Lauren

Publication Date

2017

DOI

10.5070/D3231033682

Copyright Information

Copyright 2017 by the author(s). This work is made available under the terms of a Creative Commons Attribution-NonCommercial-NoDerivatives License, available at <https://creativecommons.org/licenses/by-nc-nd/4.0/>

Peer reviewed

Apremilast for treatment of recurrent erythema multiforme

Tinley Chen¹, Jacob Levitt MD², Lauren Geller MD²

Affiliations: ¹New York University, New York, NY, ² Department of Dermatology, Icahn School of Medicine at Mount Sinai, New York, NY

Corresponding Author: Jacob Levitt, 5 East 98th St, New York, NY 10029, Tel. 914-661-1726, Fax. 212-987-1197, Email: jacoblevittmd@gmail.com

Abstract

Recurrent erythema multiforme with oral involvement is therapeutically challenging. Apremilast has been used with success in resolving the oral aphthae of Behçet disease, prompting the use of the drug in patients with oral erosions from erythema multiforme. Three patients with oral erythema multiforme were given apremilast at doses of 30-60mg daily. Complete clearance of the lesions were observed in all three patients, including those refractory to other standard therapies. Apremilast may present an effective option for recurrent erythema multiforme for patients who have failed trials antiviral and immunosuppressive therapies.

Keywords: apremilast, otezla, erythema multiforme, recurrent erythema multiforme, EM, REM, Behçet's syndrome

Introduction

Erythema multiforme (EM) is an uncommon condition with unclear etiology that is found predominantly in young adults 20 to 40 years of age and characterized by targetoid lesions with concentric color variations, sometimes accompanied by oral, genital, or ocular

mucosal erosions [1]. EM major refers to cases of EM with mucosal involvement, whereas EM minor refers to cases in the absence of mucosal involvement. Lesions normally appear over 3-5 days and resolve over 1-2 weeks, although severe cases may require up to six weeks for resolution [1]. The presentation of at least two episodes, typically an average of six episodes per year over the course of 6-10 years, constitutes recurrent EM (REM) in a subset of these patients [2]. These cases are most often associated with herpes simplex virus (HSV) and are treated with antiviral therapies. Immunosuppressive agents can be used in recalcitrant cases.

Case Synopsis

Patient 1 is a 21-year-old woman who presented with erosions in her mouth and a history of approximately six episodes per year of recurrent erosions on lips, tongue, and soft palate for over ten years. She had a previous diagnosis at age 6 of Behçet syndrome owing to recurrent oral and genital ulcers and joint pain and swelling (**Figure 1A**).

Acute episodes were successfully treated with prednisone. Trials of colchicine, dapsone, and hydroxychloroquine were unsuccessful. Serology was negative for HSV1/2. Lesions resolved completely

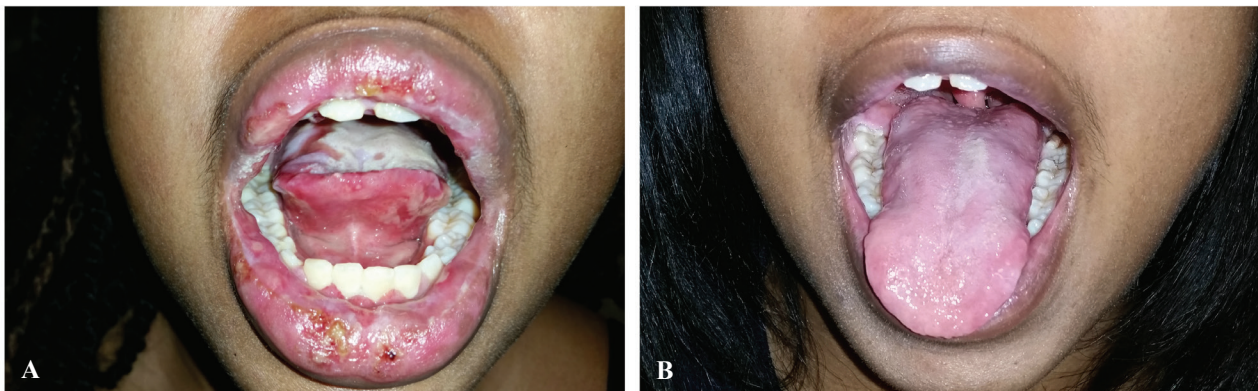


Figure 1. A) Patient 1, Erythema multiforme oral lesions. B) Patient 1, Resolved lesions post apremilast.

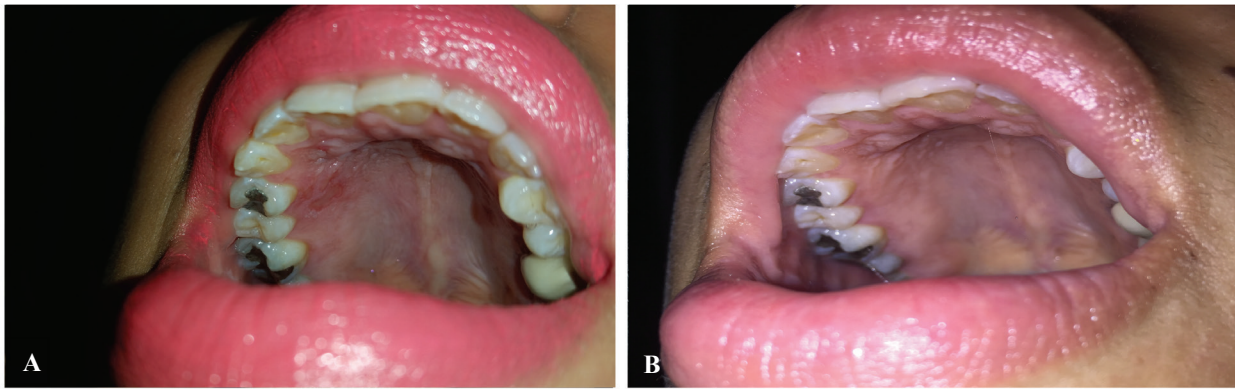


Figure 2. A) Patient 2, erythema multiforme oral lesions B) Patient 2, resolved lesions post apremilast.

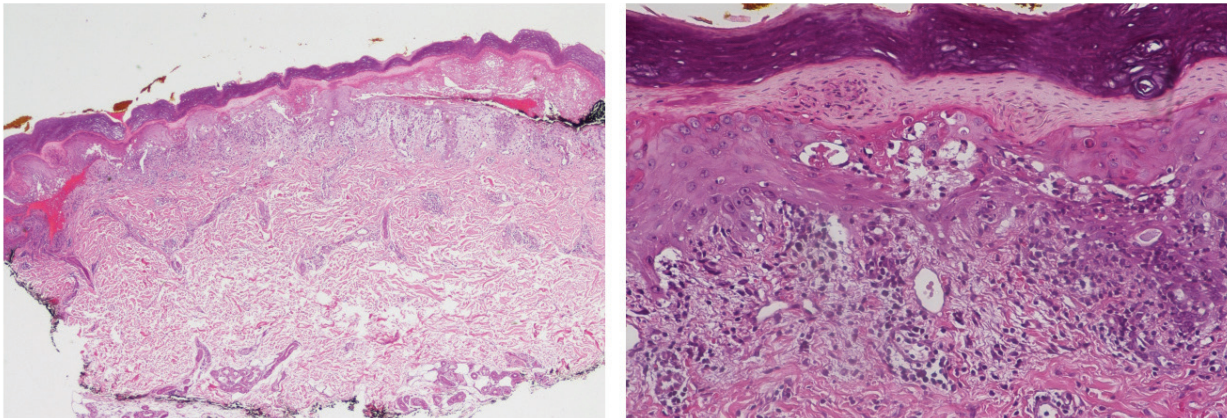


Figure 3. A) Patient 2, biopsy revealing cell-poor interface dermatitis and characterized superficial epidermal necrosis. (H&E, 10x). B) Patient 2, biopsy revealing scattered dyskeratotic keratinocytes present throughout all layers of the epidermis. Numerous dyskeratotic keratinocytes are surrounded by lymphocytes along the dermal-epidermal junction. (H&E, 20x)

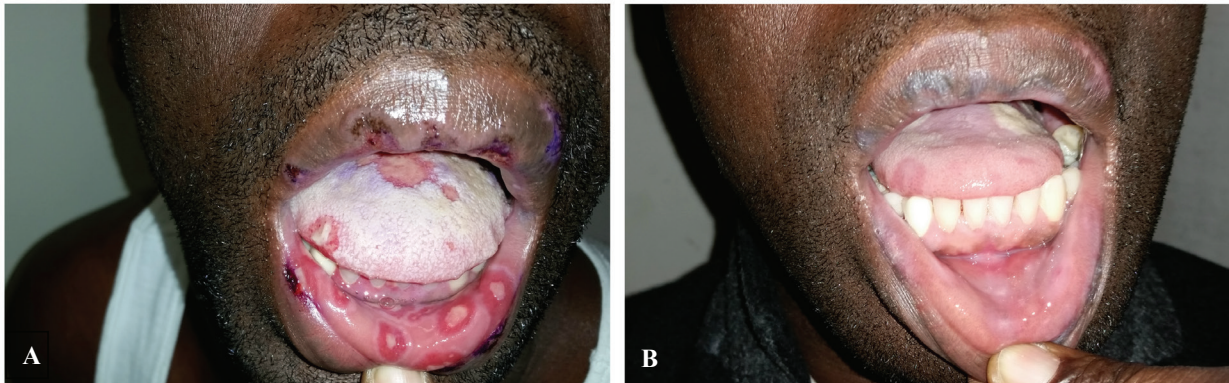


Figure 4. A) Patient 3, erythema multiforme oral lesions. B) Patient 3, resolved lesions post apremilast.

within one week after starting apremilast 30 mg PO BID with no recurrence for 6 months on therapy (**Figure 1B**).

Patient 2 is a 27-year-old woman (Patient 3 of Routt et al [3]) who presented with oral erosions of the mouth and on the hands (**Figure 2A**), consistent with EM on biopsy (**Figure 3**). These erosions were partly episodic for years and generally controlled through high dose, long-term treatment with prednisone. Serology was

positive for HSV1 and 2. Trials of IVIG, rituximab, valacyclovir, and prednisone failed to resolve lesions. The lesions initially resolved with famcyclovir 500 mg POTID; however, recurrence occurred after 3 months. Recurrence of the lesions temporarily responded to separate trials of etanercept 50 mg SC BIW and thalidomide 50 mg PO QHS, both with ultimate breakthrough. Apremilast 30 mg PO BID cleared the lesions for two months and with no recurrence (**Figure 2B**).

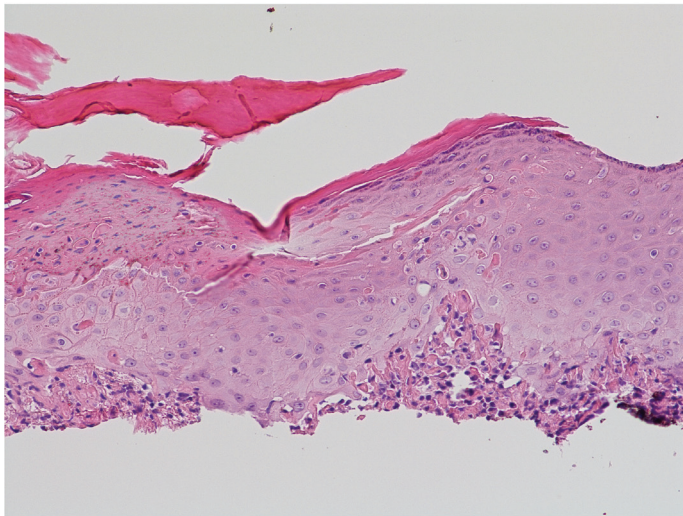


Figure 5. Patient 4, biopsy revealing cell-poor interface dermatitis characterized by scattered dyskeratotic keratinocytes present throughout all layers of the epidermis. Numerous dyskeratotic keratinocytes are surrounded by lymphocytes along the dermal-epidermal junction. (H&E, 20x)

Patient 3 is a 38-year-old man who presented with targetoid papules of the arms and hands and targetoid erosions of the lips and tongue with lip edema for four days with one previous occurrence (**Figure 4A**). The previous episode, approximately one-month prior, had lasted approximately two weeks and resolved with valacyclovir 1 g PO TID for 5 days. Treatment with valacyclovir provided no response at this time. HSV 1 and 2 IgG were negative when initially tested but HSV 1 IgG was positive on secondary testing. Biopsy confirmation was not performed. He completed a two week course of apremilast 30 mg PO BID and cleared after four days without dose titration or tapering and has not experienced recurrence to date (**Figure 4B**).

Patient 4 is a 6-year-old boy who presented to our pediatric emergency room with oral erosions and conjunctival injection consistent with erythema multiforme major upon biopsy (**Figure 5**).

HSV and mycoplasma studies were negative. He had one dose of ibuprofen prior to the onset of symptoms but did not take any other new medications in the preceding weeks. He was febrile but otherwise well. Two years prior to presentation, he was hospitalized with similar symptoms in the setting of a positive mycoplasma IgM and a new antibiotic, cefdinir. His rash at that time responded to intravenous immunoglobulin (IVIg). He was started on oral prednisone 1 mg/kg/day, but his symptoms worsened, and he developed swelling and hemorrhagic crusting of his lips (**Figure 6A**). He was subsequently treated with IVIg 2 g/kg divided over 3 days and one week of cyclosporine 5 mg/kg/day divided twice daily without improvement. He continued to have significant pain and intermittent bleeding from his oral mucosa and lips. He was unable to tolerate PO intake and required nasogastric tube feeds. At this time, a decision was made to initiate treatment with apremilast. On day one, he was given 10 mg PO BID. This was titrated up to 15 mg PO BID the next day and the following day to a final dose of 45 mg daily (30 mg PO in the morning and 15 mg PO at bedtime). His symptoms gradually began to improve. Two weeks after initiating treatment with apremilast, the swelling and hemorrhagic crusting of his lips had resolved and, except for one small erosion on his inner lower lip, his oral mucosa had healed as well (**Figure 6B**). He tolerated apremilast well without any headaches, abdominal pain, or diarrhea.

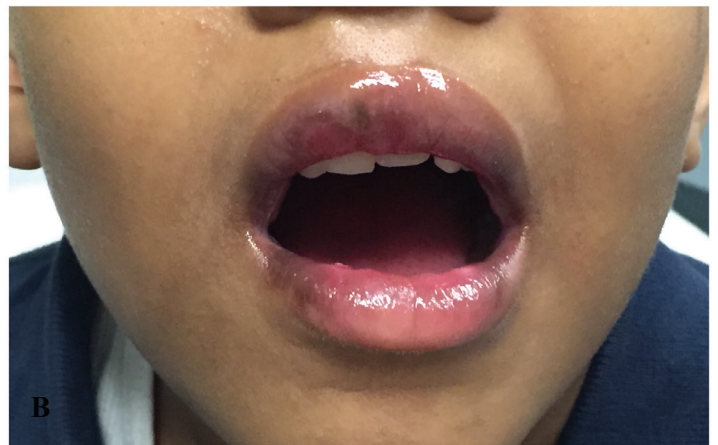
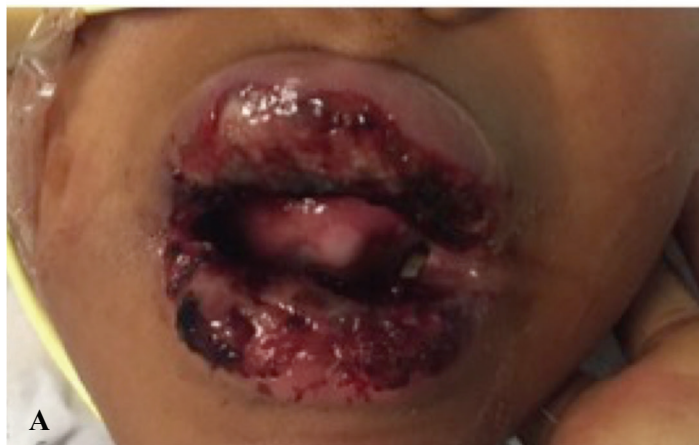
Figure 6. A) Patient 4, erythema multiforme oral lesions. B) Patient 4, resolved lesions post apremilast.

Case Discussion

The etiology of EM is not fully understood. However, onset is most commonly associated with infection, most commonly by herpes simplex virus (HSV) type 1 (less commonly type 2), constituting approximately 90% of cases of EM [4]. Patients with idiopathic EM may have sub-clinical HSV infection, which may be detected through PCR of skin biopsy specimens [4]. Currently, continuous antiviral therapy for six months has been demonstrated as the most effective first-line treatment of REM regardless of whether or not HSV is the precipitating factor [5]. Recommended treatments include acyclovir, valacyclovir, and famciclovir, and are most successful when the HSV association is clear and treatment begins at the onset of HSV flare [2, 4, 5]. Patients that are unresponsive to antiviral therapy may require treatment with immunosuppressive or immunomodulating agents. Treatments that have been used with variable success include azathioprine, prednisone, dapsone, mycophenolate mofetil, intravenous immunoglobulin, hydroxychloroquine, thalidomide, cyclosporine, and rituximab [2, 4, 6].

We found that treatment with apremilast was both effective and tolerable for four patients with REM with mucosal involvement. Although the safety and effectiveness of apremilast in patients less than 18 years of age have not been established thus far, patient 4 was able to tolerate apremilast at a dose of 1 mg/kg. In prolonged cases of REM in which antiviral and immunosuppressive agents fail, apremilast may be an effective option for recurrent erythema multiforme.

References

1. Huff JC, Weston WL, Tonnesen MG. Erythema multiforme: a critical review of characteristics, diagnostic criteria, and causes. *Journal of the American Academy of Dermatology*. 1983 Jun 30;8(6):763-75. [PMID 6345608]
2. Schofield JK, Tatnall FM, Leigh IM. Recurrent erythema multiforme: clinical features and treatment in a large series of patients. *British Journal of Dermatology*. 1993 May 1;128(5):542-5. [PMID 8504046]
3. Routt E, Levitt J. Famciclovir for recurrent herpes-associated erythema multiforme: A series of three cases. *Journal of the American Academy of Dermatology*. 2014 Jan 10;71(4):e146-7. [PMID 25219739]
4. Sokumbi O, Wetter DA. Clinical features, diagnosis, and treatment of erythema multiforme: a review for the practicing dermatologist. *International journal of dermatology*. 2012 Aug 1;51(8):889-902. [PMID 22788803]
5. Tatnall FM, Schofield JK, Leigh IM. A double-blind, placebo-controlled trial of continuous acyclovir therapy in recurrent erythema multiforme. *British Journal of Dermatology*. 1995 Feb

- 1;132(2):267-70. [PMID 7888365]
6. Hirsch G, Ingen-Housz-Oro S, Fite C, Valeyrie-Allanore L, Ortonne N, Buffard V, Verlinde-Carvalho M, Marinho E, Martinet J, Grootenboer-Mignot S, Descamps V. Rituximab, a new treatment for difficult-to-treat chronic erythema multiforme major? Five cases. *Journal of the European Academy of Dermatology and Venereology*. 2015 Sep 1. [PMID 26369288]