

UC Davis

Dermatology Online Journal

Title

Hemosiderotic (pigmented) atypical fibroxanthoma mimicking malignant melanoma

Permalink

<https://escholarship.org/uc/item/1645n2t2>

Journal

Dermatology Online Journal, 28(6)

Authors

Zhu, Tian Hao
Painter, Collin
Hendrix, John D

Publication Date

2022

DOI

10.5070/D328659728

Copyright Information

Copyright 2022 by the author(s). This work is made available under the terms of a Creative Commons Attribution-NonCommercial-NoDerivatives License, available at <https://creativecommons.org/licenses/by-nc-nd/4.0/>

Peer reviewed

Hemosiderotic (pigmented) atypical fibroxanthoma mimicking malignant melanoma

Tian Hao Zhu¹ MD, Collin Painter² BS, John D Hendrix¹ MD

Affiliations: ¹Department of Dermatology, University of Virginia Health System, Charlottesville, Virginia, USA, ²James Madison University, Harrisonburg, Virginia, USA

Corresponding Author: John D Hendrix MD, 902 East Jefferson Street, Suite 201, Charlottesville, VA 22902, Tel: 434-979-7700, Email: dermsurgcv@mac.com

Abstract

Atypical fibroxanthoma is a rare cutaneous malignancy that usually presents as a rapidly growing red papule on the head and neck in elderly white males. Several variants have been described. We report a patient who presented with a slowly enlarging pigmented lesion on his left ear that was clinically worrisome for malignant melanoma. Histopathologic evaluation with immunohistochemistry revealed an unusual case of hemosiderotic pigmented atypical fibroxanthoma. The tumor was successfully extirpated with Mohs micrographic surgery, with no recurrence at 6-month follow-up.

Keywords: atypical, fibroxanthoma, Mohs micrographic, oncology, surgery, surgical dermatology

Introduction

The clinical differential diagnosis for a slowly enlarging pigmented lesion on the skin always includes malignant melanoma but rarely atypical fibroxanthoma. Like malignant melanoma, atypical fibroxanthoma is commonly discovered on sun-exposed skin on the head and neck in elderly white males. Typically, atypical fibroxanthoma presents as an erythematous nodule that rapidly grows over a few weeks to months. Lesions may ulcerate or bleed, but most atypical fibroxanthoma tumors are asymptomatic. The pathogenesis of atypical fibroxanthoma is unknown although ultraviolet light exposure and ionizing radiation are believed to play

a role [1]. In most studies the risk of metastasis is low but the recurrence rate can be high [2].

Case Synopsis

An 89-year-old man presented with a three-year history of a slowly growing flat gray-black lesion on the left helix. The lesion had been noted as a lentigo in prior photographs, but when it became larger there was a concern by the patient for melanoma. He otherwise denied any associated tenderness, pruritus, or bleeding. There was no history of melanoma or a skin cancer on that ear but he did have a history of multiple squamous cell carcinomas elsewhere on the head and neck that had been successfully treated with surgery.

Physical examination revealed a poorly defined slightly scaly grey-black oval plaque on the scaphoid fossa of the left ear (**Figure 1**). Lymph node examination was unremarkable. A biopsy demonstrated a well-circumscribed nodular dermal tumor consisting of fascicles of plump spindle cells with prominent nuclei (**Figure 2**). Notable findings included nuclear pleomorphism and severe atypia, tumoral hemorrhage, erythrophagocytosis, and cytoplasmic hemosiderin accumulation. The presence of iron was confirmed with strongly positive Prussian blue staining.

Immunohistochemical stains were performed to further characterize the nature of the malignant cells. The tumor cells were immunoreactive for mesenchymal marker vimentin and CD10, but failed

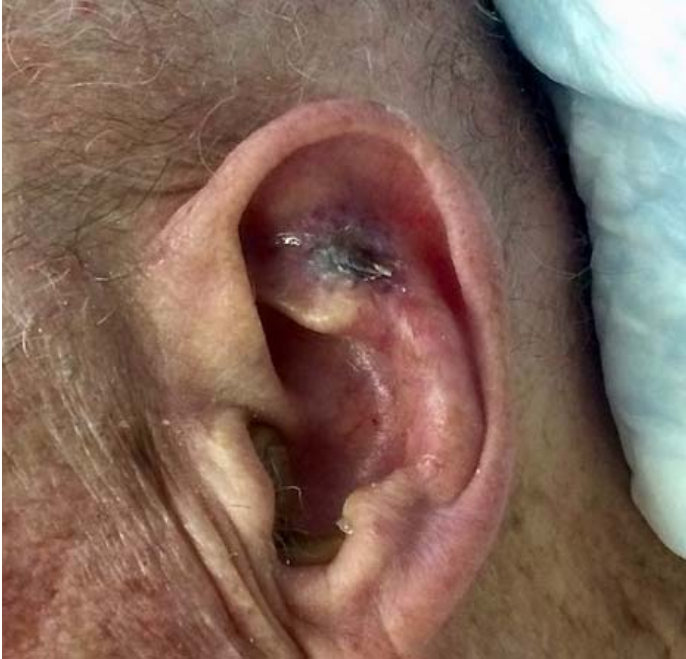

Figure 1. Left scaphoid fossae with an ill-defined slightly scaly grey-black oval plaque; no apparent ulceration.

to demonstrate positive immunoreactivity with melanocytic markers (S100, Melan A), epithelial markers (AE1-AE3, p40), or a vascular marker (CD31). Atypical mitotic figures were few, but a Ki67 stain confirmed the proliferative capacity of the cells to be markedly increased. Thus immunohistochemical stains supported a diagnosis of atypical fibroxanthoma but because the lesion was extensively present at the biopsy base, undifferentiated pleomorphic sarcoma could not be excluded. Two stages of Mohs micrographic surgery were required to completely remove the tumor, with partial cartilage excision to clear the margin. The surgical defect was repaired with a skin graft, and the patient remained disease free at 6-month follow-up.

Case Discussion

The pigmented variant of atypical fibroxanthoma was initially described by Diaz-Cascajo et al. in 1998 with a series of four patients and later in 2003 with five additional cases [3]. All of the patients were aged between 59 and 86 years and had presented with a nodule or plaque on the head and neck. The clinical diagnosis was melanocytic tumor in five cases (melanoma in three, metastatic melanoma in one, and melanocytic tumor in another), squamous cell

carcinoma in three, and *a priori* atypical fibroxanthoma in only one.

Histological examination showed that in all cases, atypical spindle cells with pleomorphic nuclei and abundant mitotic figures comprised a highly proliferative dermal tumor. Erythrocytes and

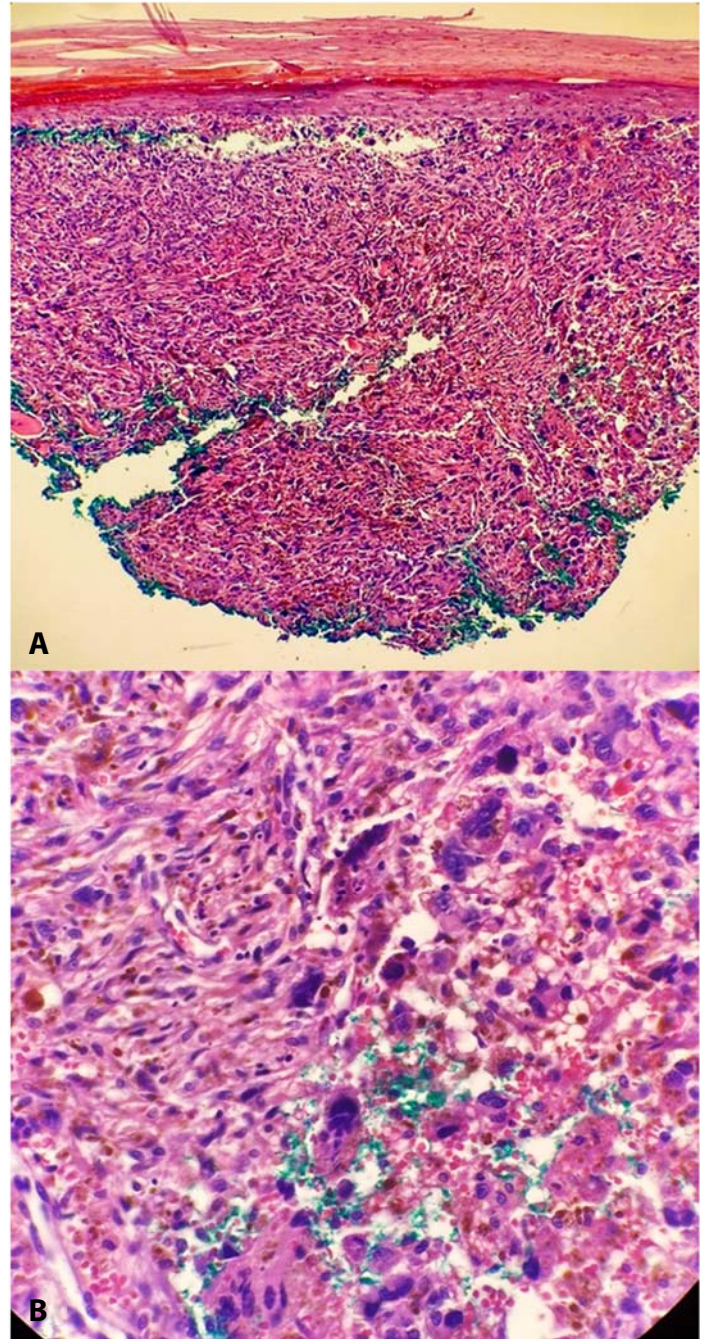


Figure 2. H&E histopathology. **A)** Section showing highly cellular proliferation in the dermis of plump spindle cells with nuclear atypia and brown granular deposits in the cytoplasm, 10 \times . **B)** Higher power shows the abundant pigment to be hemosiderin. The tumor cells demonstrate several bizarre nuclei and mitotic figures, 20 \times .

hemosiderin granules were observed in the cytoplasm of a variable number of tumor cells, in association with areas of intratumoral hemorrhage. The intratumoral deposits of hemosiderin may manifest clinically in the form of heterogeneous pigmentation, raising concern for malignant melanoma.

However, in melanocytic lesions, the pigmentation occurs as a result of melanin deposition, often in nests at the epidermal-dermal junction. In contrast, specific immunohistochemical stains for melanocytic lesions (S100, HMB45, MITF, SOX10) are notably negative in pigmented atypical fibroxanthoma.

Our patient demonstrated a pigmented lesion on the left ear that was initially concerning for melanoma. Histopathologically, the presence of pigmented granules in the cytoplasm led to identification with Prussian blue staining as hemosiderin, not melanin. Atypical fibroxanthoma is an uncommon, pleomorphic, spindle cell cutaneous malignancy that is often a diagnosis of exclusion, after epithelial, melanocytic, and vascular tumors have been ruled out. In our patient, immunohistochemistry was a valuable tool for differentiating atypical fibroxanthoma from other spindle cell tumors with similar clinical or histologic findings, including spindle cell squamous cell carcinoma and desmoplastic melanoma.

The pigmented or hemosiderotic variants of atypical fibroxanthoma have been rarely described in the literature [3-5]. Rarely, melanoma can histologically

mimic atypical fibroxanthoma [6]. Interestingly atypical fibroxanthoma within a malignant melanoma has been reported [7]. Complete surgical removal with Mohs micrographic surgery or wide excision with 2cm margins for atypical fibroxanthoma is the recommended method of treatment [8]. Atypical fibroxanthoma is considered a less aggressive superficial variant of pleomorphic dermal sarcoma (formerly known as malignant fibrous histiocytoma), [9]. Numerous histologic variants of atypical fibroxanthoma have been described, including clear-cell, desmoplastic or keloidal, granular, angiomatoid, hemosiderotic, and myxoid types [10].

Conclusion

Although rare, hemosiderotic (pigmented) atypical fibroxanthoma should be included in the differential diagnosis for a suspicious pigmented lesion. The ability of neoplastic cells to phagocytose erythrocytes ultimately leads to generation of brown pigment that is observed clinically, due to accumulation of hemosiderin in the cytoplasm. Special stains and immunohistochemistry are particularly useful for differentiating this pigmented variant of atypical fibroxanthoma from other tumors, such as malignant melanoma, that may present with similar clinical and pathological features.

Potential conflicts of interest

The authors declare no conflicts of interest.

References

1. Griewank KG, Wiesner T, Murali R, et al. Atypical fibroxanthoma and pleomorphic dermal sarcoma harbor frequent NOTCH1/2 and FAT1 mutations and similar DNA copy number alteration profiles. *Mod Pathology*. 2018;31:418-28. [PMID: 29099504].
2. Ang GC, Roenigk RK, Otley CC, et al. More than two decades of treating atypical fibroxanthoma at mayo clinic: what have we learned from 91 patients? *Dermatol Surg*. 2009;35:765-72. [PMID: 19389106].
3. Diaz-Cascajo C, Weyers W, Borghi S. Pigmented atypical fibroxanthoma: a tumor that may be easily mistaken for malignant melanoma. *Am J Dermatopathol*. 2003;25:1-5. [PMID: 12544091].
4. Pastor-Nieto MA, Kilmurray LG, Requena L. [Pigmented or hemosiderotic atypical fibroxanthoma]. *Actas Dermosifiliogr*. 2009;100:321-4. [PMID: 19463236].
5. Zelger B. Pigmented atypical fibroxanthoma, a dermatofibroma variant? *Am J Dermatopathol*. 2004;26:84-6; author reply 6-7. [PMID: 14726831].
6. Wang Y, Guo Y. Melanoma mimicking atypical fibroxanthoma: Report of an unusual case. *J Cutan Pathol*. 2021;48:1493-6. [PMID: 34258786].
7. Bhatti DS, Raj DRS, Khan MAA, et al. Atypical fibroxanthoma within a melanoma: A case report. *Cureus*. 2021;13:e20426. [PMID: 34926098].
8. Tolkachjov SN, Kelley BF, Alahdab F, et al. Atypical fibroxanthoma: Systematic review and meta-analysis of treatment with Mohs micrographic surgery or excision. *J Am Acad Dermatol*. 2018;79:929-34.e6. [PMID: 29981390].

9. Soleymani T, Tyler Hollmig S. Conception and management of a poorly understood spectrum of dermatologic neoplasms: Atypical fibroxanthoma, pleomorphic dermal sarcoma, and undifferentiated pleomorphic sarcoma. *Curr Treat Options Oncol.* 2017;18:50. [PMID: 28762020].
10. Gru AA, Santa Cruz DJ. Atypical fibroxanthoma: a selective review. *Semin Diagn Pathol.* 2013;30:4-12. [PMID: 23327726].