

# UC Irvine

## Clinical Practice and Cases in Emergency Medicine

### Title

A Case of COVID-19 Causing Croup

### Permalink

<https://escholarship.org/uc/item/17f4z03x>

### Journal

Clinical Practice and Cases in Emergency Medicine, 1(1)

### Authors

Hope, Ashley  
Myatt, Toby

### Publication Date

2017

### Copyright Information

Copyright 2017 by the author(s). This work is made available under the terms of a Creative Commons Attribution License, available at <https://creativecommons.org/licenses/by/4.0/>

Peer reviewed

## A Case of COVID-19 Causing Croup

Ashley Hope, BS  
Toby Myatt, MD

University of California, Irvine, Department of Emergency Medicine, Irvine, California

Section Editor: Christopher Sampson, MD

Submission history: Submitted February 5, 2021; Revision received April 9, 2021; Accepted April 22, 2021

Electronically published July 27, 2021

Full text available through open access at [http://escholarship.org/uc/uciem\\_cpchem](http://escholarship.org/uc/uciem_cpchem)

DOI: 10.5811/cpchem.2021.4.52071

**Introduction:** Viral laryngotracheobronchitis, or croup, is a common respiratory illness in children that presents with a fever, barking cough, and stridor. The most common viral origin of croup are the parainfluenza viruses.

**Case Presentation:** Here, we present a case of croup in which the viral panel was negative for all commonly tested viral causes of croup, but positive for coronavirus disease 2019 (COVID-19).

**Conclusion:** This case represents a new report of COVID-19 as the viral origin of croup. [Clin Pract Cases Emerg Med. XXXX;X(X):X–X.]

**Keywords:** COVID-19; SARS-COV-2; viral laryngotracheobronchitis; croup.

---

### INTRODUCTION

Viral laryngotracheobronchitis, or croup, is a common respiratory illness in children, which is clinically diagnosed and classically presents with fever, cough, and shortness of breath. These are also common symptoms for coronavirus disease 2019 (COVID-19). In this case report we present a child with croup caused by the severe acute respiratory syndrome coronavirus 2 (SARS-COV-2), review the clinical diagnosis of croup and COVID-19, and discuss important future directions in diagnosing croup and understanding COVID-19.

### CASE PRESENTATION

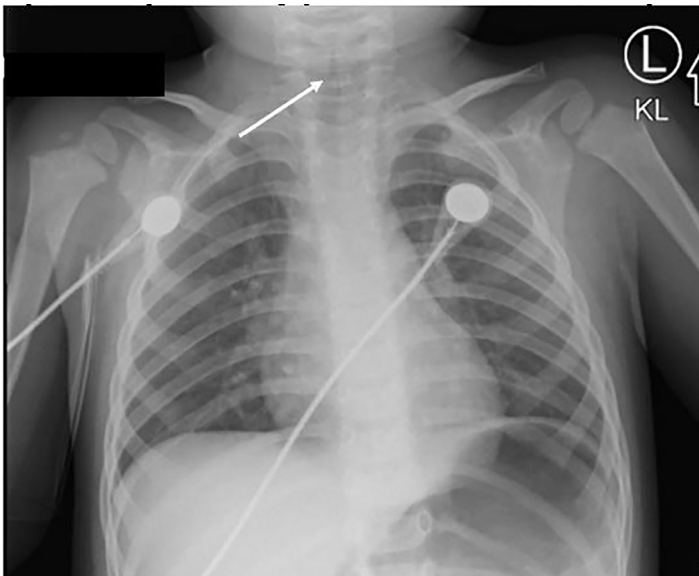
A 26-month-old male presented to the emergency department (ED) with shortness of breath. His mother reported that two nights earlier at night the patient developed a fever and “barky” cough with difficulty breathing. The patient’s pediatrician was called who suggested using a humidifier to treat the symptoms as the patient appeared to have croup. His fever was responsive to acetaminophen and ibuprofen, but his labored breathing did not improve on humidified air. On presentation to the ED, the patient was hypoxic to 77% on room air. On exam he had coarse breath sounds bilaterally with increased respiratory effort and retractions, without wheezes, rhonchi or rales. He was also febrile, tachypneic, and tachycardic. The patient was noted to have a dry, “seal-bark” cough.

On suspicion of croup, a chest radiograph (CXR) was obtained, which showed perihilar cuffing and a positive steeple sign (Image).

The patient was placed on supplemental oxygen and given two doses of racemic epinephrine as well as dexamethasone and acetaminophen. A nasal swab was obtained for multiplex testing by polymerase chain reaction (PCR), which returned negative for all viruses except for SARS-COV-2. Contact tracing revealed that the child’s parents had come into contact with two uncles who had tested positive for COVID-19 a few days prior to this visit. The patient was admitted to the hospital for two nights during which he continued to receive supplemental oxygen and racemic epinephrine treatments, eventually stabilizing and being subsequently discharged home.

### DISCUSSION

This case represents one of few reported cases of COVID-19 as the infectious origin of croup.<sup>1,2</sup> Viral laryngotracheobronchitis, or croup, is a common respiratory illness in children, which commonly presents with a fever, barking cough, and stridor. It is diagnosed clinically, with severity stratified according to the Westley croup score based on history and physical exam (Table). A positive steeple sign refers to the subglottic tracheal narrowing that resembles the steeple of a church seen on CXR, which supports but is not required to diagnose croup, as it is only 50% sensitive for croup and not specific.<sup>3</sup> Management of croup includes humidified oxygen, dexamethasone, nebulized epinephrine or racemic epinephrine and, if necessary, intubation.



**Image.** Chest radiograph of a 2-year-old male, showing subglottic tracheal narrowing (arrow) that resembles the steeple of a church – a positive “steeple sign” – which supports but is not required to diagnose croup.

Rates of COVID-19 in children are far lower than adults, comprising only approximately 8% of infections in the United States, with more reported cases asymptomatic or mild.<sup>1</sup> While rates of infection in children are rising nationally, the current rate for children zero to four-years-old is less than 2%, largely from household exposures (as in this case).<sup>4</sup> Our patient had three common symptoms of COVID-19: fever, dry cough, and shortness of breath and hypoxia.

As there are few reported cases of COVID-19 causing croup in a pediatric patient, it is worth discussing whether we should consider cases like these to be unusual presentations of COVID-19 masquerading as croup, or a case for adding COVID-19 to the list of viruses that can cause croup. No other viruses were detected in our patient – although it is not uncommon for COVID-19 patients to be co-infected with other viruses – suggesting that SARS-COV-2 caused his croup.

The most common viral origin of croup are the parainfluenza viruses, particularly parainfluenza virus type 1. Human coronavirus NL63 has recently been implicated in respiratory

*CPC-EM Capsule*

What do we already know about this clinical entity?  
*Coronavirus disease 2019 (COVID-19) is uncommon in children and often presents with fever, dry cough, shortness of breath, and hypoxia.*

What is the major impact of the image(s)?  
*This is one of few reported cases of COVID-19 presenting as the infectious origin of croup, a common respiratory illness usually diagnosed clinically.*

How might this improve emergency medicine practice?  
*Insight into pediatric presentations of COVID-19 will help improve the rapidly growing and changing body of knowledge on treating COVID-19 in the ED.*

illnesses, including croup.<sup>5</sup> Thus, it is not surprising that COVID-19, another coronavirus causing respiratory illness, could also cause croup. It is required now to screen all ED patients for COVID-19; however, even when the mandate and immediate need for it dissipates, it may be worth adding COVID-19 to the viral panel for determining the origin of croup.

**CONCLUSION**

Our knowledge of COVID-19 is incomplete and continually evolves. As the pandemic continues, it is worth noting other cases of croup caused by or co-infected by SARS-COV-2 to better understand the role of COVID-19 in this common pediatric condition, as well as to improve the underdeveloped knowledge of COVID-19 in pediatric patients.

**Table.** The Westley croup score is used to determine the severity of croup based on history and physical exam.

Westley Croup Score				
Level of Consciousness	Cyanosis	Stridor	Air entry	Retractions
0 – Normal	0 – None	0 – None	0 – Normal	0 – None
5 – Disoriented	4 – With agitation	1 – With agitation	1 – Decreased	1 – Mild
	5 – At rest	2 – At Rest	2 – Markedly decreased	2 – Moderate
				3 – Severe

Total Score: 0-2 Mild; 3-7 Moderate; 8-11 Severe; 12+ Impending respiratory failure

The authors attest that their institution requires neither Institutional Review Board approval, nor patient consent for publication of this case report. Documentation on file.

---

*Address for Correspondence:* Toby Myatt, MD, University of California, Irvine, Department of Emergency Medicine, 333 City Blvd West, Ste 640, Rt 128-01, Mail Code: 4064, Orange, CA 92868. Email: [myatt@hs.uci.edu](mailto:myatt@hs.uci.edu).

*Conflicts of Interest:* By the *CPC-EM* article submission agreement, all authors are required to disclose all affiliations, funding sources and financial or management relationships that could be perceived as potential sources of bias. The authors disclosed none.

*Copyright:* © 2021 Hope. This is an open access article distributed in accordance with the terms of the Creative Commons Attribution ([CC BY 4.0](https://creativecommons.org/licenses/by/4.0/)) License. See: <http://creativecommons.org/licenses/by/4.0/>

---

## REFERENCES

1. Pitstick CE, Rodriguez KM, Smith AC, et al. A curious case of croup: laryngotracheitis caused by COVID-19. *Pediatrics*. 2021;147(1):e2020012179.
2. Venn AMR, Schmidt JM, Mullan PC. A case series of pediatric croup with COVID-19. *Am J Emerg Med*. 2020;43:287.e1-3.
3. Rosekrans JA. Viral croup: current diagnosis and treatment. *Mayo Clin Proc*. 1998;73(11):1102-6.
4. Centers for Disease Control and Prevention. Coronavirus Disease 2019 (COVID-19) in the U.S. *Centers for Disease Control and Prevention*. 2020. Available at: <https://COVID.cdc.gov/COVID-data-tracker>. Accessed September 17, 2020.
5. Kuypers J, Martin ET, Heugel J, et al. Clinical disease in children associated with newly described coronavirus subtypes. *Pediatrics*. 2007;119(1):e70-6.