

UC Davis

Dermatology Online Journal

Title

Treatment of subcutaneous sarcoidosis with hydroxychloroquine: Report of 2 cases

Permalink

<https://escholarship.org/uc/item/19t4t1tm>

Journal

Dermatology Online Journal, 20(1)

Authors

Marchetti, Michael
Baker, Mary Grace
Noland, Mary-Margaret B

Publication Date

2014

DOI

10.5070/D3201021250

Copyright Information

Copyright 2014 by the author(s). This work is made available under the terms of a Creative Commons Attribution-NonCommercial-NoDerivatives License, available at <https://creativecommons.org/licenses/by-nc-nd/4.0/>

Peer reviewed

Case Presentation

Treatment of subcutaneous sarcoidosis with hydroxychloroquine: Report of 2 cases

Michael A. Marchetti MD¹, Mary Grace Baker BA³, Mary-Margaret B. Noland MD²

Dermatology Online Journal 20 (1): 9

¹Memorial Sloan-Kettering Cancer Center, Department of Medicine, Dermatology Service, New York, NY
University of Virginia, ²Department of Dermatology, ³School of Medicine, Charlottesville, VA

Correspondence:

Michael A. Marchetti, MD
Memorial Sloan-Kettering Cancer Center
New York, NY
marchetti.michael@gmail.com

Abstract

Although the therapeutic benefit of oral antimalarials in various types of sarcoidosis is well described, their reported use specifically in subcutaneous sarcoidosis (Darier-Roussy type sarcoidosis) is limited. We describe the cases of two patients with subcutaneous sarcoidosis treated with hydroxychloroquine, suggesting that it may represent an alternative first-line treatment for patients in whom steroid-sparing therapy is desired.

Keywords: sarcoidosis; subcutaneous sarcoidosis; Darier-Roussy; hydroxychloroquine; antimalarials; sarcoidosis/drug therapy; sarcoidosis/pathology; sarcoidosis/therapy; sarcoidosis/classification

Introduction

Subcutaneous sarcoidosis (Darier-Roussy type sarcoidosis) is a distinct cutaneous presentation of sarcoidosis characterized by typical sarcoidal granulomas restricted to the subcutaneous tissue [1]. Oral corticosteroids are considered first-line therapy but their continued use may lead to many side effects [2]. An effective first-line steroid-sparing agent would be advantageous, particularly in patients with pre-existing medical comorbidities. We report the use of hydroxychloroquine in subcutaneous sarcoidosis in two diabetic patients.

Case synopsis

A 54-year-old woman with a history of insulin-dependent diabetes mellitus presented with a 3-week history of indurated, erythematous subcutaneous nodules on her left arm (Figure 1). She had no history of any subcutaneous injections, including insulin, to the area. Skin biopsy revealed non-caseating granulomas in the deep dermis and subcutis surrounded by a moderate amount of lymphocytes (Figures 2-3). Polarized microscopy revealed no refractile foreign material and microbiologic stains and tissue cultures were negative, supporting a diagnosis of subcutaneous sarcoidosis. A systemic work-up including a chest radiograph, laboratory studies, and ophthalmologic examination did not reveal evidence of extracutaneous disease. The patient started hydroxychloroquine 200 milligrams (mg) by mouth twice daily and was noted to have 50% improvement at 4-week follow-up and 90% improvement at 12-week follow-up. Complete clinical resolution was documented at 5 months (Figure 4) and the patient was transitioned to hydroxychloroquine 200 mg by mouth once daily. At ten-month follow-up, the patient continued to have no clinical evidence of disease while on hydroxychloroquine 200 mg by mouth once daily.

The second patient was a 61-year-old non-insulin-dependent diabetic woman with a 1.5-year history of pulmonary sarcoidosis, previously treated with prednisone, who presented with a 4-week history of subcutaneous nodules on the right forearm. She had no history of any subcutaneous injections, including insulin, to the area. Histopathology demonstrated typical sarcoidal

granulomas in the subcutis with the absence of staining for microorganisms, consistent with subcutaneous sarcoidosis. Initial treatment with oral prednisone lead to disease resolution, but deep nodules returned on the bilateral forearms after medication cessation. She then started hydroxychloroquine 200 milligrams by mouth twice daily with a 50% improvement of her skin lesions at 3-month follow-up. Exam at 6 months demonstrated complete resolution of cutaneous disease, but resolution cannot be solely attributed to hydroxychloroquine because 4-6 weeks prior she had started oral prednisone and was maintained on 5 mg by mouth daily for presumed sarcoidosis-induced hypercalcemia. Upon withdrawal of oral prednisone, however, she has remained free of cutaneous disease for 7 months while continuing hydroxychloroquine 200 milligrams by mouth twice daily.

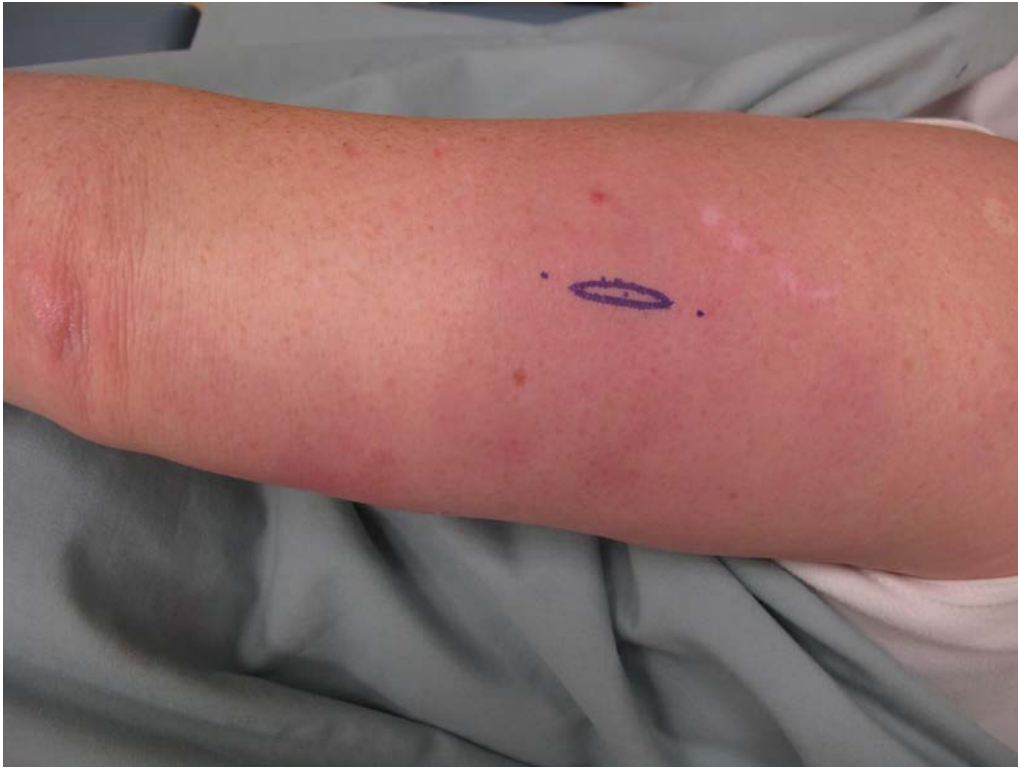

Figure 1. Ill-defined erythematous subcutaneous nodules on the left posterior arm

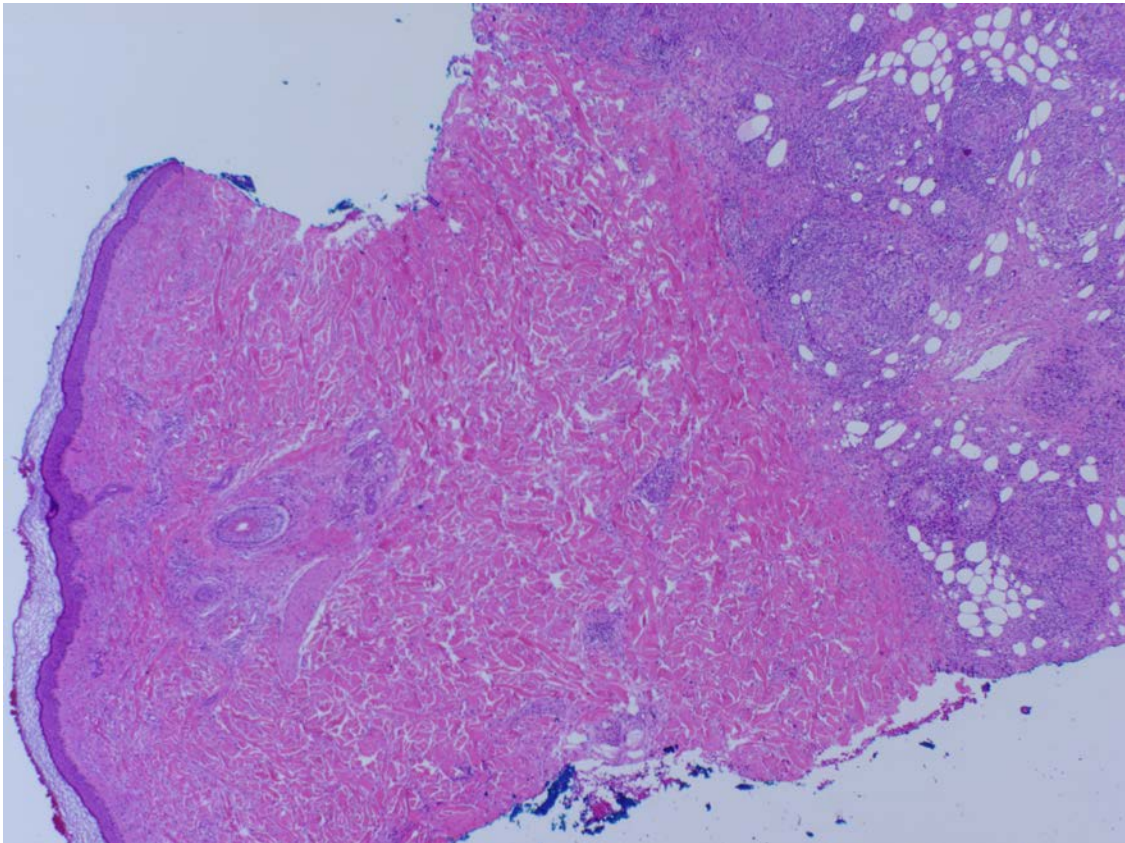


Figure 2. Incisional biopsy of the left posterior arm with granulomatous inflammation restricted to the subcutaneous tissue (Hematoxylin-eosin stain; original magnification: X2)

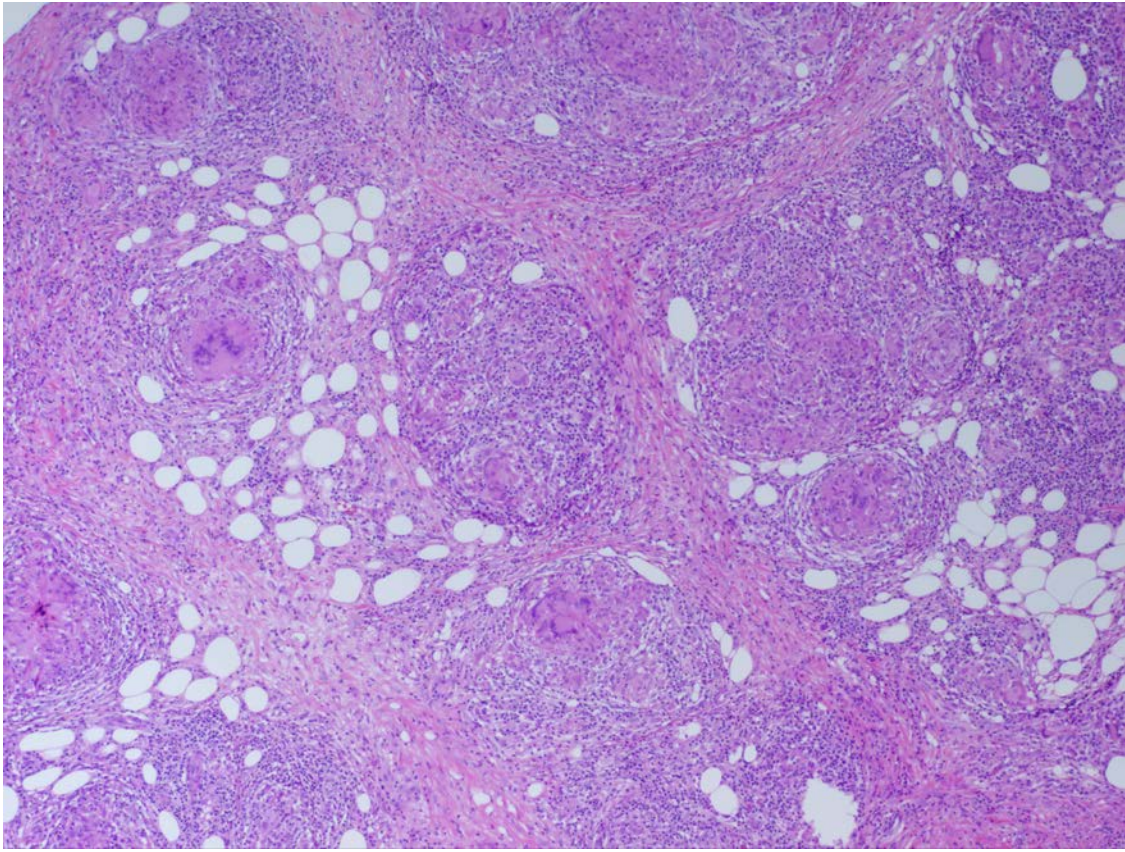


Figure 3. Typical non-caseating epithelioid granulomas in the subcutis surrounded by moderate lymphocytic infiltrate (Hematoxylin-eosin stain; original magnification: X4)

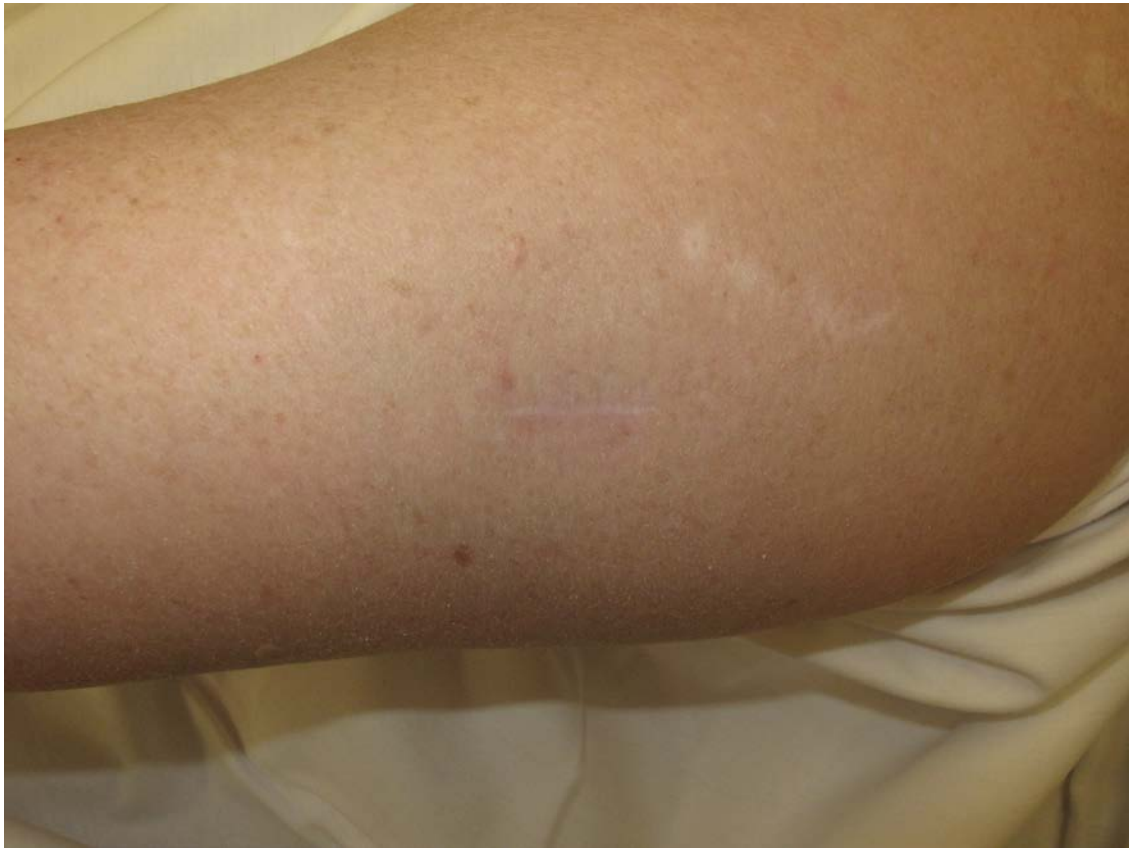

Figure 4. Resolution of cutaneous disease on the left posterior arm after five months of hydroxychloroquine 200 milligrams by mouth twice daily

Discussion

Sarcoidosis is characterized by non-caseating granuloma formation in tissue. Although the immunopathogenesis remains unknown, it is hypothesized that presentation of a putative antigen to a cluster of T cells (CD4⁺ T cells) leads to a cellular immune response and cytokine secretion (tumor necrosis factor-alpha (TNF- α), interleukin-12, interleukin-15, interleukin-18, and macrophage inflammatory protein-1) that produces granulomatous inflammation [3]. Via their lysosomotropic action within macrophages, dendritic cells, and lymphocytes, antimalarials may function in sarcoidosis by altering antigen presentation to CD4⁺ T cells. In vitro studies also demonstrate inhibition of macrophage and other inflammatory cell cytokine production, particularly TNF- α , interleukin-1, interleukin-6, interleukin-18, and interferon-gamma [4].

Although hydroxychloroquine is widely used in the treatment of sarcoidosis, the reported use of oral antimalarials specifically for subcutaneous sarcoidosis is sparse. Mizon-Pagniez et al. described a patient with subcutaneous and “elephantine” sarcoidosis who was treated with chloroquine monotherapy and experienced complete resolution of disease within two months [5]. Additionally, case reports of 5 patients have described improvement or resolution of subcutaneous sarcoidosis with concomitant corticosteroid and hydroxychloroquine therapy [6-9].

The growing body of evidence supporting the efficacy of oral antimalarials for the treatment of subcutaneous sarcoidosis suggests their role as a potential valuable first-line therapeutic option, particularly in patients with medical comorbidities that preclude the use of systemic corticosteroids. An alternative explanation for these findings includes spontaneous disease improvement unrelated to hydroxychloroquine therapy, highlighting the importance of future prospective randomized studies to validate these observations.

References

1. Vainsencher D, Winkelmann RK. Subcutaneous sarcoidosis. *Arch Dermatol*. 1984;120(8):1028–31. [PMID: 6465908]
2. Dalle Vedove C, Colato C, Girolomoni G. Subcutaneous sarcoidosis: report of two cases and review of the literature. *Clin Rheumatol*. 2011;30(8):1123-8. [PMID: 21461650]
3. Haimovic A, Sanchez M, Judson MA, Prystowsky S. Sarcoidosis: A comprehensive review and update for the dermatologist: Part I. Cutaneous disease. *J Am Acad Dermatol*. 2012;66(5):699.e1-18. [PMID: 22507585]
4. Kalia S, Dutz JP. New concepts in antimalarial use and mode of action in dermatology. *Dermatol Ther*. 2007;20(4):160-74. [PMID: 17970883]
5. Mizon-Pagniez I, Delaporte E, Alfandri S, Hachulla E, Rowland Payne CME, Piette F, Bergoend H. Subcutaneous and “elephantine” sarcoidosis successfully treated with chloroquine. *Eur J Dermatol*. 1995;5:310-2.
6. Na SY, Lee HY, Baek JO, Lee JR, Kim M, Roh JY. A case of subcutaneous sarcoidosis treated with hydroxychloroquine. *Korean J Dermatol*. 2007 Dec;45(12):1315-7.
7. Meyer-Gonzalez T, Suarez-Perez JA, Lopez-Navarro N, Hidalgo A, Herrera-Ceballos E. Subcutaneous sarcoidosis: A predictor of systemic disease? *Eur J Intern Med*. 2011 Dec;22(6):e162-3.
8. Ahmed I, Harshad SR. Subcutaneous sarcoidosis: Is it a specific subset of cutaneous sarcoidosis frequently associated with systemic disease? *J Am Acad Dermatol*. 2006;54:55-60.
9. García-Rabasco, AE, Esteve-Martínez A, Zaragoza-Ninet V, Vilata JJ, Alegre-de Miquel V. Subcutaneous sarcoidosis resembling cellulitis. *Actas Dermosifiliogr*. 2011;102(2):151-161.