

# UC Davis

## Dermatology Online Journal

### Title

Violaceous nodules in an HIV-positive man

### Permalink

<https://escholarship.org/uc/item/1b42h7nt>

### Journal

Dermatology Online Journal, 26(2)

### Authors

Scott, Brian L  
Dominguez, Arturo R  
Nguyen, Khang D

### Publication Date

2020

### DOI

10.5070/D3262047421

### Copyright Information

Copyright 2020 by the author(s). This work is made available under the terms of a Creative Commons Attribution-NonCommercial-NoDerivatives License, available at <https://creativecommons.org/licenses/by-nc-nd/4.0/>

Peer reviewed

# Violaceous nodules in an HIV-positive man

Brian L Scott<sup>1</sup> MD, Arturo R Dominguez<sup>2</sup> MD, Khang D Nguyen<sup>2</sup> MD

Affiliations: <sup>1</sup>Oregon Health & Science University, Portland, Oregon, USA, <sup>2</sup>University of Texas Southwestern Medical Center, Dallas, Texas, USA

Corresponding Author: Khang D. Nguyen MD, Assistant Professor, Department of Dermatology, UT Southwestern Medical Center, 5939 Harry Hines Boulevard, 4<sup>th</sup> floor, Suite 100, Dallas, TX 75390-9191, Tel: 214-645-2400, Fax: 214-645-8955, Email: [Khang.Nguyen@utsouthwestern.edu](mailto:Khang.Nguyen@utsouthwestern.edu)

## Abstract

Plasmablastic lymphoma (PBL) is a rare and aggressive malignancy associated with immunosuppression and the oncogenic effects of the Epstein-Barr virus (EBV). We present an HIV-positive man with PBL that presented as ulcers and violaceous exophytic nodules on the legs. The clinical features, histologic appearance, and differential diagnosis of this malignancy are briefly reviewed.

*Keywords: plasmablastic lymphoma, Epstein-Barr virus, hematologic malignancy*

## Introduction

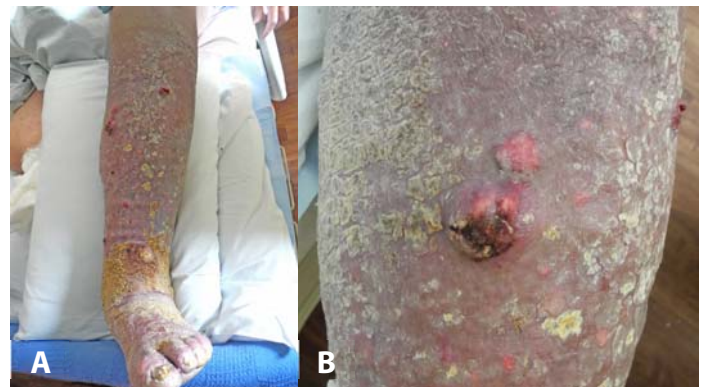Plasmablastic lymphoma (PBL) is a rare, aggressive malignancy that was initially described in 1997 [1]. There have been approximately 250 reported cases in the literature since then [1]. Most patients who develop PBL are immunosuppressed, particularly owing to HIV infection (69% of cases), [2]. HIV-associated PBL is found more commonly in men (3:1 M:F) with a median age of onset of 39-42 years old [3, 4]. The overwhelming majority (95%) of HIV-associated PBL cases present with extranodal involvement, most commonly the oral cavity (48%) and the gastrointestinal tract (12%), [2]. However, a small minority (6%) of patients with PBL present initially with skin complaints. We describe an HIV-positive man with PBL that presented as nodules and ulcers on the legs.

## Case Synopsis

A 53-year-old, man with HIV/AIDS, heart failure, venous stasis dermatitis, and recent right leg

amputation for osteomyelitis was evaluated for a two month history of left lower extremity pain and ulceration. His physical examination was notable for 2+ edema, yellow hyperkeratotic plaques, multiple small ulcers, and violaceous exophytic nodules on the left anterior and medial lower extremity (**Figure 1**). No other skin or mucosal lesions were noted. He denied fever, chills, night sweats, or a personal or family history of skin cancer. He underwent extensive laboratory studies that were notable for the following: WBC: 1.1 (4.0–10.3 x10<sup>9</sup> cells/L); Hgb: 7.0 (13.0–17.0 g/dL); platelets: 115.0 (160.0–380.0 x 10<sup>9</sup> cells/L); CD4: 81.0 (200.0–1400.0 cells/mcL); Ig kappa free light chains: 7.6 (0.3–1.9 mg/dL); Ig lambda free light chains: 3.5 (0.6–2.6 mg/dL); kappa/lambda 2.2 (0.3–1.7); UPEP with no M-spike.

Computed tomography scans of the head, neck, chest, and abdomen/pelvis demonstrated splenomegaly and multiple non-enlarged para-aortic and iliac lymph nodes. A bone marrow biopsy was negative for a hematolymphoid malignancy. A skin biopsy was performed (**Figure 2**) and found



**Figure 1.** **A)** Left lower extremity demonstrating a diffuse violaceous, yellow-brown coalescing hyperkeratotic plaques, ulcers, and exophytic violaceous nodules on the anterior and medial surfaces. **B)** Close-up photograph of the left shin demonstrating an ulcerated, violaceous nodule.

atypical enlarged immunoblastic cells, plasma cells, apoptotic bodies, and mitotic figures in the dermis. Immunostaining was positive for CD138, CD38, MUM1, and CD56. Tumor cells were negative for CD20, CD2, CD3, CD4, S-100, CD34, desmin, CD34, and HHV8. In-situ hybridization was positive for EBV and a kappa light chain restriction.

## Case Discussion

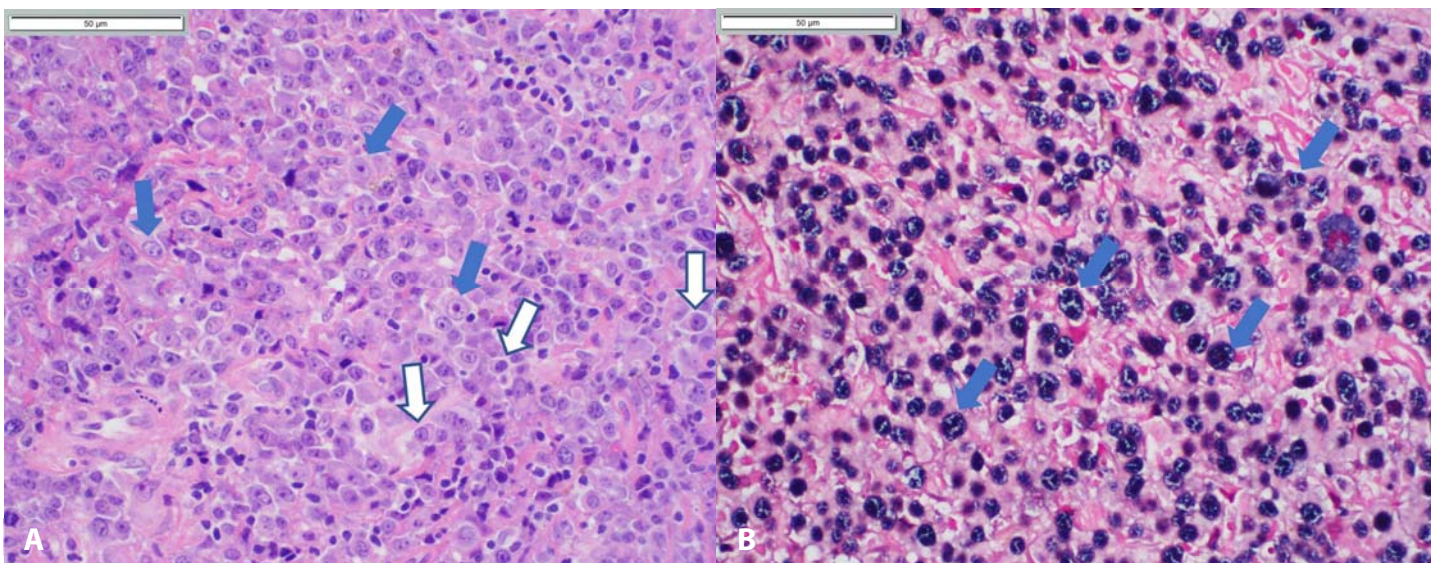
The differential diagnosis for exophytic violaceous skin nodules in an HIV positive individual is broad and includes angiosarcoma, Kaposi sarcoma, B-cell lymphomas, fungal infections, and mycobacterial infections. Within the category of B-cell lymphomas, a rare and highly aggressive cause is plasmablastic lymphoma.

Plasmablastic lymphoma is a high-grade malignancy characterized by proliferation of large immunoblastic-appearing cells with centrally-located, round nuclei with prominent eosinophilic nucleoli. Some tumors exhibit a histomorphology displaying more obvious plasmacytic differentiation with eccentric nuclei with ample basophilic cytoplasm and eosinophilic perinuclear hof [3]. Mitotic figures are generally abundant and the presence of numerous scavenger macrophages imparts a characteristic starry sky appearance to the

neoplastic infiltrate. Immunohistochemistry is key to the diagnosis, with PBL generally staining positive for multiple plasma cell markers including CD79a, MUM-1, BLIMP-1, CD38, and CD138, but not the B-cell markers CD19 or CD20 [2]. Kappa and lambda studies show a monocytic light chain restriction.

Plasmablastic lymphoma is difficult to differentiate from plasmablastic/anaplastic multiple myeloma on biopsy as they have identical histomorphology and immunophenotype. However, the presence of EBV strongly favors PBL. If present, paraproteinemia, hypercalcemia, lytic bone lesions, and immunocompetence favor multiple myeloma. In contrast to plasmablastic lymphoma and multiple myeloma, diffuse large B-cell lymphoma is CD20 positive. Rare cases of PBL positive for human herpesvirus 8 have been reported, a variant closely related to plasmablastic multicentric Castleman disease [5]. The pathogenesis of PBL is debated, but it is believed to be related to the oncogenic effects of EBV infection on B-cells and Myc gene arrangements. EBV is found in 70-75% of cases [2, 4], whereas Myc gene rearrangements are found in 67% [4].

Plasmablastic lymphoma is treated with immune reconstitution and chemotherapy but is characterized by early chemotherapy resistance. Stage of disease at presentation is strongly correlated with survival; 50% of patients with stage 1



**Figure 2.** Skin biopsy. **A)** Solid arrows indicate enlarged immunoblastic cells while unfilled arrows point at plasma cells. H&E, 40x. **B)** Solid arrows point at cells showing strong nuclear positivity for Epstein Barr virus by in-situ hybridization, 40x.

disease (single lymph node region) remain alive at 30 months compared to 30% of those with stage 4 disease (diffuse involvement of extralymphatic organs), [3]. Untreated patients have a median survival of around four months if HIV negative and three months if HIV positive [6]. Median survival increases to 16 months in patients who receive chemotherapy [6]. Our patient was started on chemotherapy (cyclophosphamide, vincristine, prednisolone, and bortezomib) and highly-active antiretroviral therapy, but unfortunately passed away one month after initiation of chemotherapy.

## References

1. Bibas M, Castillo JJ. Current knowledge on HIV-associated Plasmablastic Lymphoma. *Mediterr J Hematol Infect Dis.* 2014;6:e2014064. [PMID: 25408850].
2. Castillo JJ, Bibas M, Miranda RN. The biology and treatment of plasmablastic lymphoma. *Blood.* 2015;125:2323-2330. [PMID: 25636338].
3. Morscio J, Dierickx D, Nijs J, et al. Clinicopathologic comparison of plasmablastic lymphoma in HIV-positive, immunocompetent, and posttransplant patients: single-center series of 25 cases and meta-analysis of 277 reported cases. *Am J Surg Pathol.* 2014;38:875-886. [PMID: 24832164].
4. Loghavi S, Alayed K, Aladily TN, et al. Stage, age, and EBV status impact outcomes of plasmablastic lymphoma patients: a clinicopathologic analysis of 61 patients. *J Hematol Oncol.* 2015;10:65. [PMID: 26055271].
5. Dupin N, Diss TL, Kellam P, et al. HHV-8 is associated with a plasmablastic variant of Castleman disease that is linked to HHV-8-positive plasmablastic lymphoma. *Blood.* 2000;95:1406-12. [PMID: 10666218].
6. Castillo JJ, Winer ES, Stachurski D, et al. Clinical and pathological differences between human immunodeficiency virus-positive and human immunodeficiency virus-negative patients with plasmablastic lymphoma. *Leuk Lymphoma.* 2010;51:2047-2053. [PMID: 20919850].

## Conclusion

Plasmablastic lymphoma is a rare malignancy associated with immunosuppression that may present first to the dermatologist. Given the aggressive clinical course of PBL, it is important that dermatologists consider PBL in the differential diagnosis for rapidly growing nodules and ulcers in an immunosuppressed patient.

## Potential conflicts of interest

The authors declare no conflicts of interests.