

# UC Irvine

## Clinical Practice and Cases in Emergency Medicine

### Title

CPC-EM Full Text Issue

### Permalink

<https://escholarship.org/uc/item/1cc0x04p>

### Journal

Clinical Practice and Cases in Emergency Medicine, 6(3)

### Author

Rafi, Rubina

### Publication Date

2022

### DOI

10.5811/cpcem.2022.8.58466

### Copyright Information

Copyright 2022 by the author(s). This work is made available under the terms of a Creative Commons Attribution License, available at <https://creativecommons.org/licenses/by/4.0/>

Peer reviewed

# CPC Emergency Medicine

Volume 6, Number 3, August 2022

Open Access at [www.cpcem.org](http://www.cpcem.org)

ISSN: 2474-252X

## *Clinical Practice and Cases in Emergency Medicine*

In Collaboration with the *Western Journal of Emergency Medicine*

### Clinicopathological Cases from the University of Maryland

- 198** 60-year-old Female with Edema  
*Cali NA, Falat C, Bontempo LJ, Gatz JD*

### Case Series

- 204** Role of Tele-ultrasound for Teaching Ultrasound-guided Nerve Blocks in the Emergency Department: A Case Series from Peru  
*Martin DA, Guillen M, Farro A, Condori M, Dreyfuss A, Nagdev A*

### Case Reports

- 208** Hyperaldosteronism and Renal Artery Stenosis in a Post-Abdominal Aortic Aneurysm Patient: A Case Report  
*Davis K, Gilani CJ, Sudario G*
- 212** Occipital Lobe Status Epilepticus, A Stroke Mimic with Novel Imaging Findings: A Case Report  
*Lawson J, Triner W, Kluge B*
- 216** Level I Hyperglycemia: A Case Report  
*Nassal M, San Miguel C*
- 220** Diagnosing Pheochromocytoma in the COVID-19 Era: A Case Report  
*Mayer III F, Memon R, Stowens J*
- 225** Takotsubo Cardiomyopathy Following Traumatic Hand Amputation: A Case Report  
*Bacro-Duverger BH, Throburn AQ, Denney BD, Gullett JP, Thompson MA, Pigott DC*
- 229** Atypical Presentation of Traumatic Pediatric Carotid Artery Dissection: A Case Report  
*McGuire D, Mielke N, Bahl A*
- 232** Bilateral Central Retinal Vein Occlusion as a First Presentation of Multiple Myeloma: A Case Report  
*Tandlich MA, Williamson K*

Contents continued on page iii



**UC Irvine Health**



A Peer-Reviewed, International Professional Journal



**ACOEP stands with all emergency  
physicians and providers on the  
front line. We thank you for your  
tireless work and effort.**



[www.acoep.org](http://www.acoep.org)

# Clinical Practice and Cases in Emergency Medicine

Indexed in PubMed and full text in PubMed Central

**Rick A. McPheeters, DO, Editor-in-Chief**  
Kern Medical/UCLA- Bakersfield, California

**R. Gentry Wilkerson, MD, Deputy Editor**  
University of Maryland School of Medicine

**Mark I. Langdorf, MD, MHPE, Senior Associate Editor**  
University of California, Irvine School of Medicine- Irvine, California

**Shahram Lotfipour, MD, MPH, Senior Associate Editor**  
University of California, Irvine School of Medicine- Irvine, California

**Shadi Lahham, MD, MS, Associate Editor**  
Kaiser Permanente- Orange County, California

**Manish Amin, DO, Associate Editor**  
Kern Medical/UCLA- Bakersfield, California

**John Ashurst, DO, Decision Editor/ ACOEP Guest Editor**  
Kingman Regional Health Network, Arizona

**Anna McFarlin, MD, Decision Editor**  
Louisiana State University Health Science Center- New Orleans, Louisiana

**Christopher Sampson, MD, Decision Editor**  
University of Missouri- Columbia, Missouri

**Joel Moll, MD, Decision Editor**  
Virginia Commonwealth University School of Medicine- Richmond, Virginia

**Steven Walsh, MD, Decision Editor**  
Einstein Medical Center Philadelphia-Philadelphia, Pennsylvania

**Melanie Heniff, MD, JD, Decision Editor**  
University of Indiana School of Medicine- Indianapolis, Indiana

**Austin Smith, MD, Decision Editor**  
Vanderbilt University Medical Center-Nashville, Tennessee

**Rachel A. Lindor, MD, JD, Decision Editor**  
Mayo Clinic College of Medicine and Science

**Jacqueline K. Le, MD, Decision Editor**  
Desert Regional Medical Center

**Christopher San Miguel, MD, Decision Editor**  
Ohio State University Wexner Medical Center

## Editorial Board

Amin A. Kazzi, MD, MAAEM  
The American University of Beirut, Beirut,  
Lebanon

Anwar Al-Awadhi, MD  
Mubarak Al-Kabeer Hospital, Jabriya,  
Kuwait

Arif A. Cevik, MD  
United Arab Emirates University  
College of Medicine and Health Sciences, Al  
Ain, United Arab Emirates

Abhinandan A. Desai, MD  
University of Bombay Grant Medical  
College, Bombay, India

Bandr Mzahir, MD  
King Fahad Medical City, Riyadh, Saudi  
Arabia

Barry E. Brenner, MD, MPH  
Case Western Reserve University

Brent King, MD, MMM  
University of Texas, Houston

Daniel J. Dire, MD  
University of Texas Health Sciences Center  
San Antonio

David F.M. Brown, MD  
Massachusetts General Hospital/Harvard  
Medical School

Edward Michelson, MD  
Texas Tech University

Edward Panacek, MD, MPH  
University of South Alabama

Erik D. Barton, MD, MBA  
Icahn School of Medicine, Mount Sinai,  
New York

Francesco Dellacorte, MD  
Azienda Ospedaliera Universitaria "Maggiore  
della Carità," Novara, Italy

Francis Counselman, MD  
Eastern Virginia Medical School

Gayle Galleta, MD  
Sørlandet Sykehus HF, Akershus  
Universitetssykehus, Lorenskog, Norway

Hjalte Björnsson, MD  
Icelandic Society of Emergency Medicine

Jacob (Kobi) Peleg, PhD, MPH  
Tel-Aviv University, Tel-Aviv, Israel

Jonathan Olshaker, MD  
Boston University

Katsuhiro Kanemaru, MD  
University of Miyazaki Hospital, Miyazaki, Japan

Khrongwong Musikatavorn, MD  
King Chulalongkorn Memorial Hospital,  
Chulalongkorn University, Bangkok,  
Thailand

Leslie Zun, MD, MBA  
Chicago Medical School

Linda S. Murphy, MLIS  
University of California, Irvine School of  
Medicine Librarian

Nadeem Qureshi, MD  
St. Louis University, USA  
Emirates Society of Emergency Medicine,  
United Arab Emirates

Niels K. Rathlev, MD  
Tufts University School of Medicine

Pablo Aguilera Fuenzalida, MD  
Pontificia Universidad Católica de Chile,  
Región Metropolitana, Chile

Peter A. Bell, DO, MBA  
Baptist Health Science University

Peter Sokolove, MD  
University of California, San Francisco

Robert M. Rodriguez, MD  
University of California, San Francisco

Robert Suter, DO, MHA  
UT Southwestern Medical Center

Robert W. Derlet, MD  
University of California, Davis

Rosidah Ibrahim, MD  
Hospital Serdang, Selangor, Malaysia

Samuel J. Stratton, MD, MPH  
Orange County, CA, EMS Agency

Scott Rudkin, MD, MBA  
University of California, Irvine

Scott Zeller, MD  
University of California, Riverside

Steven Gabaeff, MD  
Clinical Forensic Medicine

Steven H. Lim, MD  
Changi General Hospital, Simei, Singapore

Terry Mulligan, DO, MPH, FIFEM  
ACEP Ambassador to the Netherlands Society of  
Emergency Physicians

Vijay Gautam, MBBS  
University of London, London, England

Wirachin Hoonpongmanont, MD, MSBATS  
Siriraj Hospital, Mahidol University, Bangkok,  
Thailand

## Advisory Board

Amal Khalil, MBA  
UC Irvine Health School of Medicine

Elena Lopez-Gusman, JD  
California ACEP  
American College of Emergency Physicians

Adam Levy, BS  
American College of Osteopathic Emergency  
Physicians

John B. Christensen, MD  
California Chapter Division of AAEM

Randy Young, MD  
California ACEP  
American College of Emergency  
Physicians

Mark I. Langdorf, MD, MHPE  
UC Irvine Health School of Medicine

Jorge Fernandez, MD  
California ACEP  
American College of Emergency Physicians  
University of California, San Diego

Peter A. Bell, DO, MBA  
American College of Osteopathic Emergency  
Physicians  
Baptist Health Science University

Robert Suter, DO, MHA  
American College of Osteopathic Emergency  
Physicians  
UT Southwestern Medical Center

Shahram Lotfipour, MD, MPH  
UC Irvine Health School of Medicine

Brian Potts, MD, MBA  
California Chapter Division of AAEM  
Alta Bates Summit-Berkeley Campus

## Editorial Staff

Isabelle Nepomuceno, BS  
Executive Editorial Director

Anuki Edirimuni, BS and Visha  
Bajaria, BS  
WestJEM Editorial Director

Zaynab Ketana, BS  
CPC-EM Editorial Director  
Associate Marketing Director

Stephanie Burmeister, MLIS  
WestJEM Staff Liaison

June Casey, BA  
Copy Editor

Cassandra Saucedo, BS  
Executive Publishing Director

Jordan Lam, BS  
WestJEM Publishing Director

Rubina Rafi, BS  
CPC-EM Publishing Director

Avni Agarwal, BS  
CPC-EM Associate Publishing Director  
Associate Marketing Director

Official Journal of the California Chapter of the American College of Emergency Physicians, the American College of Osteopathic Emergency Physicians, and the California Chapter of the American Academy of Emergency Medicine



Available in MEDLINE, PubMed, PubMed Central, Google Scholar, eScholarship, DOAJ, and OASPA.

Editorial and Publishing Office: WestJEM/Department of Emergency Medicine, UC Irvine Health, 333 City Blvd, West, Rt 128-01, Orange, CA 92866, USA

Office: 1-714-456-6389; Email: Editor@westjem.org

# Clinical Practice and Cases in Emergency Medicine

Indexed in PubMed and full text in PubMed Central

This open access publication would not be possible without the generous and continual financial support of our society sponsors, department and chapter subscribers.

## Professional Society Sponsors

AMERICAN COLLEGE OF OSTEOPATHIC EMERGENCY PHYSICIANS  
CALIFORNIA ACEP

CALIFORNIA CHAPTER DIVISION OF  
AMERICAN ACADEMY OF EMERGENCY MEDICINE

## Academic Department of Emergency Medicine Subscribers

Albany Medical College Albany, NY	INTEGRIS Health Oklahoma City, OK	Robert Wood Johnson University Hospital New Brunswick, NJ	University of Florida, Jacksonville Jacksonville, FL
American University of Beirut Beirut, Lebanon	Kaweah Delta Health Care District Visalia, CA	Rush University Medical Center Chicago, IL	University of Illinois at Chicago Chicago, IL
Arrowhead Regional Medical Center Colton, CA	Kennedy University Hospitals Turnersville, NJ	Southern Illinois University Carbondale, IL	University of Illinois College of Medicine Peoria, IL
Augusta University Augusta GA	Kern Medical Bakersfield, CA	St. Luke's University Health Network Bethlehem, PA	University of Iowa Iowa City, IA
Baystate Medical Center Springfield, MA	Lakeland HealthCare St. Joseph, MI	Stanford/Kaiser Emergency Medicine Residency Program Stanford, CA	University of Louisville Louisville, KY
Beaumont Hospital Royal Oak, MI	Lehigh Valley Hospital and Health Network Allentown, PA	Staten Island University Hospital Staten Island, NY	University of Maryland Baltimore, MD
Beth Israel Deaconess Medical Center Boston, MA	Loma Linda University Medical Center Loma Linda, CA	SUNY Upstate Medical University Syracuse, NY	University of Michigan Ann Arbor, MI
Boston Medical Center Boston, MA	Louisiana State University Health Sciences Center New Orleans, LA	Temple University Philadelphia, PA	University of Missouri, Columbia Columbia, MO
Brigham and Women's Hospital Boston, MA	Madigan Army Medical Center Tacoma, WA	Texas Tech University Health Sciences Center El Paso, TX	University of Nebraska Medical Center Omaha, NE
Brown University Providence, RI	Maimonides Medical Center Brooklyn, NY	University of Alabama, Birmingham Birmingham, AL	University of South Alabama Mobile, AL
Carl R. Damall Army Medical Center Fort Hood, TX	Maricopa Medical Center Phoenix, AZ	University of Arkansas for Medical Sciences Little Rock, AR	University of Southern California/Keck School of Medicine Los Angeles, CA
Conemaugh Memorial Medical Center Johnstown, PA	Massachusetts General Hospital Boston, MA	University of California, Davis Medical Center Sacramento, CA	University of Tennessee, Memphis Memphis, TN
Desert Regional Medical Center Palm Springs, CA	Mayo Clinic College of Medicine Rochester, MN	University of California Irvine Orange, CA	University of Texas, Houston Houston, TX
Doctors Hospital/Ohio Health Columbus, OH	Mt. Sinai Medical Center Miami Beach, FL	University of California, Los Angeles Los Angeles, CA	University of Texas Health San Antonio, TX
Eastern Virginia Medical School Norfolk, VA	North Shore University Hospital Manhasset, NY	University of California, San Diego La Jolla, CA	University of Warwick Library Coventry, United Kingdom
Einstein Healthcare Network Philadelphia, PA	Northwestern Medical Group Chicago, IL	University of California, San Francisco San Francisco, CA	University of Washington Seattle, WA
Emory University Atlanta, GA	Ohio State University Medical Center Columbus, OH	UCSF Fresno Center Fresno, CA	University of Wisconsin Hospitals and Clinics Madison, WI
Genesys Regional Medical Center Grand Blanc, Michigan	Ohio Valley Medical Center Wheeling, WV	University of Chicago, Chicago, IL	Wake Forest University Winston-Salem, NC
Hartford Hospital Hartford, CT	Oregon Health and Science University Portland, OR	University of Colorado, Denver Denver, CO	Wright State University Dayton, OH
Hennepin County Medical Center Minneapolis, MN	Penn State Milton S. Hershey Medical Center Hershey, PA	University of Florida Gainesville, FL	
Henry Ford Hospital Detroit, MI	Presence Resurrection Medical Center Chicago, IL		

## State Chapter Subscribers

ARIZONA CHAPTER DIVISION OF THE  
AMERICAN ACADEMY OF EMERGENCY MEDICINE  
CALIFORNIA CHAPTER DIVISION OF THE  
AMERICAN ACADEMY OF EMERGENCY MEDICINE  
FLORIDA CHAPTER DIVISION OF THE  
AMERICAN ACADEMY OF EMERGENCY MEDICINE

GREAT LAKES CHAPTER DIVISION OF THE  
AMERICAN ACADEMY OF EMERGENCY MEDICINE  
TENNESSEE CHAPTER DIVISION OF THE  
AMERICAN ACADEMY OF EMERGENCY MEDICINE

UNIFORMED SERVICES CHAPTER DIVISION OF THE  
AMERICAN ACADEMY OF EMERGENCY MEDICINE  
VIRGINIA CHAPTER DIVISION OF THE  
AMERICAN ACADEMY OF EMERGENCY MEDICINE

## International Society Partners

EMERGENCY MEDICINE ASSOCIATION OF TURKEY  
LEBANESE ACADEMY OF EMERGENCY MEDICINE  
MEDITERRANEAN ACADEMY OF EMERGENCY MEDICINE

NORWEGIAN SOCIETY FOR EMERGENCY MEDICINE  
SOCIEDAD ARGENTINA DE EMERGENCIAS

SOCIEDAD CHILENO MEDICINA URGENCIA  
THAI ASSOCIATION FOR EMERGENCY MEDICINE

To become a *WestJEM* departmental sponsor, waive article processing fee, receive print and copies for all faculty and electronic for faculty/residents, and free CME and faculty/fellow position advertisement space, please go to <http://westjem.com/subscribe> or contact:

Alissa Fiorentino  
*WestJEM* Staff Liaison  
Phone: 1-800-884-2236  
Email: [sales@westjem.org](mailto:sales@westjem.org)

## JOURNAL FOCUS

*Clinical Practice and Cases in Emergency Medicine* (CPC-EM) is a MEDLINE-indexed internationally recognized journal affiliated with the *Western Journal of Emergency Medicine* (WestJEM). It offers the latest in patient care case reports, images in the field of emergency medicine and state of the art clinicopathological and medicolegal cases. CPC-EM is fully open-access, peer reviewed, well indexed and available anywhere with an internet connection. CPC-EM encourages submissions from junior authors, established faculty, and residents of established and developing emergency medicine programs throughout the world.

## Table of Contents *continued*

- 236 Hypotension Unresponsive to Fluid Resuscitation: A Case Report**  
*M Mameledzija, E Nasrallah, M Hatrich*
- 240 When a Headache is More than the Flu: A Case Report**  
*AE Russ, AM Morse, DM Spiro*
- 244 Delayed Recognition of Severe Systemic Envenomation after Copperhead Bite: A Case Report**  
*PE Kelly, CJ Gerardo*
- 248 Real-time Ultrasound-Guided Manual Testicular Detorsion: A Case Report**  
*WT Smith, S Midgley, T Kummer*

### Images in Emergency Medicine

- 252 Nail Gun Injury of the Trachea and Spinal Cord**  
*K Shibahashi, K Numata*
- 254 Evolving Paralysis after Motor Vehicle Collision**  
*N Prendergast, Y Duanmu*
- 256 A Strange Twist**  
*A O'Connell, R Kong, R Biswas, J Greenstein, B Hahn*
- 259 Pediatric Cranial Dog Bite Injuries: More than Meets the Eye**  
*SA Tahir, KZ Carver, A Cappitelli, L Baird, A Marchese, IM Ganske*
- 262 Omental Prolapse Through Vaginal Cuff Dehiscence**  
*J Solberg, K Saravana*
- 264 Infant with Groin Swelling**  
*N Polavarapu, B Kilbane*
- 266 Exertional Near-Syncope: Pericardial Cyst as a Cause of Left Ventricular Outflow Obstruction**  
*R Offman, J Skopak*
- 268 Snocross "Shark-bite" Laceration**  
*W Telken, J Solberg, M Raymond*

Policies for peer review, author instructions, conflicts of interest and human and animal subjects protections can be found online at [www.cpcem.org](http://www.cpcem.org).

# *Clinical Practice and Cases in Emergency Medicine*

Indexed in PubMed and full text in PubMed Central

## JOURNAL FOCUS

*Clinical Practice and Cases in Emergency Medicine* (CPC-EM) is a MEDLINE-indexed internationally recognized journal affiliated with the *Western Journal of Emergency Medicine* (WestJEM). It offers the latest in patient care case reports, images in the field of emergency medicine and state of the art clinicopathological and medicolegal cases. CPC-EM is fully open-access, peer reviewed, well indexed and available anywhere with an internet connection. CPC-EM encourages submissions from junior authors, established faculty, and residents of established and developing emergency medicine programs throughout the world.

## Table of Contents *continued*

- 270**    **Point-of-care Ultrasound to Distinguish Retinal Detachment and Ruptured Arterial Microaneurysm**  
*R Kester, S Szymanski, M Perreault*

Policies for peer review, author instructions, conflicts of interest and human and animal subjects protections can be found online at [www.cpcem.org](http://www.cpcem.org).

# CPCEM

Clinical  
Practice  
& Cases

## CALL FOR SUBMISSIONS

- Patient Care Case Reports
- Images in Emergency Medicine

Fully open-access, peer reviewed, well indexed: CPC-EM is available anywhere with an internet connection at **CPCEM.org**

***Clinical Practice and Cases in Emergency Medicine*** is an internationally recognized journal affiliated with the MEDLINE-indexed ***Western Journal of Emergency Medicine***

**CPC-EM encourages submissions from junior authors and countries with developing emergency medicine programs**

# CPCEM

Clinical  
Practice  
& Cases

## **CALL FOR CPC-EM SECTION EDITORS!**

- Medical-Legal Case Reports
- Case Reports/Images in Emergency Medicine

**Send your CV and letter of interest to  
[editor@westjem.org](mailto:editor@westjem.org)**





Journal of Education & Teaching *in* Emergency Medicine

*A publication of* **CORD**

*Education*

We believe that all learners should benefit from active learning.

We are an online, open access, peer-reviewed journal-repository for EM educators in all major topic areas.

*Scholarship*

We believe educators should advance through the scholarship of their educational work. JETem gives you the opportunity to publish & distribute your outstanding, scholarly academic work.

**Submit your content or contact us to become a reviewer!**



*visualem*



*small groups*



*tbl*



*simulation*



*lecture*



*oral boards*



*podcasts*



*curriculum*



*innovations*

[www.jetem.org](http://www.jetem.org)



*published by*

**eScholarship University of California**




# Revenue Cycle & Practice Management Solutions.

Brault offers scalable services to support your emergency medicine practice.

Whether you're looking for a full-service RCM partner, a support team to manage your business functions, or a group of experts to advise and help grow your practice—**Brault has everything you need under one umbrella.**



Schedule a Free Review today at [www.Brault.us](http://www.Brault.us)



# ADVANCED >

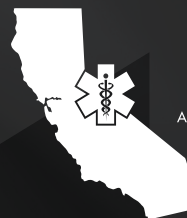## MEET THE MOMENT

### > CALIFORNIA ACEP'S ANNUAL CONFERENCE 2022

Education is targeted to Medical Students and Residents, but all are welcome to attend.

**Friday, September 2, 2022**

Westin San Diego Gaslamp Quarter



**CALIFORNIA ACEP**  
AMERICAN COLLEGE OF EMERGENCY PHYSICIANS



# UC Irvine Health

## School of Medicine

### *Department of Emergency Medicine*

#### *Position: Ultrasound Director*

The Department of Emergency Medicine at the University of California, Irvine School of Medicine is seeking applicants for a faculty position in the Health Sciences Clinical Professor Series, at the Assistant, Associate, or Full Professor rank.

The University of California, Irvine Medical Center is a 472-bed tertiary care hospital with all residencies. The ED is a progressive 35-bed Level I Trauma Center with 50,000 patients, in urban Orange County. The ED has collegial relationships with all services and offers excellent salary and benefits with an incentive plan.

#### **Criteria for the Health Sciences Clinical Professor Series:**

The incumbent will be expected to teach residents and medical students; provide direct patient care; perform research and/or creative work; and public and University service. Candidates must have demonstrated capabilities for teaching and research or creative work suitable for this series.

Candidates must possess an M.D. or D.O. degree, board certification in Emergency Medicine, and be eligible for a California Medical License. Fellowship sub-specialization in Ultrasound is also required.

The successful candidate will be expected to engage in the following:

- Maintain function and peak performance of all 6 ultrasound trollies, 4 boom-mounted machines, and 8 handheld units
- Review all EM resident scans for competency and graduation requirements
- Optimize documentation templates
- Maintain Clinical Ultrasound Accreditation Program through ACEP
- Monitor credentialing progress for each new faculty and nurse practitioner
- Administer annual "bootcamp" for all new EM faculty, residents, and fellows
- Provide Chair with quarterly faculty ultrasound metrics
- Work with hospital IT to troubleshoot workflow and middleware issues
- Establish and maintain an active transesophageal echo program
- Oversee ultrasound quality assurance

Academic rank, step, and salary will be based upon the candidate's training, qualifications, and experience.

**Application Instructions** - To be considered for the position, interested candidates should visit: <https://recruit.ap.uci.edu/JPF07727>, complete an online application profile and upload application materials electronically.

## 60-year-old Female with Edema

Nikki A. Cali, MD\*

Cheyenne Falat, MD†

Laura J. Bontempo, MD, MEd†

J. David Gatz, MD†

\*University of Maryland Medical Center, Department of Emergency Medicine, Baltimore, Maryland

†University of Maryland School of Medicine, Department of Emergency Medicine, Baltimore, Maryland

Section Editor: Joel Moll, MD

Submission history: Submitted April 11, 2022; Revision received June 8, 2022; Accepted June 24, 2022

Electronically published August 8, 2022

Full text available through open access at [http://escholarship.org/uc/uciem\\_cpccem](http://escholarship.org/uc/uciem_cpccem)

DOI: 10.5811/cpcem.2022.4.57085

**Introduction:** Many patients present to the emergency department (ED) with nonspecific, acute-on-chronic complaints. It requires a thorough diagnostic approach and broad differential diagnosis to determine whether there is serious, undiagnosed pathology.

**Case Presentation:** A 60-year-old female presented to the ED for gradually worsening bilateral lower extremity swelling with associated abdominal distension, ascites, diarrhea, vomiting, and weight loss.

**Discussion:** This case takes the reader through the evaluation of a patient with acute-on-chronic complaints who presented in a decompensated state. [Clin Pract Cases Emerg Med. 2022;6(3):198–203.]

**Keywords:** *emergency medicine; clinicopathological conference; case reports; edema; carcinoid tumor; malignant carcinoid syndrome; carcinoid heart disease.*

### CASE PRESENTATION (Dr. Cali)

A 60-year-old female presented to the emergency department (ED) with a chief complaint of bilateral lower extremity swelling. She first noticed the swelling three months earlier and felt it was gradually worsening. The swelling initially started in her legs and abdomen but then progressed to her face. She denied any associated pain in her legs but reported that they felt heavy. She denied associated orthopnea, cough, or shortness of breath. She denied any change in activity tolerance but did report a decline in her daily activities due to social distancing because of coronavirus 2019. She also described chronic, brown loose stools over the past year, which were unrelated to her diet. She had loose stools daily, which were not particularly malodorous and not associated with abdominal pain. She also noted non-bloody, non-bilious emesis intermittently over the prior year without any clear, identifiable triggers. She had a remote history of vomiting in the past with panic attacks; so she attributed her vomiting to anxiety. She also noted a 15-pound weight loss during the preceding year, which she attributed to not eating

regular meals throughout the day coupled with her persistent vomiting. She denied fevers, chills, night sweats, or chest pain.

Her past medical history included a recent diagnosis of a heart murmur one year earlier. She also had a history of anxiety, panic attacks, depression, an eating disorder (low-baseline caloric intake), and psoriasis. She was previously on fluoxetine and hydroxyzine but took herself off several years earlier as she felt they were not working. She was no longer taking any medication at the time of presentation. She was post-menopausal and had irregular periods prior to menopause. She had no children and had never been pregnant.

Vital signs were as follows: temperature 38.4° Celsius, heart rate 140 beats per minute (bpm), blood pressure 120/80 millimeters of mercury, respiratory rate 27 breaths per minute (rpm) and room air oxygen saturation 100%. Her body mass index was 27. Her physical exam was notable for a well-developed female who appeared tired and uncomfortable. Her head, eyes, ear, nose, and throat exam was significant for facial swelling and pupils that were midrange, equal, round, and reactive to light bilaterally. She had moist mucous membranes and no lymphadenopathy or palpable masses. On

cardiac exam she had a harsh 4/6 blowing systolic murmur that was loudest at the left sternal border but also auscultated through her back. She was tachypneic but had clear lung sounds. Her abdomen was distended with a fluid wave and dullness to percussion but was nontender. Her extremities were notable for 3+ pitting edema from her feet to her bilateral upper thighs. No upper extremity edema was present. On neurologic exam she had no focal deficits. She was awake, alert, and oriented to person, place, and time. Her skin was warm and dry. Her initial laboratory results (Table 1) showed multiple abnormalities. An electrocardiogram (ECG) was performed (Image 1). A computed tomography (CT) of her abdomen and pelvis with intravenous (IV) contrast was also obtained (Image 2).

The patient was initially treated with IV fluids and piperacillin-tazobactam due to concerns for sepsis with her fever and tachycardia. She acutely worsened after administration of fluids. She subsequently was placed on non-invasive ventilation and was administered IV furosemide. A test was then ordered, and a diagnosis was made.

#### CASE DISCUSSION (Dr. Falat)

A chief complaint of “edema” was rarely one that excited me. When I see a patient with edema, it is generally a problem that they have presented with previously, or it is not a terribly difficult diagnostic dilemma. So, when I was handed this case of a 60-year-old female presenting with three months of gradually worsening bilateral lower extremity edema progressing to the abdomen, I will admit that my adrenaline did not immediately surge. However, a few additional historical points did stand out to me that were somewhat atypical: she had no complaints of pain, and she was no longer able to eat regular meals. This was not going to be a simple or typical case of edema.

I like to think of edema in dichotomies: unilateral vs bilateral, and acute vs chronic. The causes of each of these categories vary and are listed in Table 2. This patient presented with chronic bilateral edema, and because my involvement in her case was through our clinicopathological case conference, I immediately felt confident excluding venous insufficiency and lymphedema, as I anticipated there to be a much more interesting etiology of her presentation (being common presentations of common diseases).

Her review of systems was significant for fevers, 15-pound weight loss, facial swelling, bilateral lower extremity edema, abdominal distention, loose brown diarrhea, random episodes of emesis without an obvious trigger, right shoulder pain, psoriatic rash, and nervousness. Could her right shoulder pain or vomiting have been due to atypical anginal symptoms? Could her fever have been indicative of endocarditis? Could her abdominal distention have been due to ascites from liver disease? My mind immediately began elevating cardiac and hepatic diseases in my differential diagnosis.

Her review of systems was also notably negative for shortness of breath, orthopnea, dyspnea on exertion, cough, chest pain, palpitations, abdominal pain, malodorous stool, or change to exercise tolerance. With that, cardiac and pulmonary disease were slightly lowered on my differential diagnosis. While going over her past medical history, medications, surgical history, social history, and family history, I noted her “heart murmur,” eating disorder, psoriasis, and absence of IV drug use. But none of those pieces of information were a game-changer at this point in her puzzle.

Next came her exam. She was tachycardic with a heart rate of 140 bpm, tachypneic with a respiratory rate of 27 rpm, and febrile with a temperature of 38.4°C. She appeared tired and uncomfortable, with a round and swollen face. She had a grade 4/6 blowing systolic murmur that was best heard at the left sternal border and back. She had abdominal distention with findings consistent with ascites but no abdominal tenderness, and she had pitting edema of bilateral lower extremities extending up to her thighs. I found the detailed description of her murmur very interesting; so her cardiac exam anchored my focus.

Cardiac murmurs can also be thought of in dichotomies: systolic vs diastolic and left vs right. Left-heart systolic murmurs are those of aortic stenosis or mitral regurgitation; right-heart systolic murmurs are those of pulmonic stenosis or tricuspid regurgitation; left-heart diastolic murmurs are those of aortic regurgitation or mitral stenosis; and right-heart diastolic murmurs are those of pulmonic regurgitation or tricuspid stenosis. Because hers was a systolic murmur, I reviewed the classic descriptions of those murmurs in further detail.

An aortic stenosis murmur is classically described as “a crescendo-decrescendo systolic murmur along the left sternal border that radiates to the upper right sternal border and into the carotid arteries.”<sup>1</sup> A mitral regurgitation murmur is classically described as “holosystolic, radiating into the axilla” and “usually heard best at the apex.”<sup>1</sup> A pulmonic stenosis murmur is classically described as “midsystolic... crescendo-decrescendo” with a “pulmonic ejection click” at the “second intercostal space at the left sternal border.”<sup>2</sup> I was getting a little overwhelmed with all these descriptions that did not quite fit the murmur of this patient when I read the classic description of a tricuspid regurgitation murmur: a “blowing, holosystolic... murmur best heard at the lower left sternal border.”<sup>2</sup> Jackpot. This exactly matched the description of the patient’s murmur.

My focus darted to the differential diagnosis for causes of tricuspid regurgitation. The patient had no history of pacemaker placement, so I knew it could not be pacemaker lead trauma. Similarly, I felt confident excluding deceleration injury, sequela of an Ebstein anomaly, or drug-induced disease given there was no history to support any of those entities. With rheumatic heart disease, infective endocarditis, pulmonary hypertension, carcinoid syndrome, ischemic heart

**Table 1.** Laboratory results of a 60-year-old female with bilateral lower extremity swelling.

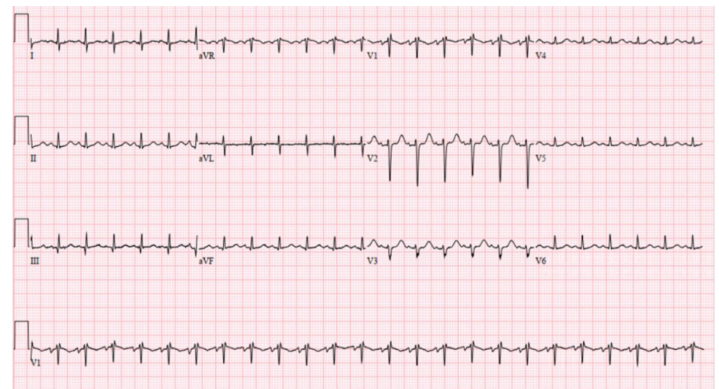
Blood test	Patient value	Normal range
Complete blood count		
White blood cells	16.1 K/mcL	4.5 – 13.0 K/mcL
Hemoglobin	9.2 g/dL	12 – 16 g/dL
Hematocrit	29.3%	36.0 – 46.0%
Platelets	578 K/mcL	153 – 367 K/mcL
Differential		
Polymorphonuclear leukocytes	78.5%	42.6–74.5%
Lymphocytes	13.9%	20.8–50.5%
Monocytes	6.1%	2–10%
Eosinophils	0.2%	1–3%
Serum chemistries		
Sodium	137 mmol/L	136–145 mmol/L
Potassium	2.7 mmol/L	3.5–5.1 mmol/L
Chloride	109 mmol/L	98–107 mmol/L
Bicarbonate	17 mmol/L	21–30 mmol/L
Blood urea nitrogen	15 mg/dL	7–17 mg/dL
Creatinine	0.66 mg/dL	0.42–0.92 mg/dL
Glucose	136 mg/dL	70–99 mg/dL
Magnesium	1.9 mg/dL	1.6–2.6 mg/dL
Phosphorus	2.6 mg/dL	2.8–4.6 mg/dL
Total protein	5.2 g/dL	6.3–8.6 g/dL
Albumin	2.3 g/dL	3.5–5.2 g/dL
Hepatic Studies		
Total bilirubin	1.0 mg/dL	0.3–1.2 mg/dL
Aspartate aminotransferase	37 u/L	14–36 u/L
Alanine aminotransferase	20 u/L	0–34 u/L
Alkaline phosphatase	153 u/L	50–130 u/L
Cardiac Studies		
N-terminal prohormone of brain natriuretic peptide	2,200 pg/mL	<900 pg/mL
Troponin	<0.02 ng/mL	<0.06 ng/mL
Coagulation studies		
Prothrombin time	16.5 seconds	12.1–15.0 seconds
Partial thromboplastin time	36 seconds	25–38 seconds
International normalized ratio	1.3	
Other		
C-reactive protein	4.3 mg/dL	<1.0 mg/dL

K, thousand; mcL, microliter; g, gram; dL, deciliter; mmol, millimole; L, liter; mg, milligram; u, microgram; pg, picogram; ml, milliliter; ng, nanogram.

**Table 1.** Continued.

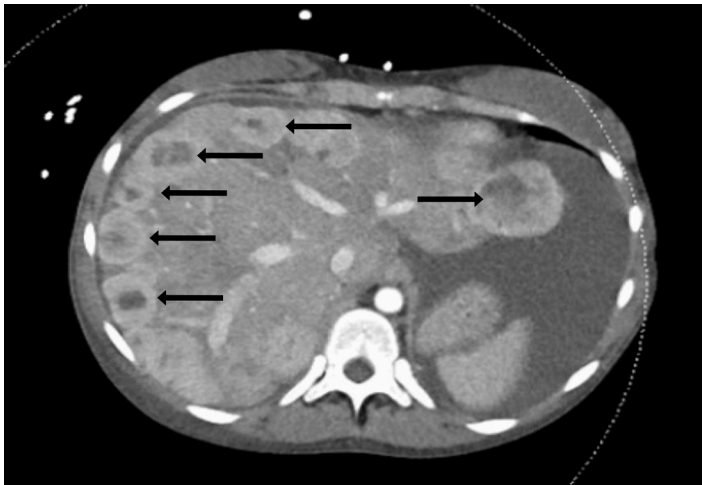
Blood test	Patient value	Normal range
Lactate dehydrogenase	696 units/L	240–670 units/L
Uric acid	8.0 mg/dL	2.6–6.0 mg/dL
Ammonia	60 mcmol/L	9–30 mcmol/L
Thyroid stimulating hormone	1.88 mIU/L	0.50–4.50 mIU/L
Respiratory viral panel		
SARS-CoV-2 (COVID-19) RNA	Not detected	
Influenza A RNA amplification	Not detected	
Influenza B RNA amplification	Not detected	
Parainfluenza 1,2,3,4 Virus RNA amplification	Not detected	
Rhinovirus/enterovirus RNA amplification	Not detected	
RSV RNA amplification	Not detected	

dL, deciliter; L, liter; mg, milligram; mcmol, micromoles; mIU, milli-international units; SARS-CoV-2, severe acute respiratory syndrome coronavirus 2; COVID-19, coronavirus 2019; RNA, ribonucleic acid; RSV, respiratory syncytial virus.

**Image 1.** Electrocardiogram of a 60-year-old female with bilateral lower extremity swelling showing sinus tachycardia, normal axis, normal intervals, and no ST or T wave changes.

disease, myxomatous degeneration, and connective tissue disorder still on the list, I turned to her labs.

This patient had notable abnormalities of leukocytosis, thrombocytosis, and an elevated C-reactive protein, but these are all nonspecific elevations and did not hint toward a diagnosis. Her elevated brain natriuretic peptide indicated perhaps cardiomegaly or strain. Her elevated lactate dehydrogenase and uric acid revealed the possibility of



**Image 2.** Computed tomography axial view with intravenous contrast of the abdomen of a 60-year-old female with bilateral lower extremity swelling. Multiple hepatic lesions are demonstrated (white arrows).

**Table 2.** Differential diagnosis of lower extremity edema.

	Acute	Chronic
Unilateral	Deep vein thrombosis Cellulitis Compartment syndrome Muscle rupture	Venous insufficiency Lymphedema Malignancy Complex regional pain syndrome
Bilateral	Medications (calcium channel blockers, steroids, hormones) Bilateral or pelvic deep vein thromboses	Venous insufficiency Lymphedema Systemic (cardiac, hepatic, renal, or pulmonary) disease

increased cell turnover. And her elevated ammonia level suggested the possibility of primary hepatic failure or the presence of a portosystemic shunt such as in the setting of portal venous hypertension secondary to vascular congestion. I interpreted her hypokalemia as confirming her reports of vomiting and diarrhea. Additionally, decreased protein and albumin, such as hers, can be found in cases of nephrotic syndrome but also in cases of hepatic disease, causing increased capillary permeability and decreased albumin synthesis.

Along with her lab abnormalities, she had notable normal values of magnesium (which was important to check given her hypokalemia), blood urea nitrogen and creatinine (which is important since I was considering renal disease), aminotransferases (which is important since I was considering hepatic disease), thyroid-stimulating hormone (which was important to check given her profound tachycardia), and troponin (which was important to check given her worsened vs new cardiac murmur).

After reviewing her labs, I significantly lowered primary hepatic failure and renal failure on my differential

diagnosis because otherwise I would have expected more profound derangements in her labs. And after reviewing her ECG, which showed no right axis deviation, and her chest radiograph (CXR), which did not reveal increased pulmonary vascular markings, I lowered and ultimately removed pulmonary hypertension and pulmonary disease off my differential.

This left me with cardiac disease as the cause of her edema, and specifically cardiac valvular disease since her exam perfectly described tricuspid regurgitation. I knew that an echocardiogram was at some point going to be performed, which, I presumed, would confirm the diagnosis of tricuspid regurgitation. But tricuspid regurgitation alone did not explain all her associated symptoms on her review of systems. And I was still left with the nagging question of “Why?” Why had she developed tricuspid regurgitation?

Her negative troponin, absence of chest pain, and absence of Q waves or ischemic changes on her ECG allowed me to cross off ischemic heart disease. I removed myxomatous degeneration and connective tissue disorders off the differential diagnosis of tricuspid regurgitation because her history did not reveal any other findings to anchor these diagnoses. Her absence of reported IV drug use, human immunodeficiency virus, prosthetic heart valves, dental work, or rheumatic heart disease allowed me to remove both infective endocarditis and rheumatic heart disease. Which left me with carcinoid syndrome.

Never having previously diagnosed a new case of carcinoid syndrome in my career, I needed to review this entity to make sure I was not way off base. Carcinoid syndrome is a constellation of symptoms arising from secretion of substances from a variety of neuroendocrine tumors (NET), with presentations varying based on the location of the primary tumors and the substances they secrete. The tumors tend to be indolent, but metastases (liver, lymph nodes, peritoneum) are common, and carcinoid syndrome usually presents once hepatic metastases arise. And after staring at the CT of her abdomen, I noticed her clear hepatic metastases staring back at me. Furthermore, carcinoid tumors are associated with cardiac fibrosis (thought to be caused by serotonin secretion from the tumors) of the right-sided valves resulting in tricuspid regurgitation and pulmonic stenosis.

Equipped with this knowledge, never had I felt so confident in making a diagnosis that I had never previously made. The patient’s symptoms and the pathophysiology of carcinoid syndrome came together like a perfect symphony. Her fevers were in the setting of flushing vs neoplastic symptoms. Her edema was due to tricuspid regurgitation causing congestive hepatopathy vs hepatic metastases. Her diarrhea and tachycardia were from her carcinoid secretory effects. Her weight loss, abdominal distention, and irregular meal habits were due to early satiety from hepatomegaly and ascites. Her labs indicated increased neoplastic cell turnover. And her beautifully described tricuspid regurgitation murmur



clinched the diagnosis since right-sided valvular cardiac fibrosis is associated with carcinoid syndrome. The most common way to diagnosis carcinoid syndrome is by a 24-hour urine collection of 5-hydroxyindoleacetic acid (5-HIAA). And with that test, I'll never look at edema with boredom again.

### CASE OUTCOME (Dr. Cali)

After the CT of the abdomen and pelvis showed multiple enhancing nodules scattered throughout the liver, the leading diagnosis was metastatic lesions, but from an unknown primary source. The patient presented to the ED in decompensated right heart failure with signs of volume overload on clinical exam including pitting edema and abdominal ascites. Her 4/6 blowing holosystolic murmur, which was best auscultated overlying the left upper sternal border, was of significant concern, and an echocardiogram was obtained. The echocardiogram showed moderate to severe tricuspid valve insufficiency, mild to moderate pulmonary valve stenosis, and mildly depressed right ventricular systolic function. In conjunction with the patient's liver lesions, these findings on echocardiogram led to a strong suspicion for carcinoid heart disease.

To confirm the diagnosis of carcinoid heart disease, the liver tumors were biopsied. Immunostains of the biopsies were positive for chromogranin and synaptophysin, negative for cytokeratin 7, cytokeratin 20, anti-hepatocyte specific antigen 1, and beta-catenin, which was consistent with a well-differentiated NET.

The patient was started on medical management including the somatostatin analog octreotide to help with her diarrhea. She ultimately required bivalvular replacement of both the tricuspid and pulmonic valves due to the extent of her cardiac disease. Her hospital course was complicated by multiple infections including endocarditis, and she ultimately did not survive the disease, dying less than two months after her initial ED presentation.

### RESIDENT DISCUSSION

Carcinoid tumors are extremely rare NETs that occur in approximately 1 in 100,000 individuals in the general population.<sup>3</sup> They are commonly found in the gastrointestinal system, anywhere from the embryologic foregut to the hindgut, with the appendix and terminal ileum being the most common sites.<sup>4</sup> Other less common sites for carcinoid tumors include the respiratory and genitourinary tracts.

Carcinoid tumors are indolent growing tumors with a peak incidence occurring between the sixth and seventh decade of life.<sup>5</sup> These tumors remain asymptomatic for several years and do not produce symptoms until they metastasize, which makes an early diagnosis challenging. Once carcinoid tumors metastasize, they have the potential to produce carcinoid syndrome, which is characterized by intermittent facial flushing, intractable secretory diarrhea, and bronchoconstriction.<sup>4</sup> However, classic carcinoid syndrome occurs in fewer than 10%

of patients with carcinoid tumors; so, a high index of clinical suspicion is imperative to make the diagnosis.<sup>6</sup>

Carcinoid syndrome is caused by vasoactive substances, such as serotonin, that are released by the tumor into the blood stream and evade hepatic degradation. When carcinoid tumors exist in the gastrointestinal system in isolation, serotonin and other vasoactive substances are degraded by monoamine oxidases in the liver, lungs, and brain into secretory byproducts, most notably 5-HIAA, which do not manifest into clinical symptoms.<sup>7</sup> When carcinoid tumors metastasize to the liver they evade hepatic degradation and their vasoactive substances are released into systemic circulation to exert downstream effects on the right side of the heart causing carcinoid heart disease.

Carcinoid heart disease was first reported in 1954. Although the mechanism behind its development is not fully understood, serotonin is considered a major initiator of the fibrotic process.<sup>3,6</sup> When the right side of the heart is exposed to serotonin from systemic circulation, this results in endocardial damage causing thickening, retraction, and fixation of the right heart valves, valvular dysfunction, and ultimately right heart failure.<sup>8</sup> Pathognomonic echocardiographic features include immobility of valve leaflets resulting in tricuspid valve regurgitation and pulmonary stenosis.<sup>4</sup> The right side of the heart is predominately affected because serotonin is degraded in the pulmonary circulation before it can reach the left side of the heart in its active form.

The diagnosis of carcinoid syndrome and carcinoid heart disease is multifactorial. First, the astute clinician must have a high index of suspicion based on the patient's history and physical exam. History may include episodic flushing episodes, which can be triggered by alcohol, exercise, or tyramine-containing foods in addition to complaints of diarrhea and wheezing. The patient should also be screened for any murmurs on cardiac exam.<sup>7</sup> In the setting of advanced carcinoid heart disease, the patient will present with signs of right-sided heart failure including jugular venous distension, ascites, dependent edema, weight gain, and hepatomegaly. Brain natriuretic peptide will likely be elevated, but this is neither sensitive nor specific to carcinoid heart disease. Key diagnostic testing includes a 24-hour urine 5-HIAA sample, which has a sensitivity of 73% and specificity of 100% for diagnosing carcinoid.<sup>7</sup>

In a patient who presents with a heart murmur and signs of heart failure, an echocardiogram is imperative to diagnosing carcinoid heart disease. Imaging such as CXRs and ECGs are typically nonspecific but should be included in the patient's workup. Computed tomography is futile in detecting primary carcinoid tumors but is helpful to evaluate extent of tumor spread.<sup>7</sup> Unfortunately, because many patients present later in their disease course, CTs are often the first identification of metastatic spread. A more sensitive imaging modality to detect smaller carcinoid tumors is somatostatin receptor scintigraphy, a radiolabeled imaging test based on the principle that

approximately 88% of carcinoid tumors possess somatostatin receptors.<sup>9</sup> This helps in diagnosing earlier, primary tumors that CT can miss.

Treatment of carcinoid disease requires a multidisciplinary approach with surgical and medical oncologists, as well as gastroenterologists. In early, non-metastatic disease, surgical resection can be curative.<sup>4</sup> In the presence of carcinoid syndrome, medical management consists of somatostatin analogs such as octreotide and lanreotide to control symptoms of flushing and diarrhea caused by secretion of tumor bioactive agents.<sup>6,10</sup> However, symptom control is typically temporary, and tumor debulking including liver resection is considered in more severe cases, when possible. In the presence of cardiac involvement with valvular dysfunction, additional management is focused on treating right-sided heart failure. Cardiac valve surgery is proposed as a final curative intervention only for patients who are mildly symptomatic due to increased perioperative mortality with more advanced heart failure.<sup>6</sup> Once cardiac involvement is present, it cannot be reversed without surgical intervention, which is why early detection and intervention of carcinoid tumors remains a strong prognostic indicator of morbidity and mortality.

## FINAL DIAGNOSIS

### Carcinoid Heart Disease

## KEY TEACHING POINTS

1. If you lack clinical suspicion for carcinoid syndrome, you will never make the diagnosis.
2. Carcinoid syndrome should be considered in any patient with persistent, unexplained diarrhea or a new right-sided heart murmur without an alternate explanation.
3. Carcinoid tumors typically become symptomatic after metastasizing to the liver.
4. Tricuspid regurgitation and pulmonary stenosis are hallmark echocardiogram findings in carcinoid heart disease.

The authors attest that their institution requires neither Institutional Review Board approval, nor patient consent for publication of this case report. Documentation on file.

**Address for Correspondence:** J. David Gatz, MD, University of Maryland, Department of Emergency Medicine, 110 S Paca St, 6th floor, Suite 200, Baltimore, MD 21201. Email: jgatz@som.umaryland.edu.

**Conflicts of Interest:** By the CPC-EM article submission agreement, all authors are required to disclose all affiliations, funding sources and financial or management relationships that could be perceived as potential sources of bias. The authors disclosed none.

**Copyright:** © 2022 Cali et al. This is an open access article distributed in accordance with the terms of the Creative Commons Attribution (CC BY 4.0) License. See: <http://creativecommons.org/licenses/by/4.0/>

## REFERENCES

1. Maganti K, Rigolin VH, Sarano ME, et al. Valvular heart disease: diagnosis and management. *Mayo Clin Proc.* 2010;85(5):483-500.
2. Alpert MA. Systolic Murmurs. In: Walker HK, Hall WD, Hurst JW, eds. *Clinical Methods: The History, Physical, and Laboratory Examinations.* 3rd ed. Boston: Butterworths; 1990.
3. Bhattacharyya S, Davar J, Dreyfus G, et al. Carcinoid heart disease. *Circulation.* 2007;116(24):2860-5.
4. Fox DJ and Khattar RS. Carcinoid heart disease: presentation, diagnosis, and management. *Heart.* 2004;90(10):1224-8.
5. Vinik A, Hughes MS, Feliberti E, et al. Carcinoid tumors. 2000. Available at: <https://www.ncbi.nlm.nih.gov/books/NBK279162/>. Accessed July 30, 2022.
6. Gustafsson B, Hauso O, Drozdov I, et al. Review: carcinoid heart disease. *Int J Cardiol.* 2008;129(3):318-24.
7. Gade AK, Olariu E, Douthit N. Carcinoid syndrome: a review. *Cureus.* 2020;12(3).
8. Møller JE, Connolly HM, Rubin J, et al. Factors associated with progression of carcinoid heart disease. *N Engl J Med.* 2003;348(11):1005-15.
9. Ganim RB, Norton JA. Recent advances in carcinoid pathogenesis, diagnosis and management. *Surg Oncol.* 2000;9(4):173-9.
10. Riechelmann RP, Pereira AA, Rego JFM, et al. Refractory carcinoid syndrome: a review of treatment options. *Ther Adv Med Oncol.* 2016;9(2):127-37.

# Role of Tele-ultrasound for Teaching Ultrasound-guided Nerve Blocks in the Emergency Department: A Case Series from Peru

David A. Martin, MD\*  
Marco Guillen, MD†  
Angel Farro, MD‡  
Maribel Condori, MD‡  
Andrea Dreyfuss, MD, MPH§  
Arun Nagdev, MD\*

\*Highland Hospital - Alameda Health System, Department of Emergency Medicine, Oakland, California  
†EsSalud Cusco: Hospital Nacional Adolfo Guevara Velasco, Department of Emergency Medicine, Cusco, Peru  
‡Hospital Nacional Dos de Mayo, Parque "Historia de la Medicina Peruana." Department of Emergency Medicine, Lima, Peru  
§Hennepin County Medical Center, Department of Emergency Medicine, Minneapolis, Minnesota

Section Editors: Shadi Lahham, MD

Submission history: Submitted January 02, 2022; Revision received February 10, 2022; Accepted February 24, 2022

Electronically published July 27, 2022

Full text available through open access at [http://escholarship.org/uc/uciem\\_cpccm](http://escholarship.org/uc/uciem_cpccm)

DOI: 10.5811/cpcem.2022.2.55417

**Introduction:** Ultrasound-guided nerve blocks (UGNB) represent a procedural skill set that can be used to treat acute pain by physicians in the emergency department (ED). However, limited access to education and training represents a barrier to widespread adoption of this core skill set. The implementation of UGNBs within the ED can aid in resource allocation, particularly in limited-resource settings.

**Case Series:** In this case series we discuss our experience using tele-ultrasound to train emergency physicians on the use of UGNBs within our international point-of-care ultrasound fellowship in Peru. We highlight the potential role UGNBs serve in management of acute pain when working in resource-limited, public safety-net hospitals in Peru.

**Conclusion:** Tele-ultrasound may represent a strategy for teaching procedures such as UGNBs via remote guidance and supervision. [Clin Pract Cases Emerg Med. 2022;6(3):204–207.]

**Keywords:** *tele-ultrasound; point-of-care ultrasound; emergency department.*

## INTRODUCTION

Ultrasound-guided nerve blocks (UGNB) are a critical part of the multimodal armamentarium for emergency physicians (EP) when treating acute, painful injuries. The UGNB can reduce reliance on systemic opioids, thereby limiting their potential deleterious side effects.<sup>1</sup> Additionally, in the emergency department (ED), UGNBs can be used as an alternative to resource- and time-intensive procedural sedation.<sup>2</sup> The American College of Emergency Physicians recently endorsed a policy statement that states UGNBs represent a core component of multimodal pain management for patients in the ED and are within the scope of practice of

EPs.<sup>3</sup> Despite these advantages, UGNBs have not been widely used in limited-resource settings, and within the United States there is substantial variation among institutions in their use.<sup>4</sup> We believe that lack of education and training in UGNBs is one of the primary barriers to widespread adoption globally.

Advances in hardware have led to the development of less expensive, handheld ultrasound systems, allowing for greater access to bedside imaging globally. The development of tele-ultrasound on these same systems has allowed for education to be delivered remotely. Moreover, tele-ultrasound has already been shown to be an effective tool for training learners in image acquisition and improving diagnostic accuracy,<sup>5–7</sup> as

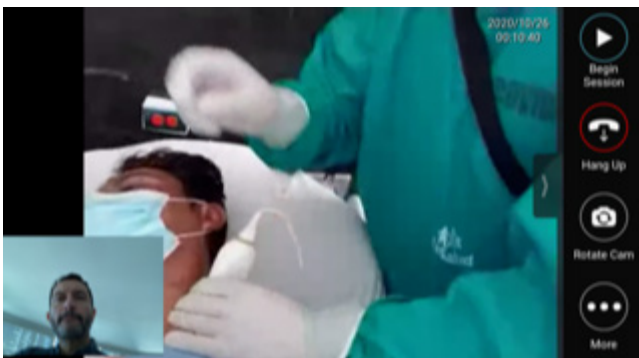well as providing real-time procedural guidance.<sup>8</sup> Collectively, these advances allow for the rapid expansion of bedside imaging and a method to increase remote education.

In our international point-of-care ultrasound (POCUS) fellowship training program in Peru, tele-ultrasound has been an integral part of our educational model.<sup>9</sup> This was clearly evident during the ongoing coronavirus disease 2019 (COVID-19) pandemic, where remote supervision with tele-ultrasound has been vital in continued education and supervision. With the aid of tele-ultrasound over the past three years, we have been able to train numerous clinicians how to safely and effectively perform UGNBs for acute pain management. We herein present our experience in implementing tele-ultrasound education for UGNBs in multiple limited-resource, safety-net hospitals in Peru. We believe that with the growth of the handheld ultrasound market, tele-ultrasound can be an ideal tool to teach procedures such as UGNBs.

## CASE SERIES

### Case 1

A 34-year-old man presented with acute onset of left elbow pain after falling from a five-foot ladder. On exam the left elbow was swollen and neurovascularly intact. Plain film radiography demonstrated a closed, displaced left supracondylar fracture. The orthopedic surgeon recommended the patient be placed in a posterior long arm splint and undergo outpatient operative repair; however, oral and intramuscular medications were unsuccessful at reducing the patient's pain to a tolerable level for splint application. The EP, one of our POCUS fellows in Cusco, Peru, suspected a UGNB could be used to provide analgesia for his patient's orthopedic injury, so he contacted the on-call group of POCUS fellowship instructors to request assistance with selecting and performing an UGNB. The EP was able to connect via tele-ultrasound with one of the instructors located in the US who recommended performing an ultrasound-guided supraclavicular brachial plexus block. The instructor was able to visualize and guide the ultrasound probe positioning, as shown in Image 1.



**Image 1.** Remote instructor visualizing the ultrasound probe positioning on the patient's neck.

### *CPC-EM Capsule*

What do we already know about this clinical entity?

*Ultrasound-guided nerve blocks (UGNB) are useful when treating acute injuries in the Emergency Department, but limited access to training inhibits widespread adoption.*

What makes this presentation of disease reportable?

*Data is limited on the use of tele-ultrasound to provide remote, real-time procedural guidance, particularly in the context of global health training programs.*

What is the major learning point?

*Tele-ultrasound can help provide ongoing remote supervision and training for teaching procedures in settings where access to on-site expert support is limited.*

How might this improve emergency medicine practice?

*Emergency physicians can use UGNBs in low-resource settings to improve pain control, and tele-ultrasound can help scale up access to training.*

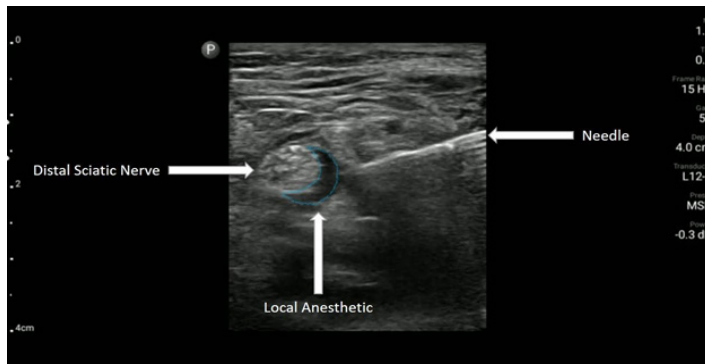
The EP was able to identify the supraclavicular brachial plexus and successfully inject 20 milliliters (mL) of 0.5% bupivacaine using real-time needle visualization by the remote instructor. The patient's pain significantly improved at 20 minutes, and he was able to tolerate splint application. He was subsequently discharged home on an oral pain regimen.

### Case 2

A 57-year-old man with poorly controlled diabetes presented to the ED with severe foot pain due to a worsening right-sided diabetic heel ulcer over the prior 10 days. On exam, there was concern for bacterial superinfection and the podiatry service was consulted, which recommended operative debridement. Unfortunately, there was a severe backlog of surgical cases, which meant the patient would likely have to wait several days for operative debridement. The EP consulted one of the ultrasound fellowship directors who proposed performing a distal sciatic UGNB based on the location of the diabetic foot ulcer. The EP was able to perform an UGNB she had never previously performed with the help of the remote guidance provided via the tele-ultrasound software on the handheld device. She was able to identify the distal sciatic

nerve and injected 20 mL of bupivacaine 0.5% after hydro-dissecting open the potential space with 0.9% normal saline as seen in Image 2.

The patient underwent surgical debridement of the diabetic heel ulcer in the ED and was subsequently admitted to the medicine service for treatment with intravenous antibiotics.



**Image 2.** Ultrasound image showing the distal sciatic nerve with surrounding local anesthetic and needle visualized using an in-plane approach.

### Case 3

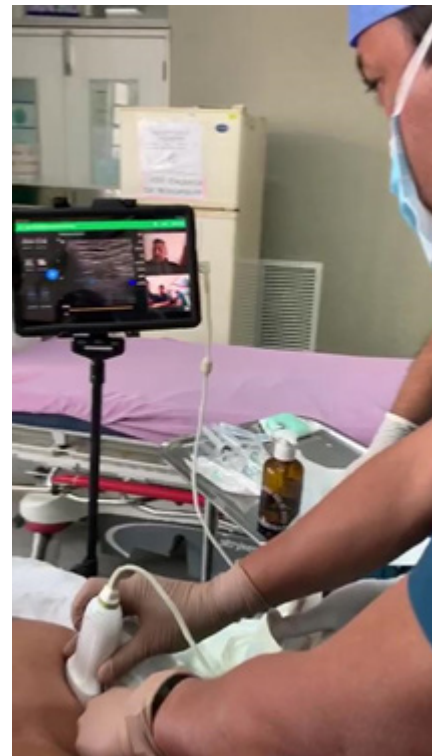A 35-year-old man was brought to the ED by ambulance after being struck by a vehicle at low speed, complaining of acute onset of right upper arm pain. On exam, the patient had an obvious deformity of the right upper arm that was neurovascularly intact. Plain film radiography revealed a right-sided displaced, mid-shaft humeral fracture. The patient was placed in a coaptation splint but continued to endorse severe pain despite receiving oral and intramuscular pain medication. The EP consulted with the on-call instructor who recommended a retroclavicular brachial plexus block. Although the EP had never previously performed this UGNB, through the use of tele-ultrasound software, an instructor was able to guide the physician to deposit 20 mL of bupivacaine 0.5% in the appropriate space as seen in Image 3.

After the UGNB the patient's pain reduced from 8/10 to 1/10 severity, and he was subsequently discharged home on an oral pain regimen.

### DISCUSSION

Despite the recognized benefits of UGNBs in the treatment of acute pain within the ED, this mode of analgesia remains underused in low-resource settings.<sup>10</sup> Ultrasound-guided nerve blocks represent a core procedural skill set for EPs in the US;<sup>3</sup> however, limited access to education resources represents a challenge both domestically and globally. Tele-ultrasound can be an ideal technological solution for training EPs in the use of UGNBs in the US and globally.

In our POCUS fellowship training program in Peru, we



**Image 3.** Ultrasound positioning while tele-ultrasound is being employed to provide live needle guidance.

have integrated the use of tele-ultrasound to provide ongoing remote diagnostic and procedural guidance for our trainees on a weekly scheduled basis. We have been able to circumvent geographical barriers and, more recently, travel restrictions due to the COVID-19 pandemic by employing the use of tele-ultrasound to augment hands-on training and provide procedural guidance as demonstrated by this case series.

We acknowledge that the reproducibility of this intervention is contingent on the existence of a baseline knowledge of POCUS applications. Additionally, the use of tele-ultrasound is dependent on the existence of reliable internet connectivity, although we have been able to reliably use our tele-ultrasound software with one of our fellows who was working in a remote city in the Amazon rainforest. Our success in setting up UGNBs within Peru forms part of a larger educational intervention leveraging technological advances to facilitate cross-continental learning. We are currently working on a descriptive study detailing the total number of UGNBs performed since the initiation of our educational intervention. We are hopeful that these cases will highlight the potential impact that tele-ultrasound can have specifically when it comes to providing remote procedural guidance.

### CONCLUSION

Treating acute pain in the emergency department can be challenging, particularly when working in a low-resource setting. Ultrasound-guided nerve blocks can be used by

emergency physicians in low-resource settings to provide improved pain control and resource allocation, particularly in the context of ED crowding resulting from the COVID-19 pandemic. Tele-ultrasound can help provide ongoing remote supervision and training for teaching procedures such as UGNBs in settings where there is limited access to on-site expert support.

The authors attest that their institution requires neither Institutional Review Board approval, nor patient consent for publication of this case report. Documentation on file.

---

*Address for Correspondence:* David A. Martin, MD, Highland Hospital – Alameda Health System, Department of Emergency Medicine, 1411 East 31st Street, Oakland, CA 94602. Email: [dmartin@alamedahealthsystem.org](mailto:dmartin@alamedahealthsystem.org).

*Conflicts of Interest:* By the *CPC-EM* article submission agreement, all authors are required to disclose all affiliations, funding sources and financial or management relationships that could be perceived as potential sources of bias. The authors disclosed none.

*Copyright:* © 2022 Martin. This is an open access article distributed in accordance with the terms of the Creative Commons Attribution ([CC BY 4.0](http://creativecommons.org/licenses/by/4.0/)) License. See: <http://creativecommons.org/licenses/by/4.0/>

---

## REFERENCES

1. Beaudoin FL, Haran JP, Liebmann O. A comparison of ultrasound-guided three-in-one femoral nerve block versus parenteral opioids alone for analgesia in emergency department patients with hip fractures: a randomized controlled trial. *Acad Emerg Med.* 2013;20(6):584-91.
2. Blaivas M, Adhikari S, Lander L. A prospective comparison of procedural sedation and ultrasound-guided interscalene nerve block for shoulder reduction in the emergency department. *Acad Emerg Med.* 2011;18(9):922-7.
3. Beeson MS, Ankel F, Bhat R, et al. The 2019 Model of the Clinical Practice of Emergency Medicine. *J Emerg Med.* 2020;59(1):96-120.
4. Amini R, Kartchner JZ, Nagdev A, et al. Ultrasound-guided nerve blocks in emergency medicine practice. *J Ultrasound Med.* 2016;35(4):731-6.
5. Constantinescu EC, Nicolau C, Săftoiu A. Recent developments in tele-ultrasonography. *Curr Health Sci J.* 2018;44(2):101-6.
6. Olivieri PP, Verceles AC, Hurley JM, et al. A pilot study of ultrasonography-naïve operators' ability to use tele-ultrasonography to assess the heart and lung. *J Intensive Care Med.* 2020;35(7):672-8.
7. Eke OF, Henwood PC, Wanjiku GW, et al. Global point-of-care ultrasound education and training in the age of COVID-19. *Int J Emerg Med.* 2021;14(1):12.
8. Drake AE, Hy J, MacDougall GA, et al. Innovations with tele-ultrasound in education sonography: the use of tele-ultrasound to train novice scanners. *Ultrasound J.* 2021;13:6.
9. Dreyfuss A, Martin DA, Farro A, et al. A novel multimodal approach to point-of-care ultrasound education in low-resource settings. *West J Emerg Med.* 2020;21(4):1017-21.
10. Schnittger T. Regional anaesthesia in developing countries. *Anaesthesia.* 2007;62(Suppl 1):44-7.

# Hyperaldosteronism and Renal Artery Stenosis in a Post-Abdominal Aortic Aneurysm Patient: A Case Report

Konnor Davis, BS\*  
Christopher J. Gilani, MD†  
Gabriel Sudario, MD, MEd†

\*University of California, Irvine, School of Medicine, Irvine, California  
†University of California, Irvine, Department of Emergency Medicine, Orange, California

Section Editor: Rick McPheeters, DO and R. Gentry Wilkerson, MD

Submission History: Submitted March 12, 2022; Revision received April 22, 2022; Accepted June 09, 2022

Electronically published August 8, 2022

Full text available through open access at [http://escholarship.org/uc/uciem\\_cpem](http://escholarship.org/uc/uciem_cpem)

DOI: 10.5811/cpcem2022.6.56522

**Introduction:** Patients with history of abdominal aortic aneurysm (AAA) undergoing surgical repair can have a myriad of surgical complications including compromise to large arteries branching from the aorta. Secondary hyperaldosteronism, characterized by high levels of aldosterone and renin, can be due to a multitude of causes, including renal artery stenosis, and presents with nonspecific symptoms of fatigue, increased thirst, and muscle spasms. While it can initially be difficult to diagnose given its multitude of metabolic abnormalities, secondary hyperaldosteronism is important to consider in patients presenting with uncontrolled hypertension, hypokalemia, and metabolic alkalosis.

**Case Report:** This report explores the case of a 65-year-old male with a complicated medical history presenting to the emergency department with hypokalemia and hypertension six months after undergoing endovascular repair for an AAA and was found to have metabolic abnormalities including hypokalemia and metabolic alkalosis consistent with secondary hyperaldosteronism, likely secondary to renal artery stent stenosis. He was admitted to the hospital for four days and made a full recovery.

**Conclusion:** This case highlights the need to understand, identify, and accurately diagnose hyperaldosteronism and recognize post-AAA repair complications of renal artery stenosis as a cause of this metabolic derangement. [Clin Pract Cases Emerg Med. 2022;6(3):208–211.]

**Keywords:** *abdominal aorta aneurysm; AAA; hyperaldosteronism; stent; case report.*

## INTRODUCTION

An abdominal aortic aneurysm (AAA) is a weakening and balloon-like dilation of the abdominal aorta. Abdominal aortic aneurysms are often asymptomatic and undiagnosed until complications occur; ultrasound and computed tomography angiography (CTA) are essential to diagnosis. There are many risk factors for AAA including old age, being male, familial history, hypertension, dyslipidemia, and most importantly, smoking.<sup>1</sup> In regard to the most serious AAA complication, a rupture accounts for roughly 150,000-200,000 deaths each year.<sup>2</sup> Treatment of an AAA, which is not always indicated, includes open surgical repair (OSR) with placement of a straight or bifurcated graft or endovascular repair (EVAR)

entering various arteries near the abdominal aorta to place covered stents.<sup>1,3</sup> Each method has its own pros and cons; however, treatment is necessary because once an AAA ruptures, more than half of these patients will die before reaching the operating table and of those who do make it to surgery, mortality rates remain around 50%.<sup>3</sup>

Aldosterone is the main mineralocorticoid produced in the zona glomerulosa of the adrenal cortex. Aldosterone's main function is to control electrolyte homeostasis and extracellular volume in the kidneys through sodium reabsorption and potassium and hydrogen ion excretion via urine.<sup>4</sup> Aldosterone secretion is controlled by a myriad of factors including, but not limited to, angiotensin II, potassium, and adrenocorticotropic

hormone.<sup>4</sup> However, the principal regulator of aldosterone is the renin-angiotensin-aldosterone system (RAAS), which becomes activated in states of hypovolemia and renal hypoperfusion.<sup>4</sup> Subsequently, aldosterone can be over- or under-secreted (hyper- and hypoaldosteronism, respectively) given various clinical conditions.

In this report we document a case of a previously unheard-of combination of complications of secondary hyperaldosteronism secondary to renal artery thrombosis as well as a focally stenosed renal artery stent following EVAR treatment for AAA. Despite the novelty of this presentation, the sequela of difficult to diagnose complications of hyperaldosteronism, especially in the presence of a patent stent following AAA repair, warrants discussion.

### CASE REPORT

A 65-year-old male with past medical history of hypertension, AAA without rupture status post endovascular repair (six months prior), mixed hyperlipidemia, and tobacco usage presented to the emergency department (ED) from an outside physician for an abnormal potassium of 2.3 millimoles per liter (mmol/L) (reference range: 3.5-5.1 mmol/L) and hypertension. On evaluation, he reported 2-3 months of polyuria and polydipsia that had progressively worsened. He reported needing to urinate hourly and was unable to sleep due to this symptom. He also reported generalized weakness and some constipation. He denied dysuria, abdominal or chest pain, shortness of breath, fever, cough, or diarrhea. Presentation vital signs showed a blood pressure of 195/122 millimeters mercury, oxygen saturation of 97% on room air, heart rate of 89 beats per minute, and respiratory rate of 18 breaths per minute.

Of note, the patient had been admitted six months prior with a non-ruptured AAA. He underwent aneurysm repair with aortoiliac stent graft and left renal artery snorkel placement/stenting. On exam, the patient was alert and oriented with no signs of trauma. Heart, lungs, and abdominal exam were all normal. Initial labs in the ED were notable for sodium of 133 mmol/L (reference range: 136-145 mmol/L), potassium of 2.4 mmol/L (3.5-5.1 mmol/L), chloride of 89 mmol/L (98-107 mmol/L), and hemoglobin of 17.6 grams per deciliter (g/dL) (12.0-16.0 g/dL). Venous blood gas revealed a pH of 7.53 (7.35-7.45), arterial bicarbonate of 38.5 mmol/L (21-27 mmol/L), and a total carbon dioxide of 40 mmol/L (36-42 mmol/L). Glomerular filtration rate was 55 mL/min/1.73 m<sup>2</sup> and glucose was 129 milligrams per deciliter (mg/dL) (35-125 mg/dL). Urinalysis resulted in a urine protein of 9,087 (50-80 mg/day). On imaging, a CTA abdomen and pelvis showed chronic occlusion/thrombosis of the right main renal artery, moderate right renal atrophy, postsurgical changes of the endovascular repair, and left renal artery stent with a non-flow limiting focal area of stenosis midway through the stent. These findings were new in comparison to a CTA abdomen and pelvis obtained six months earlier prior to EVAR. An ultrasound Doppler of the abdomen and pelvis also showed

### CPC-EM Capsule

What do we already know about this clinical entity?

*Secondary hyperaldosteronism presents with multiple metabolic abnormalities and can signify failure or occlusion of the post-abdominal aortic aneurysm repair stent.*

What makes this presentation of disease reportable?

*Secondary hyperaldosteronism secondary to renal artery thrombosis as well as a focally-stenosed renal artery stent following endovascular repair treatment for abdominal aortic aneurysm is novel.*

What is the major learning point?

*The metabolic derangements associated with hyperaldosteronism, metabolic alkalosis with hypokalemia, in those with renal artery stents must be recognized by the Emergency Medicine physician.*

How might this improve emergency medicine practice?

*Accurately diagnosing hyperaldosteronism and recognizing post-AAA repair complications of renal artery stenosis.*

the left renal artery stent with patent flow. Chest radiograph was unremarkable.

The patient's initial presentation was concerning for secondary hyperaldosteronism given his hypokalemia and metabolic alkalosis. Given the patient's history of AAA status post EVAR and abnormal CTA results, vascular surgery was consulted. Similarly, endocrinology and nephrology were consulted due to metabolic derangement. In conjunction with the various consulting specialties, the patient was admitted for four days and was started on amlodipine, hydralazine, and spironolactone (which was up titrated during the hospital stay due to persistent hypertension and hypokalemia). At discharge, renin-aldosterone levels were pending but eventually resulted at 44.4 nanograms per milliliter per hour (ng/mL/hr) (reference range: supine = 0.2-1.6; upright = 0.5-4.0) for renin, and 56.0 nanograms per deciliter (ng/dL) (less than 16 ng/dL) for aldosterone. Upon discharge, all three medications above were continued, angiotensin-converting enzyme inhibitors and angiotensin II receptor blockers were recommended to be avoided, and the patient was scheduled for an outpatient captopril study.



## DISCUSSION

Aldosterone, a mineralocorticoid produced by the adrenal glands, exerts its effects throughout the body. However, the effects are most often targeted to the kidneys in the presence of low blood volume or electrolyte disturbances. The RAAS system is the principal regulator for the production and potentiation of aldosterone and is vital for survival.<sup>5</sup> In short, the enzyme renin is secreted from the kidneys and acts on angiotensinogen (produced by the liver). The product is angiotensin I, which then is transformed into angiotensin II in the lungs. Angiotensin II can exert its own influence in the body through generalized vasoconstriction, increased proximal tubule reabsorption of sodium, stimulation of antidiuretic hormone secretion, and, most importantly, stimulation of aldosterone secretion.<sup>4</sup> In the presence of decreased systemic arterial pressure, resulting in decreased glomerular filtration and renovascular pressure, or high serum potassium, aldosterone acts in the kidneys to reabsorb sodium, water, and excrete potassium.<sup>4</sup>

The case described above exhibits a clinical syndrome known as secondary hyperaldosteronism, in which the body produces excess aldosterone secondary to overactivation of the RAAS system.<sup>6</sup> The excess aldosterone does not come from an aldosterone-producing tumor (which distinguishes primary from secondary) but rather from a high amount of renin secondary to causes such as renal artery stenosis, aortic coarctation, reninoma, pregnancy, or cirrhosis.<sup>4,6</sup> Our patient had many potential sources of his secondary hyperaldosteronism given his newly diagnosed chronic right renal artery thrombosis and left renal artery stent with focal stenosis. While Doppler imaging showed adequate flow through his left renal artery, we postulate that his bilateral decreased renal perfusion contributed to over-activation of his RAAS system leading to a hyperaldosterone state.

Patients with excess aldosterone are prone to hypervolemia and hypertension as aldosterone influences the kidneys to reabsorb sodium and water to return volume levels to acceptable levels.<sup>7</sup> Angiotensin II, from the activation of the RAAS system, can also contribute to hypertension and increased thirst, which were experienced by the patient. Hypokalemia and metabolic alkalosis are common in hyperaldosteronism and are a consequence of aldosterone's action on the renal collecting tubules, leading to increased sodium reabsorption, which causes movement of cations (hydrogen and potassium) into the tubular lumen to maintain electrical neutrality.

Given the initial concern for the patient's left renal artery stent stenosis contributing to his presentation, it is important to discuss other complications of AAA repair. Perioperative complications are similar between EVAR and OSR and include wound complications, renal failure, colonic ischemia, death, myocardial infarction, and pneumonia.<sup>8</sup> Postoperative, long-term complications include endoleaks (leakage of blood between the graft and aneurysm sac; more common in EVAR than OSR), graft infection, aortoenteric

fistula, buttock claudication and limb occlusion, and sexual dysfunction.<sup>8</sup> Patients receiving EVAR are spared the ischemic insult of aortic cross-clamping and often have less perioperative hemorrhage, but one must consider the potential nephrotoxicity associated with intravenous contrast as well as manipulating the aorta in such a way that plaques can become disrupted and embolize into the renal vasculature.<sup>9</sup> Unfortunately, renal failure is common post AAA repair and can have significant and long-lasting downstream effects on the body such as the metabolic derangement seen in our patient with secondary hyperaldosteronism.

The primary treatment of secondary hyperaldosteronism is with mineralocorticoid receptor blockade with spironolactone or eplerenone. Spironolactone is a nonselective mineralocorticoid receptor antagonist with binding ability to both androgen and progesterone receptors as well.<sup>10</sup> The majority focus of spironolactone is the renal cortical collecting ducts as it acts as potassium sparing diuretic and antihypertensive drug.<sup>11</sup> Spironolactone is dosed at 25-200mg/24hr through either oral suspension or tablet.<sup>12</sup> Dosage can be titrated to goal blood pressure as needed outpatient. Side effects include gynecomastia, menstrual disturbances, and impotence due to its effects on androgen and progesterone receptors.<sup>13</sup> In patients experiencing sexual side effects, eplerenone may be used in place.<sup>14</sup>

## CONCLUSION

As aldosterone has many effects on the human body, it is important for the emergency physician to consider the diagnosis of hyperaldosteronism in patients presenting with hypertension with hypokalemia and metabolic alkalosis. This is especially true in patients who have undergone EVAR of AAA and left renal artery stenting as this could signify failure or occlusion of the stent.

The authors attest that their institution requires neither Institutional Review Board approval nor patient consent for publication of this case report. Documentation on file.

---

*Address for Correspondence:* Gabriel Sudario, MD, MSEd, University of California, Irvine, Department of Emergency Medicine, 3800 W. Chapman Ave, Suite 3200, Orange, CA 92868. Email: [gsudario@uci.edu](mailto:gsudario@uci.edu).

*Conflicts of Interest:* By the CPC-EM article submission agreement, all authors are required to disclose all affiliations, funding sources and financial or management relationships that could be perceived as potential sources of bias. The authors disclosed none.

*Copyright:* © 2022 Davis et al. This is an open access article distributed in accordance with the terms of the Creative Commons Attribution (CC BY 4.0) License. See: <http://creativecommons.org/licenses/by/4.0/>

## REFERENCES

1. Golledge J. Abdominal aortic aneurysm: update on pathogenesis and medical treatments. *Nat Rev Cardiol*. 2019;16(4):225-42.
2. Sampson UK, Norman PE, Fowkes FG, et al. Global and regional burden of aortic dissection and aneurysms: mortality trends in 21 world regions, 1990 to 2010. *Glob Heart*. 2014;9(1):171.
3. Chaikof EL, Brewster DC, Dalman RL, et al. The care of patients with an abdominal aortic aneurysm: the Society for Vascular Surgery practice guidelines. *J Vasc Surg*. 2009;50(4):S2-49.
4. Papadopoulou-Marketou N, Vaidya A, Dluhy R, et al. Hyperaldosteronism. 2000. Available at: <https://europepmc.org/article/med/25905293>. Accessed December 27, 2021.
5. Patel S, Rauf A, Khan H, et al. Renin-angiotensin-aldosterone (RAAS): The ubiquitous system for homeostasis and pathologies. *Biomed Pharmacother*. 2017;94:317-25.
6. Dominguez A, Muppidi V, Gupta S. Hyperaldosteronism. 2020. Available at: <https://www.ncbi.nlm.nih.gov/books/NBK499983/>. Accessed December 27 2021.
7. Xu N, Hirohama D, Ishizawa K, et al. Hypokalemia and pendrin induction by aldosterone. *Hypertension*. 2017;69(5):855-62.
8. Clancy K, Wong J, Spicher A. Abdominal aortic aneurysm: a case report and literature review. *The Permanente Journal*. 2019;23(18.218).
9. Wald R, Waikar SS, Liangos O, et al. Acute renal failure after endovascular vs open repair of abdominal aortic aneurysm. *J Vasc Surgery*. 2006;43(3):460-66.
10. Patibandla S, Heaton J, Kyaw H. Spironolactone. 2020. Available at: <https://www.ncbi.nlm.nih.gov/books/NBK554421/>. Accessed December 29 2021.
11. Karagiannis A, Tziomalos K, Papageorgiou A, et al. Spironolactone versus eplerenone for the treatment of idiopathic hyperaldosteronism. *Expert Opin Pharmacother*. 2008;9(4):509-15.
12. The Johns Hopkins Hospital, Kleinman K, McDaniel L, et al. (2020) *Harriet Lane Handbook: The Johns Hopkins Hospital*. Baltimore, Maryland: Elsevier.
13. Ménard J. The 45-year story of the development of an anti-aldosterone more specific than spironolactone. *Mol Cell Endocrinol*. 2004;217(1-2):45-52.
14. Reyes AJ, Leary WP, Crippa G, et al. The aldosterone antagonist and facultative diuretic eplerenone: a critical review. *Eur J Intern Med*. 2005;16(1):3-11.

# Occipital Lobe Status Epilepticus, A Stroke Mimic with Novel Imaging Findings: A Case Report

Jordan Lawson, DO\*  
Wayne Triner, DO, MPH\*  
Brady Kluge, BS†

\*Prisma Health Upstate, Department of Emergency Medicine, Greenville, South Carolina  
†University of South Carolina, School of Medicine, Greenville, South Carolina

Section Editor: Jacqueline Le, MD

Submission History: Submitted November 23, 2021; Revision received December 28, 2021; Accepted January 4, 2022

Electronically published July 26, 2022

Full text available through open access at [http://escholarship.org/uc/uciem\\_cpem](http://escholarship.org/uc/uciem_cpem)

DOI: 10.5811/cpem.2022.1.55482

**Introduction:** Stroke mimics are a major diagnostic challenge during the initial evaluation of patients presenting with an acute focal neurological deficit. This case reviews a patient who presented to the emergency department (ED) with homonymous hemianopsia, a rare manifestation of focal status epilepticus of the occipital lobe. Her initial brain computed axial tomographic perfusion scan and magnetic resonance imaging revealed novel findings associated with this diagnosis.

**Case Report:** A 70-year-old female presented to our ED with left visual field hemianopsia, dyskinesia, dysmetria, and facial droop. Her initial diagnosis was left posterior fossa circulation cerebrovascular accident. However, her neuroimaging indicated hypervascularity of the left occipital lobe without evidence of infarct or structural lesion. A cerebral angiogram excluded arteriovenous malformation. Subsequently, an electroencephalogram showed left occipital lobe status epilepticus.

**Conclusion:** Hemianopsia is a rare presentation of focal status epilepticus mimicking stroke. Hypervascularity seen on advanced neuroimaging may have suggested this diagnosis on initial ED evaluation. [Clin Pract Cases Emerg Med. 2022;6(3):212-215.]

**Keywords:** *case report; stroke mimics; hemianopsia; status epilepticus.*

## INTRODUCTION

The initial emergency department (ED) diagnosis of ischemic stroke remains a clinical one. It is based upon the sudden loss of neurological function corresponding to a discrete vascular and anatomic distribution within the brain (and less commonly, the spinal cord). Generally, this diagnosis is accomplished by a focused history, which includes specific time of onset and subjective report of symptoms. This is coupled with an equally focused neurological examination designed to uncover a specific neurological deficit. The history and physical are augmented by laboratory and neuroimaging studies, which might reveal alternative explanations for the deficit such as hypoglycemia, and structural lesions within the brain. Additionally, neuroimaging is employed to exclude medical or interventional revascularization in the face of intracerebral hemorrhage.

The accuracy of stroke diagnosis has important implications since cerebral revascularization, whether systemic or interventional, carries risk of harm while incurring significant allocation of resources. Thus, stroke mimics, which account for up to 25% of admissions for probable strokes, are a major diagnostic challenge during the initial evaluation of patients presenting with an acute focal neurological deficit.<sup>1</sup> Common stroke mimics include metabolic derangements, seizure, complex migraine, central nervous system infections, sepsis, non-stroke cardiovascular events, and functional disorders. To this end, methodologies, either already employed in early stroke evaluation or potentially available within the ED, may help physicians to identify uncommon stroke mimics with greater frequency. In this case report, we present a rare cause of a stroke mimic with novel neuroradiologic findings.

## CASE REPORT

A 70-year-old, functionally independent female presented to the ED by emergency medical services after her son had found her on the floor. She reported that she had “blurred vision.” The visual disturbance and fall were reported by the patient to have occurred 10 hours prior to ED presentation with associated left-sided “tingling and weakness.” She had a past medical history of hyperlipidemia, uncontrolled type II diabetes, carotid artery disease, coronary artery disease, stage III chronic kidney disease and hypothyroidism. She acknowledged poor adherence with her home medications, which included insulin lispro, insulin degludec, sacubitril/valsartan, torsemide, spironolactone, and metoprolol extended release.

On arrival to the ED, she had fluent speech, was managing her own airway, and had good peripheral perfusion. Her blood pressure was 131/61 millimeters mercury, heart rate 67 beats per minute, respiratory rate 18 breaths per minute, temperature 97.5° Fahrenheit, and oxygen saturation of 100% on room air. The initial evaluation was most notable for a left visual field hemianopsia. She also had left-sided dyskinesia and dysmetria with a subtle left facial droop. She had no other strength deficits. Her National Institutes of Health Stroke Scale score was 5 (age and month -1, mild left facial palsy -1, hemianopsia -2, limb ataxia -1). The remainder of her physical examination was unremarkable.

Based on the focality of her neurological examination referable to a left posterior fossa lesion and being within the 24-hour window for mechanical clot extraction, our stroke team was mobilized. She underwent non-contrast head computed axial tomography (CT), showing only mild atrophy. Being outside the window for systemic thrombolysis, she had a head and neck CT angiogram with perfusion study. This study revealed hyperperfusion of her left occipital lobe thought to be suggestive of an arteriovenous fistula (AVF). There were no apparent large vessel occlusions, infarcts, or penumbras. A brain magnetic resonance imaging (MRI) later that day offered similar findings without discrete evidence of an AVF.

Her initial laboratory studies in the ED included a white blood cell count of 11,800 cells per milliliter (mL) (reference range: 4000-11,500 cells/mL), hemoglobin of 14.5 grams per deciliter (g/dL) (12-18 g/dL), platelet count of 446 platelets/mL (125-415 platelets/mL). She had a serum sodium of 131 millimoles per liter (mmol/L) (133-144 mmol/L), potassium of 4.5 mmol/L (3.4-5.1 mmol/L), chloride 91 mmol/L (101-111 mmol/L), bicarbonate ion of 27 mmol/L (20-30 mmol/L), a calculated glomerular filtration rate of 40 mL per minute (min) (reference: greater than 59 mL/min), and an elevated serum glucose of 583 milligrams (mg)/dL (82-99 mg/dL). Her urine toxicology screen did not show the presence of amphetamines, benzodiazepines, cannabinoids, cocaine, or opioids. Her electrocardiogram revealed non-specific ST-segment abnormalities.

### *CPC-EM Capsule*

What do we already know about this clinical entity?

*Stroke mimics are common and important to identify. However, findings of stroke mimics can be subtle.*

What makes this presentation of disease reportable?

*This is a report of a stroke mimic, occipital lobe status epilepticus, previously undefined in the emergency medicine literature, with novel findings on imaging.*

What is the major learning point?

*Perfusion studies carried out during an acute stroke evaluation may lead the clinician to consider this and other presentations of complex status epilepticus.*

How might this improve emergency medicine practice?

*Understanding this finding on imaging may lead the physician to consider the diagnosis of stroke mimic and redirect care appropriately.*

Following initial stroke assessment, our patient was then admitted to the hospitalist service for in-patient evaluation of her unexplained neurological deficits and continued concern for an AVF. On hospital day two, due to persistence of the unexplained neurologic deficits the patient underwent a bedside electroencephalogram (EEG). This study revealed left occipital lobe focal status epilepticus. This prompted administration of levetiracetam 1500 mg loading dose intravenously and 750 mg orally twice daily. The following day, her left visual field deficit persisted. On day three of hospitalization, a cerebral angiogram excluded an arteriovenous malformation and revealed only several non-critical stenoses. A long-term EEG showed persistent left occipital lobe status epilepticus prompting the addition of lacosamide 200 mg twice daily during her hospitalization. She was then transferred to an in-patient rehabilitation facility for mobility and muscle conditioning.

Seven days following her initial presentation, physical medicine and rehabilitation documented that she had regained full visual fields with no dyskinesia or dysmetria. Unfortunately, 30 days following initial presentation,

our patient was re-admitted to our hospital with acute cholecystitis. During that hospitalization, she had a downward course that included a large cerebral infarct culminating in withdrawal of support.

## DISCUSSION

Our patient had several stroke risk factors including advanced age, diabetes mellitus, hyperlipidemia, and renal dysfunction. Her initial evaluation was dominated by a dense left hemianopsia and left-sided dysmetria and dyskinesia, thus localizing her deficit to her left posterior fossa. Our initial evaluation pointed us toward ischemic stroke, since hemianopsia can occur in as many as 7% of all strokes.<sup>2</sup> It is possible her seizure may have been associated with a transient ischemic attack (TIA). This, however, did not negate the importance of her seizure, since that was the diagnosis requiring expeditious treatment.

The incidence of focal occipital status epilepticus is rare and unknown other than found in a handful of case reports.<sup>3,4,5,6</sup> Occipital lobe status epilepticus may present in several fashions. There may be “negative” features such as unilateral vision loss, as our patient presented. This should not be confused with a structural cause of vision loss (tumor) and secondary seizure. Likewise, there may be “positive” features such as visual hallucinations or flashing lights, which may be difficult to distinguish from occipital migraine, but for EEG findings of epileptiform activity. It is possible for propagation of the seizure to include adjacent areas of the brain to incorporate oculomotor or other motor features.<sup>7</sup> To our knowledge, this is the first occurrence of occipital lobe status epilepticus to be reported in the emergency medicine (EM) literature.

Hyperperfusion of the left occipital lobe seen on perfusion CT angiography and MRI, may represent preliminary findings associated with focal status epilepticus.<sup>7,8</sup> This is the first report of this finding to our knowledge to be reported in the EM literature. While this finding would be more likely associated with an AVF, one was not visualized by angiography or MRI. An EEG subsequently revealed her underlying diagnosis: focal status epilepticus of the left occipital lobe.

Our patient had a well-defined focal neurological deficit, which after initial imaging went unexplained. This resulted in a 48-hour delay in diagnosis and treatment. This could have been averted had focal status epilepticus been considered. Should this diagnosis have entered consideration earlier, emergency EEG acquisition could have been obtained in the ED through either conventional or point-of-care EEG monitoring.<sup>9,10</sup>

## CONCLUSION

Two features of this case have importance for emergency physicians. The first is the finding of hemianopsia as a stroke mimic resulting from focal status epilepticus. This

presentation of stroke mimic appears to be very rare and has not previously been reported in the EM literature. This contrasts with the relatively common occurrence of hemianopsia resulting from ischemic stroke. Second, cerebral hypervascularity implied by both CT angiography and MRI may be a finding associated with focal status epilepticus. This association has recently gained attention in the neuroradiology literature.<sup>6,7,8</sup> Hyperperfusion, however, is not limited to seizure. It has been demonstrated following reperfusion of cerebral vessels as might occur with TIA or therapeutic reperfusion.<sup>11</sup>

In the context of contemporary stroke care, CT perfusion of the brain is now commonly carried out in centers with access to invasive neuroradiology to determine the appropriateness of invasive neuroradiology in those patients for whom systemic thrombolysis is contraindicated. This finding may then be reported to the emergency physician who will need to assess its clinical relevance. Yet the performance characteristics of this finding (sensitivity and specificity) are still undefined. In conclusion, hemianopsia although a rare manifestation of focal status epilepticus merits consideration as a possible stroke mimic and may also carry unique radiologic findings.

The authors attest that their institution requires neither Institutional Review Board approval nor patient consent for publication of this case report. Documentation on file.

---

*Address for Correspondence:* Wayne Triner, DO, MPH, Prisma Health Upstate, Department of Emergency Medicine, 701 Grove Rd, Greenville, SC 29605. Email: wayne.triner@prismahealth.org.

*Conflicts of Interest:* By the CPC-EM article submission agreement, all authors are required to disclose all affiliations, funding sources and financial or management relationships that could be perceived as potential sources of bias. The authors disclosed none.

*Copyright:* © 2022 Lawson. This is an open access article distributed in accordance with the terms of the Creative Commons Attribution (CC BY 4.0) License. See: <http://creativecommons.org/licenses/by/4.0/>

---

## REFERENCES

- Gibson LM and Whiteley W. The differential diagnosis of suspected stroke: a systematic review. *J R Coll Physicians Edinb.* 2013;43(2):114-8
- Zhang X, Kedar S, Lynn MJ, et al. Homonymous hemianopia in stroke. *J Neuroophthalmol.* 2006;26(3):180-3.
- Siatouni A, Gatzonis S, Alexopoulos A, et al. Simple partial status epilepticus manifested as homonymous hemianopsia: a rare intracranial recording. *Clin Pract.* 2016;6(1):840.
- Yang Y, Zhang S, Duan J, et al. Acute visual impairment as a main presenting symptom of non-convulsive status epilepticus: a case report. *BMC Neurol.* 2020;20(1):51.
- Matsumoto Y, Akamatsu Y, Ogasawara Y, et al. A case of paroxysmal

- homonymous hemianopsia: uncommon presentation of nonconvulsive status epilepticus. *Radiol Case Rep.* 2020;15(6):668-71.
6. González-Cuevas M, Coscojuela P, Santamarina E. Usefulness of brain perfusion CT in focal-onset status epilepticus. *Epilepsia.* 2019;60(7):1317-24.
  7. Schäffler L and Karbowski K. Zur Frage der epileptischen Aktivität des Okzipitallappens. Klinisch-elektroenzephalographischer Beitrag [Epileptic activity of the occipital lobe. Clinico-electroencephalographic contribution]. *Fortschr Neurol Psychiatr.* 1988;56(9):286-99.
  8. Shimogawa T, Morioka T, Sayama T, et al. The initial use of arterial spin labeling perfusion and diffusion-weighted magnetic resonance images in the diagnosis of nonconvulsive partial status epilepticus. *Epilepsy Res.* 2017;129:162-73.
  9. Gugger JJ, Llinas RH, Kaplan PW. The role of CT perfusion in the evaluation of seizures, the post-ictal state, and status epilepticus. *Epilepsy Res.* 2020;159:106256.
  10. Rittenberger JC, Weissman A, Baldwin M, et al. Pittsburgh Post Cardiac Arrest Service. Preliminary experience with point-of-care EEG in post-cardiac arrest patients. *Resuscitation.* 2019;135:98-102
  11. Brenner JM, Kent P, Wojcik SM, et al. Rapid diagnosis of nonconvulsive status epilepticus using reduced-lead electroencephalography. *West J Emerg Med.* 2015;16(3):442-6.
  12. Copen WA, Schaefer PW, Wu O. MR perfusion imaging in acute ischemic stroke. *Neuroimaging Clin N Am.* 2011;21(2):259-83.

## Level I Hyperglycemia Alert: A Case Report

Michelle Nassal, MD, PhD  
Christopher San Miguel, MD

The Ohio State University, Wexner Medical Center, Department of Emergency  
Medicine, Columbus, Ohio

Section Editor: Austin Smith, MD

Submission History: Submitted October 20, 2021; Revision received January 18, 2022; Accepted February 4, 2022

Electronically published August 8, 2022

Full text available through open access at [http://escholarship.org/uc/uciem\\_cpccem](http://escholarship.org/uc/uciem_cpccem)

DOI: 10.5811/cpcem.2022.2.55160

**Introduction:** Nonketotic hyperglycemia-associated chorea is a rare condition that upon presentation to the emergency department can be easily misdiagnosed as a seizure or a stroke. Although uncommon, identification of this condition can aid emergency physicians in avoiding unnecessary and potentially harmful treatments for other neurological pathology. Furthermore, prompt hyperglycemic control can result in reversal of symptoms within days.

**Case Report:** We present a case of nonketotic hyperglycemia-associated chorea where the patient was transferred to our facility as a hemorrhagic stroke alert, based on a false-positive interpretation of head computed tomography (CT) imaging.

**Conclusion:** Nonketotic hyperglycemia on CT imaging and clinical presentation can mimic stroke presentations. Prompt recognition of key features can lead to appropriate treatment.  
[Clin Pract Cases Emerg Med. 2022;6(3):216-219.]

**Keywords:** *hyperglycemia; stroke mimic; nonketotic hyperglycemia.*

### INTRODUCTION

We present a case of a patient with nonketotic hyperglycemia hemichorea who was transferred to our facility as a hemorrhagic stroke alert. This alert was based on a hyperdensity seen on a non-contrast computed tomography (CT) of the head. Physical exam findings included choreiform movement of the patient's right upper extremity. Magnetic resonance imaging (MRI) findings were consistent with nonketotic hyperglycemia hemichorea. The patient was admitted to medicine for diabetic control with improvement of her symptoms. She was ultimately discharged home several days later.

### CASE REPORT

A 57-year-old female with history of type 2 diabetes mellitus, coronary artery disease status post-coronary artery bypass graft, hypertension, hyperlipidemia, hypothyroidism, anxiety, and depression presented to the emergency department (ED). She reported five days of progressive, uncontrolled right arm movements and facial twitching that she could only briefly suppress. Her arm movements were

also increasing in magnitude. On the day of her presentation, she also started to have "slurred speech" described as having difficulty enunciating words. She denied a prior history of traumatic brain injury, seizures, and/or stroke. Her home medications included insulin, aspirin, clopidogrel, risperidone, and venlafaxine, and no other relevant medications. The referring hospital read the patient's head CT as an intracerebral hemorrhage and she was promptly transferred to our Comprehensive Stroke Center for further management.

Upon arrival to the ED, the patient's vital signs were recorded as follows: blood pressure 117/58 millimeters of mercury, heart rate 77 beats per minute, temperature 36.7°C, saturating 94% on room air with respiratory rate 18 breaths per minute. Point-of-care glucose was 203 milligrams per deciliter (mg/dL) (reference range: 70-99 mg/dL). On physical exam, she was alert and oriented to person, place, and time. She did not have objective speech difficulties. She had choreiform movement of her right upper extremity and simultaneous right-sided facial grimacing that she could briefly suppress (Video). She had right upper extremity ataxia and drift due to choreiform

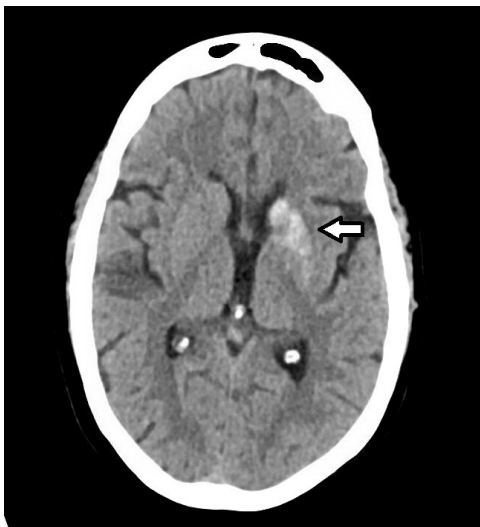movement. She also exhibited right lower extremity drift. She denied any sensory deficits.

A repeat head CT revealed a “hyperdensity within the left caudate and lentiform nucleus with apparent sparing of the anterior limb of the internal capsule” (Image 1). She also had a remote lacunar infarct near the left caudate. The neurovascular stroke team simultaneously evaluated the patient with the emergency physicians. As the patient’s exam was not consistent with a hemorrhagic stroke in the left caudate and lentiform nucleus, an emergent MRI of her brain was obtained. T1-weighted fluid-attenuated inversion recovery (FLAIR) hyperintense signal with T2-FLAIR and diffusion-weighted hypointense signal abnormalities without surrounding edema was observed on MRI. This was supportive of nonketotic hyperglycemia rather than acute hemorrhage (Image 2).

The patient’s laboratory findings were significant for hemoglobin A1c of 14.8% (4.7-5.6%) and negative urine ketones. She was admitted to a medicine service where she was followed by endocrinology and neurology. Her insulin regimen was increased, and carbohydrate-correction education was provided. After a four-day inpatient hospitalization, the patient’s chorea improved with decreased amplitude of the movements. The neurology team projected gradual improvement with improved glucose control. The patient was ultimately discharged home with advice for close follow-up.

## DISCUSSION

Nonketotic hyperglycemia-induced hemichorea (or hemiballismus) is a rare condition seen with uncontrolled diabetes. It is commonly initially misdiagnosed as a seizure due to the uncontrolled choreiform movement of one extremity.<sup>1</sup>



**Image 1.** Computed tomography head imaging, which shows hyperintensity (arrow) in left caudate nucleus concerning for potential hemorrhagic stroke.

### *CPC-EM Capsule*

What do we already know about this clinical entity?

*Nonketotic hyperglycemia-associated chorea is a rare condition that can mimic seizures and/or hemorrhagic stroke on computed tomography (CT).*

What makes this presentation of disease reportable?

*Prompt identification can prevent potentially harmful hemorrhagic stroke interventions and facilitate correct treatment of glycemic management.*

What is the major learning point?

*Nonketotic hyperglycemia-associated chorea can mimic hemorrhagic stroke on CT, but prompt recognition can result in appropriate glycemic control.*

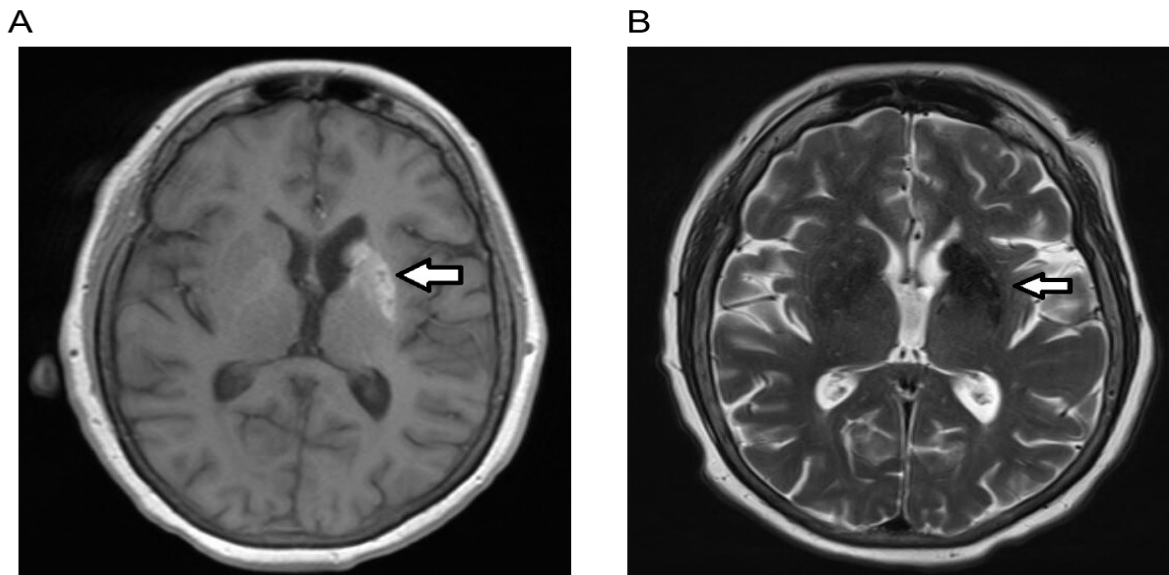
How might this improve emergency medicine practice?

*Awareness of this presentation can result in appropriate, emergent magnetic resonance imaging to confirm diagnosis and improve patient outcomes with appropriate treatment.*

However, hemichorea can also be the presenting symptoms of an acute cerebrovascular accident in the basal ganglia, specifically in the subthalamic nucleus, or parietal lobe.<sup>2,3</sup> Other diagnostic considerations include serotonin syndrome, neuroleptic malignant syndrome, post-streptococcal Sydenham chorea, hyperthyroid disorders, and tardive dyskinesia. The exact prevalence and pathophysiology of nonketotic hyperglycemia-induced hemichorea are unknown. Proposed causes include micro-ischemia to the basal ganglia from the hyperviscosity caused by hyperglycemia. Other proposed causes include interruptions in gamma-aminobutyric acid synthesis, micro-hemorrhagic injury, or auto-immune injury.<sup>4</sup> Prompt identification of nonketotic hyperglycemia can lead to correct treatment with insulin and improvement in the hemichorea.

Diagnostic tools to help identify nonketotic hyperglycemia-induced hemichorea include laboratory evaluation, CT and MRI. Surprisingly, this patient did not have significantly elevated glucose on presentation; however, her A1C was 14.8% suggesting poor diabetic control over the previous several months. Chronic poor diabetic control followed by several days of carefully controlled treatment to improve hemichorea suggests the basal ganglia insult is





**Image 2.** Magnetic resonance imaging of brain showing nonketotic hyperglycemia. (A) shows T1-weighted fluid-attenuated inversion-recovery (FLAIR) imaging with hyperintensity (arrow) in correlation with computed tomography imaging as seen Image 1. (B) on T2-FLAIR and diffusion-weighted imaging signal is hypointense (arrow) with no surrounding edema. This supports nonketotic hyperglycemia rather than acute hemorrhage.

subacute. This raises the question: At which threshold of basal ganglia injury does a patient become acutely symptomatic? The hyperdensity seen on her CT was consistent with her ultimate diagnosis but could not be definitively distinguished from acute hemorrhage. To differentiate hemorrhagic stroke from nonketotic hyperglycemia MRI was necessary. According to Yu et al, MRI imaging, specifically differentiation on T1 and T2/FLAIR sequences, can help correctly identify nonketotic hyperglycemia.<sup>5</sup> Emergent MRI confirmed nonketotic hyperglycemia. This allowed the patient to promptly begin carefully controlled diabetic management resulting in improvement of her symptoms. Without prompt identification, management may have been directed at treating a hemorrhagic stroke: antiepileptic medication, strict blood pressure control, reversal of anticoagulation, and potential neurosurgical procedures.

Nonketotic hyperglycemia hemichorea is rare. Within the last 20 years, an estimated 85 case reports have been published, mostly within neurologic journals.<sup>6-8</sup> Due to its rarity, large databases with long-term clinical outcomes do not exist. However, small studies with four patients have shown that 50% of patients have long-term neurologic symptoms.<sup>9</sup> Contrastingly, case reports have shown improvement, if not complete resolution, of chorea with continued diabetic control.<sup>10,11</sup> Some case series (N = 12) have also suggested that the addition of dopamine receptor inhibitors and lorazepam can lead to neurological improvement in the majority of patients.<sup>12</sup> This data suggests that clinical improvement with correct initial diagnosis and treatment is feasible, but a complete reversal of symptoms may not be achieved in all cases.

## CONCLUSION

Hemichorea presenting to the ED can be caused by several emergent diagnoses including acute cerebrovascular accident, seizures, and nonketotic hyperglycemia. Differentiation between these diagnoses requires laboratory studies with advanced imaging including CT and MRI. Knowledge of classic MRI radiologic findings is required to diagnose nonketotic hyperglycemic hemichorea. Appropriate early diagnosis of nonketotic hyperglycemia can lead to prompt treatment, improvement of symptoms, and costs savings without the harms of unnecessary interventions. Further, emergency physician awareness of imaging characteristics of nonketotic hyperglycemia hemichorea can lead to improved outcomes.

**Video.** Characteristic hemichorea and ipsilateral facial twitching of nonketotic hyperglycemia can be observed in this video.

Patient consent has been obtained and filed for the publication of this case report.

*Address for Correspondence:* Michelle Nassal, MD, PhD, The Ohio State Wexner Medical Center, Department of Emergency Medicine, 376 W 10th Ave., Columbus, OH 43210. Email: michelle.nassal@osumc.edu.

*Conflicts of Interest:* By the CPC-EM article submission agreement, all authors are required to disclose all affiliations, funding sources and financial or management relationships that could be perceived as potential sources of bias. The authors disclosed none.

*Copyright:* © 2022 Nassal. This is an open access article distributed in accordance with the terms of the Creative Commons Attribution (CC BY 4.0) License. See: <http://creativecommons.org/licenses/by/4.0/>

## REFERENCES

1. Aggarwal A, Bansal N, Aggarwal R. Nonketotic hyperglycemia presenting as monoballism. *J Emerg Med.* 2016;50(3):e133-4.
2. Patel AR, Patel AR, Desai S. Acute hemiballismus as the presenting feature of parietal lobe infarction. *Cureus.* 2019;11(5):e4675.
3. Ghika-Schmid F, Ghika J, Regli F, et al. Hyperkinetic movement disorders during and after acute stroke: the Lausanne Stroke Registry. *J Neurol Sci.* 1997;146(2):109-16.
4. Zheng W, Chen L, Chen JH, et al. Hemichorea associated with non-ketotic hyperglycemia: a case report and literature review. *Front Neurol.* 2020;11:96.
5. Yu F, Steven A, Birnbaum L, et al. T2\*-based MR imaging of hyperglycemia-induced hemichorea-hemiballism. *J Neuroradiol.* 2017;44(1):24-30.
6. Oh SH, Lee KY, Im JH, et al. Chorea associated with non-ketotic hyperglycemia and hyperintensity basal ganglia lesion on T1-weighted brain MRI study: a meta-analysis of 53 cases including four present cases. *J Neurol Sci.* 2002;200(1-2):57-62.
7. Tocco P, Barbieri F, Bonetti B, et al. Hemichorea-hemiballismus in patients with non-ketotic hyperglycemia. *Neurol Sci.* 2016;37(2):297-8.
8. Cosentino C, Torres L, Nunez Y, et al. Hemichorea/hemiballism associated with hyperglycemia: report of 20 cases. *Tremor Other Hyperkinet Mov (NY).* 2016;6:402.
9. El Otmani H, Moutaouakil F, Fadel H, et al. Chorea-ballismus in acute non-ketotic hyperglycaemia. *Funct Neurol.* 2009;24(3):129-32.
10. Lee BC, Hwang SH, Chang GY. Hemiballismus-hemichorea in older diabetic women: a clinical syndrome with MRI correlation. *Neurology.* 1999;52(3):646-8.
11. Wilson TJ, Than KD, Stetler WR, et al. Non-ketotic hyperglycemic chorea-hemiballismus mimicking basal ganglia hemorrhage. *J Clin Neurosci.* 2011;18(11):1560-1.
12. Guo Y, Miao YW, Ji XF, et al. Hemichorea associated with nonketotic hyperglycemia: clinical and neuroimaging features in 12 patients. *Eur Neurol.* 2014;71(5-6):299-304.

## Diagnosing Pheochromocytoma in the COVID-19 Era: A Case Report

Frank Mayer III DO, MBA\*  
Raafia Memon, MD†  
Justin Stowens, MD\*

\*Christiana Care Health System, Department of Emergency Medicine, Newark, Delaware  
†Christiana Care Health System, Department of Endocrinology, Newark, Delaware

Section Editor: Rick McPheeters, DO

Submission history: Submitted October 18, 2021; Revision received February 22, 2022; Accepted February 25, 2022

Electronically published July 26, 2022

Full text available through open access at [http://escholarship.org/uc/uciem\\_cpem](http://escholarship.org/uc/uciem_cpem)

DOI: 10.5811/cpcem.2022.2.55091

**Introduction:** Pheochromocytomas and paragangliomas are rare neuroendocrine tumors that secrete catecholamines. Symptoms of these tumors are related directly to catecholamine excess but can be intermittent and easily misattributed to other, more common pathologies. Identification in the emergency department (ED) is inherently difficult. During the coronavirus 2019 (COVID-19) pandemic, physicians have had to account for both the disease itself as well as associated increased prevalence of cardiac, pulmonary, and vascular complications. Such shifting of disease prevalence arguably makes rarer diseases like pheochromocytoma less likely to be recognized.

**Case Report:** We report a case of pheochromocytoma in a patient who presented to the ED in the fall of 2020, at a regional height of the COVID-19 pandemic, with complaints of fatigue, tachycardia, and diaphoresis. The differential diagnosis included pulmonary embolism, cardiomyopathy, congestive heart failure, and infectious causes. A broad workup was begun that included serology, electrocardiogram, computed tomography angiogram (CTA), and COVID-19 testing. Imaging was consistent with COVID-19 infection, and laboratory testing confirmed the diagnosis. A tiny retroperitoneal tumor was reported on CTA as “incidental” in the setting of multifocal pneumonia from severe acute respiratory syndrome coronavirus 2 infection. Additional history-taking revealed many years of intermittent symptoms suggesting that the tumor may have been more contributory to the patient’s presentation than originally suspected. Subsequent magnetic resonance imaging and surgical pathology confirmed the dual diagnosis of pheochromocytoma and COVID-19 pneumonia.

**Conclusion:** This case presentation highlights the importance of careful history-taking, keeping a broad differential, and examining incidental findings in the context of the patient’s presentation. [Clin Pract Cases Emerg Med. 2022;6(3):220–224.]

**Keywords:** *case report; pheochromocytoma; COVID-19; cardiomyopathy; paraganglioma.*

### INTRODUCTION

Compared to other specialties, in emergency medicine patients are usually undifferentiated at the time of initial presentation. During the coronavirus 2019 (COVID-19) pandemic the overwhelming prevalence of patients presenting with COVID-19 has likely increased the occurrence of premature closure of the differential. This case presentation of a patient with a pheochromocytoma highlights this challenge

and demonstrates that rare diseases should still be identified in the emergency department (ED), allowing patient care and referral to subspecialists to be expedited.

### CASE PRESENTATION

A 45-year-old woman with past medical history of anxiety, hypertension, and preeclampsia (10 years prior), presented to the ED with three weeks of transient fatigue and tachycardia that had

worsened over the prior 24 hours. She additionally complained of intermittent tachypnea, dyspnea, chills, and profuse diaphoresis. The patient, who exercised regularly, was an active mother of three children. On the day before her ED presentation, she had run five miles on her treadmill without difficulty. Outpatient lab work from two weeks prior was remarkable for anemia, with hemoglobin of 7.0 grams per deciliter (g/dL) (reference range 11.7-15.7 g/dL). She had received an iron infusion the week prior to presentation, and symptoms had abated. However, when her dyspnea returned she presented to the ED wondering if a second iron infusion would help.

The patient was being evaluated during the regional peak of the COVID-19 pandemic prior to vaccine availability, and she had not been tested for COVID-19 previously. Notably, she reported abiding by social distancing guidelines and wearing a mask regularly.

Her triage vital signs were temperature of 36.8° Celsius, heart rate 137 beats per minute (bpm), respiratory rate 24 breaths per minute, blood pressure 173/132 millimeters of mercury (mm Hg), and peripheral oxygen saturation of 99% on room air. On physical exam she was anxious, speaking quickly and in earnest. She was notably diaphoretic. She was tachycardic but without murmurs, rubs, or gallops; 2+ pulses were palpated in all four extremities. Despite her dyspnea and tachypnea, her lungs were clear bilaterally with equal bilateral chest rise. She uncomfortably shifted her position frequently in the stretcher. An electrocardiogram (ECG) showed sinus tachycardia with ST-segment depression in the inferior leads with T-wave flattening in I and aVL (Image 1).

### CPC-EM Capsule

What do we already know about this clinical entity?

*Pheochromocytomas are rare and the prevalence of coronavirus disease 2019 (COVID-19) dwarfs them by comparison. Recognition is key as common medications used to control heart rate and blood pressure can worsen symptoms.*

What makes this presentation of disease reportable?

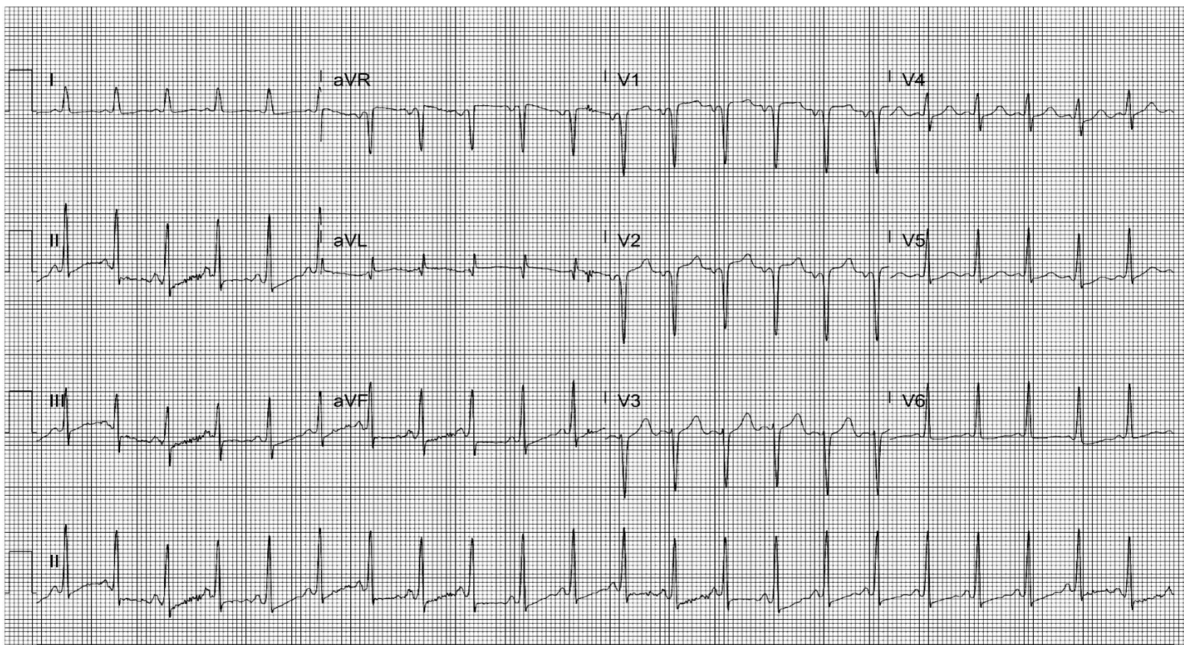
*The increased prevalence of cardiac, respiratory, and vascular complications associated with the COVID-19 virus make detection of rarer diseases more difficult during the pandemic.*

What is the major learning point?

*Keeping a broad differential can be difficult during COVID-19 surges. Avoid premature diagnostic closure and reexamine the differential as more data becomes available.*

How might this improve emergency medicine practice?

*This case reinforces the importance of a broad differential and demonstrates that making challenging diagnoses can and should be done in the emergency department.*



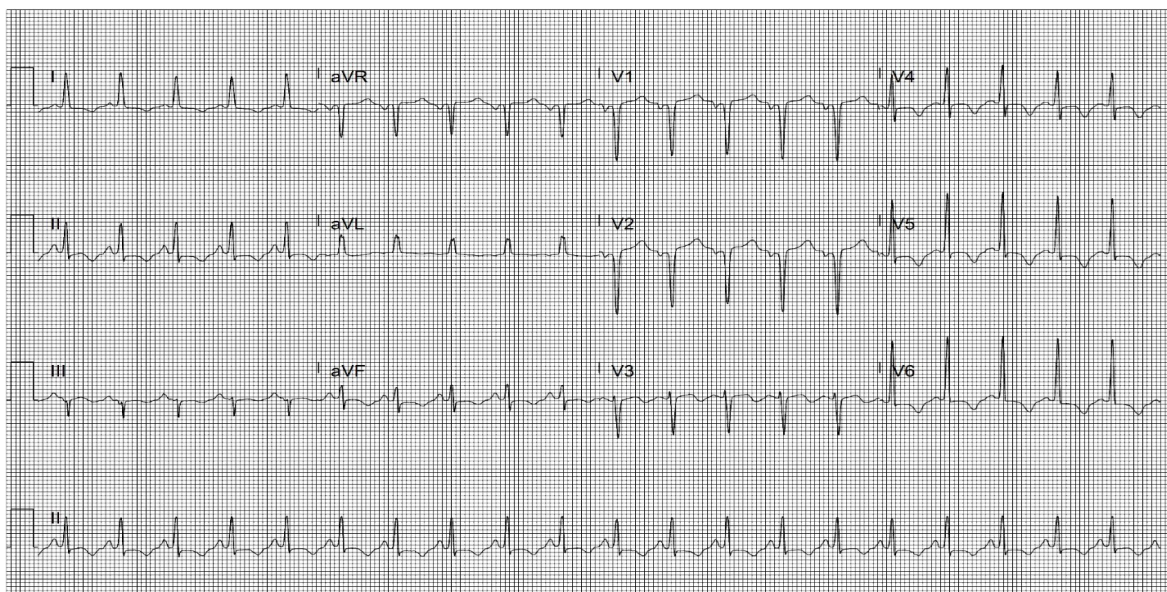
**Image 1.** Electrocardiogram showing heart rate of 132 beats per minute, small ST-segment depressions in inferior leads with T-wave flattening in I and aVL.

Preliminary workup was started for a differential diagnosis that included pulmonary embolism, acute coronary syndrome (ACS), anemia, and infectious etiologies including COVID-19. Intravenous fluids were given as well as 0.5 milligrams of IV lorazepam as the patient was experiencing severe anxiety. Labs were significant for only a mild anemia with a hemoglobin of 9.2 g/dL, and an elevated brain natriuretic peptide (BNP) of 3871 picograms per milliliter (pg/mL) (reference range 0-192 pg/mL). Troponin T was also noted to be < 0.01 nanogram per milliliter (ng/mL) (reference range 0.00-0.03 ng/mL). A two-view chest radiograph demonstrated mild multi-lobar infiltrates. Subsequent computed tomography angiogram (CTA) of the chest was negative for pulmonary embolism but did show evidence of pulmonary edema vs infection as well as a right-sided consolidation consistent with pneumonia. Multiple incidental findings including a small renal cyst, small liver cyst, and tiny mass in the left retroperitoneum were found on the CTA for which magnetic resonance imaging (MRI) and further follow-up was recommended. Testing for COVID-19 returned positive within a few hours. Clinician hand-off occurred at this point with a closed differential of severe COVID-19 infection.

The patient improved greatly with fluids and benzodiazepines. Her heart rate decreased to just above 100 bpm, blood pressure decreased to 130/80 mm Hg, and all reported symptoms completely resolved at a two-hour reassessment. She was admitted to the hospital for further management. Pending transfer to the floor, an hour later she had a return of symptoms with palpitations and shortness of breath. Her vital signs were now notable for a return of tachycardia and tachypnea as well as elevated blood pressure. She remained afebrile. Repeat ECG showed new T-wave inversions in leads I, II, V4, V5, and V6 (Image 2).

Although not widely reported at this stage in the pandemic, concern for the possibility of a COVID-19-induced myocarditis was raised as well as new development of pulmonary embolism, pericardial effusion, or new occurrence of ACS. Elevated blood pressures were fortunately not consistent with dilated cardiomyopathy that has been seen with other viral pathogens. Initial troponin testing had also been negative. Serial troponin testing was sent, and a point-of-care cardiac ultrasound was performed. This demonstrated a hyperdynamic left ventricle with reduced ejection fraction of approximately 45%. Left ventricular wall thickness was increased and there were no signs of pericardial effusion, focal wall motion abnormality, or increased size of the right ventricle. Highly specific findings for right heart strain such as McConnell's sign and decreased tricuspid annular plane systolic excursion were absent. As point-of-care cardiac ultrasound showed signs of heart failure without a dilated cardiomyopathy and serial troponin testing was negative, viral myocarditis did not seem likely.

During this re-evaluation further history was obtained. The patient revealed that she had been treated for hypertension intermittently over the prior nine years and that the pattern of sudden onset of symptoms with sudden resolution of symptoms had been occurring with less severity for many years. With the change in the patient's clinical condition, an enhanced clinical history, dynamic vital sign changes, and bedside echocardiography suggestive of heart failure, the clinical workup and differential was reviewed. The CTA showing the incidental retroperitoneal mass raised the possibility of a catecholamine-producing tumor, and this was discussed with the inpatient team. The patient was successfully stabilized with alpha blockade as well as beta blockade over the next few days.



**Image 2.** Electrocardiogram showing sinus tachycardia at 100 beats per minute; new T-wave inversions are noted in V4 though V6, as well as leads I, II, with T-wave flattening in aVF.

Inpatient testing revealed elevated levels of plasma-free metanephrines, specifically norepinephrine at greater than 20 times the normal level, strongly suggestive of a neuroendocrine tumor. An MRI was performed demonstrating a 4.0 x 3.9 x 3.5-centimeter retroperitoneal mass consistent with pheochromocytoma (PCC). The patient was treated as well for COVID-19 pneumonia and medically optimized before discharge. As an outpatient she was evaluated by an endocrine surgeon and had subsequent adrenalectomy, after which pathology demonstrated a neuroendocrine tumor with capsular and vascular invasion. Following surgery, the patient had resolution of all symptoms and has not required further antihypertensive treatment.

## DISCUSSION

Paragangliomas and PCCs are part of the family of neuroendocrine tumors, with an exceedingly rare prevalence of between two and eight per million.<sup>1</sup> Pheochromocytomas are catecholamine-producing tumors that arise from the adrenal medulla, while paragangliomas, their closely related counterparts, arise from non-head-and-neck sympathetic ganglia. They often produce more norepinephrine than epinephrine, but sometimes exclusively epinephrine. In contrast, paragangliomas produce mostly norepinephrine with some dopamine. Together they account for only 0.2-0.6% of all cases of severe hypertension in adults.<sup>2</sup> Most tumors are benign, but those that are malignant are generally associated with familial genetic disorders.<sup>3</sup> Malignancy is determined by metastases and local invasion.<sup>1</sup> As in this case, up to 61% of tumors are found incidentally on imaging.<sup>4-6</sup>

The classic triad of headache, diaphoresis, and tachycardia is associated with catecholamine tumors. However, these symptoms do not present together in a majority of patients. As seen in this case, the most common sign is paroxysmal or sustained hypertension, although 5-15% may be normotensive.<sup>7</sup> Certain medications and physiologic stressors such as metoclopramide, anesthetics, and beta-blockers, trauma, surgery, or infection can precipitate symptoms. Cardiomyopathy is a rare complication and is attributed to the direct toxic effects of catecholamines on the myocardium and catecholamine-induced myocardial stunning, similar to the pathophysiology of takotsubo cardiomyopathy. It may be more common when PCC is untreated for long periods of time.<sup>8</sup>

Besides an example of rare pathology and an additionally rare occurrence of dual pathologies, this case offers an example of premature diagnostic closure. Premature diagnostic closure is a type of cognitive bias whereby the physician anchors on a diagnosis early in the clinical decision-making process and excludes other possible diagnoses, even when evidence supporting an alternative diagnosis is present. This can result in failure to make the correct diagnosis. It can also lead to diagnostic momentum where the incorrect diagnosis drives the ongoing workup and treatment plan further in the wrong direction, making

correction more difficult.<sup>9</sup> Keeping a broad early differential and reexamining that differential as new evidence becomes available helps avoid this type of error. Fortunately, in this case the early diagnostic closure was recognized when the patient's clinical presentation worsened in a way not consistent with the working (incorrect) diagnosis of solitary COVID-19 infection.

This case specifically highlights an additional push toward early diagnostic closure due solely to the prevalence of COVID-19 disease during the local peak of the pandemic surge. For example, most patients with COVID-19 had a complaint of shortness of breath. It therefore became so likely that a complaint of shortness of breath was due to COVID-19 that it became difficult to consider attributing the shortness of breath to a different cause. In this case, the concomitant presence of COVID-19 made this push even stronger.

The novelty of the virus added yet another opportunity for early diagnostic closure. This patient presented during the stage of the pandemic when complications and varied presentations of the infection were still being discovered. Complications such as the relationship between the infection and thromboembolic disease were yet to be confirmed.<sup>10</sup> In such a setting, unique or rarer complaints of patients with COVID-19 might be inappropriately attributed to the infection as simply "under-reported" when in truth they were due to a different disease process. In our patient, the transient nature of the patient's hypertension and dyspnea were initially incorrectly attributed to COVID-19.

The presence of the COVID-19 infection resulted in premature diagnostic closure. It should be noted that the difficulties with making this diagnosis extended beyond the cognitive challenge. With MRI resources kept out of routine use due to extensive cleaning needed between COVID-19 patients, there was significant delay in completing the MRI. In fact, the patient's urinary metanephrine test (a 10-day, send-out test) resulted on the same day that the patient finally received the MRI.

## CONCLUSION

Pheochromocytomas are rare and have signs and symptoms that typically arise from more common causes, making them a difficult diagnosis in the ED in non-pandemic times. As always in emergency medicine, careful history-taking, considering the patient's entire constellation of symptoms, and keeping a broad differential is critical to making the diagnosis. In the setting of COVID-19 these tasks become equally more paramount and more difficult. Cases such as the one we report here highlight the need for heightened suspicion and diligence during this time of diagnostic obfuscation caused by the COVID-19 pandemic.

The authors attest that their institution requires neither Institutional Review Board approval, nor patient consent for publication of this case report. Documentation on file

**Address for Correspondence:** Justin Stowens, MD, Christiana Care Health System, Department of Emergency Medicine, 4755 Ogeltown-Stanton Rd, Newark, DE 19713. Email: justin.stowens@christianacare.org.

**Conflicts of Interest:** By the CPC-EM article submission agreement, all authors are required to disclose all affiliations, funding sources and financial or management relationships that could be perceived as potential sources of bias. The authors disclosed none.

**Copyright:** © 2022 Mayer. This is an open access article distributed in accordance with the terms of the Creative Commons Attribution (CC BY 4.0) License. See: <http://creativecommons.org/licenses/by/4.0/>

## REFERENCES

- Pappachan J, Raskauskiene D, Sriraman R, et al. Diagnosis and management of pheochromocytoma: A practical guide to clinicians. *Curr Hypertens Rep.* 2014;16(7):442.
- Pappachan JM, Tun NN, Arunagirinathan G, et al. Pheochromocytomas and hypertension. *Curr Hypertens Rep.* 2018;20(1):3.
- Reisch N, Peczkowska M, Januszewicz A, et al. Pheochromocytoma: presentation, diagnosis, and treatment. *J Clins Hypertens.* 2006;24(12):2331-9.
- Aygun N and Uludag M. Pheochromocytoma and paraganglioma: from epidemiology to clinical findings. *The Medical Bulletin of Sisli Etfal Hospital.* 2020;54(2):159.
- Baguet JP, Hammer L, Mazzuco TL, et al. Circumstances of discovery of phaeochromocytoma: a retrospective study of 41 consecutive patients. *Eur J Endocrinol.* 2004;150(5):681-6.
- Motta-Ramirez GA, Remer EM, Herts BR, et al. Comparison of CT findings in symptomatic and incidentally discovered pheochromocytomas. *AJR Am J Roentgenol.* 2005;185(3):684-8.
- Manger WM and Gifford RW. Pheochromocytoma. *J Clins Hypertens.* 2002;4(1):62-72
- Mantes L, Marlière S, Chabre O, et al. Could pheochromocytoma induced cardiomyopathy be influenced by an excessive delay before diagnosis? Discussion about two case-reports. *J Clins Hypertens.* 2019;37:e272.
- Saposnik, G., Redelmeier, D., Ruff, C.C. et al. Cognitive biases associated with medical decisions: a systematic review. *BMC Med Inform Decis Mak* 2016;16(1):138.
- Malas MB, Naazie IN, Elsayed N, et al. Thromboembolism risk of COVID-19 is high and associated with a higher risk of mortality: a systematic review and meta-analysis. *E Clinical Medicine.* 2020;29-30:100639

# Takotsubo Cardiomyopathy Following Traumatic Hand Amputation: A Case Report

**Bastien H. Bacro-Duverger, MD\*** \*The University of Alabama at Birmingham, Department of Emergency Medicine, Birmingham, Alabama  
**Ashley Q. Thorburn, MD†**  
**Brad D. Denney, MD†** †The University of Alabama at Birmingham, Division of Plastic Surgery, Department of Surgery, Birmingham, Alabama  
**John P. Gullett, MD\***  
**Maxwell A. Thompson, MD\***  
**David C. Pigott, MD\***

Section Editor: Rachel Lindor, MD, JD

Submission History: Submitted November 20, 2021; Revision received March 20, 2022; Accepted March 30, 2022

Electronically published July 27, 2022

Full text available through open access at [http://escholarship.org/uc/uciem\\_cpem](http://escholarship.org/uc/uciem_cpem)

DOI: 10.5811/cpem.2022.2.55463

**Introduction:** Takotsubo or stress cardiomyopathy is a syndrome of transient left ventricular systolic dysfunction seen in the absence of obstructive coronary artery disease.

**Case Report:** We describe a case of stress cardiomyopathy diagnosed in the emergency department (ED) using point-of-care ultrasound associated with traumatic hand amputation. The patient suffered a near-complete amputation of the right hand while using a circular saw, subsequently complicated by brief cardiac arrest with rapid return of spontaneous circulation. Point-of-care ultrasonography in the ED revealed the classic findings of takotsubo cardiomyopathy, including apical ballooning of the left ventricle and hyperkinesis of the basal walls with a severely reduced ejection fraction. After formalization of the amputation and cardiovascular evaluation, the patient was discharged from the hospital in stable condition 10 days later.

**Conclusion:** Emergency physicians should be aware of the possibility of stress cardiomyopathy as a cause for acute decompensation, even in isolated extremity trauma. [Clin Pract Cases Emerg Med. 2022;6(3):225–228.]

**Keywords:** *stress cardiomyopathy; takotsubo cardiomyopathy; traumatic amputation; ultrasonography; case report.*

## INTRODUCTION

First described in the 1990s in Japan, takotsubo or stress cardiomyopathy is an uncommon cause of acute-onset heart failure, although its pathogenesis is still poorly understood.<sup>1</sup> It is a syndrome of transient left ventricular systolic dysfunction seen in the absence of obstructive coronary artery disease. Although a sudden stressful or emotional event is often a precursor to the development of this condition, up to 30% of cases have no identifiable precipitating event.<sup>2</sup> The name comes from a Japanese octopus trap, which resembles the balloon-like shape often taken by the left ventricle in takotsubo cardiomyopathy. The left ventricular wall motion abnormalities seen in takotsubo cardiomyopathy

typically extend beyond the distribution of a single coronary artery. Hypotheses for the pathogenesis of this condition include catecholamine excess, microvascular dysfunction, and coronary artery spasm.<sup>3</sup> Epidemiologically, stress cardiomyopathy affects postmenopausal women (as in this case) disproportionately.<sup>4</sup>

Mayo Clinic diagnostic criteria for stress cardiomyopathy are the following: 1) transient left ventricular systolic dysfunction usually extending beyond a single coronary distribution; 2) absence of obstructive coronary disease explaining the wall motion abnormalities; 3) new electrocardiogram (ECG) abnormalities or elevation in cardiac troponins; and 4) absence of pheochromocytoma or

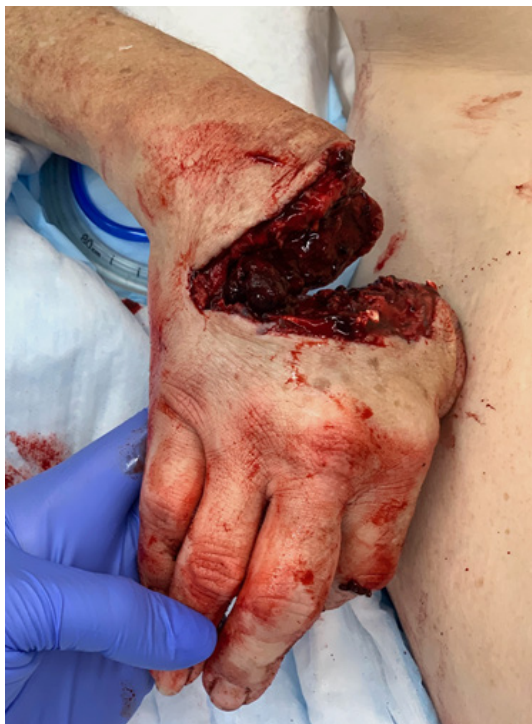

myocarditis.<sup>5</sup> Mortality in the International Takotsubo Registry study was reported at 4.1%.<sup>2</sup> Those that survive typically recover systolic function within one to four weeks.<sup>6</sup> As the name implies, stress cardiomyopathy is typically diagnosed surrounding emotionally or physiologically stressful events. This case reminds us that stress cardiomyopathy must remain on the differential even in isolated extremity trauma.

## CASE REPORT

A 63-year-old female presented to the emergency department (ED) following an accidental subtotal amputation of her right hand with a circular saw while working on a craft project with her husband. She initially presented to an outside hospital who arranged transfer to a tertiary care center by air for plastic surgery consultation and possible re-implantation. En route she had an episode of nausea and vomiting accompanied by bradycardia to the 20s. She became briefly pulseless and underwent one round of Advanced Cardiac Life Support including chest compressions, intravenous epinephrine, and intubation. She was diverted to the closest ED for stabilization where she received one unit of packed red cells for a hemoglobin of 8 grams per deciliter (g/dL) (reference range: 11.3-15.2 g/dL). She was subsequently transported to our tertiary care center by ambulance.

Physical examination revealed subtotal amputation through the base of all five metacarpals extending from radial to ulnar aspect with a small remaining tissue bridge along the ulnar border. An intermittent monophasic Doppler signal was



**Image 1.** Photograph of right hand near-total amputation.

### CPC-EM Capsule

What do we already know about this clinical entity?

*Takotsubo or stress cardiomyopathy is typically a short-term illness, diagnosed by echocardiography. Its causes may include stress, trauma, or sudden illness.*

What makes this presentation of disease reportable?

*We describe a novel association between severe extremity trauma complicated by cardiac arrest with the rapid development of takotsubo cardiomyopathy.*

What is the major learning point?

*In the trauma or post-cardiac arrest patient, point-of-care ultrasound (POCUS) may yield findings that could have important implications for subsequent patient care.*

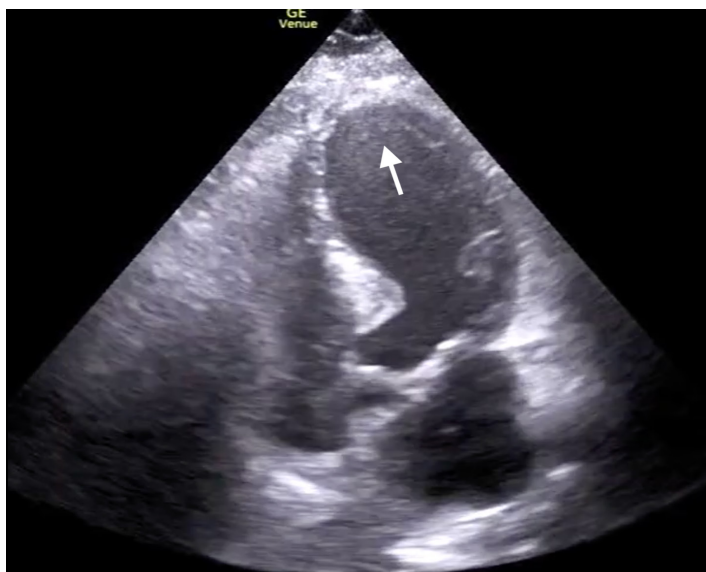How might this improve emergency medicine practice?

*The use of POCUS, as well as the recognition and diagnosis of takotsubo cardiomyopathy, can expedite appropriate patient management and specialty referral.*

present near the ulnar artery. All five fingers were cold and pale without capillary refill (Image 1).

On arrival, laboratory evaluation revealed a hemoglobin of 10.7 g/dL, lactic acid of 3.7 millimoles per liter (mmol/L) (reference range: 0.5-2.2 mmol/L), and troponin of 0.183 nanograms per milliliter (ng/mL) (0.000-0.029 ng/mL). An ECG demonstrated one millimeter ST elevations in the anterior precordial leads without reciprocal depression. Point-of-care echocardiogram in the ED revealed severely reduced left ventricular ejection fraction of 25-30% with apical hypokinesis, basal hyperkinesis, mild mitral regurgitation, and preserved right heart function. This presentation and echocardiographic findings were highly concerning for takotsubo cardiomyopathy (Image 2, Video).

Following completion of the patient's amputation at the bedside by plastic surgery, the patient was admitted to the medical intensive care unit for further management. Formal echocardiography approximately 24 hours after presentation revealed moderately reduced left ventricular systolic function with an ejection fraction of 35-40%. The mid to distal septal, anterior, and lateral walls were severely hypokinetic to akinetic with akinetic apex. The right ventricle remained



**Image 2.** Apical 4-chamber ultrasound view demonstrating apical ballooning (arrow).

normal in size and function. Troponin peaked at 1.589 ng/mL and B-type natriuretic peptide uptrended from 39 picograms per milliliter (pg/mL) on arrival to 536 pg/mL (reference range: 0.0-100.0 pg/ml).

Left heart catheterization was performed on hospital day one and revealed minimal non-obstructive coronary artery disease with luminal irregularities and elevated left ventricular end diastolic pressure of 19 millimeters of mercury (mm Hg) (<12 mm Hg), essentially ruling out coronary artery disease as a cause for her cardiomyopathy. She underwent formalization of her right hand amputation with plastic surgery and was subsequently extubated. She was discharged from the hospital after a 10-day admission. Eight months following the accident the patient was fitted with a bioelectric hand prosthesis. Unfortunately, no further information was available regarding her cardiovascular recovery.

## DISCUSSION

We present the case of a previously healthy 63-year-old female who developed stress cardiomyopathy and brief cardiac arrest following isolated severe extremity trauma. Her initial hemodynamic instability and cardiovascular collapse could not be fully explained by hypovolemic shock secondary to hemorrhage. Point-of-care ultrasound (POCUS) in the ED revealed the classically described wall motion abnormalities of apical ballooning of the left ventricle and hyperkinesis of the basal walls. Diagnosis of takotsubo cardiomyopathy was later confirmed by comprehensive echocardiogram and coronary catheterization revealing an absence of significant coronary artery disease.

Although relatively uncommon – studies have placed the incidence at 1-2% in patients presenting with symptoms concerning for acute coronary syndrome – takotsubo

cardiomyopathy is a diagnosis most emergency physicians will encounter in their practice, although it may not be easily recognizable.<sup>7,8</sup> Our patient fits the classic demographic, as the syndrome disproportionately affects post-menopausal females. In the International Takotsubo Registry study, 88.9% of the affected patients were females and the mean age was 66.4 years.<sup>2</sup> Takotsubo cardiomyopathy has been reported following multiple types of traumatic injury, including brain injury, subarachnoid hemorrhage, and burns, as well as motor vehicle collision.<sup>9-11</sup>

## CONCLUSION

In this case we describe a patient who suffered a cardiac arrest in the setting of isolated extremity trauma and then developed stress cardiomyopathy within hours of the initial insult. This patient had the classic findings of stress cardiomyopathy on bedside echocardiography in the ED: apical ballooning; basal hyperkinesis; and reduced ejection fraction. This case emphasizes the utility of POCUS in the critically ill or injured ED patient, providing important diagnostic information that may not be otherwise available. It reminds the emergency physician to maintain a broad differential even when the diagnosis seems to be apparent.

Because the patient's stress cardiomyopathy was not immediately evident on ED arrival, POCUS enabled the clinical team to avoid potential subsequent mismanagement of undiagnosed severe cardiac disease. In the setting of post-traumatic cardiac arrest, a POCUS-guided diagnosis of new-onset cardiomyopathy may, as in this case, provide important diagnostic data to guide the patient's subsequent ED management and hospital course.

**Video.** Point-of-care ultrasound demonstrating apical ballooning (arrow) and basal hyperkinesis (arrowheads), typical for takotsubo cardiomyopathy.

Documented patient informed consent and/or Institutional Review Board approval has been obtained and filed for publication of this case report.

**Address for Correspondence:** David C. Pigott, MD, The University of Alabama at Birmingham, Department of Emergency Medicine, 701 20th Street South., Birmingham, AL 35233 Email: dpigott@uabmc.edu.

**Conflicts of Interest:** By the CPC-EM article submission agreement, all authors are required to disclose all affiliations, funding sources and financial or management relationships that could be perceived as potential sources of bias. The authors disclosed none.

**Copyright:** © 2022 Bacro-Duverger. This is an open access article distributed in accordance with the terms of the Creative Commons Attribution (CC BY 4.0) License. See: <http://creativecommons.org/licenses/by/4.0/>

## REFERENCES

1. Sato H, Tateishi H, Uchida T. (1990). Takotsubo-type cardiomyopathy due to multivessel spasm. In: Kodama K, Haze K, Hon M, (Eds.), *Clinical Aspect of Myocardial Injury: From Ischemia to Heart Failure (56)*. Tokyo: Kagakuhyouronsha.
2. Templin C, Ghadri J, Diekmann J, et al. Clinical features and outcomes of takotsubo (stress) cardiomyopathy. *N Engl J Med*. 2015;373(10):929.
3. Wittstein I, Thiemann D, Lima J, et al. Neurohumoral features of myocardial stunning due to sudden emotional stress. *N Engl J Med*. 2005;352(6):539.
4. Bybee K, Kara T, Prasad A, et al. Systematic review: transient left ventricular apical ballooning: a syndrome that mimics ST-segment elevation myocardial infarction. *Ann Intern Med*. 2004;141(11):858.
5. Prasad A, Lerman A, Rihal C. Apical ballooning syndrome (Tako-Tsubo or stress cardiomyopathy): a mimic of acute myocardial infarction. *Am Heart J*. 2008;155(3):408.
6. Tsuchihashi K, Ueshima K, Uchida T, et al. Transient left ventricular apical ballooning without coronary artery stenosis: a novel heart syndrome mimicking acute myocardial infarction. Angina pectoris-myocardial infarction investigations in Japan. *J Am Coll Cardiol*. 2001;38(1):11.
7. Kurowski V, Kaiser A, von Hof K, et al. Apical and midventricular transient left ventricular dysfunction syndrome (takotsubo cardiomyopathy): frequency, mechanisms, and prognosis. *Chest*. 2007 Sep;132(3):809-16.
8. Gianni M, Dentali F, Grandi A, et al. Apical ballooning syndrome or takotsubo cardiomyopathy: a systematic review. *Eur Heart J*. 2006 Jul;27(13):1523-9.
9. Cheah C, Kofler M, Schiefecker A, et al. Takotsubo cardiomyopathy in traumatic brain injury. *Neurocrit Care*. 2017 Apr;26(2):284-291.
10. Fagin A, Sen S, Palmieri T, et al. Takotsubo cardiomyopathy caused by severe burn injury. *J Burn Care Res*. 2012 Sep-Oct;33(5):e243-6.
11. Renko A, Doyle W, Sokoloski P. Traumatic takotsubo cardiomyopathy in a patient with extensive coronary artery disease. *Case Rep Emerg Med*. 2019 Jun 12;2019:7270426.

# Atypical Presentation of Traumatic Pediatric Carotid Artery Dissection: A Case Report

Duncan McGuire, DO\*  
Nicholas Mielke, BS†  
Amit Bahl, MD\*

\*Beaumont Hospital, Department of Emergency Medicine, Royal Oak, Michigan  
†Oakland University William Beaumont School of Medicine, Department of Emergency Medicine, Royal Oak, Michigan

Section Editor: Austin Smith, MD

Submission history: Submitted February 18, 2022; Revision received April 13, 2022; Accepted April 15, 2022

Electronically published August 6, 2022

Full text available through open access at [http://escholarship.org/uc/uciem\\_cpem](http://escholarship.org/uc/uciem_cpem)

DOI: 10.5811/cpem.2022.4.56488

**Introduction:** Carotid artery dissection is a rare but serious condition manifesting with signs and symptoms that closely overlap with other more benign medical diagnoses. This vascular injury, however, can result in debilitating sequelae, including thromboembolic cerebrovascular accidents.

**Case Report:** We describe the atypical presentation of a healthy eight-year-old male who presented to the emergency department (ED) with generalized abdominal pain and non-bloody, non-bilious emesis. These symptoms occurred nine days after he sustained blunt head trauma after a non-syncopal fall from standing while playing hockey. He was initially diagnosed with gastroesophageal reflux disease and constipation and was discharged home. The following day he developed an acute headache followed shortly by gait ataxia, prompting a return visit to the ED. Imaging of the head and neck revealed a left internal carotid artery dissection. The patient was started on intravenous unfractionated heparin and admitted to the hospital. He was later discharged symptom-free on therapeutic enoxaparin for eight weeks, followed by daily aspirin therapy.

**Conclusion:** Pediatric trauma patients, especially those sustaining insult to the head and cervical spine, are at risk for craniocervical arterial injuries. This rare but dangerous pathology often manifests in a non-specific, delayed fashion making it a challenging diagnosis for physicians to make on the initial medical encounter.<sup>1,2</sup> Maintaining a high clinical suspicion for carotid artery dissection is required to make this diagnosis and should guide a thorough history, physical examination, and appropriate imaging in order to improve patient morbidity and mortality. This case emphasizes key clinical features and risk factors of this disease that may help emergency clinicians promptly recognize and treat this entity. [Clin Pract Cases Emerg Med. 2022;6(3):239–231.]

**Keywords:** *carotid artery dissection; craniocervical artery dissection; pediatric trauma; ataxia; emergency medicine.*

## INTRODUCTION

Acute ischemic stroke (AIS) in the pediatric population is a relatively rare event, with an incidence estimated at around 2.5–8 per 100,000 children per year.<sup>3</sup> Up to 20%<sup>4</sup> of childhood AIS is due to craniocervical arterial dissection (CCAD), which can occur spontaneously, typically in an adolescent with known risk factors, but it most often presents after head and neck trauma.<sup>3</sup> Craniocervical arterial dissection in children can lead to devastating neurological impairment and other long-

term sequelae; so early recognition of CCAD in the pediatric population is crucial. In this case study, we present a young boy with a delayed presentation of post-traumatic CCAD.

## CASE REPORT

We present a case of a previously healthy eight-year-old male who fell while ice skating during a hockey scrimmage. The patient suffered a small scalp contusion, but there was no loss of consciousness, neurologic deficit, depressed Glasgow

Coma Scale, subsequent seizure, or retrograde amnesia. He was not on anticoagulation. Nine days later, the patient presented to the emergency department (ED) with a chief complaint of diffuse abdominal pain and post-prandial, non-bloody, non-bilious emesis. He did not have any neurologic signs or symptoms at that time and was discharged from the ED with a diagnosis of gastroesophageal reflux disease and constipation. The following day he developed a headache followed shortly by an episode of acute ataxia resulting in difficulty with ambulation, prompting a return to the ED.

Upon repeat evaluation, the patient was well-appearing, in no acute distress, and well-hydrated. He was afebrile and hemodynamically stable (39.1 kilograms; temperature 36.5°C; heart rate 64 beats per minute; respiratory rate 24 breaths per minute; and blood oxygen saturation 100% on room air). On physical exam, he had an ataxic gait. The remainder of the exam was unremarkable. Given the acute neurological deficit, he underwent brain computed tomography (CT) without contrast, CT angiography (CTA) of the brain and neck, and magnetic resonance imaging (MRI) of the brain, which revealed a subacute left internal carotid artery dissection. With no known risk factors for spontaneous or traumatic vascular injury, this finding was presumed to be secondary to his prior non-syncopal fall. The patient was immediately started on an intravenous infusion of weight-based unfractionated heparin, which was later switched to subcutaneous enoxaparin. Neurosurgery was consulted and advised against acute surgical intervention. He was discharged symptom-free on therapeutic enoxaparin for eight weeks, followed by daily aspirin therapy. Subsequent repeat MRI several weeks later demonstrated spontaneous resolution of the intimal dissection.

## DISCUSSION

Craniovascular arterial dissection is an exceedingly uncommon event, with an annual incidence of 2.6–2.9 per 100,000 people. This pathology, however, accounts for up to 20% of strokes in young adults, a disproportionately large percentage.<sup>4</sup> Vascular dissections can be spontaneous or traumatic in origin, with often innocuous mechanisms of injury. Craniovascular arterial dissection risk factors include connective tissue disorders that can predispose to vascular injury (eg, Ehlers-Danlos, Marfan's syndrome, osteogenesis imperfecta, and fibromuscular dysplasia), blunt or penetrating head and neck trauma, male gender (53-57% of cases), migraine with aura, and hypercholesterolemia.<sup>1,4</sup> Due to the spectrum of potential factors predisposing to dissection, it is critical to obtain a thorough medical history and perform a tailored diagnostic evaluation of patients found to have CCAD.

If clinical suspicion is high, magnetic resonance angiography (MRA), which possesses a sensitivity and specificity of 84% and 99%, respectively, is the recommended initial imaging modality.<sup>5</sup> Alternative modalities include CTA (with sensitivity rates between 51-100% and specificity values

### *CPC-EM Capsule*

What do we already know about this clinical entity?

*Early diagnosis of craniocervical arterial dissection (CCAD) in children is crucial given the potentially devastating neurological impairment and other long-term sequelae.*

What makes this presentation of disease reportable?

*This delayed and non-specific presentation emphasizes the importance that history, exam, and clinical suspicion play in the diagnosis of CCAD in children.*

What is the major learning point?

*Obtaining a history of trauma remains crucial, even in patients presenting with seemingly benign symptoms.*

How might this improve emergency medicine practice?

*This case emphasizes key clinical features and risk factors that may help emergency clinicians promptly recognize and treat CCAD.*

67-100%), Doppler ultrasound (sensitivity ranging between 71-96%), and conventional angiography.<sup>6,7</sup> Conventional angiography is considered the gold standard for diagnosis of CCAD in pediatric and adult populations; however, potential complications including femoral hematoma, radiation exposure, and sedation requirement have contributed to the increasing popularity of MRI/MRA.<sup>1,8</sup> In addition to being non-invasive and requiring no radiation exposure, MRI/MRA can simultaneously evaluate for stroke and dissection. Furthermore, this imaging modality can visualize intramural hematomas along arterial walls, which are estimated to occur in 76–91% of all vessel dissections.<sup>1</sup>

Patients with either spontaneous or traumatic CCAD often present with transient and nonspecific symptoms ranging from benign to severe in nature. Innocuous symptoms, which may include vomiting and neck pain, among others, can occur in the presence or absence of more concerning symptoms. One study reports that diffuse headache is more common than neck pain in children.<sup>9</sup> Interestingly, the number of days from onset of headache or neck pain to neurological deficits is 15 hours and 14 days, respectively.<sup>10</sup> Children with CCAD frequently present

with neurologic findings; internal carotid artery dissection often results in the triad of ipsilateral neck and/or head pain, ipsilateral Horner syndrome, and delayed neurologic symptoms secondary to ischemia.<sup>3,9,11</sup> Symptoms specific to ischemia of the anterior circulation include aphasia and hemiparesis, whereas posterior circulation ischemia most often results in ataxia, ipsilateral cranial nerve involvement, hemiplegia, and dysarthria. Cerebrovascular ischemic events can occur within minutes; however, they may not be present until up to one month after the initial insult.<sup>12</sup> Patients who develop cerebral ischemia or infarction tend to have a good prognosis with nearly 75% regaining full functionality within 12 weeks.<sup>4</sup>

The case that we present highlights the tortuous course that may accompany diagnosing CCAD, emphasizing the importance that history and examination, and the clinician's suspicion of this pathology play in this diagnosis. This suspicion should be increased in patients with nonspecific, delayed, post-traumatic symptoms and repeat ED visits. Although our patient did not develop any symptoms until nine days after his fall, eliciting a history of prior head and neck trauma during his initial ED presentation may have prompted the emergency physicians to consider a neurologic etiology for his seemingly benign symptoms of abdominal pain and emesis. It was not until the tenth day after his injury that he developed a headache and associated ataxia resulting in a thorough neurologic evaluation on repeat ED visit, which ultimately revealed the underlying diagnosis.

## CONCLUSION

Despite its rarity, craniocervical arterial dissection is the leading cause of cerebrovascular accidents in children. A wide variety of congenital and chronic diseases can predispose patients to CCAD; however, these conditions are not essential for this injury to occur. While symptoms related to CCAD can be immediate, many patients present in a delayed fashion. Clinicians must maintain a high index of suspicion when evaluating at-risk patient populations, recognizing that a benign mechanism of injury may cause this serious insult. This suspicion should be heightened when treating patients with repeat ED visits and should be in the differential when evaluating post-concussive patients, particularly those with a persistent or worsening headache or neurologic signs or symptoms.

Documented patient informed consent and/or Institutional Review Board approval has been obtained and filed for publication of this case report.

*Address for Correspondence:* Duncan McGuire, DO, Beaumont Hospital, Department of Emergency Medicine, 3601 West 13 Mile Road, Royal Oak, MI 48073. Email: [Duncan.McGuire@beaumont.org](mailto:Duncan.McGuire@beaumont.org)

**Conflicts of Interest:** By the CPC-EM article submission agreement, all authors are required to disclose all affiliations, funding sources and financial or management relationships that could be perceived as potential sources of bias. The authors disclosed none.

**Copyright:** © 2022 McGuire. This is an open access article distributed in accordance with the terms of the Creative Commons Attribution (CC BY 4.0) License. See: <http://creativecommons.org/licenses/by/4.0/>

## REFERENCES

1. Stence NV, Fenton LZ, Goldenberg NA, et al. Craniocervical arterial dissection in children: diagnosis and treatment. *Curr Treat Options Neurol.* 2011;13(6):636-48.
2. Mortazavi MM, Verma K, Tubbs RS, et al. Pediatric traumatic carotid, vertebral and cerebral artery dissections: a review. *Childs Nerv Syst.* 2011;27(12):2045-56.
3. Nash M and Rafay MF. Craniocervical arterial dissection in children: pathophysiology and management. *Pediatr Neurol.* 2019;95:9-18.
4. Blum CA and Yaghi S. Cervical artery dissection: a review of the epidemiology, pathophysiology, treatment, and outcome. *Arch Neurosci.* 2015;2(4):e26670.
5. Rodallec MH, Marteau V, Gerber S, et al. Craniocervical arterial dissection: spectrum of imaging findings and differential diagnosis. *Radiographics.* 2008;28(6):1711-28.
6. Benninger DH, Georgiadis D, Gandjour J, et al. Accuracy of color duplex ultrasound diagnosis of spontaneous carotid dissection causing ischemia. *Stroke.* 2006;37(2):377-81.
7. Nebelsieck J, Sengelhoff C, Nassenstein I, et al. Sensitivity of neurovascular ultrasound for the detection of spontaneous cervical artery dissection. *J Clin Neurosci.* 2009;16(1):79-82.
8. Dawkins AA, Evans AL, Wattam J, et al. Complications of cerebral angiography: a prospective analysis of 2,924 consecutive procedures. *Neuroradiology.* 2007;49(9):753-9.
9. Lin JJ, Chou ML, Lin KL, et al. Cerebral infarct secondary to traumatic carotid artery dissection. *Pediatr Emerg Care.* 2007;23(3):166-8.
10. Silbert PL, Mokri B, Schievink WI. Headache and neck pain in spontaneous internal carotid and vertebral artery dissections. *Neurology.* 1995;45(8):1517-22.
11. Lee VH, Brown RD, Mandrekar JN, et al. Incidence and outcome of cervical artery dissection: a population-based study. *Neurology.* 2006;67(10):1809-12.
12. Biousse V, D'Anglejan-Chatillon J, Touboul PJ, et al. Time course of symptoms in extracranial carotid artery dissections. A series of 80 patients. *Stroke.* 1995;26(2):235-9.

# Bilateral Central Retinal Vein Occlusion as a First Presentation of Multiple Myeloma: A Case Report

Michael Andrew Tandlich, MD\*  
Kelly Williamson, MD†

\*Northwestern University, Department of Emergency Medicine, Chicago, Illinois  
†Northwestern University, Feinberg School of Medicine, Department of Emergency Medicine, Chicago, Illinois

Section Editor: Rachel Lindor, MD, JD

Submission history: Submitted December 15, 2021; Revision received April 18, 2022; Accepted April 22, 2022

Electronically published July 27, 2022

Full text available through open access at [http://escholarship.org/uc/uciem\\_cpem](http://escholarship.org/uc/uciem_cpem)

DOI: 10.5811/cpem.2022.4.55710

**Introduction:** Acute presentation of multiple myeloma in the emergency department (ED) is an uncommon yet life-threatening clinical entity.

**Case Report:** A 42-year-old male presented to the ED with severe generalized fatigue and vision changes most notable in his left eye. Bilateral central retinal vein occlusion (CRVO) was diagnosed on dilated fundus exam in the ED.

**Conclusion:** The most common cause of CRVO in adults over age 50 is vascular disease, but in younger adults, conditions of systemic inflammation or hyperviscosity must be considered. Diagnosis of CRVO requires emergent ophthalmology consultation and further treatment with phototherapy, steroids, and potentially anti-vascular endothelial growth factor. Ultimately, patients require hematology/oncology and ongoing management of acute hyperviscosity syndrome. We present this case to increase awareness surrounding this diagnosis among emergency physicians. Multiple myeloma should be considered in young patients who present to the ED with bilateral CRVO, acute renal failure, and symptomatic anemia. [Clin Pract Cases Emerg Med. 2022;6(3):232–235.]

**Keywords:** *case report; bilateral central retinal vein occlusion.*

---

## INTRODUCTION

Multiple myeloma is a neoplasm characterized by the proliferation of plasma cells producing monoclonal immunoglobulins. While the presentation is often subacute or chronic, a small proportion of patients will present acutely. Patients may present with bone pain secondary to lytic lesions, an increased serum protein concentration, unexplained anemia, hypercalcemia, or acute renal failure. Although less common, acute presentations of multiple myeloma may present to the emergency department (ED), where it is imperative the emergency physician appropriately diagnose and manage this neoplasm. We report a case of bilateral central retinal vein occlusion (CRVO), acute renal failure, and symptomatic anemia in a man previously undiagnosed with multiple myeloma.

## CASE REPORT

A 42-year-old male presented to the ED, referred by his primary care physician for concern of anemia and vision changes. Over the previous two weeks, blurred vision to the left eye progressed to solid black centrally with sparing of the peripheral vision. Over the previous five days he also noticed right eye blurred vision. On review of systems, the patient endorsed experiencing occasional floaters and flashes bilaterally and unintentional weight loss of more than 60 pounds in the previous four months. He denied eye pain, headache, jaw claudication, scalp tenderness, fevers, or chills. Past medical history included only hypertension and hyperlipidemia, maintained on nifedipine 30 milligrams (mg) and simvastatin 20 mg daily, as well as strabismus of the left eye. The patient had been recently admitted to the hospital

for symptomatic anemia, was found to have low vitamin B12 and borderline iron levels, had received a transfusion, and was started on ferrous gluconate and cyanocobalamin before being discharged. Social history included non-injection heroin use.

On the exam, he was well-appearing, resting comfortably in bed, in no distress. His vital signs were as follows: 36.6°C; blood pressure 160/87 millimeters of mercury (mm Hg); heart rate 75 beats per minute; respiratory rate 18 breaths per minute; and pulse oximetry 98% on room air. His head, ear, eye, nose and throat exam was notable for mild strabismus of the left eye compared with the right, as well as decreased central vision in the left eye. Fundoscopic exam was notable for significant retinal hemorrhage of the left eye. The remainder of the physical exam was unremarkable. The blood work was significant for a red blood cell count of 2.31 million/microliter (M/ $\mu$ L) (reference range 4.30-5.80 M/ $\mu$ L); hemoglobin of 7.0 grams/deciliter (g/dL) (13-17.5 g/dL); mean corpuscular volume of 104 femtoliters (80-99 femtoliters), platelets of 94/ $\mu$ L (140-390/ $\mu$ L), creatinine of 1.37 mg/dL (0.6-1.3 mg/dL); glucose of 156 mg/dL (65-100 mg/dL); prothrombin time of 17.2 seconds (10.5-13.5 seconds); partial thromboplastin time of 28.7 seconds (24.8-38.4 seconds). Complete blood count differential was notable for absolute plasma cells of 0.1 K/uL, or 3% (0 K/uL), and red blood cell count morphology was notable for rouleaux. Calcium level was 8.9 mg/dL (8.3-10.5 mg/dL).

Given the patient's vision change and findings of retinal hemorrhage noted on ED fundoscopic exam, ophthalmology was consulted. Their exam was notable for visual acuity: 20/60 without correction and 20/40 pinhole on right eye. On the left eye, he was able to count fingers only. His visual fields were full on right eye, full and central scotoma on left eye. Extraocular movements were intact bilaterally, and pupils were equal, round, and reactive bilaterally. Intraocular pressures were 9 mm Hg on the right eye and 7 mm Hg on the left eye (10-21 mm Hg). His slit lamp exam of the eyes bilaterally was notable for clear corneas, absence of conjunctival injection, round and flat irises, and clear lens and vitreous. His dilated fundus exam with 1% tropicamide and 2.5% phenylephrine revealed optic discs with sharp margins, pink rims, and no edema. The macula exam demonstrated possible edema on right and macular edema on left. The vessel exam was significant for diffuse hemorrhages throughout with vascular tortuosity of most vasculature and notable flame hemorrhage inferior to disc in both eyes.

The patient was diagnosed with bilateral central retinal vein occlusions, acute kidney injury, and symptomatic anemia. He received two liters of fluid. Consultation was made to hematology/oncology for presumed diagnosis of multiple myeloma. Due to the absence of other systemic signs or symptoms of hyperviscosity, the decision was made not to start plasmapheresis. Inpatient bone marrow biopsy confirmed the diagnosis of multiple myeloma, and the patient was started on steroids. On follow-up ophthalmology exams, the patient's

### *CPC-EM Capsule*

What do we already know about this clinical entity?

*The appropriate diagnosis of an acute presentation of multiple myeloma is important, as it may result in life-threatening illness and severe morbidity if untreated.*

What makes this presentation of disease reportable?

*We present one of the first case reports of a patient with new onset multiple myeloma presenting to the Emergency Department with bilateral central retinal vein occlusion.*

What is the major learning point?

*The most common cause of central retinal vein occlusion (CRVO) in adults is vascular disease, but in younger adults, conditions of systemic inflammation or hyperviscosity must be considered.*

How might this improve emergency medicine practice?

*Multiple myeloma should be considered in young patients who present to the emergency department with bilateral CRVO.*

vision has maintained at 20/200 bilaterally. He continued to follow up in the hematology/ oncology clinic. He was initially started on bortezomib and methylprednisolone and then daratumumab and hyaluronidase human-fihj were added. At the time of manuscript submission, the patient was a candidate for bone marrow transplant and undergoing workup.

### **DISCUSSION**

To the best of our knowledge, we present the first case in the ED literature of a patient diagnosed with bilateral CRVO as the presenting symptom of multiple myeloma. Central retinal vein occlusion is commonly associated with systemic vascular disease, hypertension and diabetes, and most commonly presents in older patients. In patients younger than 50, CRVO is uncommon, and bilateral presentation warrants investigation into conditions that cause a hyperviscous or inflammatory state.<sup>1,2</sup> Bilateral CRVO in particular is an extremely rare complication of an underlying hyperviscosity state, in which increased serum viscosity can result in vascular obstruction and tissue hypoxia. The hyperviscosity state in multiple myeloma is caused by excessive amounts of circulating immunoglobulins.<sup>3</sup> In the case of multiple myeloma, CRVO is characterized by diffuse retinal hemorrhage and is associated with abnormalities



in the retinal vein, such as engorgement, as well as optic disc swelling and macular edema.<sup>4</sup> Symptoms of CRVO generally include painless changes in visual acuity, which may be sudden or progressive in onset.<sup>5</sup> Additional symptoms associated with hyperviscous states include dyspnea, high output cardiac failure, and even myocardial infarction.

Bilateral CRVO is exceedingly rare, and its presentation has been documented in only a handful of case studies in association with hypercoagulable and hyperviscous states.<sup>6-8</sup> In the rare case of bilateral CRVO, the differential diagnosis should include systemic lupus erythematosus, acute myeloid leukemia, Waldenstrom's macroglobinemia, antiphospholipid antibody syndrome, and dysproteinemias.<sup>9</sup> Multiple myeloma is most commonly diagnosed in the presence of hypercalcemia, renal insufficiency, anemia, and the presence of osteolytic bone lesions on skeletal radiography. However, definitive diagnosis requires bone marrow biopsy.<sup>10</sup>

Management involves an emergent consult to ophthalmology. Several therapies are available for the treatment of CRVO such as anticoagulants, photocoagulation, corticosteroids, and intravitreal injections, and therapy is often guided by an ophthalmologist.<sup>11</sup> Further management of the underlying risk factors or etiology of the CRVO is also important and may require emergency physician referral to specialist care. When a hyperviscous state is deemed to be the etiology, treatment must be considered with supportive therapy such as fluids (as dehydration may worsen hyperviscosity), plasma exchange or plasmapheresis, and chemotherapy.<sup>12</sup> Ultimately, corticosteroids and anti-vascular endothelial growth factor therapy may improve the visual acuity in patients experiencing CRVO. Adjuvant therapy such as retinal photocoagulation and surgical options have limited supporting data.<sup>11</sup>

In the case described above, the patient presented with bilateral CRVO leading to a diagnosis of multiple myeloma, associated with severe symptomatic anemia and acute renal failure.<sup>13,14</sup> Acute presentation of multiple myeloma, therefore, must be considered in patients presenting to the ED with bilateral CRVO.

## CONCLUSION

This is one of the first case reports to document a patient with new onset of multiple myeloma presenting to the ED with bilateral central retinal vein occlusion. The appropriate diagnosis of an acute presentation of multiple myeloma is important, as it may result in life-threatening illness and severe morbidity if left untreated. Multiple myeloma should be considered in young patients who present to the ED with bilateral CRVO. Management includes consultation with ophthalmology and to hematology/oncology, and treatment for hyperviscosity syndrome should be considered.

The authors attest that their institution requires neither Institutional Review Board approval nor patient consent for publication of this

case report. Documentation on file.

**Address for Correspondence:** Kelly Williamson, MD, Associate Professor of Emergency Medicine, Northwestern University Feinberg School of Medicine, Department of Emergency Medicine, 211 E Ontario Street Suite 300, Chicago, IL 60611. Email: Margaret.williamson@northwestern.edu

**Conflicts of Interest:** By the CPC-EM article submission agreement, all authors are required to disclose all affiliations, funding sources and financial or management relationships that could be perceived as potential sources of bias. The authors disclosed none.

**Copyright:** © 2022 Tandlich. This is an open access article distributed in accordance with the terms of the Creative Commons Attribution (CC BY 4.0) License. See: <http://creativecommons.org/licenses/by/4.0/>

## REFERENCES

1. Tomasini DN and Segu B. Systemic considerations in bilateral central retinal vein occlusion. *Optometry*. 2007;78(8):402-8.
2. Fong AC and Schatz H. Central retinal vein occlusion in young adults. *Surv Ophthalmol*. 1993;37(6):393-417.
3. Perez Rogers A and Estes M. Hyperviscosity syndrome. 2022. Available at: <https://www.ncbi.nlm.nih.gov/books/NBK518963/>. Accessed March 20, 2022.
4. McAllister IL. Central retinal vein occlusion: a review. *Clin Exp Ophthalmol*. 2012;40(1):48-58.
5. Oellers P, Hahn P, Fekrat S. (2018). Central retinal vein occlusion. In *Ryan's Retina 1166-1179*. Edinburgh, United Kingdom: Elsevier.
6. Uhr JH, Thau A, Chung C, et al. Rare presentation of bilateral central retinal vein occlusion and leukemic retinopathy in a young adult diagnosed with T-cell acute lymphoblastic leukemia. *Cureus*. 2020;12(1):e6666.
7. Schwartz SG, Hickey M, Puliafito CA. Bilateral CRAO and CRVO from thrombotic thrombocytopenic purpura: OCT findings and treatment with triamcinolone acetonide and bevacizumab. *Ophthalmic Surg Lasers Imaging*. 2006;37(5):420-2.
8. Tóth G, Sándor GL, Reichel C, et al. Bilateral simultaner retinaler zentralvenenverschluss bei Protein-S-Mangel [Bilateral simultaneous central retinal vein occlusion in protein S deficiency]. *Ophthalmologe*. 2015;112(11):929-31.
9. Green WR, Chan CC, Hutchins GM, et al. Central retinal vein occlusion: a prospective histopathologic study of 29 eyes in 28 cases. *Trans Am Ophthalmol Soc*. 1981;79:371-422.
10. Albagoush SA, Shumway C, Azevedo AM. Multiple myeloma. 2022. Available at: <https://www.ncbi.nlm.nih.gov/books/NBK534764/>. Accessed March 20, 2022.
11. Patel A, Nguyen C, Lu S. Central retinal vein occlusion: a review of current evidence-based treatment options. *Middle East Afr J Ophthalmol*. 2016;23(1):44-8.

12. Perez Rogers A and Estes M. Hyperviscosity syndrome. 2022. Available at: <https://www.ncbi.nlm.nih.gov/books/NBK518963/>. Accessed November 15, 2021.
13. Golesic EA and Sheidow TG. An otherwise healthy young man presents with bilateral CRVO as the first sign of hyperviscosity syndrome in the setting of new multiple myeloma. *Retin Cases Brief Rep.* 2015;9(1):38-40.
14. Aggio FB, Cariello AJ, Almeida MS, et al. Bilateral central retinal vein occlusion associated with multiple myeloma. *Ophthalmologica.* 2004;218(4):283-7.

# Hypotension Unresponsive to Fluid Resuscitation: A Case Report

**Mahir Mameledzija, MD, MBA\***  
**Erin Nasrallah, MD†**  
**Molly Hartrich, MD, MPH\***

\*University of Illinois at Chicago, Department of Emergency Medicine, Chicago, Illinois  
†Advocate Lutheran General Hospital, Department of Emergency Medicine, Park Ridge, Illinois

Section Editor: Joel Moll, MD

Submission history: Submitted January 12, 2022; Revision received April 22, 2022; Accepted April 29, 2022

Electronically published July 27, 2022

Full text available through open access at [http://escholarship.org/uc/uciem\\_cpem](http://escholarship.org/uc/uciem_cpem)

DOI: 10.5811/cpcem.2022.4.55896

**Introduction:** Iron deficiency anemia is commonly seen in the emergency department (ED), and the cause can be complex and variable.

**Case Report:** We present a case of a female without known medical history who presented to the ED for generalized weakness and was found to have severe anemia in the setting of chronic lice infestation.

**Conclusion:** Severe and chronic pediculosis can cause chronic blood loss and be an unusual and rare cause of iron deficiency anemia. In the setting of anemia and hypotension unresponsive to fluid resuscitation, consideration should be given to early packed red blood cell transfusion and subsequent investigation of causes of severe anemia. [Clin Pract Cases Emerg Med. 2022;6(3):236–239.]

**Keywords:** *pediculosis; lice infestation; hypotension; anemia; case report.*

---

## INTRODUCTION

Anemia is a condition in which the number of red blood cells (RBC) in a patient's blood are lower than normal and insufficient to meet an individual's physiologic needs.<sup>1</sup> While the etiology of a patient's anemia may be complex and variable given the wide spectrum of conditions causing anemia, the initial workup and management of anemia is quite straightforward.<sup>2</sup> Anemia is caused by bleeding, decreased production of RBCs, as in iron deficiency anemia (IDA), or increased destruction of RBCs, as in sickle cell anemia.

Lice infestation is a common finding among children in North America, with pediculosis capitis (head lice) known to be highly prevalent among the pediatric population.<sup>3</sup> Pediculosis corporis (body lice) is rarer, and despite the prevalence of head lice infestation in the pediatric population, the literature on body lice infestation causing profound anemias is limited to a few case reports. In this case report, we present a patient with profound anemia likely due to chronic lice infestation.

## CASE REPORT

A 50-year-old woman with no known past medical history was brought into the emergency department (ED) by her older sister for evaluation of generalized weakness. Initial history provided by her sister suggested that the patient had not seen a doctor in years, had a history of "psychiatric problems," and had been feeling weak for the prior month or two. The patient's weakness and fatigue had extended to a point where her brother had to carry her around the house. The patient denied any medical problems and denied taking any prescription or over-the-counter medications.

On initial exam, the patient was hypotensive with a systolic blood pressure of 75 millimeters of mercury (mm Hg) and tachycardic to 110 beats per minute on arrival to the ED. The remainder of her vital signs were within normal limits. She had a normal mental status and was breathing comfortably on room air. At the time of evaluation the patient endorsed diffuse and profound weakness without focality for the prior month; the remainder of her review of systems was

unremarkable. She reported she had been eating and drinking normally; however, family noted she would eat only dairy products and pudding.

On exam, she was a thin, ill-appearing person who was disheveled. Except for mild tachycardia, her cardiopulmonary exam was unremarkable. Her abdomen was benign. Her skin was hyperpigmented with multiple, scattered excoriations, and she had innumerable, wingless, dark-colored insects crawling in her hair and all over her body. One of the insects was isolated and inspected. It was noted to have a clear-tan shell with six legs and an elongated oval body, and was identified as a body louse.

While she was able to stand up straight and transfer herself to the exam bed from the wheelchair, according to the patient her weakness was too profound to attempt ambulation. On strength examination, she had diffuse, symmetric, upper and lower extremity weakness in the proximal to distal muscle groups. Apart from her profound weakness, there were no focal neurologic deficits, and the remainder of her exam was unremarkable.

Labs were collected, and an electrocardiogram (ECG) and radiograph were performed. For her hypotension, the patient was provided two liters of normal saline over one hour. Despite 30 cubic centimeters per kilogram of fluid resuscitation, her blood pressure and tachycardia persisted. Her labs were notable for lactic acid of 8.5 millimoles per liter (mmol/L) (reference range 0.5-2.2 mmol/L). There were no severe electrolyte abnormalities. Blood urea nitrogen/creatinine and liver function tests were within normal limits. We considered adrenal insufficiency with Addisonian crisis, especially given her exam finding of hyperpigmented skin, and a random cortisol level was added to her labs; however given normal sodium, potassium, and glucose level, steroids were deferred.

The patient's hemoglobin and hematocrit resulted critically low at 1.6 grams per deciliter (g/dL) (reference range 12.0-15.5 g/dL) and 6.6% (36.0-46.5%), respectively (Table 1). Given concern for error, the complete blood count (CBC) was repeated with similar results. Her white blood cell count was 14.0 thousand cells per cubic microliter (K/ $\mu$ L) (4.2-11.0 K/ $\mu$ L) and platelets were 355 K/ $\mu$ L (140-450 K/ $\mu$ L). A rectal exam was performed without findings of gross blood or melena. Both the patient and her family denied trauma and gastrointestinal or genitourinary blood losses, and she had entered menopause approximately five years previously. Broad spectrum antibiotics were empirically started given concern for sepsis. The patient was subsequently resuscitated with two units of un-crossmatched packed red blood cells (PRBC) given the critical hemoglobin level, while an additional two units of crossmatched PRBCs were prepared in the blood bank.

The patient was quarantined and decontaminated in the ED exam room. Given her relative stability despite a critically low hemoglobin level, a traumatic etiology was thought to be

### *CPC-EM Capsule*

What do we already know about this clinical entity?

*Iron deficiency anemia (IDA) has a wide spectrum of causes, many of which are not formally diagnosed during the patient's stay in the Emergency Department.*

What makes this presentation of disease reportable?

*This case offers important considerations for patients unresponsive to initial crystalloid resuscitation and an uncommon etiology of profound anemia.*

What is the major learning point?

*Severe and chronic pediculosis can cause chronic blood loss, an unusual and rare cause of IDA.*

How might this improve emergency medicine practice?

*Early recognition offers the opportunity for point-of-care testing and earlier transfusion of packed red blood cells or other focused treatments.*

very unlikely, and her hemoglobin had likely dropped slowly over a lengthy period. The patient was subsequently admitted to the medical intensive care unit for further evaluation and management of profound anemia and hypotension.

In total, the patient received four units of PRBCs in the ED and did not require further transfusions during her hospital course. Following the transfusion, her morning hemoglobin was 7.5 grams per deciliter (g/dL) (reference range 12.0-15.5 g/dL) and had a total of five stable hemoglobin levels on daily CBCs thereafter. She had an upper endoscopy and extensive laboratory workup led by hematology/oncology given the degree of her anemia; her subsequent workup did not reveal a source of bleeding, blood dyscrasia, or significant mineral or vitamin deficiency that would have contributed to her anemia. The patient responded very well to the PRBC transfusion, and after pediculosis was resolved her anemia did not return, which led us to believe her anemia was due to slow blood loss by chronic lice infestation.

### **DISCUSSION**

The patient's labs were consistent with IDA. While it was unlikely the IDA was due to acute blood loss, the elevated reticulocyte count indicates that there was ongoing blood loss with appropriate bone marrow compensation. As noted by the family, the patient's diet was exclusively dairy

**Table 1.** Lab results in adult patient with severe body lice infestation.

Lab result	Value	Reference range
White blood cell	14.0 K/mcL	4.2-11.0 K/mcL
Red blood cell	1.0 million/mm <sup>3</sup>	4.00-5.20 million/mm <sup>3</sup>
Hemoglobin	1.6 g/dL	12.0-15.5 g/dL
Hematocrit	6.60%	36.0-46.5%
Mean corpuscular volume	66 fL	78.0-100.0 fL
Mean corpuscular hemoglobin	16 pg	26.0-34.0 pg
Mean corpuscular hemoglobin concentration	24.2 g/L	32.0-36.5 g/L
Red cell distribution width	21.90%	11-15.0%
Platelets	355 K/mcL	140-450 K/mcL
Iron	14 µg/dL	50-170 µg/dL
Iron percent saturation	2%	15%-45%
Total iron binding capacity	496 µg/dL	250-450 µg/dL
Ferritin	4 ng/mL	8-252 ng/mL
Lactate dehydrogenase	346 U/L	82-240 U/L
Reticulocyte count	3.60%	0.3-2.5%

*K/mcL*, thousand cells per microliter; *million/mm<sup>3</sup>*, million per cubic millimeter; *g/dL*, grams per deciliter; *fL*, femtoliters; *pg*, picograms; *µg/dL*, microgram per deciliter; *ng/mL*, nanogram per milliliter; *U/L*, units per liter.

products; consumption of large amounts of cow's milk may lead to IDA. This, however, is typically seen in children, and it is unlikely we would have seen such a profound anemia from heavy consumption of cow's milk. Her lice infestation was impressive, and coupled with poor nutritional status, we concluded that her chronic and severe pediculosis was the most likely cause of her severe anemia. Although lice infestation is encountered with relative frequency in the ED, such a chronic and severe case leading to life-threatening anemia is quite rare. Spurred by this unique case, we reviewed the literature for case reports and studies of profound anemia due to pediculosis.

A review of the literature revealed case reports and one case series of patients with chronic and severe lice infections with profound anemias (Table 2). These were almost always microcytic IDA, with numerous cases requiring blood transfusion. Despite there being no causal or definite relationship between anemia and lice infestation,

**Table 2.** Previously reported cases of pediculosis and anemia.

Author	Patient	Type of infestation	HgB level
Hau and Muhi-Iddin. <sup>6</sup>	11-year-old female	Pediculosis Capitis	4.2 g/dL
Althomali, Alzubaidi and Alkhaldi. <sup>7</sup>	23-year-old female	Pediculosis Capitis	2.2 g/dL
Ronsley et al. <sup>8</sup>	4-year-old male	Pediculosis Capitis + Corporis	2.2 g/dL
Woodruff and Chang. <sup>9</sup>	74-year-old female	Pediculosis Capitis + Corporis	3.8 g/dL
Batool et al. <sup>10</sup>	32-year-old male	Pediculosis Capitis + Corporis	6.3 g/dL
Fustino, Waddell and Panzer. <sup>11</sup>	12-year-old female	Pediculosis Capitis + Corporis	4.7 g/dL

*HgB*, hemoglobin; *g/dL*, gram per deciliter.

there is a theoretical relationship in that heavy infestation can lead to blood loss over the span of months and cause IDA, after other causes of IDA have been ruled out. Authors of a 2006 study published in the *International Journal of Dermatology* attempted to quantify the blood intake of a head louse in children.<sup>4</sup> The authors concluded that heavy, chronic infestation would have a great potential to lead to iron deficiency and could be significant in an already iron-deficient child. In 2011 researchers performed a thorough chart review of ED cases and highlighted a possible association between lice infestation and profound IDA.<sup>5</sup> While not pertinent to our patient, communicable diseases transmitted by lice such as epidemic typhus, trench fever, and epidemic relapsing fever are important considerations when treating patients with lice infestation as well as for medical staff safety. We found six individual case reports from 2015–2021 reporting lice infestation and associated anemia (Table 2).

Reports given by our patient's family of her severe deconditioning and poor diet and hygiene suggested the possibility that her baseline hemoglobin was low and the infestation had worsened her anemia. It remained unclear how long she had been severely infested with lice and the trajectory of her weakness. Her hyperpigmented skin may have suggested adrenal insufficiency, particularly considering the initial refractory hypotension; however, her labs were not consistent with adrenal insufficiency and her inpatient workup did not reveal adrenal insufficiency. A skin condition associated with chronic body lice infestation, pediculosis corporis (also known as "vagabond's disease") demonstrates thickened and darkened skin similar to that of our patient.

## CONCLUSION

Despite the limited literature on the hematologic consequences of chronic lice infestation, this case offers important considerations for unknown etiologies of profound anemia and also for patients unresponsive to initial crystalloid resuscitation. In cases where a patient may be severely ill and there is lag time for labs to result, this may offer the opportunity for point-of-care testing and allow for earlier transfusion of packed red blood cells or other focused treatments. To our knowledge, the vast majority of the literature discussing severe iron deficiency anemia due to pediculosis has been in reference to IDA in young children and animals. This case report illustrates an important cause of IDA in older adults, especially those who are vulnerable and do not regularly interact with the medical community.

Documented patient informed consent and/or Institutional Review Board approval has been obtained and filed for publication of this case report.

---

*Address for Correspondence:* Mahir Mameledzija MD, MBA, University of Illinois at Chicago, Department of Emergency Medicine, 808 South Wood Street, 471 CMET MC 724, Chicago, IL 60612. Email: mmamel2@uic.edu.

*Conflicts of Interest:* By the CPC-EM article submission agreement, all authors are required to disclose all affiliations, funding sources and financial or management relationships that could be perceived as potential sources of bias. The authors disclosed none.

*Copyright:* © 2022 Mameledzija et al. This is an open access article distributed in accordance with the terms of the Creative Commons Attribution (CC BY 4.0) License. See: <http://creativecommons.org/licenses/by/4.0/>

---

## REFERENCES

1. World Health Organization. Haemoglobin concentrations for the diagnosis of anaemia and assessment of severity. 2011. Available at: <https://apps.who.int/iris/handle/10665/85839>. Accessed February 28, 2021.
2. Goldman L and Schafer AI. (2019). Approach to the anemias. *Goldman-Cecil Medicine, 2-Volume Set*. 26th ed. Philadelphia, Pennsylvania: Elsevier.
3. Centers for Disease Control and Prevention. Parasites—lice. 2013. Available at: [www.cdc.gov/parasites/lice/index.html](http://www.cdc.gov/parasites/lice/index.html). Accessed February 28, 2021.
4. Speare R, Canyon DV, Melrose W. Quantification of blood intake of the head louse: pediculus humanus capitis. *Int J Dermatol*. 2006;45(5):543-6.
5. Guss DA, Koenig M, Castillo EM. Severe iron deficiency anemia and lice infestation. *J Emerg Med*. 2011;41(4):362-5.
6. Hau V and Muhi-Iddin N. A ghost covered in lice: a case of severe blood loss with long-standing heavy pediculosis capitis infestation. *BMJ Case Rep*. 2014;2014:bcr2014206623.
7. Althomali SA, Alzubaidi LM, Alkhaldi DM. Severe iron deficiency anaemia associated with heavy lice infestation in a young woman. *BMJ Case Rep*. 2015;2015:bcr2015212207.
8. Ronsley R, Ling F, Rehmus W, Dmytryshyn A. Lice infestation causing severe anemia in a 4-year-old child. *Can Fam Physician*. 2019;65(7):473-5.
9. Woodruff CM and Chang AY. More than skin deep: severe iron deficiency anemia and eosinophilia associated with pediculosis capitis and corporis infestation. *JAAD Case Rep*. 2019;5(5):444-7.
10. Batool N, Song D, Reyes JVM, et al. Ectoparasitosis, a rare cause of severe iron deficiency anemia: a case report. *Ann Med Surg (Lond)*. 2021;69:102784.
11. Fustino NJ, Waddell JP, Panzer ZR. A 12-year-old girl with chronic pediculosis infestation presenting with severe iron deficiency anemia. *J Pediatr Hematol Oncol*. 2022;44(3):e804-6.

## When a Headache Is More than the Flu: A Case Report

Abigail E. Russ, DO  
Amber M. Morse, MD  
David M. Spiro, MD, MPH

University of Arkansas for Medical Sciences, Arkansas Children's Hospital,  
Department of Pediatric Emergency Medicine, Little Rock, Arkansas

Section Editor: Jacqueline Le, MD

Submission History: Submitted February 18, 2022; Revision received June 21, 2022; Accepted June 24, 2022

Electronically published August 8, 2022

Full text available through open access at [http://escholarship.org/uc/uciem\\_cpem](http://escholarship.org/uc/uciem_cpem)

DOI: 10.5811/cpcem2022.6.56491

**Introduction:** When influenza (flu) season arrives, it is easy for emergency department clinicians to anchor on the diagnosis of flu, sending patients on their way with or without anti-influenza medication. It is important not to miss the outlier – the patient who seems to have typical symptoms of influenza but with certain subtleties that should make one consider expanding the differential diagnosis.

**Case Report:** We describe an 11-year-old previously healthy male who presented with eight days of fever, myalgias, cough, congestion, and headache in the context of positive influenza exposure. The length and severity of his symptoms prompted laboratory and imaging investigation. He was positive for influenza type B with elevated inflammatory markers but otherwise normal laboratory workup and normal chest radiograph. He complained of a headache and was given fluids and antipyretics, and was admitted for overnight observation. He specifically did not have any forehead swelling. The next day during his inpatient stay he developed right frontal forehead edema and appeared ill. He was taken for a sinus computed tomography, which showed changes consistent with frontal bone osteomyelitis. Even after drainage by neurosurgery and otolaryngology, the patient subsequently developed repeat abscesses and ultimately a superior sagittal sinus thrombosis.

**Conclusion:** Other sources of infection should be considered in patients who have flu-like symptoms that last longer than expected, present with focality, or appear ill. [Clin Pract Cases Emerg Med. 2022;6(3):240–243.]

**Keywords:** *Pott's puffy tumor; frontal bone osteomyelitis; influenza; case report; sinusitis.*

### INTRODUCTION

When influenza (flu) season arrives, it is easy for clinicians in the emergency department (ED) to anchor on the diagnosis of flu, sending patients on their way with or without anti-influenza medication. It is important not to miss the outlier – the patient who seems to have typical symptoms of influenza but with certain subtleties that should make one consider expanding the differential diagnosis.

### CASE REPORT

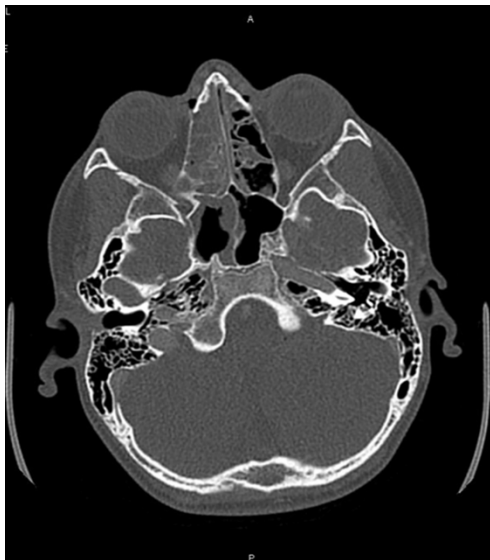A previously healthy 11-year-old male presented to an urban pediatric ED complaining of fever, rhinorrhea, congestion, cough, myalgias, and headache. His mother,

father, and brothers had all been diagnosed with flu over the prior several days and had recovered within three to four days. The patient had a negative influenza test at an urgent care center. He had not received the current flu vaccine but otherwise was fully vaccinated. He had daily fevers, up to 104° Fahrenheit, for eight days prior to evaluation in the ED, with worsening rhinorrhea and an intermittent frontal headache. He had received antipyretics but no other medications. His physical exam was significant for a pale, thin, and ill-appearing male. He had tenderness to palpation of his right and middle forehead without overlying swelling or discoloration. He had full range of motion of his neck, dry mucus membranes, tonsil stones present in the oropharynx,

normal heart and lung findings, and no neurological abnormalities, specifically no ataxia, meningismus, peripheral nerve deficits, or cranial nerve deficits.

Our differential diagnosis at the time included an atypical presentation of influenza, mononucleosis infection, sinusitis, migraine, Kawasaki disease, dehydration, and sepsis. His neurological exam did not make us suspicious for meningitis. He had no joint or bony pain or swelling that led us to include a joint infection or osteomyelitis in our differential diagnosis. He was given an antipyretic for fever and a fluid bolus for borderline tachycardia and dehydration. Laboratory workup was significant for a negative rapid influenza test but a positive respiratory pathogen polymerase chain reaction test for influenza B. His C-reactive protein was elevated at 102.0 milligrams per deciliter (mg/dL) (reference range: 0.0-9.9 mg/dL). Blood and urine cultures were obtained. A complete blood count, comprehensive metabolic panel, urinalysis, rapid streptococcus test, ferritin, anti-streptolysin O titer, and Monospot test were all within normal limits. A chest radiograph showed no abnormalities. An electrocardiogram showed normal sinus rhythm. Given his length of fever, ill appearance and elevated inflammatory markers, he was admitted for overnight observation and intravenous fluids. Antibiotics were not started secondary to a lack of nidus for bacterial infection.

He continued to be febrile overnight. The next morning, he was febrile, tachycardic, and more ill-appearing with headache and pronounced swelling over the right-middle forehead. A sinus computed tomography with contrast (Image 1) was obtained and demonstrated a midline frontal empyema displacing and narrowing the superior sagittal sinus over a segment measuring nine centimeters (cm). The empyema measured 1 cm in thickness. A subperiosteal abscess was



**Image 1.** Computed tomography of our patient showing right ethmoid (white arrow) and maxillary (white arrowhead) sinusitis with enhancement demonstrating abscess formation (arrow).

### *CPC-EM Capsule*

What do we already know about this clinical entity?

*We know frontal bone osteomyelitis (i.e. Pott's puffy tumor) is a rare occurrence in children and is usually a complication of sinusitis, trauma, acute otitis media, or insect stings.*

What makes this presentation of disease reportable?

*Very rarely has frontal bone osteomyelitis occurred in conjunction with influenza infection.*

What is the major learning point?

*The most common symptoms of frontal bone osteomyelitis are headache and fever, which are also two common influenza symptoms. It is important to consider other diagnoses in a patient with viral disease or illness.*

How might this improve emergency medicine practice?

*Consideration of other disease processes will lead to prompt recognition and management of a serious disease that can have dire neurological complications if left untreated.*

seen in the left frontal region with surrounding phlegmonous changes of the scalp. Although no obvious lytic lesions were seen within the calvarium, the presence of subperiosteal abscess and intracranial empyema was concerning for frontal bone osteomyelitis, also described in the literature as Pott's puffy tumor. Additionally, acute sinus disease involving bilateral frontal, right ethmoid, right sphenoid, and right maxillary sinus was seen.

The patient was taken to the operating room (OR) by both neurosurgery and otolaryngology for a right frontal craniotomy for evacuation of the abscesses and a functional endoscopic sinus surgery with septoplasty. After surgery, he was taken to the pediatric intensive care unit (PICU) for overnight monitoring and broad-spectrum antibiotics were initiated including ceftriaxone, vancomycin, and metronidazole. A brain magnetic resonance image (MRI) was obtained postoperatively that showed post-surgical changes, resolution of the abscesses, and no further evidence of osteomyelitis. Wound cultures from the intracranial abscesses grew *Streptococcus anginosus* that was sensitive to ceftriaxone and metronidazole. He had a peripherally inserted central catheter placed and was discharged home after eight days of hospitalization on IV ceftriaxone and oral metronidazole for six weeks of outpatient



antimicrobial therapy.

After discharge home, he returned to the ED two days later with slowed speech, difficulty finding his words, ataxia, and headache. A brain MRI with contrast was ordered and showed right frontal bone osteomyelitis with abscesses overlying the right frontal bone and an anterior superior sagittal sinus thrombosis (Image 2). He was taken to the OR by neurosurgery for drainage of the subcutaneous, epidural, and subperiosteal abscesses, and a subgaleal drain was placed. He was transferred postoperatively to the PICU for anticoagulation, anti-seizure prophylaxis, and monitoring. His wound cultures did not grow any bacteria or fungus. He was discharged home and continued ceftriaxone and metronidazole and enoxaparin injections. At his subsequent follow-up visits, he continued to have no further complications and has made a full neurological recovery.

## DISCUSSION

The description of Pott's puffy tumor was first penned by Sir Percivall Pott in the mid-1700s.<sup>1</sup> The "tumor" refers to the forehead edema that occurs as a reaction to the underlying frontal bony infection. The infection may be isolated to the bone (ie, osteomyelitis) or may create an abscess in the subcutaneous tissue or brain. The most common cause of the tumor is extension of sinusitis into the frontal bone; however, although rare, trauma, acute otitis media, and insect stings have also been implicated.<sup>2,4</sup>

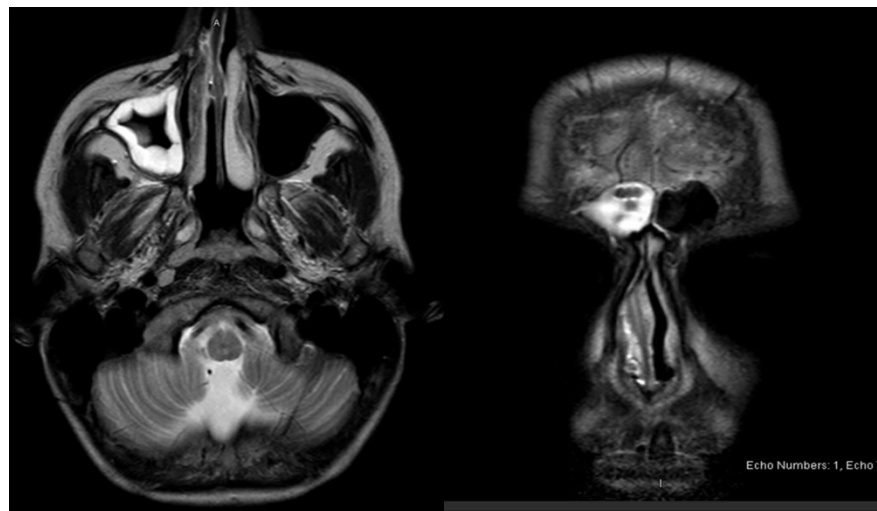The most common bacteria associated with this process is the *Streptococcus anginosus* group, which includes *Streptococcus anginosus*, *Streptococcus intermedius*, and *Streptococcus constellatus*.<sup>2</sup> Polymicrobial infections have also been described in the literature, most commonly a combination of anaerobic bacteria and *Staphylococcus aureus*.<sup>1</sup> *S. anginosus* has been implicated in infections throughout the body as it is a member of the body's natural flora, primarily in the mouth and

the gastrointestinal tract. *S. anginosus* can cause life-threatening head and neck abscesses as well as septic thrombi in the brain and must be taken seriously.<sup>3</sup>

The majority of patients reported throughout the literature over the last 40 years were teenagers who presented with headache, fever, and scalp swelling. Depending on the extent of the abscess, patients may present with neurological deficits such as aphasia, cranial nerve deficit, and hemiplegia, although these seem to be infrequent complications.<sup>1</sup> Given the intimately adjoining anatomy of bone, dura, and vasculature of the frontal sinus, infection can spread quickly, invading the brain and not only causing abscesses, meningitis, and bacteremia but also septic thrombi, leading to microvascular damage, strokes, and other severe neurologic sequelae. As in our patient, septic thrombi can form and remain subclinical in nature, only diagnosed on angiography, thus emphasizing the importance of obtaining vascular imaging from the first diagnostic scan.

Antimicrobial management alone is inadequate for treatment of these intracranial abscesses. If no abscess is present, one could argue that antimicrobial management with close observation for abscess formation may be adequate. However, for definitive management, neurosurgical intervention is required. Some patients have required a bone flap and multiple visits to the OR, as seen in our patient.

The association between influenza and Pott's puffy tumor has been described in one other case series by Foster et al in 2019. Their report describes six patients with head and neck infections with influenza co-infection. One of these patients was a 12-year-old male with influenza who on day four of illness developed left eye pain with left eye swelling and left forehead swelling. He was diagnosed with sinusitis, Pott's puffy tumor, and orbital cellulitis. He was taken to the OR for endoscopic sinus surgery. Cultures grew *S. anginosus* group, *Streptococcus mitis*, *Peptostreptococcus*, and *Prevotella*. He was treated with ceftriaxone and metronidazole for five weeks. This patient was



**Image 2.** Brain magnetic resonance imaging with contrast of our patient. A) Demonstrates significant mucosal thickening of the maxillary sinus (arrow) consistent with recurrent sinusitis. B) Demonstrates return of right frontal osteomyelitis (arrow).

readmitted two weeks after discharge for vomiting and postnasal drip and did not have any reported neurological dysfunction.<sup>5</sup>

## CONCLUSION

Although rare, given its potential for serious neurological complications, Pott's puffy tumor should be considered in the differential diagnosis for all patients with headache, fever, facial pain, and/or facial swelling. These symptoms may be consistent with the diagnosis of influenza but should not lead a diagnostician down the path of excluding other diagnoses, as co-infection is possible. The most common cause of Pott's puffy tumor is sinusitis, although the absence of sinusitis does not exclude the diagnosis. Influenza may predispose a patient to subsequent bacterial infections as seen in our patient. This case demonstrates the need for clinicians to consider other diagnoses in the context of a definitive diagnosis of influenza.

The authors attest that their institution requires neither Institutional Review Board approval nor patient consent for publication of this case report. Documentation on file.

*Address for Correspondence:* Abigail E. Russ, DO, University of Colorado Anschutz Medical Campus, Department of Pediatric Emergency Medicine, 13121 E 17th Ave Mail Stop 8410, Aurora, CO 80045. Email: [abigail.russ@cuanschutz.edu](mailto:abigail.russ@cuanschutz.edu).

*Conflicts of Interest:* By the CPC-EM article submission agreement, all authors are required to disclose all affiliations, funding sources and financial or management relationships that

could be perceived as potential sources of bias. The authors disclosed none.

*Copyright:* © 2022 Russ et al. This is an open access article distributed in accordance with the terms of the Creative Commons Attribution (CC BY 4.0) License. See: <http://creativecommons.org/licenses/by/4.0/>

## REFERENCES

1. Bambakidis NC and Cohen AR. Intracranial complications of frontal sinusitis in children: Pott's puffy tumor revisited. *Pediatr Neurosurg*. 2001;35(2):82-9.
2. McNeil JC, Dunn JJ, Kaplan SL, Vallejo JG. Complications of otitis media and sinusitis caused by *Streptococcus anginosus* group organisms in children. *Pediatr Infect Dis J*. 2020;39(2):108-13.
3. Stratton C and Sexton DI. Infections due to the *Streptococcus anginosus* (*Streptococcus milleri*) group. 2018. Available at: [https://www.uptodate.com/contents/infections-due-to-the-streptococcus-anginosus-streptococcus-milleri-group?search=3.%09%20Infections%20due%20to%20the%20Streptococcus%20anginosus%20\(Streptococcus%20milleri\)%20group.&source=search\\_result&selectedTitle=1~150&usage\\_type=default&display\\_rank=1](https://www.uptodate.com/contents/infections-due-to-the-streptococcus-anginosus-streptococcus-milleri-group?search=3.%09%20Infections%20due%20to%20the%20Streptococcus%20anginosus%20(Streptococcus%20milleri)%20group.&source=search_result&selectedTitle=1~150&usage_type=default&display_rank=1). Accessed April 19, 2020.
4. Sharma P, Sharma S, Gupta N, et al. Pott puffy tumor. *Proc (Bayl Univ Med Cent)*. 2017;30(2):179-81.
5. Foster CE and Kaplan SL. Complicated head and neck infections following influenza virus infection in children. *Pediatr Infect Dis J*. 2019;38(9):e226-8.

## Delayed Recognition of Severe Systemic Envenomation after Copperhead Bite: A Case Report

Patrick E. Kelly, MD  
Charles J. Gerardo, MD, MHS

Duke University Hospital, Department of Surgery, Durham, North Carolina

Section Editor: Steven Walsh, MD

Submission History: Submitted March 1, 2022; Revision received June 10, 2022; Accepted June 16, 2022

Electronically published August 8, 2022

Full text available through open access at [http://escholarship.org/uc/uciem\\_cpchem](http://escholarship.org/uc/uciem_cpchem)

DOI: 10.5811/cpcem2022.6.56592

**Introduction:** We report a case of severe systemic copperhead, *Agkistrodon contortrix*, envenomation that resulted in long-term sequelae.

**Case Report:** A 72-year-old man presented to the emergency department after suffering a copperhead snakebite. He developed severe systemic toxicity before local tissue injury developed. Clinicians did not initially recognize his envenomation syndrome and sought alternative explanations for his systemic symptoms before polyvalent immune fab (ovine) antivenom was administered. Although the patient improved, he was discharged with new stage three chronic kidney disease.

**Conclusion:** Although rare, copperhead envenomation can cause severe systemic toxicity. Envenomation should be promptly treated with antivenom. [Clin Pract Cases Emerg Med. 2022;6(3):244–247.]

**Keywords:** case report; snakebite; copperhead; *Agkistrodon contortrix*; antivenin.

### INTRODUCTION

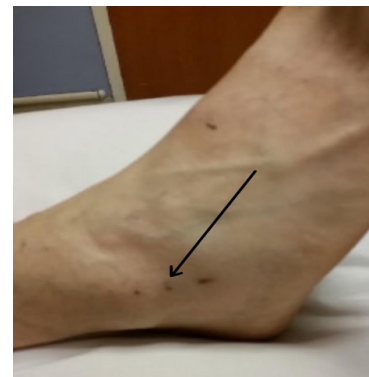The Crotalinae subfamily of snakes is responsible for 98% of the nearly 9,000 venomous bites in the United States per year.<sup>1,2</sup> Envenomation can present with systemic toxicity, hemotoxicity, and venom-induced tissue injury. Patients bitten by the species *Agkistrodon contortrix* (copperheads) rarely develop severe systemic envenomation, and some authors have discouraged antivenom administration.<sup>3,4</sup> We report a case in which this did occur and diagnosis as well as treatment were delayed to due to an atypical presentation for this species.

### CASE REPORT

A 72-year-old man with a history of hypertension treated with amlodipine and lisinopril presented to the emergency department (ED) within 30 minutes of copperhead snakebite to the right lateral ankle. A physician with expertise in snakebite and local snake identification verified the species by a photo of the offending snake. Initial vital signs were a temperature 36.7°C, heart rate 100 beats per minute (bpm), respiratory rate 19 breaths per minute, blood pressure 144/74 millimeters of mercury (mm Hg), and oxygen saturation 95%

on room air. Examination revealed puncture wounds (Image) without surrounding erythema, edema, or tenderness. The triage physician felt that the patient had suffered a dry bite and placed him in a room for further evaluation.

The patient then told his treating physician that he had also experienced chest tightness, shortness of breath,



**Image.** Lateral foot and ankle upon presentation demonstrating puncture wounds (arrow) from a copperhead snakebite without associated local tissue injury.

abdominal pain, and anxiety after the bite. Two hours after arrival to the ED, he developed nausea with repeated vomiting and diarrhea. He became lightheaded and lost consciousness in front of his wife. His physicians were called to the room. He was confused, and his vital signs were unstable with sinus bradycardia (heart rate 44 bpm), hypotension (blood pressure 74/52 millimeters of mercury), and tachypnea (respiratory rate 29 breaths per minute). In the absence of apparent local tissue injury, the treating physicians did not attribute the shock state to the snakebite due to the snake species and continued lack of soft tissue injury. They instead pursued an evaluation of alternative diagnoses including vasovagal syncope, arrhythmogenic syncope, cardiac ischemia, hypovolemia, and electrolyte abnormalities while providing supportive care.

One liter of normal saline and atropine 0.5 milligrams (mg) were administered with increase in the heart rate to 68 bpm. However, the patient remained relatively hypotensive (blood pressure ranging from 84-123/54-67 mm Hg) compared to his baseline (blood pressure 138-164/68-74 mm Hg). Electrocardiogram (ECG) showed new submillimeter ST-segment elevations in the anterior precordial leads. Serial troponin T measurements were added to the initial laboratory evaluation and resulted at 0.01 nanograms/milliliter (ng/mL) (reference range:  $\leq$  0.10 ng/mL) at both time zero and 12 hours. A consulting cardiologist attributed the dynamic ECG changes to a stress response in the setting of presumed vasovagal syncope. The initial laboratory evaluation collected at the time of patient arrival to the ED was remarkable for a creatine evaluation to 1.4 milligrams per deciliter (mg/dL) (reference range: 0.6 to 1.3 mg/dL) from 1.1 mg/dL just one month earlier. Platelets were marginally elevated at  $523 \times 10^9$  per liter [L]. Activated partial thromboplastin time was negligibly low at 25.5 seconds (26.8-37.1 seconds). Prothrombin time was 11.8 seconds (9.5-13.1 seconds), fibrinogen was 334 mg/dL (275 mg/dL), and creatine kinase was 86 units/L (U/L) (30-220 U/L).

The patient received an additional three liters of normal saline resuscitation. He was then observed to have developed ecchymosis, edema, and tenderness nine hours after the time of the initial snakebite. His symptoms were then attributed to envenomation, and crotaline polyvalent immune fab (ovine) antivenom (FabAV) was ordered. Initial control was achieved with six vials. His systemic symptoms and relative hypotension resolved, his blood pressure remained at his baseline afterward, and the leading edge of his tissue edema stopped progressing (Figure). Pain and swelling extended to just below the knee at its worst, and creatinine peaked at 2.0 mg/dL. Five additional two-vial doses of FabAV were administered to maintain control of his local tissue findings. In total, 16 vials of FabAV were administered.

After 51 hours from presentation, he was discharged with vitals that approximated his pre-envenomation baseline, an improving exam, and a downtrending creatinine. On long-term follow-up, his new baseline creatinine was 1.3-1.5 mg/dL

### *CPC-EM Capsule*

What do we already know about this clinical entity?

*Although rare, copperhead envenomation can cause severe systemic toxicity. Envenomation should be promptly treated with antivenom.*

What makes this presentation of disease reportable?

*We present a case of severe systemic envenomation where diagnosis was delayed and the patient developed stage three chronic kidney disease.*

What is the major learning point?

*Copperhead snakebites can cause severe systemic envenomation even in the absence of early local tissue injury.*

How might this improve emergency medicine practice?

*Early treatment requires prompt diagnosis and emergency physicians should be aware that systemic toxicity can precede or occur in the absence of local tissue injury.*

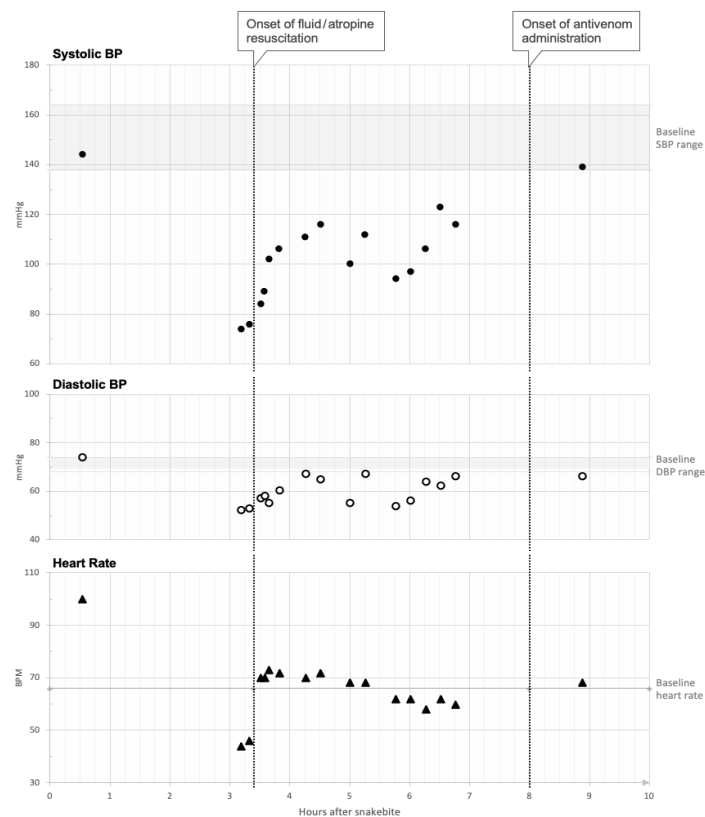
consistent with stage three chronic kidney disease.

## DISCUSSION

Pit viper snakebites are the most common venomous snakebites in the US.<sup>1</sup> Copperhead snakes are less likely to cause severe envenomation syndromes than rattlesnakes, and nearly all symptomatic cases eventually develop signs of local tissue injury.<sup>5-7</sup> However, clinicians must still recognize that these trends are not universal, and overt bleeding, systemic toxicity, and even death have been reported with copperhead snakebite.<sup>2,8</sup>

The clinical presentation of snakebite is widely variable because venom is composed of a complex mixture of proteins and peptides that exert symptoms across multiple organ systems. The venom effects are often grouped into local tissue injury, hematologic, cardiovascular, neurologic, gastrointestinal, and pulmonary venom toxicity domains.<sup>9</sup> Severity does not correlate strongly between domains and the presence of venom effects within one domain cannot be used to predict another.<sup>9</sup> Our patient presented with early systemic symptoms that culminated in hemodynamic instability and syncope despite normal coagulation studies and only isolated fang marks to the affected extremity.

This patient met criteria for antivenom therapy early in his ED visit according to the unified treatment algorithm for



**Figure.** Visual display of the patient's hemodynamic response to different treatment modalities measured over time. Baseline characteristics (systolic blood pressure, diastolic blood pressure, and heart rate) are depicted with horizontal lines for reference. Onset and type of medical intervention are labeled with vertical, dotted lines.

*BP*, blood pressure; *SBP*, systolic blood pressure; *DBP*, diastolic blood pressure; *mmHg*, millimeters of mercury; *BPM*, beats per minute.

management of crotaline snakebite.<sup>10</sup> He did not receive early antivenom therapy because of a delay in the diagnosis of his envenomation syndrome. After discussion with the physicians providing care to this patient, the absence of erythema, edema, and pain upon his arrival played a role in this delay. However, even in the initial absence of local tissue signs, this patient's chest tightness, shortness of breath, and abdominal pain should have been recognized as early systemic symptoms.

Snake species biased the treating clinicians who did not recognize that toxicity in one venom effect domain does not predict toxicity in another.<sup>9</sup> They were falsely reassured that copperhead snakebites rarely cause severe systemic envenomation based on previously published case series where no hypotensive events were documented.<sup>4,11</sup> Some authors have used this observation to recommend against routine use of antivenom in copperhead snakebites.<sup>4</sup> This approach neglects the rare, severe systemic envenomation syndromes that have been described in the literature, resulting in shock requiring antivenom therapy.<sup>12</sup>

Time from envenomation to treatment greater than six hours increases the likelihood of severe systemic toxicity in other pit viper envenomations.<sup>5</sup> In copperhead snakebite specifically, later treatment results in longer times to recovery.<sup>13</sup> Our patient was treated with only fluids and atropine and not FabAV for nine hours after the snakebite. He remained relatively hypotensive until receiving standard-of-care therapy with FabAV, at which point his clinical course began to improve. He was left with stage three chronic kidney disease as a potentially preventable complication.

We hypothesize that this patient's kidney injury was the result of prolonged hypotension. His fractional excretion of sodium was calculated at the time of his worst documented renal function and found to be 0.1%, making prerenal pathology most likely. Direct and immune-complex nephrotoxicity cannot be entirely excluded. However, he did not have evidence of acute tubular necrosis or microscopic hematuria, and pigment nephropathy seems highly unlikely in the absence of rhabdomyolysis or consumptive coagulopathy.

Well-established cognitive errors led to delays in diagnosis and treatment in this case.<sup>14, 15, 16</sup> The clinicians became anchored to an incorrect diagnosis through triage cueing and diagnostic momentum.<sup>14</sup> Their judgment fell victim to representative restraint as this rare case did not comprise all features of severe toxicity across multiple domains.<sup>14</sup> Prevalence perception played a role as it is uncommon for copperhead snakebites to result in severe systemic toxicity.<sup>15</sup> These classic cognitive errors resulted in a delayed diagnosis and consequently delayed antivenom treatment. Earlier empiric antivenom was further delayed due to omission bias and the focus on nonmaleficence.<sup>14</sup>

The exact etiology of such severe systemic findings in a copperhead envenomation patient, given that most patients have mild or no systemic symptoms, is not clear. The cause may have been specific to this individual snake's venom, although that degree of within-species venom variation would be extreme. There may have been patient-specific factors that caused his symptoms, such as comorbidities like his chronic hypertension or other undiagnosed cardiovascular disease. There may have also been a patient-specific inflammatory response leading to a cascade of downstream cardiovascular sequelae, which has been demonstrated in other pit viper snakebites.<sup>17</sup> In all likelihood, the presentation was multifactorial and included several of the possibilities described. The possibility of the patient having a mild envenomation and a concurrent, severe, unrelated cardiovascular event at the same time does not seem plausible. Since his severe symptoms preceded Fab AV administration, we conclude that this was not an adverse reaction to the medication.

## CONCLUSION

Although copperhead snakes are less likely to cause severe envenomation than are rattlesnakes, this case highlights an important example of a severe systemic toxicity

with delayed diagnosis and treatment, and a long-term complication. Per existing guidelines, all pit viper snakebites should be observed at a minimum, and antivenom treatment initiated once venom effects progress regardless of venom effect domain.<sup>10</sup>

The authors attest that their institution requires neither Institutional Review Board approval nor patient consent for publication of this case report. Documentation on file.

---

*Address for Correspondence:* Patrick E. Kelly, MD, Duke University Hospital, Department of Surgery, DUMC Box 3096, Durham, NC, 27701. Email: patrick.kelly@duke.edu.

*Conflicts of Interest:* By the CPC-EM article submission agreement, all authors are required to disclose all affiliations, funding sources and financial or management relationships that could be perceived as potential sources of bias. The authors disclosed none.

*Copyright:* © 2022 Kelly et al. This is an open access article distributed in accordance with the terms of the Creative Commons Attribution (CC BY 4.0) License. See: <http://creativecommons.org/licenses/by/4.0/>

---

## REFERENCES

- Gummin DD, Mowry JB, Spyker DA, et al. 2016 annual report of the American Association of Poison Control Centers' National Poison Data System (NPDS): 34th annual report. *Clin Toxicol (Phila)*. 2017;55(10):1072-1254.
- Greene SC, Folt J, Wyatt K, et al. Epidemiology of fatal snakebites in the United States 1989-2018. *Am J Emerg Med*. 2021;45:309-16.
- Gale SC, Peters JA, Allen L, et al. FabAV antivenin use after copperhead snakebite: clinically indicated or knee-jerk reaction? *J Venom Anim Toxins Inc Trop Dis*. 2016;22:2.
- Walker JP and Morrison RL. Current management of copperhead snakebite. *J Am Coll Surg*. 2011;212(4):470-5.
- Gerardo CJ, Vissoci JRN, Evans CS, et al. Does this patient have a severe snake envenomation? The rational clinical examination systematic review. *JAMA Surg*. 2019;154(4):346-54.
- Gerardo CJ, Vissoci JRN, Brown MWJ, et al. Coagulation parameters in copperhead compared to other Crotalinae envenomation: secondary analysis of the F(Ab')<sub>2</sub> versus Fab antivenom trial. *Clin Toxicol (Phila)*. 2017;55(2):109-14.
- Ruha AM, Kleinschmidt KC, Greene S, et al. The epidemiology, clinical course, and management of snakebites in the North American Snakebite Registry. *J Med Toxicol*. 2017;13(4):309-20.
- Thorson A, Lavonas EJ, Rouse AM, et al. Copperhead envenomations in the Carolinas. *J Toxicol Clin Toxicol*. 2003;41(1):29-35.
- Dart RC, Hurlbut KM, Garcia R, et al. Validation of a severity score for the assessment of crotalid snakebite. *Ann Emerg Med*. 1996;27(3):321-6.
- Lavonas EJ, Ruha AM, Banner W, et al. Unified treatment algorithm for the management of crotaline snakebite in the United States: results of an evidence-informed consensus workshop. *BMC Emerg Med*. 2011;11:2.
- Lavonas EJ, Gerardo CJ, O'Malley G, et al. Initial experience with Crotalidae polyvalent immune Fab (ovine) antivenom in the treatment of copperhead snakebite. *Ann Emerg Med*. 2004;43(2):200-6.
- Zad O, Cooper H, Crocker P, et al. Shock, respiratory failure, and coagulopathy after an intravenous copperhead envenomation. *Am J Emerg Med*. 2009;27(3):377.e1-377.e5.
- Anderson VE, Gerardo CJ, Rapp-Olson M, et al. Early administration of Fab antivenom resulted in faster limb recovery in copperhead snake envenomation patients. *Clin Toxicol (Phila)*. 2019;57(1):25-30.
- Croskerry P. The importance of cognitive errors in diagnosis and strategies to minimize them. *Acad Med*. 2003;78(8):775-80.
- Campbell SG, Croskerry P, Bond WF. Profiles in patient safety: a "perfect storm" in the emergency department. *Acad Emerg Med*. 2007;14(8):743-9.
- Graber ML, Franklin N, Gordon R. Diagnostic error in internal medicine. *Arch Intern Med*. 2005;165(13):1493-9.
- Gutiérrez JM, Escalante T, Rucavado A. Experimental pathophysiology of systemic alterations induced by Bothrops asper snake venom. *Toxicon*. 2009;54(7):976-87.

# Real-time Ultrasound-Guided Manual Testicular Detorsion: A Case Report

Wilson T. Smith, MD\*  
Stephanie Midgley, MD\*  
Tobias Kummer, MD†

\*Vassar Brothers Medical Center, Department of Emergency Medicine, Poughkeepsie,  
New York

†Mayo Clinic, Department of Emergency Medicine, Rochester, Minnesota

Section Editor: Melanie Heniff, MD, JD

Submission History: Submitted April 28, 2022; Revision received May 25, 2022; Accepted June 29, 2022

Electronically published August 8, 2022

Full text available through open access at [http://escholarship.org/uc/uciem\\_cpem](http://escholarship.org/uc/uciem_cpem)

DOI: 10.5811/cpcem2022.6.57256

**Introduction:** Acute testicular torsion is a surgical emergency due to acute testicular ischemia. Manual testicular detorsion is a testis-saving, bedside therapeutic when performed correctly and in a timely fashion. This procedure is most commonly performed blindly with pain relief as the endpoint for detorsion. However, up to one-third of patients continued to show signs of residual torsion in the operating room even using pain relief as the stopping point for the procedure.

**Case Report:** We present a case demonstrating the utility of color Doppler ultrasound to confirm complete manual detorsion in a 14-year-old male with acute testicular torsion. The patient underwent 360-degree detorsion and had relief of pain; however, color Doppler demonstrated incomplete return of flow to the testis. After an additional 180-degree turn was made, color Doppler demonstrated complete return of normal vascular flow to the torsed testis.

**Conclusion:** When it comes to testicular viability, timely restoration of blood flow to the testicle is of utmost importance. Manual detorsion is a non-invasive intervention that can be quickly and effectively performed at the bedside. Moreover, using color Doppler ultrasound guidance can ensure that physicians detorse in the proper direction and to completion, by providing instant visualization of restorative flow and ensuring reperfusion of the testis while awaiting definitive surgical management. [Clin Pract Cases Emerg Med. 2022;6(3):248–251.]

**Keywords:** *testicular torsion; detorsion; ultrasound; color Doppler; case report.*

## INTRODUCTION

The estimated yearly incidence of testicular torsion in males under the age of 18 presenting to the emergency department (ED) is 3.8 per 100,000.<sup>1</sup> Testicular torsion is a urological emergency due to the negative effect of prolonged ischemia on testicular function and viability. For every 10-minute delay in the ED, the chance of having a viable testis decreases 4.8%.<sup>4</sup> Within four hours of symptom onset, the torsed testis begins to atrophy, resulting in lower sperm counts and potential infertility. Moreover, long-term semen analysis may only be normal in up to 50% of these patients.<sup>3</sup> As the time to detorsion increases, the viability of the testis decreases. Due to current coronavirus 2019 pandemic

challenges, prompt surgical treatment may be delayed, making manual detorsion even more critical. Manual detorsion in the ED is a manipulative technique that can restore blood flow and preserve the long-term viability of the testis and provide dramatic pain relief.

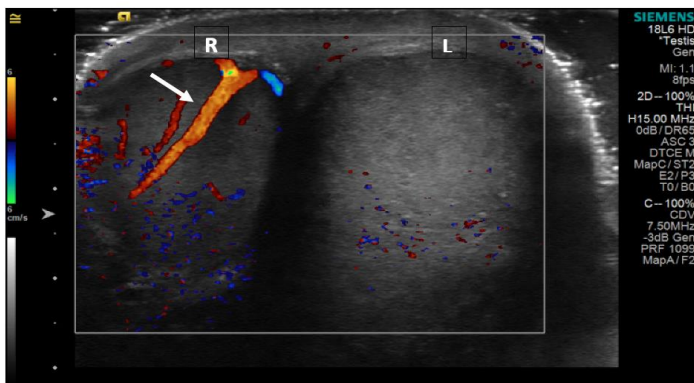
Manual testicular detorsion is a bedside procedure taught to emergency care practitioners and performed blindly. Conventional emergency medicine teaching dictates that torsions occur in the lateral-to-medial direction and, therefore, detorsion should be performed in the medial-to-lateral or “open-book” fashion until pain relief.<sup>5</sup> Although this is true for most cases, Sessions et al found that as many as 30% of testicular torsions require lateral-to-medial

manipulation to successfully detorse.<sup>6</sup> Additionally, residual torsion was discovered in the operating room (OR) in as many as one-third of cases in which a patient had undergone blind manual detorsion using pain resolution as the determinant to stop detorsing.<sup>6</sup>

With as little as 180 degrees of torsion causing testicular infarct,<sup>6</sup> ensuring complete detorsion while awaiting surgical correction is of the utmost importance. Color Doppler ultrasound (CDU), which is used to confirm the diagnosis of testicular torsion, has also been reported to guide detorsion.<sup>9,10</sup> By using CDU to visualize the return of vascular flow, it can demonstrate that the direction of detorsion is correct and confirm complete detorsion while awaiting definite surgical intervention. This technique can be used in real time by assessing vascular flow after each rotation or by assessing flow at the end of the procedure. There have been no studies comparing blind manual detorsion vs CDU guided, but futures studies may determine that CDU-guided detorsion is a superior method to ensuring complete detorsion.

### CASE REPORT

A 14-year-old male presented to the ED with vomiting and sudden onset of left testicular pain, waking him up from sleep approximately two hours prior. The patient denied experiencing trauma, fever, chills, diarrhea, or difficulty urinating. Physical examination revealed a high-riding left testicle and absent left-sided cremasteric reflex without erythema or swelling. Scrotal ultrasound was performed in the radiology ultrasound suite using both color Doppler and spectral Doppler. Both testes had normal echotexture and appeared to be of the same size. Arterial and venous waveforms were identified in the right testis but were absent on the left (Image 1).



**Image 1.** Testicular ultrasound before detorsion shows normal flow to the right testicle (R) as indicated by the white arrow and absent flow to the left (L) testicle.

In the ultrasound suite, with the aid of the ultrasound technician, the emergency physician manually detorsed the left testicle by turning it from medial to lateral and

### CPC-EM Capsule

What do we already know about this clinical entity?

*Testicular torsion is a surgical emergency and manual testicular detorsion, when performed correctly, is a testis-saving bedside therapeutic.*

What makes this presentation of disease reportable?

*Color Doppler ultrasound detorsion guidance was performed with the aid of an ultrasound technician to confirm complete testicular detorsion with reperfusion.*

What is the major learning point?

*Color Doppler ultrasound guidance can be used to guide manual testicular detorsion for correct direction and confirm complete detorsion.*

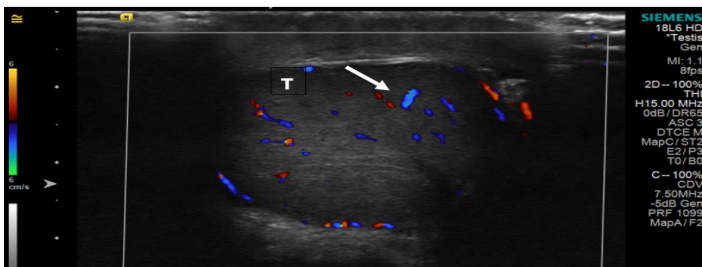
How might this improve emergency medicine practice?

*Color Doppler ultrasound guided testicular detorsion can be performed both as a point-of-care ultrasound procedure or performed with an ultrasound technician.*

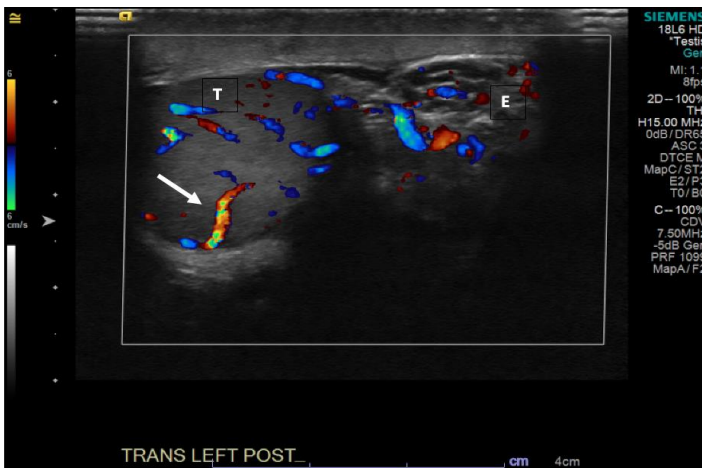
re-evaluated for return of flow with CDU after each 180-degree turn. After the first 180-degree rotation, the patient's pain did not begin to decrease, bringing into question torsion directionality. Color Doppler ultrasound demonstrated a small increase in vascular flow to the left testis, suggesting the correct detorsion direction but the need for further rotations. An additional 180-degree rotation was performed, resulting in a marked decrease in pain; however, repeat CDU showed no improvement in flow. Given the continued paucity of vascular flow to the left testis when compared to the right (Image 2) there was concern for only partial detorsion; thus, a third 180-degree rotation (540° total) was performed, which brought additional pain relief, and CDU showed return of normal vascular flow to the left testis (Image 3).

The on-call urologist then brought the patient to the OR for bilateral testicular orchiopexy. During surgery, the left testicle was delivered from the left hemiscrotum and was noted to be completely detorsed, pink, and viable. There were no surgical complications, and the patient was discharged that day.





**Image 2.** Left testicle (T) after two medial-to-lateral rotations (360 degrees) shows improved flow as indicated by the white arrow, but still reduced flow.



**Image 3.** Left testicle (T) and epididymis (E) after three complete clockwise rotations of the left testicle (540 degrees) with the white arrow indicating restoration of normal flow to the affected testis.

## DISCUSSION

Testicular torsion accounts for up to 25% of pediatric cases of acute scrotal pain.<sup>7</sup> Color Doppler ultrasound is useful in both diagnosing and treating testicular torsion. In a comprehensive literature review, Chen and Esler found that CDU had a diagnostic sensitivity of 91.9% and specificity of 98.9% when confirmed with surgical findings.<sup>7</sup> Once the diagnosis of torsion has been made, and manual detorsion is attempted, the direction and degree of rotations must be determined. However, there is a lack of studies assessing the use of real-time ultrasound for guidance during detorsion attempts.

Conventional teaching dictates that to detorse a testis, it should be manually rotated in a medial-to-lateral direction.<sup>5</sup> However, data of 200 testicular torsions confirmed by surgical findings collected over 20 years showed that only two-thirds of the time was the testis torsed medially.<sup>6</sup> One study by Hosokawa showed that the directionality of testicular torsion can be better identified with CDU. In that study, CDU correctly predicted directionality 78.6% of the time.<sup>8</sup> The key finding was the so-called “whirlpool sign,” a spiral twist of the spermatic cord to the extent that its patency is decreased or completely occluded.<sup>11</sup>

Once the direction of detorsion has been determined, the next step is to determine the number of rotations to be made when attempting manual testicular detorsion. Rotations can be performed in 180-degree increments using CDU to assess for the restoration of vascular flow after each turn. Although pain resolution has been associated with testicular reperfusion, residual torsion was discovered in the OR in as many as one-third of cases in which a patient had undergone manual detorsion without the use of ultrasound.<sup>6</sup> With as little as 180 degrees of torsion causing testicular infarct,<sup>6</sup> using real-time CDU guidance becomes even more prudent to ensure complete detorsion while waiting for definitive surgical treatment.

## CONCLUSION

When it comes to testicular viability, timely restoration of blood flow to the testicle is of utmost importance. Manual detorsion is a non-invasive intervention that can be quickly and effectively performed at the bedside. Moreover, using CDU guidance can ensure that physicians detorse in the proper direction and to completion, by providing instant visualization of restorative flow and ensuring reperfusion of the testis while awaiting definitive surgical management. Prior case reports demonstrate CDU guidance as a viable point-of-care US (POCUS) procedure.<sup>9,13</sup> However, the cases were performed by more experienced ultrasound-fellowship trained emergency physicians. Testicular ultrasound is an advanced clinical ultrasound application, requiring additional training beyond residency. Many emergency physicians have not had additional ultrasound training, which limits their ability to perform POCUS-guided detorsion. This case demonstrates that CDU detorsion guidance can be successfully performed with the aid of an ultrasound technician. This allows emergency physicians without additional POCUS training the benefit of using this technique for guiding their manual detorsion.

The authors attest that their institution does not require Institutional Review Board approval. Patient consent has been obtained and filed for the publication of this case report. Documentation on file.

*Address for Correspondence:* Stephanie Midgley, MD, Vassar Brothers Medical Center, Department of Emergency Medicine, 45 Reade Place, Poughkeepsie, NY 12601. Email: stephanie.midgley@nuvancehealth.org.

*Conflicts of Interest:* By the CPC-EM article submission agreement, all authors are required to disclose all affiliations, funding sources and financial or management relationships that could be perceived as potential sources of bias. The authors disclosed none.

*Copyright:* © 2022 Smith et al. This is an open access article distributed in accordance with the terms of the Creative Commons Attribution (CC BY 4.0) License. See: <http://creativecommons.org/licenses/by/4.0/>

## REFERENCES

1. Zhao LC, Lautz TB, Meeks JJ, et al. Pediatric testicular torsion epidemiology using a national database: incidence, risk of orchiectomy and possible measures toward improving the quality of care. *J Urol*. 2011;186(5):2009-13.
2. Romeo C, Impellizzeri P, Arrigo T, et al. Late hormonal function after testicular torsion. *J Pediatr Surg*. 2010;45(2):411-3.
3. Visser AJ and Heyns CF. Testicular function after torsion of the spermatic cord. *BJU Int*. 2003;92(3):200-3.
4. Gold DD, Lorber A, Levine H, et al. Door to detorsion time determines testicular survival. *Urology*. 2019;133:211-15.
5. Budhram G. (2017) Male genital problems. In: Cydulka RK, Fitch MT, Joing SA, Wang VJ, Cline DM, Ma O. eds. *Tintinalli's Emergency Medicine Manual*, 8e. McGraw Hill; 2017. Available at <https://accessemergencymedicine.mhmedical.com/content.aspx?sectionid=109433740&bookid=1658>. Accessed June 17, 2022.
6. Sessions AE, Rabinowitz R, Hulbert WC, et al. Testicular torsion: direction, degree, duration and disinformation. *J Urol*. 2003;169:663-5.
7. Chen M and Esler R, Accuracy and delay of using ultrasound in testicular torsion. *J Urol Surg*, 2019;6(4):273-7.
8. Hosokawa T, Takahashi H, Tanami Y, et al. Diagnostic accuracy of ultrasound for the directionality of testicular rotation and the degree of spermatic cord twist in pediatric patients with testicular torsion. *J Ultrasound Med*. 2020;39(1):119-26
9. Bomann JS and Moore C. Bedside ultrasound of a painful testicle: before and after manual detorsion by an emergency physician. *Acad Emerg Med*. 2009;16(4):366.
10. Güneş M, Umul M, Çelik AO, et al. A novel approach for manual detorsion of an atypical (outward) testicular torsion with bedside Doppler ultrasonography guidance. *Can Urol Assoc J*. 2015;9(9-10):E676-8.
11. Vijayaraghavan SB. Sonographic differential diagnosis of acute scrotum: real-time whirlpool sign, a key sign of torsion. *J Ultrasound Med*. 2006;25(5):563-74
12. Cannon ML, Finger MJ, Bulas DI. Manual testicular detorsion aided by color Doppler ultrasonography. *J Ultrasound Med*, 1995;14:407-9.
13. Manivel V and Mirmiran B. Ultrasound-guided manual testicular detorsion in the emergency department. *J Emerg Med*. 2019;S0736-4679(19)30803-0.

# Nail Gun Injury of the Trachea and Spinal Cord

Kohei Shibahashi, MD  
Kenji Numata, MD, MPH

St. Marianna University School of Medicine, Department of Emergency and Critical Care Medicine, Kawasaki, Japan

Section Editor: Austin Smith, MD

Submission History: Submitted February 10, 2022; Revision received March 17, 2022; Accepted March 17, 2022

Electronically published July 27, 2022

Full text available through open access at [http://escholarship.org/uc/uciem\\_cpccem](http://escholarship.org/uc/uciem_cpccem)

DOI: 10.5811/cpcem.2022.3.56410

**Introduction:** A 26-year-old man was impaled by a nail after a nail gun accident. He was fully conscious with weakness and loss of sensation in the extremities. Cervical computed tomography showed a 9-centimeter long nail penetrating the spinal cord. The nail was removed surgically six hours after the incident. Neurological deficits gradually improved, and at three-month follow-up the patient had completely recovered from muscle weakness and reported only mild sensory deficits in the bilateral sole of his foot.

**Discussion:** This case showed a favorable neurological course, which may be attributed to the fact that the cervical spinal cord injury did not involve the corticospinal tracts and anterior horn. [Clin Pract Cases Emerg Med. 2022;6(3):252-253.]

**Keywords:** *spinal cord injury; orthopedic; neurology; nail gun injury; emergency medicine.*

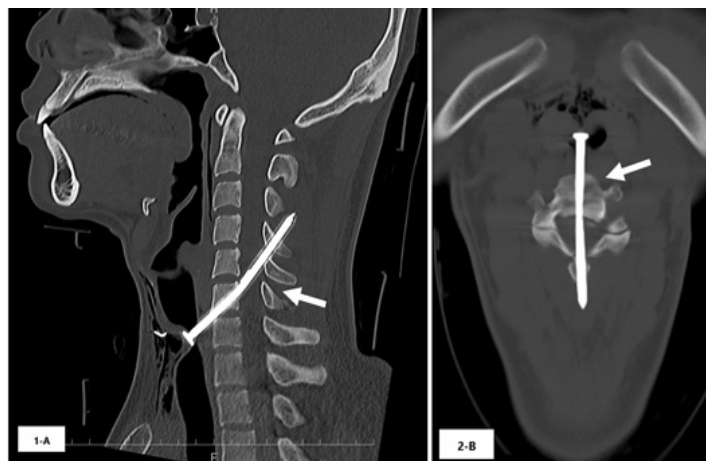## INTRODUCTION

The trachea and spinal cord of a 26-year-old man were penetrated by a nail after he slipped while using a nail gun and accidentally shot a nail into his neck. A 5-millimeter hole was found under the laryngeal ridge. His airway, breathing, and circulation were sustained. He was fully conscious with weakness in the extremities (manual muscle test scores of both upper and lower extremities were 3), and decreased sensation below the xiphoid level, as well as bladder and rectal disturbance. Cervical computed tomography showed a 9-centimeter nail penetrating the trachea, anterior vertebral body, and spinal cord (Image 1).

Because the nail had penetrated the trachea, a tracheotomy was performed by an otolaryngologist while the patient was conscious. The nail was removed under general anesthesia six hours after the incident by an orthopedic surgeon. His neurological deficits gradually improved, and at three-month follow-up he had completely recovered from muscle weakness and reported only mild sensory deficits of the bilateral sole of his foot.

## DISCUSSION

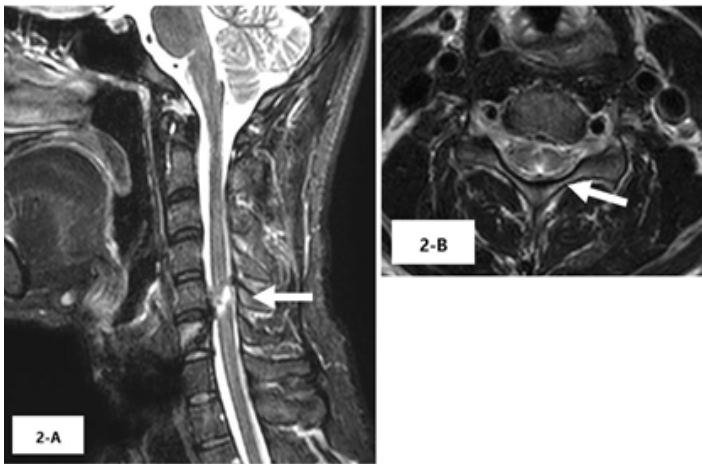
The mechanism of injury in a patient with traumatic spinal



**Image 1.** Cervical computed tomography showing a 9-centimeter nail penetrating the trachea, anterior vertebral body, and spinal cord (arrows).

cord injury can be divided into two major categories: blunt spinal cord injury (BSCI), and penetrating spinal cord injury (PSCI). Outcomes for patients with PSCI remain relatively

understudied. However, Roach et al reported that PSCI results in poorer neurological and functional outcomes than BSCI, and only 19.6% patients with PSCI undergo spinal cord surgery (vs 80.6% for those with BSCI).<sup>1</sup> They reported that this discrepancy may reflect the uncertainty of neurological benefits of surgery for patients with PSCI due to the lack of evidence for surgical treatment in this population. The present case showed a good neurological course. Postsurgical cervical magnetic resonance imaging revealed high T2 signal intensity at the posteromedial region of the sixth cervical level (Image 2).



**Image 2.** Postsurgical cervical magnetic resonance imaging showing high T2 signal intensity at the posteromedial region of the sixth cervical level, without any evidence of corticospinal tract damage (arrows).

Lateral corticospinal tracts and anterior horn are located on the sides of spinal cord. In our case, the good neurological course was believed to be attributed to the penetration of the nail to the center of the spinal cord; the cervical spinal cord injury did not involve the corticospinal tracts and anterior horn.<sup>2</sup> We considered that the nail penetrated the gracile fasciculus because this anatomic feature is at the center of the spinal cord. Therefore, the patient's sensory disturbance was localized to his legs.

Documented patient informed consent and/or Institutional Review Board approval has been obtained and filed for publication of this case report.

*Address for Correspondence:* Kenji Numata, MD, St. Marianna University School of Medicine, Department of Emergency and Critical Care Medicine, 2 Chome-16-1 Sugao, Miyamae Ward, Kawasaki, Kangawa 216-8511, Japan. Email: kenjinumata777@hotmail.co.jp

### *CPC-EM Capsule*

What do we already know about this clinical entity?

*Traumatic spinal cord injury results in poor neurological and functional outcomes; only 19.6% of patients with penetrating spinal cord injury undergo spinal surgery.*

What is the major impact of the image(s)?

*These images of a 9-centimeter long nail that penetrated the patient's spinal cord and resulted in muscle weakness suggest a poor neurological outcome.*

How might this improve emergency medicine practice?

*Non-involvement of the corticospinal tracts and anterior horn in penetrating spinal cord injuries may be a predictor of favorable neurological course following surgery.*

**Conflicts of Interest:** By the CPC-EM article submission agreement, all authors are required to disclose all affiliations, funding sources and financial or management relationships that could be perceived as potential sources of bias. The authors disclosed none.

**Copyright:** © 2022 Shibahashi. This is an open access article distributed in accordance with the terms of the Creative Commons Attribution (CC BY 4.0) License. See: <http://creativecommons.org/licenses/by/4.0/>

### REFERENCES

1. Roach MJ, Chen Y, Kelly ML. Comparing blunt and penetrating trauma in spinal cord injury: analysis of long-term functional and neurological outcomes. *Top Spinal Cord Inj Rehabil.* 2018; 24: 121-32.
2. Fix, JD. (2009). Tracts of the Spinal Cord. In A. Taylor & B. Squazzo (Eds.), *High-Yield Neuroanatomy* (58-64). Maryland: Lippincott Williams & Wilkins.

## Evolving Paralysis after Motor Vehicle Collision

Nicole Prendergast, MD  
Youyou Duanmu, MD, MPH

Stanford University School of Medicine, Department of Emergency Medicine, Palo Alto, California

Section Editor: Rachel Lindor, MD, JD

Submission History: Submitted November 4, 2021; Revision received March 17, 2022; Accepted March 20, 2022

Electronically published July 27, 2022

Full text available through open access at [http://escholarship.org/uc/uciem\\_cpccem](http://escholarship.org/uc/uciem_cpccem)

DOI: 10.5811/cpcem2022.3.51179

**Case Presentation:** An 85-year-old male who had been prescribed prasugrel presented to the emergency department (ED) after a motor vehicle collision and developed progressive neurological deficits. Computed tomography imaging demonstrated epidural thickening from the second through seventh cervical vertebrae, and magnetic resonance imaging was notable for a cervicothoracic epidural hematoma. The patient underwent emergent decompression with a favorable outcome.

**Discussion:** Cases of traumatic spinal epidural hematomas are rarely seen in the ED. These are part of a small subset of operative neurological emergencies that benefit from urgent surgical intervention. [Clin Pract Cases Emerg Med. 2022;6(3):254-255.]

**Keywords:** *images; trauma; spinal epidural hematoma; operative neurological emergencies.*

### CASE PRESENTATION

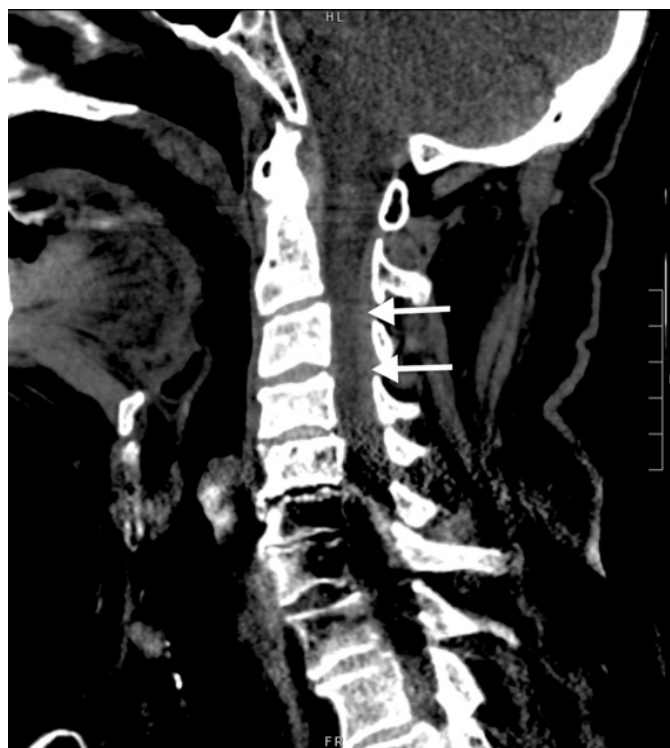An 85-year-old male presented to the emergency department (ED) after a motor vehicle accident with abdominal pain, neck pain, and stool incontinence. The patient's medication list included prasugrel, but it was unclear whether he was taking it. Exam was notable for cervical and thoracic spine tenderness, decreased rectal tone, decreased bilateral upper extremity sensation, and mild weakness of the right lower extremity. Cervical spine computed tomography (CT) demonstrated dorsal epidural thickening from the second through seventh cervical vertebrae (Image 1).

On reassessment, the patient had loss of sensation below the seventh thoracic dermatome and markedly diminished bilateral lower extremity strength and reflexes concerning for ascending paralysis due to spinal cord compression. Magnetic resonance imaging (MRI) of the complete spine showed a cervicothoracic epidural hematoma (Image 2).

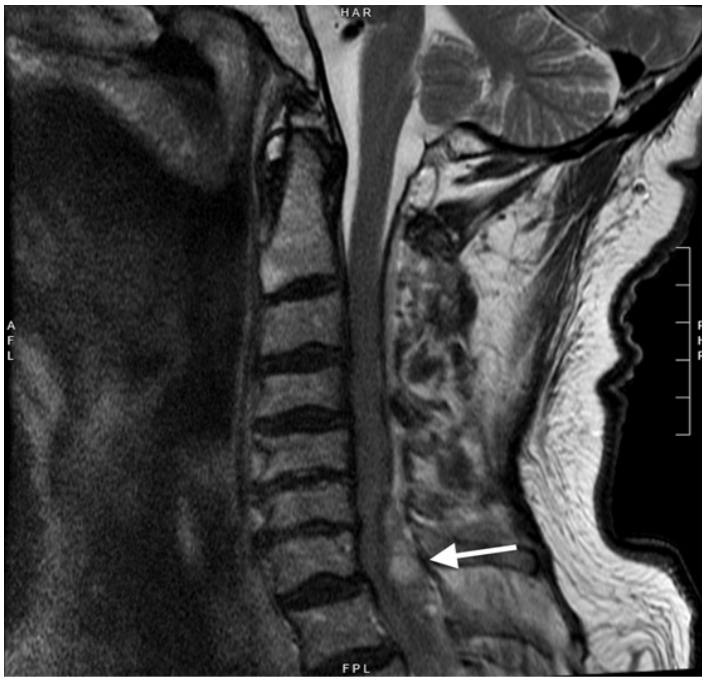
Orthopedic spine surgery performed emergent decompression, and the patient experienced rapid postoperative improvement in strength and sensation.

### DISCUSSION

A spinal epidural hematoma is a collection of blood between the spinal canal dura and vertebrae.<sup>1</sup> Spinal epidural hematomas can lead to permanent neurological deficit or



**Image 1.** Sagittal non-contrast computed tomography of the cervical spine showing hyperdense dorsal epidural thickening (arrows) from second through seventh cervical vertebrae.



**Image 2.** Sagittal T2-weighted, non-contrast magnetic resonance imaging of the cervical spine showing hyperintense dorsal epidural hematoma with cord compression most pronounced at the seventh cervical vertebra (arrow).

death and, therefore, are a surgical emergency.<sup>2</sup> Occurring in 1 per 1,000,000 annually, the cause is most commonly idiopathic (29.7%) followed by anticoagulation and vascular disorders.<sup>2</sup> Those caused by trauma are rare (9.8%) and can be associated with minor injury.<sup>1,2</sup> Symptoms involve radiating back or neck pain followed by neurological deficits consistent with evolving spinal cord compression including numbness, paresis, and loss of bowel or bladder function.<sup>2,3</sup>

Given the non-specific clinical findings, spinal epidural hematomas are challenging to diagnose.<sup>1</sup> Non-contrast CT may show an epidural bleed as a hyperdense mass. An MRI with contrast (preferred if active extravasation or other spine pathology is suspected) or without contrast is the study of choice given the ability to estimate the location, size, and severity of compression.<sup>2</sup> In the ED, medical management with dexamethasone and anticoagulant reversal, when indicated, can be initiated.<sup>4</sup> In patients with neurologic deficits, the definitive treatment is urgent surgical decompression, with operative intervention occurring under 12 hours of deficit onset associated with improved outcomes.<sup>2,4,5</sup>

Documented patient informed consent and/or Institutional Review Board approval has been obtained and filed for publication of this case report.

*Address for Correspondence:* Nicole Prendergast, MD, Stanford University Medical Center, Department of Emergency Medicine, 900 Welch Road, Suite 350, Palo Alto, CA 94304. Email: nprender@stanford.edu

### *CPC-EM Capsule*

What do we already know about this clinical entity?

*A spinal epidural hematoma is a collection of blood between the spinal canal dura and vertebra that presents as back or neck pain with progressive neurological deficits.*

What is the major impact of the image(s)?

*Cases of traumatic spinal epidural hematomas are part of a small subset of neurological emergencies that benefit from early recognition and surgical intervention.*

How might this improve emergency medicine practice?

*Correlation of presentation with computed tomography and magnetic resonance imaging is essential to diagnose spinal epidural hematomas.*

**Conflicts of Interest:** By the CPC-EM article submission agreement, all authors are required to disclose all affiliations, funding sources and financial or management relationships that could be perceived as potential sources of bias. The authors disclosed none.

**Copyright:** © 2022 Prendergast et al. This is an open access article distributed in accordance with the terms of the Creative Commons Attribution (CC BY 4.0) License. See: <http://creativecommons.org/licenses/by/4.0/>

### REFERENCES

1. Ricart P, Verma R, Fineberg S, et al. Post-traumatic cervical spine epidural hematoma: Incidence and risk factors. *Injury*. 2017;48(11):2529–33.
2. Kreppel D, Antoniadis G, Seeling W. Spinal hematoma: a literature survey with meta-analysis of 613 patients. *Neurosurg Rev*. 2003;26(1):1-49.
3. Buyukkaya R, Aydin O, Hakyemez B, et al. Rapid spontaneous recovery after development of a spinal epidural hematoma: a case report. *Am J Emerg Med*. 2014;32(3):291.
4. Kim T, Lee CH, Hyun SJ, et al. Clinical outcomes of spontaneous spinal epidural hematoma: a comparative study between conservative and surgical treatment. *J Korean Neurosurg Soc*. 2012;52(6):523-7.
5. Lawton MT, Porter RW, Heiserman JE, et al. Surgical management of spinal epidural hematoma: relationship between surgical timing and neurological outcome. *J Neurosurg*. 1995;83(1):1-7.

## A Strange Twist

Annete O'Connell, MD\*  
Rodrigo Kong, MD\*  
Rohan Biswas, MD†  
Josh Greenstein, MD\*  
Barry Hahn, MD\*

\*Staten Island University Hospital, Department of Emergency Medicine, Staten Island, NY  
†Staten Island University Hospital, Department of Radiology, Staten Island, NY

Section Editor: Melanie Heniff, MD

Submission history: Submitted February 02, 2022; Revision received March 09, 2022; Accepted April 07, 2022

Electronically published July 27, 2022

Full text available through open access at [http://escholarship.org/uc/uciem\\_cpem](http://escholarship.org/uc/uciem_cpem)

DOI: 10.5811/cpem.2022.4.56344

**Case Presentation:** A 16-year-old female presented to the emergency department with acute onset of right lower quadrant abdominal pain for several hours. The patient was afebrile and physical examination was notable for isolated tenderness in the right lower quadrant. Ultrasound and computed tomography demonstrated an adnexal cystic structure. Pelvic magnetic resonance imaging was ordered to better characterize the pathology.

**Discussion:** Isolated fallopian tube torsion is an uncommon entity requiring prompt surgical intervention. Recognition and appropriate management are essential. [Clin Pract Cases Emerg Med. 2022;6(3):256–258.]

**Keywords:** *fallopian tube; pelvic pain; torsion.*

### CASE PRESENTATION

A 16-year-old nulliparous, sexually active female with a history of type 2 diabetes mellitus presented to the emergency department with acute onset of non-radiating right lower quadrant pain and tenderness to palpation for several hours. She reported nausea but denied fever, vomiting, diarrhea, anorexia, urinary symptoms or vaginal discharge. Vital signs were blood pressure 135/77 millimeters mercury (mmHg), heart rate 103 beats per minute, and temperature 37.2°C. Physical examination was significant for tenderness to palpation in the right lower abdomen without peritoneal signs. A pelvic examination was unremarkable. Urine pregnancy was negative. Pelvic ultrasound demonstrated an 8 x 8 x 5 centimeter (cm) right adnexal cystic structure, normal-sized ovaries without edema, and normal Doppler flow (Image 1).

This finding prompted computed tomography (CT) with intravenous contrast to delineate the pathology further. Computed tomography revealed a large cystic structure within the pelvis, distinct from the right ovary (Image 2).

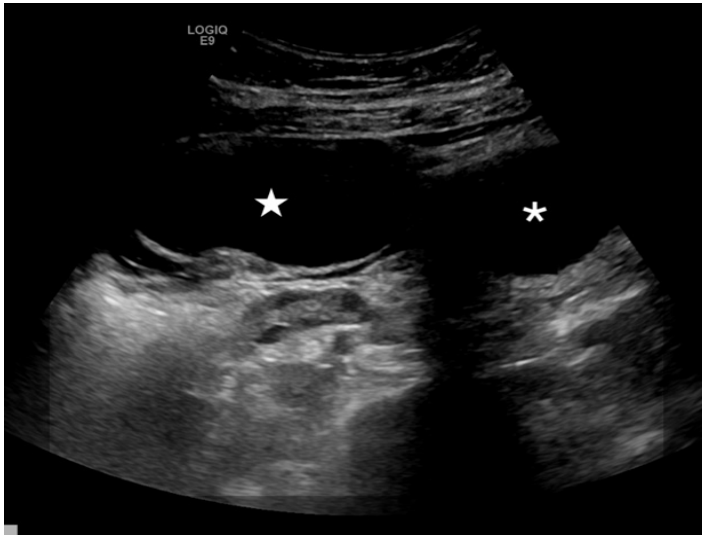
Emergent pelvic magnetic resonance imaging (MRI) with and without intravenous contrast was subsequently ordered to better characterize the masses (Image 3).

### DISCUSSION

Isolated fallopian tube torsion (IFTT) is the rotation of the fallopian tube on itself or around its ligamentous supporting structures. This process is uncommon and typically co-occurs with torsion of the ovary, which is termed adnexal or tubo-ovarian torsion. The reported incidence of IFTT ranges from 1:500,000 to 1:1,500,000, without a defined predilection to a specific age group.<sup>1</sup> Proposed risk factors for IFTT include pathology of the fallopian tube, endometriosis, and adhesions.<sup>1,2</sup>

Patients typically report sudden onset of sharp lower abdominal pain, nausea and vomiting, and localized tenderness.<sup>3</sup> Differential diagnoses include ovarian torsion, adnexal torsion, ectopic pregnancy, ruptured cyst, tubo-ovarian abscess, and appendicitis. Patients have ipsilateral hydrosalpinx or para-ovarian cysts.<sup>1,3-4</sup> Para-ovarian, or paratubal cysts, are encapsulated, fluid-filled sacs that form near an ovary or fallopian tube but do not adhere to any internal organ.

Pelvic ultrasound is the initial imaging method for evaluating most gynecological pathology. Sonographic findings of IFTT include fallopian tube dilation with wall



**Image 1.** Transabdominal ultrasound image obtained with a curvilinear 5-megahertz transducer demonstrates a 7-centimeter cystic mass (star) in the right adnexa near midline, adjacent to the bladder (asterisk).

### *CPC-EM Capsule*

What do we already know about this clinical entity?

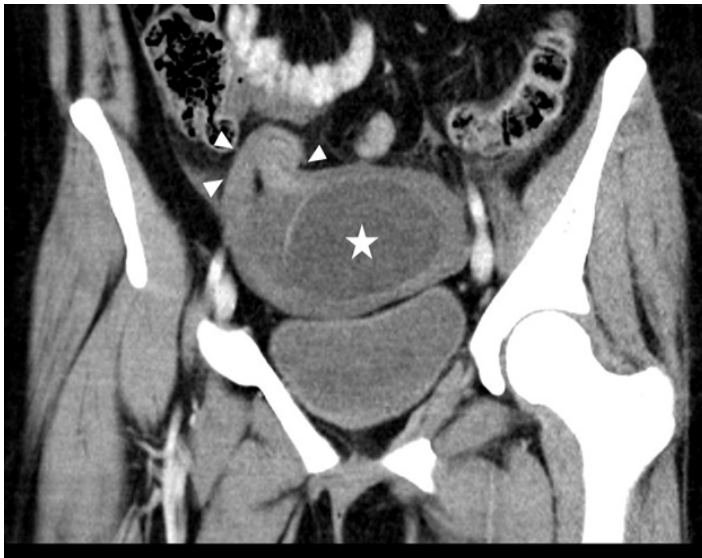*Isolated fallopian tube torsion is an uncommon entity requiring prompt surgical intervention.*

What is the major impact of the image(s)?

*Diagnosis requires a high index of suspicion supported by advanced imaging.*

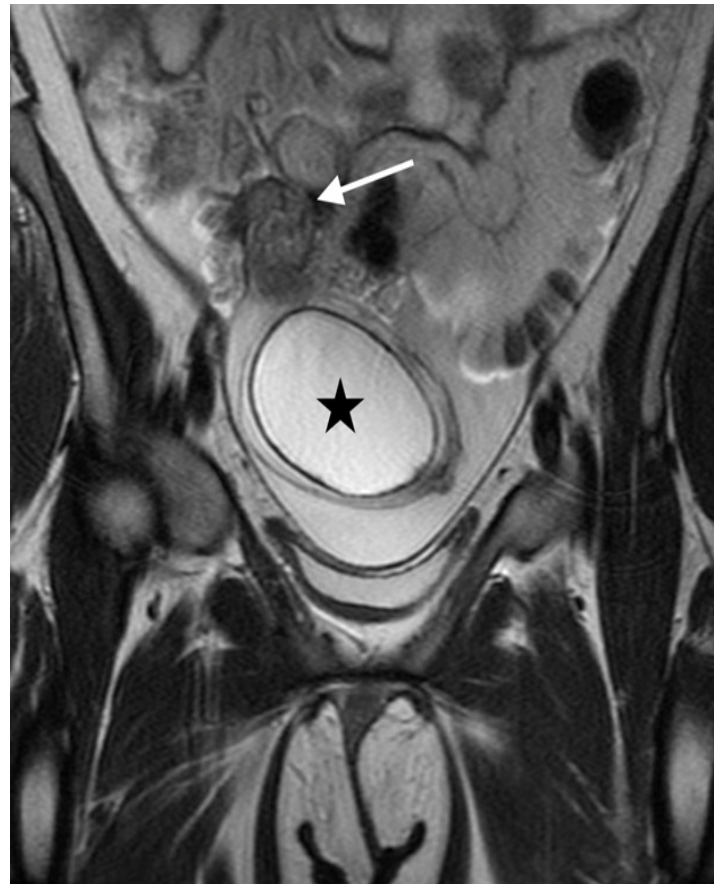How might this improve emergency medicine practice?

*Recognition and appropriate management are essential.*



**Image 2.** Coronal computed tomography of the pelvis shows the 7-centimeter cystic structure (star) within the pelvis with surrounding fluid. Along the right side of the cystic structure there is extension into the location of the area of the right fallopian tube (arrowheads).

thickening in the setting of normal-appearing ovaries.<sup>2</sup> Computed tomography and MRI may aid in the diagnosis. On CT, a mass between the uterus and the ovary is a sensitive (97%) and specific (81%) feature in women with adnexal torsion. Still, no consistent characteristic has been described for IFTT.<sup>2</sup> Magnetic resonance imaging is preferable for sparing radiation exposure but may not always be readily available in all EDs. Definitive treatment is



**Image 3.** Coronal T2 weighted magnetic resonance imaging of the pelvis demonstrates a 7-centimeter fluid signal tubal mass (star) with a twisted appearance of the torted right fallopian tube (arrow).



surgical detorsion. Salpingectomy is controversial and may hinder future fertility.<sup>1-4</sup>

Intraoperatively, the patient was found to have right hydrosalpinx and bilateral paratubal cysts, right-sided measuring 5 cm in maximum dimension, and left-sided measuring 7 x 5 x 1 cm. The patient underwent right salpingectomy, fallopian tube detorsion, and bilateral cystectomy without complications. The pathology report was negative for malignancy, and tumor markers were within normal limits. The patient remained asymptomatic at two-week follow-up.

The authors attest that their institution requires neither Institutional Review Board approval, nor patient consent for publication of this case report. Documentation on file.

---

*Address for Correspondence:* Mukund Mohan, MD, Staten Island University Hospital, Department of Emergency Medicine, 475 Seaview Ave, Staten Island, NY, 10305. Email: azhandasova1@northwell.edu

*Conflicts of Interest:* By the CPC-EM article submission agreement, all authors are required to disclose all affiliations, funding sources and financial or management relationships that

could be perceived as potential sources of bias. The authors disclosed none.

*Copyright:* © 2022 Zhandasova. This is an open access article distributed in accordance with the terms of the Creative Commons Attribution (CC BY 4.0) License. See: <http://creativecommons.org/licenses/by/4.0/>

---

## REFERENCES

1. Casey RK, Damle LF, Gomez-Lobo V. Isolated fallopian tube torsion in pediatric and adolescent females: a retrospective review of 15 cases at a single institution. *J Pediatr Adolesc Gynecol.* 2013; 26(3):189-92.
2. Delacroix C, Hcini N, Vintejoux E, et al. Isolated tubal twist: a case series of a rare event occurring at different times in reproductive life. *Int J Surg Case Rep.* 2021; 80:105688.
3. Hagege R, Sharvit M, Hamou B, et al. Isolated fallopian tube torsion: an under-diagnosed entity with debatable management. *J Minim Invasive Gynecol.* 2021; 29(1):158-63.
4. Bertozzi M, Noviello C, Molinaro F, et al. Isolated fallopian tube torsion in pediatric age: an italian multicenter retrospective study. *J Pediatr Surg.* 2020;55(4):711-4.

## Pediatric Cranial Dog Bite Injuries: More than Meets the Eye

Shanze A. Tahir, BA\*  
Karen Z. Carver, DMD, MD†  
Alex Cappitelli, BA†  
Lissa Baird, MD‡  
Ashley Marchese, MD§  
Ingrid M. Ganske, MD, MPA†

\*Harvard Medical School, Boston, Massachusetts  
†Harvard Medical School, Boston Children's Hospital, Department of Plastic and Oral Surgery, Boston, Massachusetts  
‡Harvard Medical School, Boston Children's Hospital, Department of Neurosurgery, Boston, Massachusetts  
§Harvard Medical School, Boston Children's Hospital, Department of Emergency Medicine, Boston, Massachusetts

Section Editor: Austin Smith, MD

Submission history: Submitted February 4, 2022; Revision received April 7, 2022; Accepted April 15, 2022

Electronically published August 6, 2022

Full text available through open access at [http://escholarship.org/uc/uciem\\_cpem](http://escholarship.org/uc/uciem_cpem)

DOI: 10.5811/cpcem.2022.4.56178

**Case Presentation:** A six-month-old female presented to a community hospital with small lacerations to the scalp, face, and left eyelid from a dog bite injury. Computed tomography imaging revealed an impacted right frontal bone fracture and left superior orbital fracture, prompting transfer, neurosurgical repair, and infectious disease management of the injury.

**Discussion:** This report highlights the importance of having a high level of suspicion for deeper injury in pediatric and especially infant craniofacial dog bites, obtaining radiographic imaging, and initiating appropriate multidisciplinary triage to prevent life-threatening infection and complications. [Clin Pract Cases Emerg Med. 2022;6(3):259-261.]

**Keywords:** *trauma; imaging; neurosurgery; plastic surgery.*

### CASE PRESENTATION

A six-month-old female presented to a community hospital with superficial-appearing lacerations of the scalp, face, and left eyelid after a dog bite. The dog and infant were both up to date on immunizations. Upon presentation, the patient was alert and stable. Computed tomography imaging demonstrated right frontal impacted calvarial fracture with displaced fragment and adjacent right frontal intraparenchymal hemorrhagic contusions, as well as a left superior orbital fracture (Image). The patient was treated with ampicillin-sulbactam and transferred in stable condition to a tertiary care center for neurosurgical intervention and management.

Upon transfer, the patient was neurologically intact. The infectious disease (ID) team recommended treatment with ceftriaxone and metronidazole for central nervous system coverage and broad-spectrum coverage of common canine oral flora, including *Pasteurella canis*, *Viridans streptococci*, *Staphylococcus aureus*, and *Fusobacterium*. Neurosurgery took the patient to the operating room for irrigation and debridement

and elevated and repaired the depressed skull fracture, contouring the calvarium to its normal frontal shape. Plastic surgery repaired the remaining facial and eyelid lacerations.

Following repair, the patient was admitted to the intensive care unit for monitoring for two nights and ultimately discharged on postoperative day five. According to ID recommendations, the patient was continued on ceftriaxone and metronidazole for four weeks post-surgery. The patient recovered without seizures, emesis, lethargy, fever, or weakness. Follow-up magnetic resonance imaging four months post injury showed evolving right frontal lobe encephalomalacia at the site of presentation of hemorrhagic contusions but no evidence of intracranial abscess, fluid collection, or parenchymal edema to suggest ongoing infection. The lacerations healed well.

### DISCUSSION

Although there are a handful of reports in the craniofacial and neurosurgical literature<sup>1-4</sup> of severe intracranial injury

from dog bites, emergency medicine diagnosis and triaging of such injuries has not been well reported.<sup>5</sup> This case highlights the important role of imaging in the emergency evaluation of dog-bite injuries to the head in infants to specifically assess for occult skull fracture, even when lacerations may appear superficial. The thin infant cranium is more easily injured, and greenstick fractures may be difficult to palpate. Using radiographic imaging to evaluate the extent of the penetrating injury can help direct prompt triage, consultations, and management to minimize the risk of life-threatening complications from untreated deep infection.

Open skull fractures and depressed skull fractures with underlying mass effect or aesthetic implications are both indications for neurosurgical washout and repair. Our standard management of such fractures entails prophylactic pre- and intraoperative antibiotics, as well as postoperative antibiotics for polymicrobial exposure. Whereas punctate bite wounds in soft tissue alone are often left open to drain and heal secondarily, such injuries over open skull fractures are typically closed after thorough irrigation, debridement, and fracture reduction. Follow-up imaging is obtained to rule out abscess development.

### CPC-EM Capsule

What do we already know about this clinical entity?

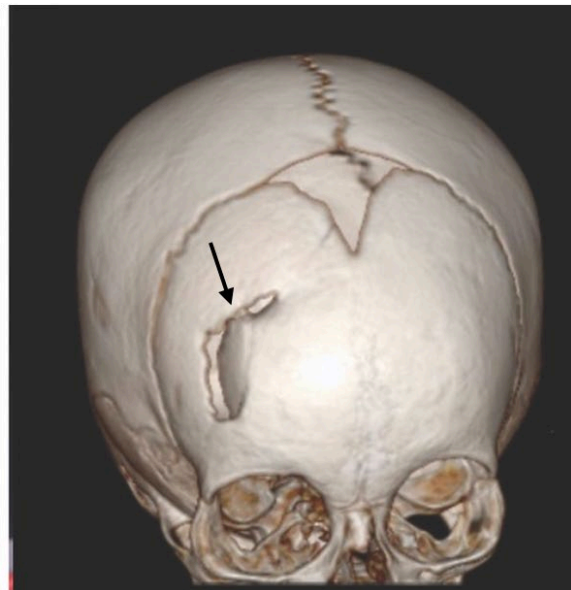
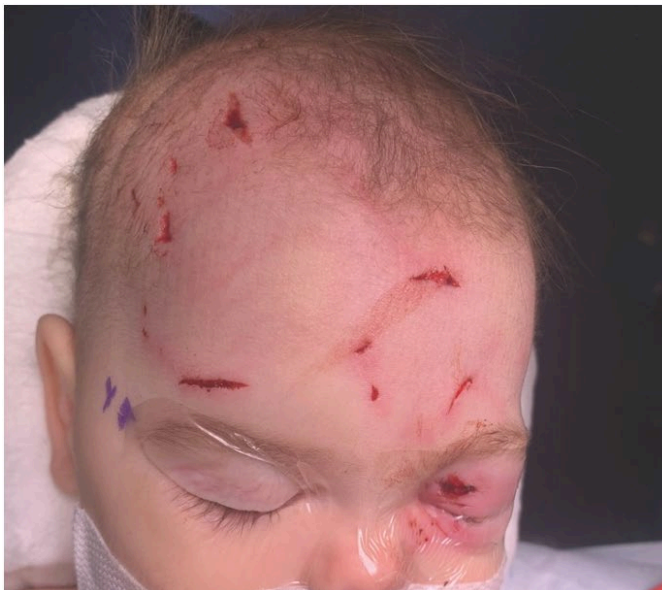*Infants are more susceptible to skull fractures from dog bite lacerations to the head.*

What is the major impact of the image(s)?

*Computed tomography imaging showed a depressed skull fracture under the superficial-appearing puncture wound. This finding necessitated surgical intervention.*

How might this improve emergency medicine practice?

*Beware of superficial-appearing scalp or facial dog-bite injuries in infants; imaging may reveal skull injuries that portend risk of life-threatening complications.*



**Image.** (Left) Facial and scalp lacerations; (Right) Computed tomography reconstruction demonstrating right frontal depressed skull fracture (arrow) under small scalp puncture wound from a dog bite.

We recommend that clinicians be wary of minor-appearing dog bite lacerations of the scalp in infants and strongly suggest obtaining imaging in the emergency department for all young patients with dog bites to the head.

Documented patient informed consent and/or Institutional Review Board approval has been obtained and filed for publication of this case report.

*Address for Correspondence:* Ingrid Ganske, MD, MPA, Boston Children's Hospital, Department of Plastic and Oral Surgery, 300 Longwood Avenue, Boston, MA 02115. Email: Ingrid.ganske@childrens.harvard.edu.

*Conflicts of Interest:* By the CPC-EM article submission agreement, all authors are required to disclose all affiliations, funding sources and financial or management relationships that could be perceived as potential sources of bias. The authors disclosed none.

Copyright: © 2022 Tahir. This is an open access article distributed in accordance with the terms of the Creative Commons Attribution (CC BY 4.0) License. See: <http://creativecommons.org/licenses/by/4.0/>

## REFERENCES

1. Klein DM and Cohen ME. Pasteurella multocida brain abscess following perforating cranial dog bite. *J Pediatr*. 1978;92(4):588-9.
2. Pinckney LE and Kennedy LA. Fractures of the infant skull caused by animal bites. *AJR Am J Roentgenol*. 1980;135(1):179-80.
3. Wilberger JE Jr and Pang D. Craniocerebral injuries from dog bite in an infant. *Neurosurgery*. 1981;9(4):426-8.
4. Steinbok P, Flodmark O, Scheifele DW. Animal bites causing central nervous system injury in children. A report of three cases. *Pediatr Neurosci*. 1985;12(2):96-100.
5. Steen T, Ravin K, Timmons S, et. al. Intracranial Injuries from dog bites in children. *Pediatr Neurosurg*. 2015;50(4):187-95.

# Omental Prolapse Through Vaginal Cuff Dehiscence

Jon Solberg, MD\*  
Karan Saravana, BS†

\*University of North Dakota, Department of Emergency Medicine, Bismarck, North Dakota  
†University of North Dakota, School of Medicine and Health Sciences, Bismarck, North Dakota

Section Editor: Manish Amin, DO

Submission History: Submitted February 3, 2022; Revision received February 28, 2022; Accepted May 19, 2022

Electronically published July 27, 2022

Full text available through open access at [http://escholarship.org/uc/uciem\\_cpem](http://escholarship.org/uc/uciem_cpem)

DOI: 10.5811/cpem.2022.2.56353

**Case Presentation:** A 31-year-old female presented to the emergency department with abdominal pain and a 15-centimeter bloody vaginal protrusion, which resulted during an attempted bowel movement. Reduction of the mass was unsuccessful, and the patient was taken to the operating room for examination.

**Discussion:** In patients with a history of vaginal hysterectomy, the vaginal cuff can dehisce and abdominal contents may protrude through the vaginal canal. In this case presentation, the vaginal mass was found to be omental tissue, which could be mistaken for a prolapse of vaginal mucosa. Therefore, a proper pelvic exam is imperative, as prolapse through a cuff dehiscence can lead to severe complications. [Clin Pract Cases Emerg Med. 2022;6(3):262-263.]

**Keywords:** *vaginal cuff dehiscence; omental prolapse; vaginal mass.*

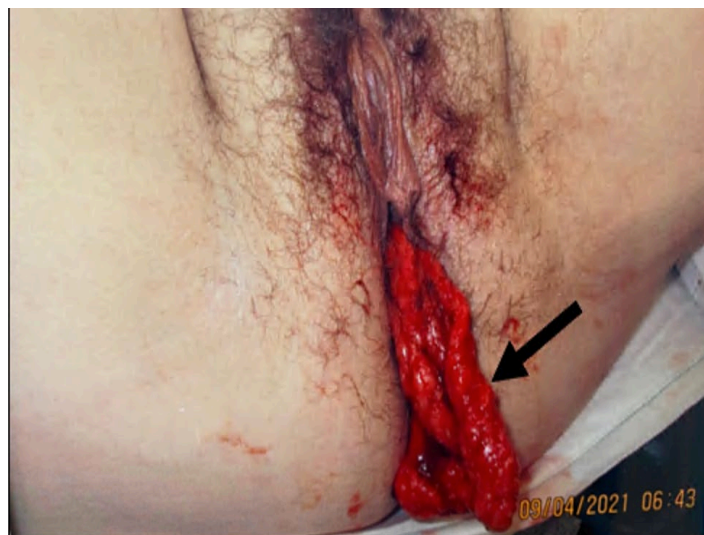## CASE PRESENTATION

A 31-year-old female with a history of laparoscopic-assisted vaginal hysterectomy two years prior presented by ambulance to the emergency department with an acute onset of abdominal pain and a vaginal protrusion that occurred while straining to pass a bowel movement. Physical examination was notable for a flat but slightly tender abdomen, normal bowel sounds, scant vaginal bleeding, and a 15-centimeter long, blood-tinged mass protruding from the vagina.

A brief and unsuccessful attempt at reduction was made by the emergency physician. Obstetrics and gynecology was consulted, and the patient was taken to the operating room for exam under anesthesia.

## DISCUSSION

The diagnosis was omental prolapse through vaginal cuff dehiscence. Following a vaginal hysterectomy, the vaginal cuff is closed surgically.<sup>1</sup> Occasionally, this site can dehisce, allowing abdominal contents such as the small bowel or omentum to enter the vagina or protrude through the vaginal canal.<sup>2,3</sup> In existing literature, reports of prolapses of omentum are uncommon, and photographed cases may illustrate an anterior or apical vaginal bulge, as opposed to a completely



**Image.** External pelvic examination demonstrates a blood-tinged mass (arrow) protruding from the vagina.

visible omental mass, as seen here.<sup>4</sup> Vaginal cuff dehiscence is estimated to have a rate of 0.39%. It is more commonly seen after total laparoscopic hysterectomy (1.35%) compared with

laparoscopic-assisted vaginal hysterectomy (0.28%).<sup>4</sup>

Risk factors include trauma from sexual intercourse, repetitive Valsalva maneuvers, smoking, malnutrition, anemia, diabetes, immunosuppression, and corticosteroid use.<sup>2</sup> Cases typically present as vaginal spotting or post-coital bleeding, and occasionally as pelvic pressure or protrusion.<sup>2</sup> Most cases occur within weeks to months after the procedure, but some can present years later. Patients are at risk for infection due to exposure of peritoneal contents to vaginal and skin flora. Management includes administration of broad-spectrum antibiotics. Partial dehiscence can be managed with rest, but large dehiscence is usually managed surgically.

This case highlights the importance of the pelvic exam in patients with vaginal bleeding and abdominal pain, and care should be taken to not mistake protruding omental tissue for prolapsed vaginal mucosa.

Documented patient informed consent and/or Institutional Review Board approval has been obtained and filed for publication of this case report.

*Address for Correspondence:* Karan Saravana, BS, University of North Dakota, School of Medicine and Health Sciences, 1301 N Columbia Rd Stop 9037, Grand Folks, ND 58202. Email: k.saravana@umd.edu.

*Conflicts of Interest:* By the CPC-EM article submission agreement, all authors are required to disclose all affiliations, funding sources and financial or management relationships that could be perceived as potential sources of bias. The authors disclosed none.

*Copyright:* © 2022 Solberg. This is an open access article distributed in accordance with the terms of the Creative Commons Attribution (CC BY 4.0) License. See: <http://creativecommons.org/licenses/by/4.0/>

### *CPC-EM Capsule*

What do we already know about this clinical entity?

*Vaginal cuff dehiscence is seen in patients with a history of vaginal hysterectomy. Abdominal contents can prolapse through the vaginal cuff and protrude through the vagina.*

What makes this presentation of disease reportable?

*The image illustrates a rare photograph of omental prolapse via cuff dehiscence.*

What is the major learning point?

*This condition will appear as a bloody mass, which should not be mistaken for prolapsed vaginal mucosa, due to risk of infection.*

How might this improve emergency medicine practice?

*Immediate recognition allows for decreased misidentification and decreased chance of risk, such as infection of peritoneal contents.*

### REFERENCES

1. Binz NM. Complications of gynecologic procedures. In: *Emergency Medicine: A Comprehensive Study Guide*, 9e. McGraw Hill; 2020.
2. McGrane O and Owens S. Elderly female with abdominal pain. *Images Emerg Med*. 2012; 60 (1):132.
3. Sokol ER and Munro EG. Incarcerated vaginal herniation of the omentum mimicking vaginal prolapse. *Am J Obstet Gynecol*. 2007 Mar;196(3):e7-8.
4. Clarke-Pearson DL, Geller EJ. Complications of hysterectomy. *Obstet Gynecol*. 2013 Mar;121(3):654-73.

## Infant with Groin Swelling

Nisha Polavarapu, MD\*  
Brendan Kilbane, MD†

\*Hackensack Meridian School of Medicine, Hackensack University Medical Center, Department of Pediatric Emergency Medicine, Hackensack, New Jersey  
†Rainbow Babies and Children's Hospital, Department of Pediatric Emergency Medicine, Cleveland, Ohio

Section Editor: Jacqueline Le, MD

Submission History: Submitted February 14, 2022; Revision received June 3, 2022; Accepted June 9, 2022

Electronically published August 8, 2022

Full text available through open access at [http://escholarship.org/uc/uciem\\_cpccem](http://escholarship.org/uc/uciem_cpccem)

DOI: 10.5811/cpcem2022.6.56426.

**Case Presentation:** A 21-day-old female presented to the pediatric emergency department with swelling of the left groin. Physical examination revealed a soft, nontender abdomen and a two-centimeter firm and fixed mass on the left aspect of her mons pubis. Point-of-care ultrasound revealed a left inguinal hernia with incarcerated ovary.

**Discussion:** Inguinal hernias are common in the pediatric population. In female patients, particularly those less than one year old, inguinal hernias most frequently contain an ovary rather than bowel; so they require careful evaluation to protect future reproductive function. [Clin Pract Cases Emerg Med. 2022;6(3):264-265.]

**Keywords:** *hernia; groin; ovary; infant; ultrasound.*

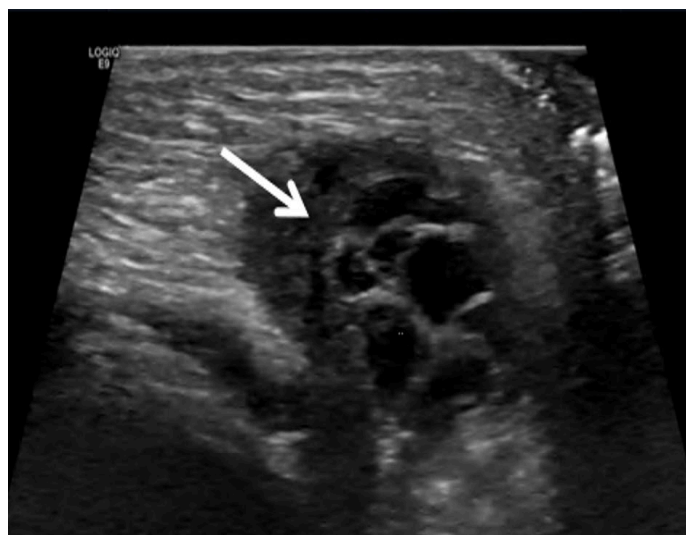### CASE PRESENTATION

A 21-day-old female presented to the pediatric emergency department with swelling of the left groin, which was first noticed while her family changed her diaper the morning of presentation. They denied any redness or warmth over the site but felt that she was fussier than normal overnight. They reported that she fed normally that morning and had her normal number of wet diapers. The patient was otherwise healthy and born at 37 weeks gestation without complications. On physical examination, the patient was well appearing with a soft, nontender abdomen and an irreducible two-centimeter (cm) firm and fixed mass on the left aspect of her mons pubis that was tender to palpation.

A point-of-care ultrasound was performed and showed a two-cm mass with follicles. A confirmatory formal ultrasound was subsequently obtained, which showed a 2.1 x 1.1 x 2.1 cm mass in the left perineal region with subcentimeter follicles and flow demonstration, which confirmed the diagnosis of an inguinal hernia with incarcerated ovary (Images 1-3). Pediatric surgery was consulted, and the patient was taken to the operating room for left inguinal hernia repair with reduction of an incarcerated ovary.

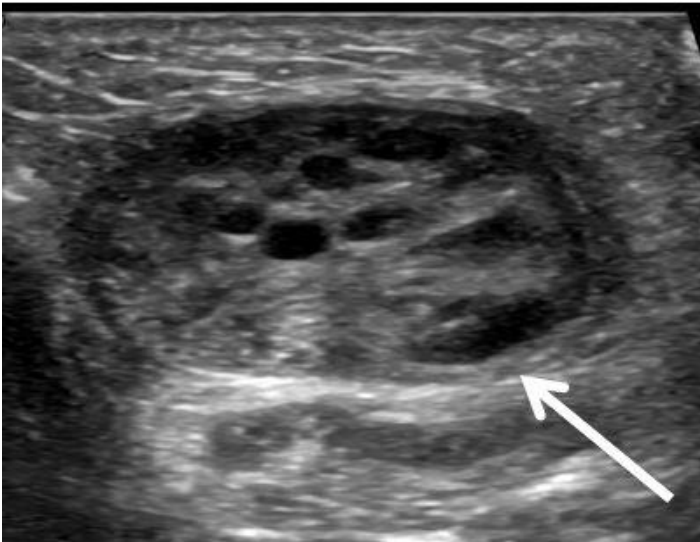
### DISCUSSION

Inguinal hernias in the pediatric population are more commonly seen in premature infants, in male infants, and in

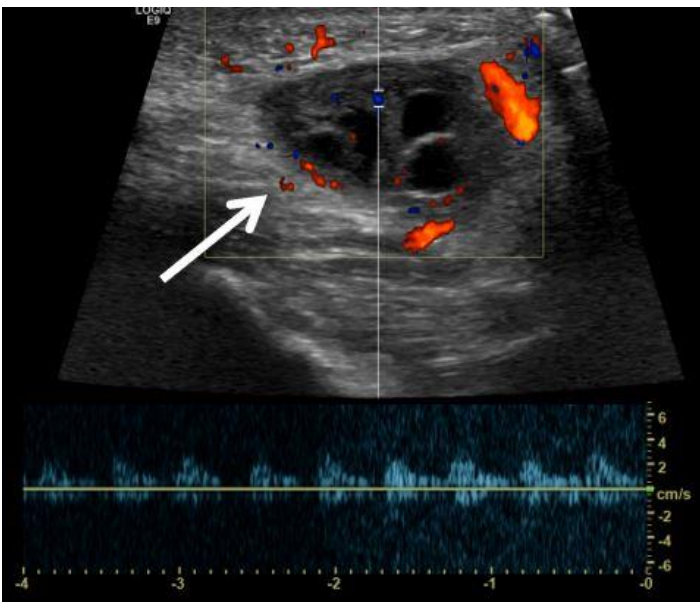


**Image 1.** Ultrasonography (transverse view) showing an incarcerated ovary (arrow) within an inguinal hernia.

those less than one year old.<sup>1</sup> In female patients, particularly those less than a year old, inguinal hernias most frequently contain an ovary rather than bowel; so they require careful evaluation to protect future reproductive function.<sup>2</sup> Prompt ultrasound is important in females if the mass is not easily



**Image 2.** Ultrasonography (sagittal view) showing an incarcerated ovary (arrow) within an inguinal hernia.



**Image 3.** Ultrasonography with Doppler showing an incarcerated ovary (arrow) within an inguinal hernia.

reducible, as forceful reduction of the mass could result in torsion.<sup>3</sup> Ultrasound will differentiate the contents of the hernia sac and determine whether appropriate blood flow is present if an ovary is involved.<sup>4</sup> An irreducible ovary is at higher risk for ovarian torsion, given alteration of anatomy, and should be treated as a surgical emergency.<sup>5</sup>

The authors attest that their institution requires neither Institutional Review Board approval nor patient consent for publication of this case report. Documentation on file.

### *CPC-EM Capsule*

What do we already know about this clinical entity?

*Inguinal masses are a common chief complaint in infants presenting for emergency care. Majority of these are inguinal hernias and may contain bowel.*

What is the major impact of the image(s)?

*These images demonstrate an inguinal hernia in a female containing an ovary rather than bowel.*

How might this improve emergency medicine practice?

*Point-of-care ultrasound to identify the contents of an inguinal mass will improve and expedite patient care and management.*

*Address for Correspondence:* Nisha Polavarapu, MD, Hackensack University Medical Center, Department of Pediatric Emergency Medicine, 30 Prospect Ave, Hackensack, NJ 07601. Email: nisha.polavarapu@hmn.org.

*Conflicts of Interest:* By the CPC-EM article submission agreement, all authors are required to disclose all affiliations, funding sources and financial or management relationships that could be perceived as potential sources of bias. The authors disclosed none.

*Copyright:* © 2022 Polavarapu et al. This is an open access article distributed in accordance with the terms of the Creative Commons Attribution (CC BY 4.0) License. See: <http://creativecommons.org/licenses/by/4.0/>

### REFERENCES

1. Yeap E, Pacilli M, Nataraja RM. Inguinal hernias in children. *Aust J Gen Pract.* 2020;49(1-2):38-43.
2. Cerit KK, Ergelen R, Colak E, et al. Inguinal hernia containing uterus, fallopian tube, and ovary in a premature newborn. *Case Rep Pediatr.* 2015;2015:807309.
3. Abdulhai SA, Glenn IC, Ponsky TA. Incarcerated pediatric hernia. *Surg Clin North Am.* 2017;97(1):129-45.
4. Tilt L and Kessler DO. Rapid evaluation of an inguinal mass in a female infant using point-of-care ultrasound. *Pediatr Emerg Care.* 2014;30(5):366-7.
5. Boley SJ, Cahn D, Lauer T, et al. The irreducible ovary: a true emergency. *J Pediatr Surg.* 1991;26(9):1035-8.



# Exertional Near-Syncope: Pericardial Cyst as a Cause of Left Ventricular Outflow Obstruction

Ryan Offman, DO  
Joseph Skopek, DO

Michigan State University College of Osteopathic Medicine, Mercy Health – Muskegon,  
Department of Emergency Medicine, Muskegon, Michigan

Section Editor: Austin Smith, MD

Submission History: Submitted March 13, 2022; Revision received June 6, 2022; Accepted June 9, 2022

Electronically published August 8, 2022

Full text available through open access at [http://escholarship.org/uc/uciem\\_cpccem](http://escholarship.org/uc/uciem_cpccem)

DOI: 10.5811/cpccem2022.6.56749

**Case Presentation:** A 41-year-old otherwise healthy male presented to the emergency department with recurrent exertional near-syncope. He was eventually found to have a large pericardial cyst causing an outflow obstruction. After resection of the cyst by cardiothoracic surgery, he had an uneventful hospital course and was discharged seven days later with no recurrent syncopal episodes.

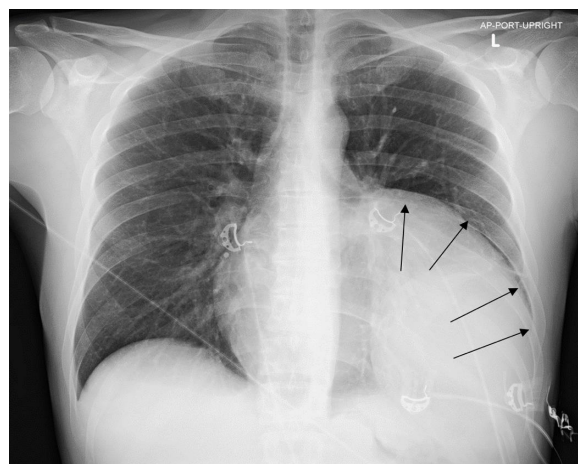
**Discussion:** We describe an otherwise healthy patient who exhibited symptomatic left ventricular outflow obstruction from a pericardial cyst. These cysts are usually benign and asymptomatic, although they can progress to cause significant morbidity or mortality. Surveillance is recommended if no hemodynamic compromise is present. Patients who are symptomatic or have hemodynamic compromise may undergo needle aspiration or thoracoscopy with resection. [Clin Pract Cases Emerg Med. 2022;6(3):266–267.]

**Keywords:** *pericardial cyst; near-syncope.*

## CASE PRESENTATION

A 41-year-old male presented to the emergency department (ED) describing recurrent, exertional presyncope. While using a sitz bath, he became diaphoretic, short of breath, and experienced one to two minutes of chest pain and lightheadedness. Subsequently, the patient noted he would have recurrence of these symptoms with minimal exertion. Symptoms would resolve with rest. He denied history of venous thromboembolism, prior exertional chest pain, or any significant rectal bleed. In the ED, he was hemodynamically stable. Physical examination demonstrated decreased left-sided breath sounds but was otherwise normal. A plain film of his chest revealed cardiomegaly vs underlying mass (Image 1). A computed tomography angiography of his chest was obtained.

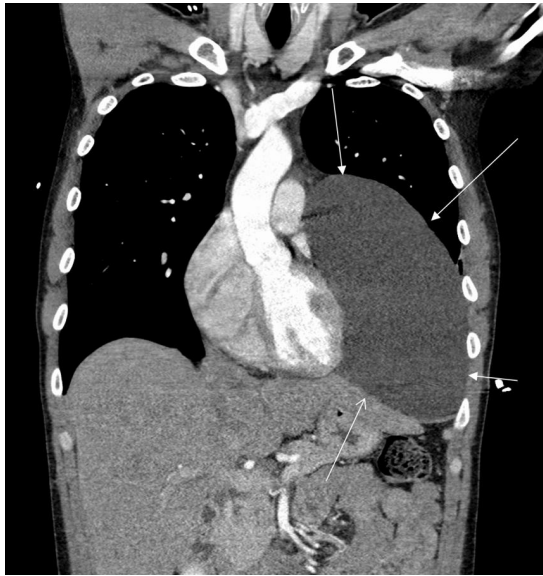
Images revealed a large pericardial cyst (Images 2 and 3). An emergent cardiology-performed echocardiogram was performed showing the compression of the inferior left ventricle. High sensitivity troponin and D-dimer were both negative. He was admitted to the hospital and his pericardial cyst was resected by cardiothoracic surgery the following day. Histopathology demonstrated a benign thymic mass. He had an uneventful hospital course and routine follow-up without return of his shortness of breath or presyncopal episodes.



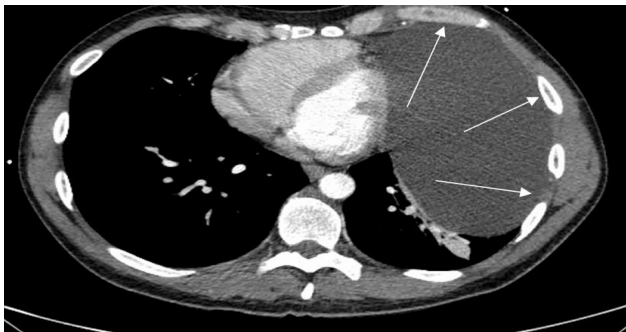**Image 1.** A plain film radiograph of the chest revealing cardiomegaly with a left lower lobe opacity versus mass outlined by arrows.

## DISCUSSION

Pericardial cysts are generally asymptomatic, benign masses. However, they occasionally can cause chest pain and/or shortness of breath. They typically form at the cardiophrenic angle.<sup>1</sup> They are usually asymptomatic but can occasionally cause cardiac tamponade or outflow obstruction. Echocardiography is a key



**Image 2.** A computed tomography angiogram revealing a large cystic lesion in the left lower and mid-chest abutting the mediastinum and left heart border measuring 20 x 11 x 17 centimeters. The arrows outline the mass.



**Image 3.** A computed tomography angiogram revealing the large pericardial cyst in an axial cut outlined by the arrows.

diagnostic imaging modality to determine management in these cases. Management typically involves serial echocardiograms if the cysts are asymptomatic.<sup>2</sup> Treatment options consist of needle aspiration or thoracoscopy with resection depending on the size of the cyst and symptoms resulting from the cyst. The most worrisome complications of pericardial cysts include cardiac tamponade, heart failure, atrial fibrillation, outflow obstruction, and airway collapse.<sup>3</sup> Our patient demonstrated compression of the inferior wall of the left ventricle, which could potentially progress to sudden cardiac death by pericardial tamponade.<sup>4</sup>

Pericardial cysts and other mediastinal masses are important considerations in the differential diagnosis of syncope to clinicians, and they may not be able to be differentiated on radiograph alone. The cysts can manifest with similar clinical presentations as more common etiologies. Transthoracic echocardiogram may be indicated during the emergent work-up of these patients especially if they present with exertional symptoms, unstable vital signs, or abnormal chest radiography.

### *CPC-EM Capsule*

What do we already know about this clinical entity?

*Pericardial cysts are usually asymptomatic and benign but can occasionally cause cardiac tamponade or outflow obstruction.*

What is the major impact of the image(s)?

*Pericardial cysts are important considerations in the differential diagnosis of syncope to clinicians, and they may not be able to be differentiated on radiograph alone.*

How might this improve emergency medicine practice?

*Cardiomegaly on plain radiograph has a broad differential and echocardiography is key in assessing cardiovascular effects of pericardial cysts.*

The authors attest that their institution requires neither Institutional Review Board approval nor patient consent for publication of this case report. Documentation on file.

*Address for Correspondence:* Ryan Offman, DO, Mercy Health – Muskegon, Department of Emergency Medicine, 1675 LeahySt. Ste 315A, Muskegon, MI, 49442. Email: Ryan.offman@mercyhealth.com.

*Conflicts of Interest:* By the CPC-EM article submission agreement, all authors are required to disclose all affiliations, funding sources and financial or management relationships that could be perceived as potential sources of bias. The authors disclosed none.

*Copyright:* © 2022 Offman et al. This is an open access article distributed in accordance with the terms of the Creative Commons Attribution (CC BY 4.0) License. See: <http://creativecommons.org/licenses/by/4.0/>

### REFERENCES

1. Najib MQ, Chaliki HP, Raizada A, et al. Symptomatic pericardial cyst: a case series. *Eur J Echocardiogr.* 2011;12(11):E43.
2. Abbey AM and Flores RM. Spontaneous resolution of a pericardial cyst. *Ann Thorac Cardiovasc Surg.* 2010;16(1):55-6.
3. Satur CM, Hsin MK, Dussek JE. Giant pericardial cysts. *Ann Thorac Surg.* 1996;61(1):208-10.
4. Bandeira FC, de Sa VP, Moriguti JC, et al. Cardiac tamponade: an unusual complication of pericardial cyst. *J Am Soc Echocardiogr.* 1996;9(1):108-12.

## Snocross “Shark-bite” Laceration

Wyatt Telken, BS  
Jon Solberg, MD, DiMM  
Mark Raymond, BS

University of North Dakota School of Medicine and Health Sciences, Department of  
Emergency Medicine, Bismarck, North Dakota

Section Editor: Melanie Heniff, MD, JD

Submission History: Submitted April 13, 2022; Revision received June 3, 2022; Accepted June 9, 2022

Electronically published August 8, 2022

Full text available through open access at [http://escholarship.org/uc/uciem\\_cpem](http://escholarship.org/uc/uciem_cpem)

DOI: 10.5811/cpcem2022.6.57128

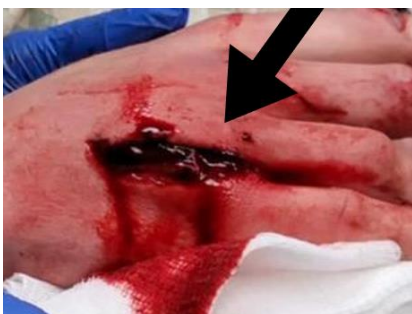**Case Presentation:** A snowmobile racer fell from his sled and was run over by another, sustaining “shark bite” to his hand and leg. He was evacuated to a trackside medical trailer where the characteristic wounds were felt to require further exploration at a hospital.

**Discussion:** “Shark bite” is a colloquial term for lacerations sustained from metal studs attached to a snowmobile’s track. “Shark-bite” lacerations may be more prone to complications than other lacerations commonly sustained in motorsports events. [Clin Pract Cases Emerg Med. 2022;6(3):268–269.]

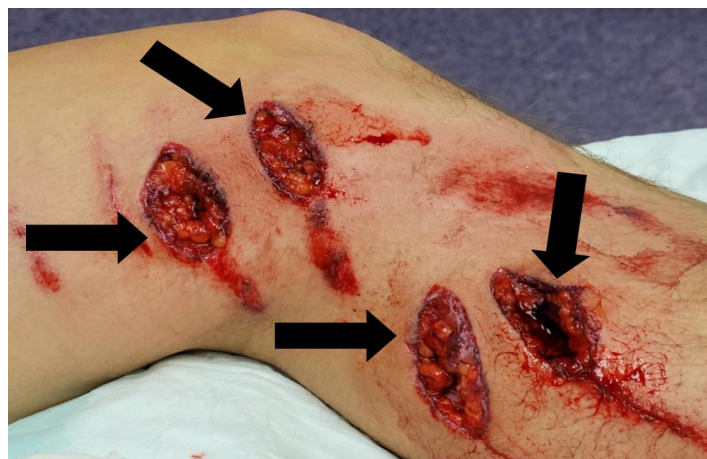**Keywords:** *Snocross; laceration; shark bite; motorsport; wound.*

### CASE PRESENTATION

A 30-year-old male Snocross (competitive snowmobile racing) rider fell from his snowmobile and was run over by another rider. An emergency medical technician who evaluated him trackside found a painful, bloody hand and ripped pants saturated with blood. The patient was able to be transported to a trackside medical trailer. Physical exam was significant for a right hand (Image 1) open laceration dorsally with fourth and fifth digits held in passive flexion with sensation intact, and left leg (Image 2) with several linear



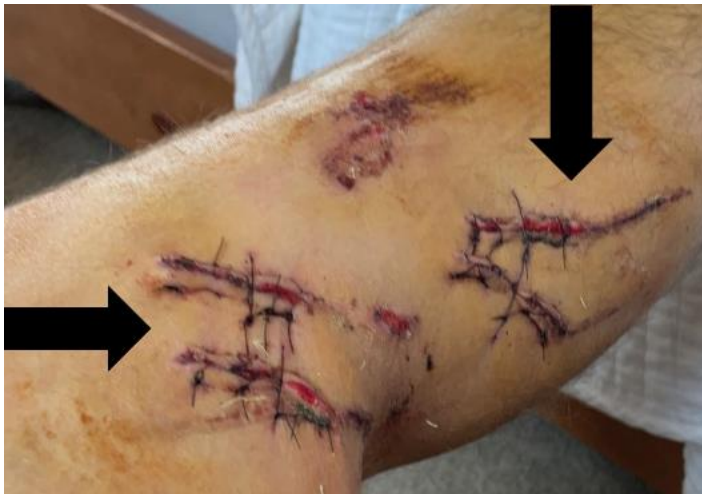**Image 1.** Image of the patient’s right hand on presentation to the hospital, demonstrating a laceration (arrow) to the dorsal side between the fourth and fifth metacarpals. Patient had weakness to extension of the right fingers and was found to have extensor tendon lacerations.



**Image 2.** Image of the left thigh and calf demonstrating four deep lacerations as well as multiple abrasions. These lacerations (arrows) are referred to as “shark bite” in the world of Snocross competition due to their resemblance to wounds experienced by those in a shark attack. They occur when the rider is run over by the metal treads of the snowmobile track. They are powerful enough to tear through the racer’s thick winter gear to cause these deep lacerations.

lacerations extending at least into the subcutaneous fat. The “shark bite” associated with metal cleats from a snowmobile track can be deep, contaminated, associated with significant

underlying injury, and prone to tetanus. The wounds were covered with saline-soaked gauze and wrapped. The hand was placed in a volar splint of malleable aluminum and wrapped with an elastic bandage. The patient was transported to a local hospital by private vehicle.



**Image 3.** After washout and repair in the operating room, the leg in the image demonstrates closure of the lacerations (arrows) to the left lower extremity.

## DISCUSSION

Orthopedic injuries from snowmobile accidents have been documented previously.<sup>1</sup> However, soft tissue injuries from snowmobile track, known as “shark bite” have not been previously described in the literature. Shark bite can be a major injury associated with snowmobiles or other recreational vehicles that rely on studded tracks for traction; emergency physicians in winter climates should be aware of this type of injury. While the repair of a laceration is commonplace for an emergency physician, consideration needs to be made for antibiotics and tetanus vaccination of these patients due to the nature of their injuries. Snowmobile tracks frequently contact soil and contaminated snow and could become broken and dislodged in these wounds. *Clostridium tetani* is a pathogen whose spores can survive in the soil during the winter.<sup>2</sup>

Patient consent has been obtained and filed for the publication of this case report.

### *CPC-EM Capsule*

What do we already know about this clinical entity?

*No similar information on the mechanism of this injury or images of the injury can be found in the literature. Standard wound care for lacerations is well known.*

What is the major impact of the image(s)?

*Bringing forth images not currently in the literature along with the unique name of “shark bite” that coincides with the injury and its mechanism.*

How might this improve emergency medicine practice?

*Providing physicians with these images provides knowledge of what to expect when encountering a snowmobile track laceration for those who do not often see them.*

*Address for Correspondence:* Jon Solberg, MD, DiMM, University of North Dakota School of Medicine and Health Sciences, Department of Emergency Medicine, 701 E Rosser Ave, Second Floor, Bismarck, ND 58501. Email: jon.solberg@und.edu.

*Conflicts of Interest:* By the CPC-EM article submission agreement, all authors are required to disclose all affiliations, funding sources and financial or management relationships that could be perceived as potential sources of bias. The authors disclosed none.

*Copyright:* © 2022 Telken et al. This is an open access article distributed in accordance with the terms of the Creative Commons Attribution (CC BY 4.0) License. See: <http://creativecommons.org/licenses/by/4.0/>

## REFERENCES

1. Whiting P, Rice C, Siy A, et al. Orthopaedic Injuries from snowmobile accidents: a multi-center analysis of demographics, injury patterns, and outcomes. *Eur J Orthop Surg Traumatol.* 2019;29(8):1617-21.
2. Baumgardner DJ. Soil-related bacterial and fungal infections. *J Am Board Fam Med.* 2012;25(5):734-44.

# Point-of-care Ultrasound to Distinguish Retinal Detachment and Ruptured Arterial Microaneurysm

Rachel Kester, MD  
Scott Szymanski, MD  
Michael Perreault, MD

Madigan Army Medical Center, Department of Emergency Medicine, Joint Base Lewis-McChord, Washington

Section Editors: Joel Moll, MD

Submission History: Submitted November 4, 2021; Revision received April 7, 2022; Accepted April 15, 2022

Electronically published August 12, 2022

Full text available through open access at [http://escholarship.org/uc/uciem\\_cpem](http://escholarship.org/uc/uciem_cpem)

DOI: 10.5811/cpcem2022.4.55301

**Case presentation:** We present the case of an older male with point-of-care-ultrasound (POCUS) imaging consistent with retinal detachment who was instead found by ophthalmology to have a ruptured arterial microaneurysm with vitreous and preretinal hemorrhage. The patient later had complete resolution of his symptoms. We discuss this retinal detachment “mimic.”

**Discussion:** Preretinal hemorrhage is an uncommon condition that can be mistaken for ophthalmologic emergencies such as retinal detachment. The images and videos shown here add to the body of evidence that POCUS is useful in diagnosing pre-retinal hemorrhage but must be differentiated from retinal detachment. These images also emphasize the need for further research and application of POCUS for the identification of preretinal hemorrhage. [Clin Pract Cases Emerg Med. 2022;6(3):270-271.]

**Keywords:** *point-of-care ultrasound; preretinal hemorrhage; retinal detachment.*

## CASE PRESENTATION

A 64-year-old male presented to the emergency department (ED) with sudden, dark, “curtain-like” painless vision loss in his right eye after heavy lifting three days earlier. Vision loss had since resolved; however, the patient complained of continued persistent floaters and blurriness. Visual acuity in his left eye was 20/20 and 20/60 in his right eye without diplopia. He had intact extraocular movements with pupils equal and reactive to light. Intraocular pressure was 13 millimeters of mercury in both eyes. Point-of-care ultrasound (POCUS) findings were concerning for a retinal detachment and vitreous hemorrhage (Video). The patient was not on any blood thinner medication. No further workup was obtained in the ED and ophthalmology consult determined the final diagnosis to be a ruptured arterial microaneurysm at the superotemporal arcade with vitreous and preretinal hemorrhage.

## DISCUSSION

Valsalva retinopathy is an uncommon condition most typically seen in young males following sudden increases in

intra-abdominal pressure from activities such as vomiting or, as in the case of our patient, weightlifting, which cause a spontaneous rupture of ocular capillaries.<sup>1</sup> While this condition is mostly self-limited with a favorable visual prognosis, it is imperative to distinguish this condition from other ophthalmologic emergencies that require immediate intervention, such as a retinal detachment. Diagnosing retinal detachment via POCUS has been shown to have a sensitivity of 97% and specificity of 88%.<sup>2</sup> Ultrasound findings of a bright, continuous, folded membrane with independent excursion upon recruitment of extraocular muscles while visualizing the optic nerve are highly suggestive of a retinal detachment but cannot rule out a ruptured arterial microaneurysm based on POCUS alone.<sup>2</sup>

Thus, these ultrasound findings warrant an ophthalmologic consult for definitive diagnosis and treatment. While this is not a diagnosis typically made by an emergency physician, it is important for the emergency physician to be aware of such retinal detachment “mimics” when discussing with consultants and patients, especially when valsalva is involved in the history. In these cases, however, retinal

detachment remains the “must not miss” diagnosis.

**Video.** Point-of-care ultrasound on patient’s right eye demonstrating a bright, echogenic undulating membrane extending across the posterior vitreous area that is highly concerning for retinal detachment.

Documented patient informed consent and/or Institutional Review Board approval has been obtained and filed for publication of this case report.

---

*Address for Correspondence:* Rachel Kester, MD, Madison Army Medical Center, Department of Emergency Medicine, 9040 Jackson Avenue, Tacoma, WA 98431. Email: Rachel.m.kester2.mil@mail.mil.

*Conflicts of Interest:* By the CPC-EM article submission agreement, all authors are required to disclose all affiliations, funding sources and financial or management relationships that could be perceived as potential sources of bias. The authors disclosed none. The views expressed here are those of the authors and do not reflect the official policy of the Department of the Army, the Department of Defense, or the U.S. Government.

*Copyright:* © 2022 Kester. This is an open access article distributed in accordance with the terms of the Creative Commons

## REFERENCES

1. Waikar S, and Srivastava VK. Valsalva retinopathy in a young healthy individual. *Med J Armed Forces India*. 2013;69(2):193-5.
2. Lahham S, Shniter I, Thompson M, et al. Point-of-care ultrasonography in the diagnosis of retinal detachment, vitreous hemorrhage, and vitreous detachment in the emergency department. *JAMA Netw Open*. 2019;2(4):e192162.
3. Garcia K, Jakubowski J, Archer L. Pre-retinal hemorrhage on point-of-care ultrasound. *Clin Pract Cases Emerg Med*. 2018;2(3):274-5.

### *CPC-EM Capsule*

What do we already know about this clinical entity?

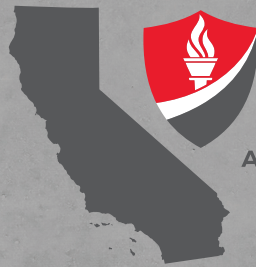*We know about the treatment and management of preretinal hemorrhage and retinal detachment but not how the two entities differ diagnostically.*

What is the major impact of the images?  
*Preretinal hemorrhage appears similar to retinal detachment on orbital ultrasound.*

How might this improve emergency medicine practice?

*Point-of-care-ultrasound can be used to diagnose preretinal hemorrhage, while demonstrating that ophthalmologic emergencies such as retinal detachment cannot be ruled out.*

**JOIN  
CAL/AAEM!**



**CALAAEM**

CALIFORNIA CHAPTER DIVISION OF THE  
AMERICAN ACADEMY OF EMERGENCY MEDICINE

*Championing  
individual physician rights  
and workplace fairness*

## **BENEFITS**

- *Western Journal of Emergency Medicine* Subscription
- CAL/AAEM News Service email updates
- Discounted AAEM pre-conference fees
- And more!

## **CAL/AAEM NEWS SERVICE**

- Healthcare industry news
- Public policy
- Government issues
- Legal cases and court decisions

In collaboration with our official journal

**WestJEM** Integrating Emergency Care  
with Population Health



FACEBOOK.COM/CALAAEM



FOLLOW US @CALAAEM

[HTTP://WWW.CALAAEM.ORG](http://www.calaaem.org)



**CALIFORNIA ACEP**

**50**

**ANNIVERSARY**