

# UC Davis

## Dermatology Online Journal

### Title

Juvenile dermatomyositis with joint contractures and calcinosis cutis

### Permalink

<https://escholarship.org/uc/item/1cg4c5pn>

### Journal

Dermatology Online Journal, 21(10)

### Authors

Turan, Enver  
Yesilova, Yavuz  
Surucu, Hacer Altun  
[et al.](#)

### Publication Date

2015

### DOI

10.5070/D32110028957

### Copyright Information

Copyright 2015 by the author(s). This work is made available under the terms of a Creative Commons Attribution-NonCommercial-NoDerivatives License, available at <https://creativecommons.org/licenses/by-nc-nd/4.0/>

Peer reviewed

**Photo vignette**

**Juvenile dermatomyositis with joint contractures and calcinosis cutis**

Enver Turan, Yavuz Yesilova, Hacer Altın Surucu, Osman Tanrikulu, Naime Eroğlu, Sezen Kocarlan

Dermatology Online Journal 21 (10): 15

Harran University Faculty of Medicine

**Correspondence:**

Enver Turan  
Harran University Faculty of Medicine  
enverturan@gmail.com

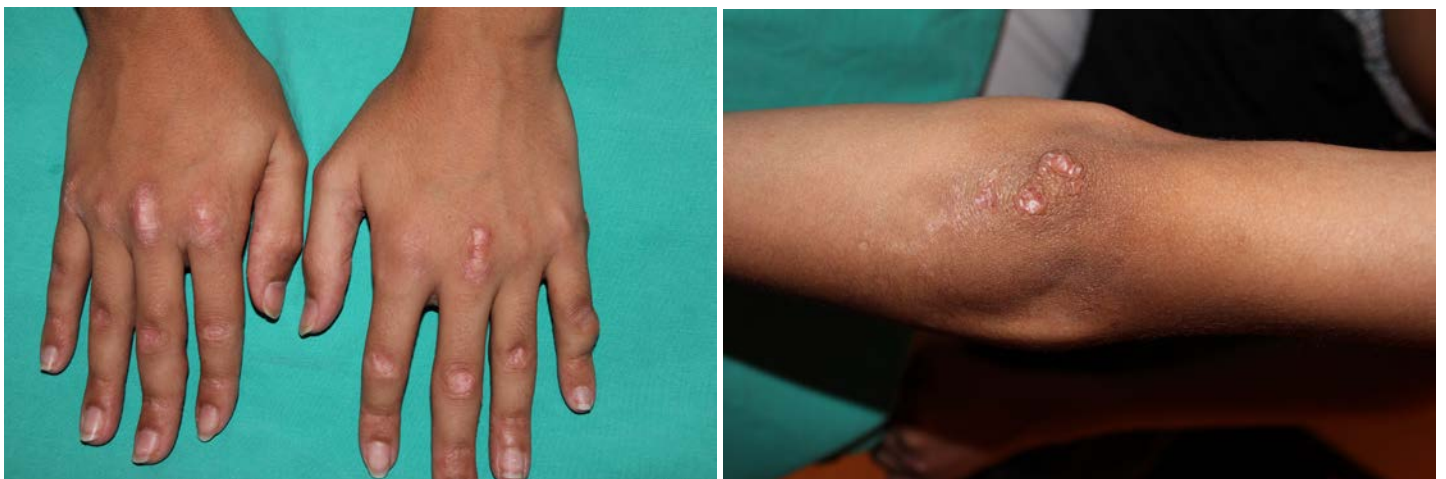---

**Abstract**

A 12-year-old boy presented to our department with firm papules on the fingers of both hands, erythematous scaly plaques on the dorsum of the hands and elbow, and deformities and limitation of motion in the joints of the hands and feet. His parents reported that the eruption started 6 years prior to presentation. He was previously diagnosed with psoriasis by physicians and acitretin treatment was given. However, he did not benefit from the treatment.

**Case synopsis**

Physical examination revealed atrophic erythematous papules and plaques, 1–2 cm in diameter (Gottron papules), over metacarpophalangeal and proximal and distal interphalangeal joints and elbow (Figure 1-2). Skin-coloured painless papules and nodules were observed in the medial phalanx of the little finger and in the metacarpophalangeal joint in the left hand, clinically recognized as calcinosis cutis (Figure 3). The nodules were circumscribed and firm.

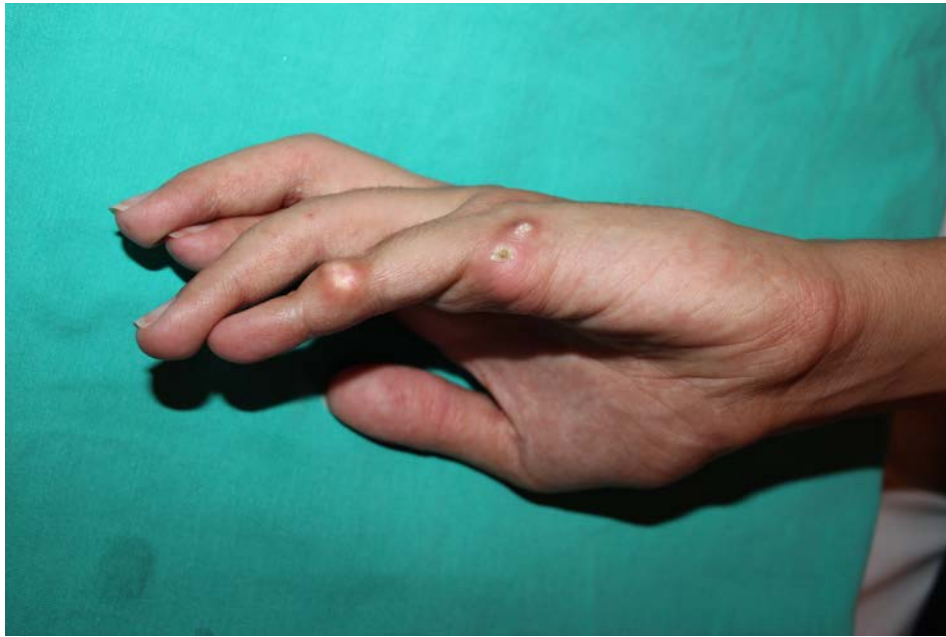

**Figure 1.** Atrophic erythematous papules and plaques over metacarpophalangeal joint (Gottron papules). **Figure 2.** Atrophic erythematous plaques on elbow

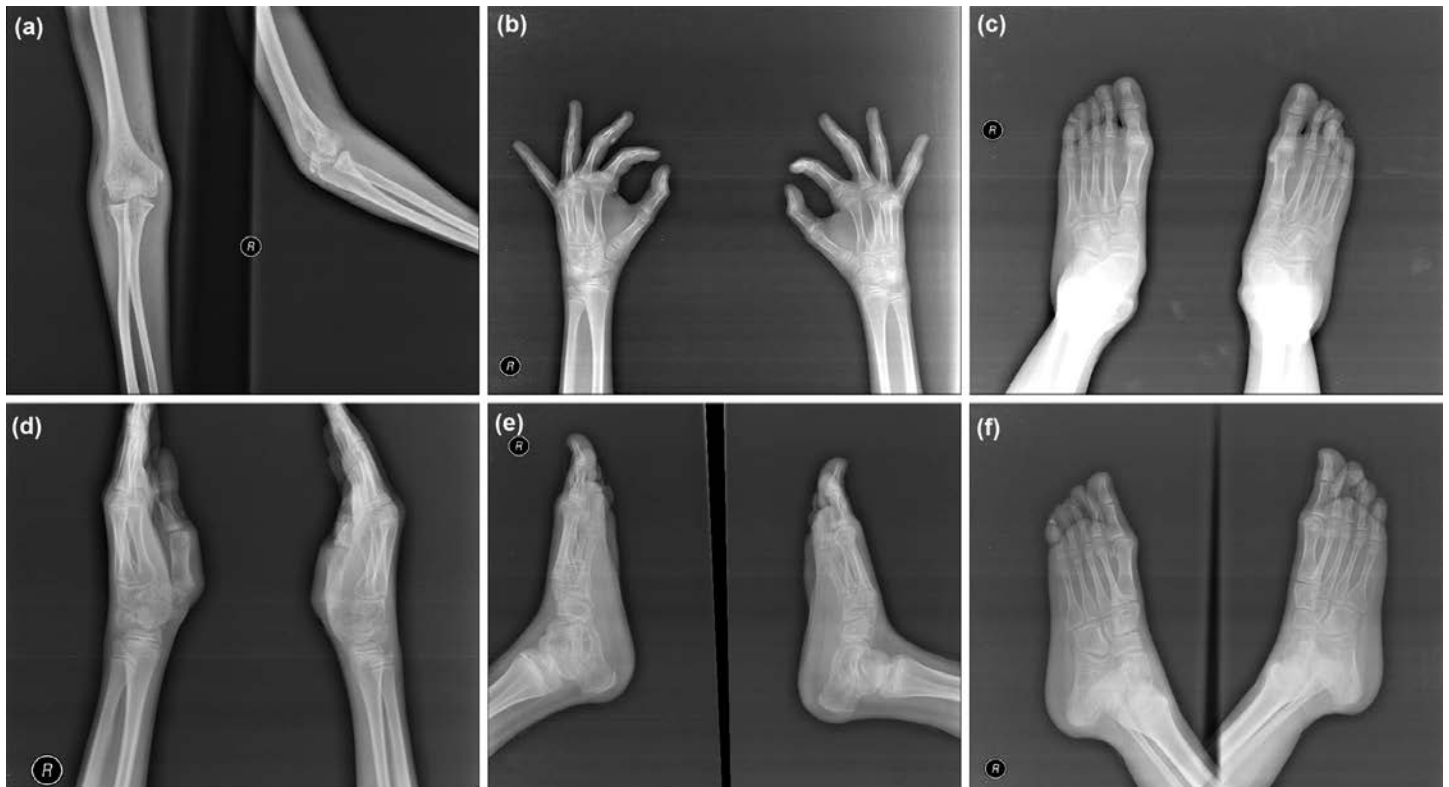
The patient had a history of complaints of difficulty with walking, rapid fatigue, and avoidance of games during childhood, but these complaints decreased over time. Examination of the joints showed joint contractures of both the hands and feet, but all joints were normal by radiological examination (Figure 4:a-f)

A histopathological examination of biopsy material of the elbow plaque lesions was compatible with dermatomyositis (Figure 5). Histopathological examination of 4 mm formalin-fixed punch biopsies from a nodule demonstrated dermal calcification

confirming a diagnosis of calcinosis cutis (Figure 6). X-rays showed calcified lesions in several areas of the fingers (Figure 7). A moderate increase of muscle enzymes was detected in biochemical analyses (creatine kinase [CK], serum aldolase, and lactate dehydrogenase [LDH]).



**Figure 3.** Skin-colored painless nodules on medial phalanx of the little finger (calcinosis cutis)

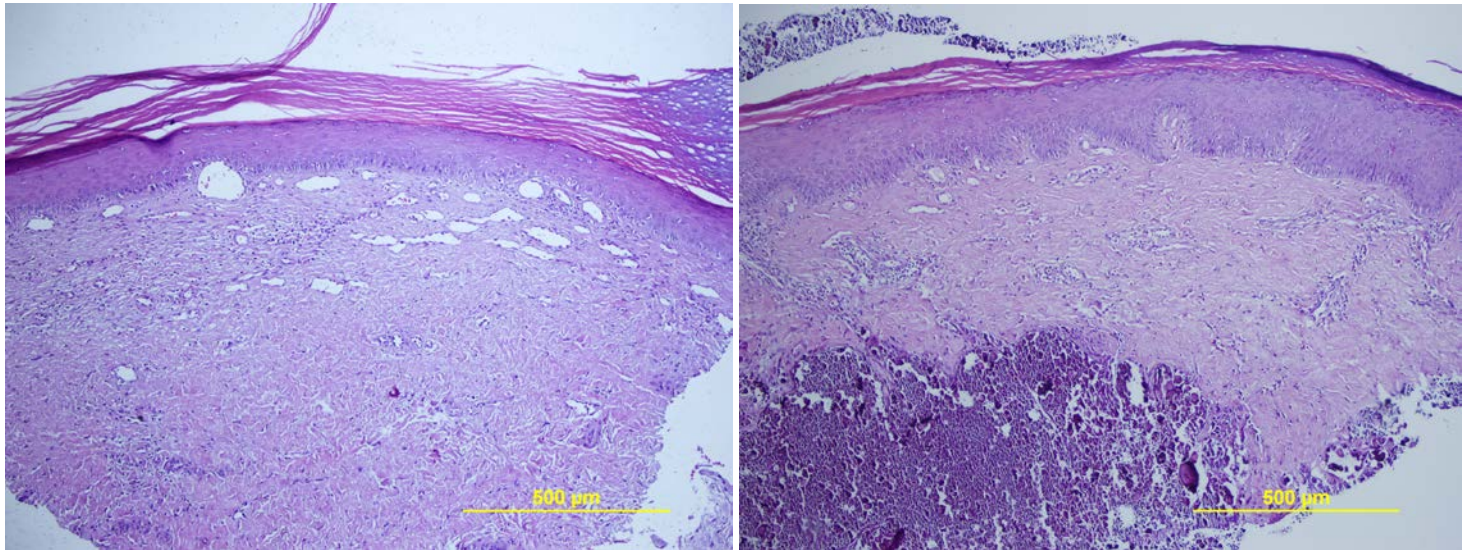


**Figure 4.** Radiological images of the upper extremity, hand, and foot

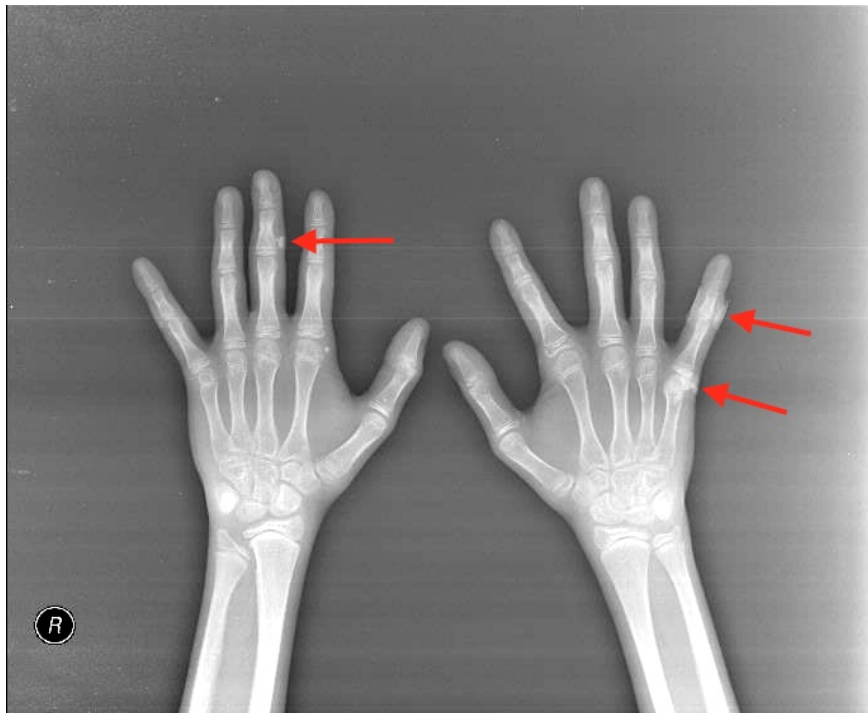
Laboratory examination revealed elevated levels of lactate dehydrogenase (LDH) (492 U/l), creatine kinase (1285 U/l), alanine transaminase (ALT) (118 U/l), and aspartate aminotransferase (AST) (72 U/l). Increased circulating von Willebrand factor antigen, a marker of vasculopathy, was also identified. Autoantibodies including ANA, anti-Mi-2-, anti-Jo-1, and anti-AMA-M2 were negative. All other laboratory data were within normal range. Chest X-ray, electrocardiogram, and echocardiography showed no abnormalities, whereas abdominal ultrasound revealed moderate hepatomegaly

Antibodies to extractable nuclear antigens (anti SS-A [Ro], anti SS-B [La], anti jo-1, anti double-stranded DNA, anti-Sm/RNP, anti-histone, anti-Sm, anti-Scl-70 [anti-topoisomerase I], anti-Mi-2) were within normal limits. Electromyography revealed myopathic changes characterised by increased irritability with spontaneous fibrillation and sharp waves. The patient was diagnosed with JDM based on his history and the clinical and laboratory findings. The patient was given topical steroids and emolient creams for the skin lesions. Intralesional triamcinolone acetonide 5 mg/ml was initiated for the calcinosis cutis.

A nutritionist recommended a protein-rich, calcium-poor diet. Muscle exercises were initiated following physical therapy consultation and the patient consulted an orthopedic specialist for the joint contractures.



**Figure 5.** Histopathological examination demonstrates thinning of the epidermis, hydropic degeneration of the basal layer, papillary dermal edema, and a mild perivascular and periadnexal lymphocytic infiltrate in the superficial and deep dermis (H&Ex40). **Figure 6.** Calcium deposits in the dermis and subcutaneous tissue (H&Ex40)



**Figure 7.** Calcified lesions in several areas of the hands

Juvenile dermatomyositis (JDM) is a multisystemic inflammatory dermatosis, which mainly affects the skin and skeletal muscles [1]. JDM often begins in the first decade of life, but it is very rare for the disease to be diagnosed before the age of 4 years [2]. JDM causes erythematous, edematous papules and plaques on the skin, as well as weakness and inflammation of the skeletal muscles [3]. Patients may also have symptoms related to the gastrointestinal tract and joint involvement [4]. In this article, we report a 12-year-old boy with significant joint involvement and calcinosis cutis, in addition to muscle weakness and typical skin lesions. Although rare, JDM should be kept in mind in pediatric age groups. A multidisciplinary approach to patient management is needed owing to the multisystemic course of the disease.

## References

1. Patwardhan A, Rennebohm R, Dvorchik I, Spencer CH: Is juvenile dermatomyositis a different disease in children up to three years of age at onset than in children above three years at onset? A retrospective review of 23 years of a single center's experience. *Pediatr Rheumatol Online J* 2012, 10(1):34.

2. Chiu YE, Co DO: Juvenile dermatomyositis: immunopathogenesis, role of myositis-specific autoantibodies, and review of rituximab use. *Pediatr Dermatol* 2011, 28(4):357-367.
3. Yun SJ, Lee JB, Kim SJ, Lee SC, Won YH, Kang HC: Calcinosis cutis universalis with joint contractures complicating juvenile dermatomyositis. *Dermatology* 2006, 212(4):401-403.
4. Rosa Neto NS, Goldenstein-Schainberg C: Juvenile dermatomyositis: review and update of the pathogenesis and treatment. *Rev Bras Reumatol* 2010, 50(3):299-312.