

# UC Davis

## Dermatology Online Journal

### Title

Thiotepa hyperpigmentation preceding epidermal necrosis: malignant intertrigo misdiagnosed as Stevens-Johnson syndrome-toxic epidermal necrolysis overlap

### Permalink

<https://escholarship.org/uc/item/1dq125z2>

### Journal

Dermatology Online Journal, 26(2)

### Authors

Choate, Evan A  
Sarantopoulos, George P  
Worswick, Scott D  
et al.

### Publication Date

2020

### DOI

10.5070/D3262047412

### Copyright Information

Copyright 2020 by the author(s). This work is made available under the terms of a Creative Commons Attribution-NonCommercial-NoDerivatives License, available at <https://creativecommons.org/licenses/by-nc-nd/4.0/>

Peer reviewed

# Thiotepa hyperpigmentation preceding epidermal necrosis: malignant intertrigo misdiagnosed as Stevens-Johnson syndrome-toxic epidermal necrolysis overlap

Evan A Choate<sup>1</sup> BA, George P Sarantopoulos<sup>2</sup> MD, Scott D Worswick<sup>3</sup> MD, Allison K Truong<sup>4</sup> MD

Affiliations: <sup>1</sup>Division of Dermatology, Department of Medicine, David Geffen School of Medicine, University of California, Los Angeles, California, USA, <sup>2</sup>Division of Dermatopathology, Department of Pathology and Laboratory Medicine, David Geffen School of Medicine, University of California, Los Angeles, California, USA, <sup>3</sup>Department of Dermatology, Keck School of Medicine, University of Southern California, California, USA, <sup>4</sup>Cedars Dermatology, Cedars Sinai Medical Group, California, USA

Corresponding Author: Allison K Truong MD, 99 La Cienega Boulevard #202, Beverly Hills, CA 90069, Tel: 310-385-3300, Email: [allisontruongmd@gmail.com](mailto:allisontruongmd@gmail.com)

## Abstract

Thiotepa is a common alkylating agent known to precipitate cutaneous reactions consistent with toxic erythema of chemotherapy, including erythema and hyperpigmentation. Herein, we describe an atypical case of malignant intertrigo involving preferential erythema and desquamation not only of skin folds but also of occluded areas after thiotepa-based conditioning. The diagnosis was complicated by concurrent stomatitis and oral petechiae in the setting of autologous stem cell transplant 11 days prior for diffuse large B-cell lymphoma. Histopathological examination from two cutaneous sites demonstrated epidermal dysmaturation and eccrine gland necrosis consistent with thiotepa-induced desquamation and not Stevens-Johnson syndrome or graft-versus-host-disease. Malignant intertrigo can present with extensive cutaneous involvement, as evidenced by our patient who had 25% body surface area affected. Mucosal involvement is common with most chemotherapeutic regimens and its presence should not deter the astute clinician from consideration of a diagnosis of toxic erythema of chemotherapy. No further interventions were needed and the patient healed spontaneously.

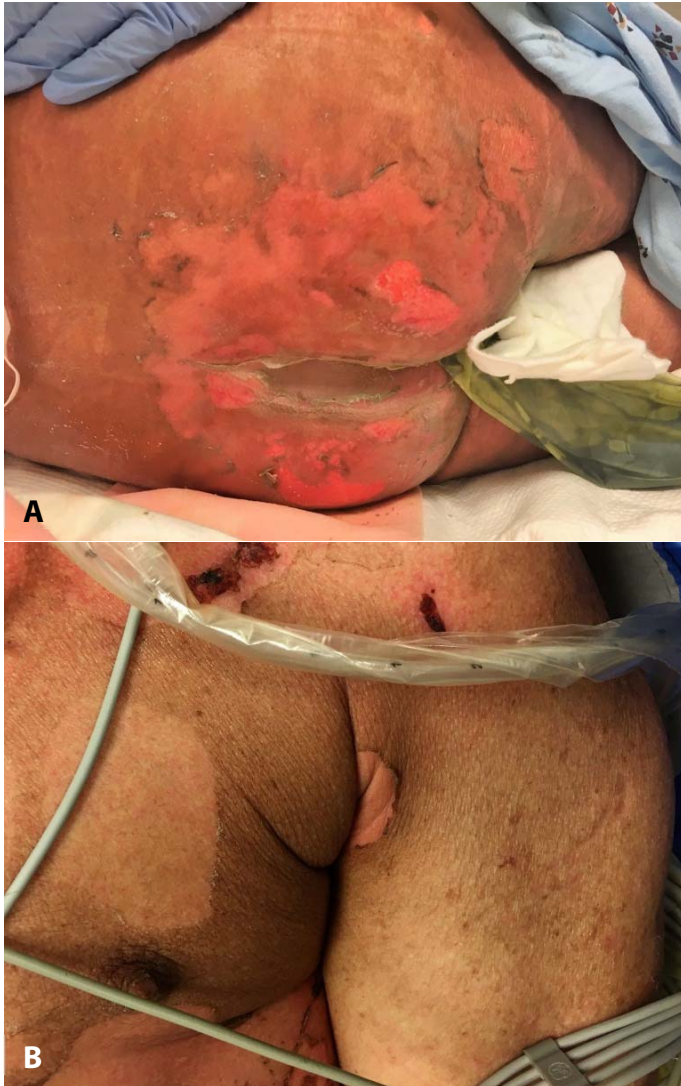
*Keywords: thiotepa, toxic erythema of chemotherapy, malignant intertrigo, mucositis, epidermal necrosis, adverse drug reaction, Stevens-Johnson syndrome, toxic epidermal necrolysis, lymphoma, stem cell transplant*

## Introduction

Toxic erythema of chemotherapy (TEC) caused by thiotepa typically manifests as localized cutaneous erythema, hyperpigmentation, or oropharyngeal mucositis and stomatitis [1-5]. Although thiotepa toxicity is known to demonstrate a preference for intertriginous sites, a clinical presentation known as malignant intertrigo [6], to our knowledge there has not previously been reported a case involving extensive areas of intertriginous and occluded areas so as to mimic early Stevens-Johnson syndrome (SJS) or toxic epidermal necrolysis (TEN). Herein, we present a patient with SJS-like mucositis, erythema, and desquamation in occluded areas. The patient had been undergoing thiotepa-based conditioning chemotherapy for diffuse large B-cell lymphoma and the eruption was consistent with thiotepa-induced malignant intertrigo.

## Case Synopsis

A 71-year-old man with diffuse large B-cell lymphoma involving the right frontal operculum was admitted for conditioning chemotherapy and autologous stem cell transplant (ASCT). The patient had completed two initial cycles of cytarabine and thiotepa, TBC (thiotepa, busulfan, and cyclophosphamide) conditioning, and subsequent ASCT. A dermatology consultation was requested eleven days post-transplantation for evaluation for



**Figure 1.** Day of presentation: dusky erythema and hyperpigmentation around sites of desquamation. **A)** buttocks, and **B)** left axilla.

presumed SJS-TEN overlap. History from family members confirmed that previous to desquamation the patient had localized erythema in areas of occlusion.

Initial examination revealed an afebrile, ill-appearing, intubated, supine man with dusky erythema and overlying superficial erosions on the neck, bilateral axillae, back, buttocks, and thighs involving about 25% of his body surface area (BSA), (**Figure 1**). In the mouth, scattered petechiae on the hard palate and crusting along the superior labial mucosa were found. Laboratory tests were notable for pancytopenia, including a white blood cell count of  $3.85 \times 10^3/\mu\text{L}$  and an absolute lymphocyte count of

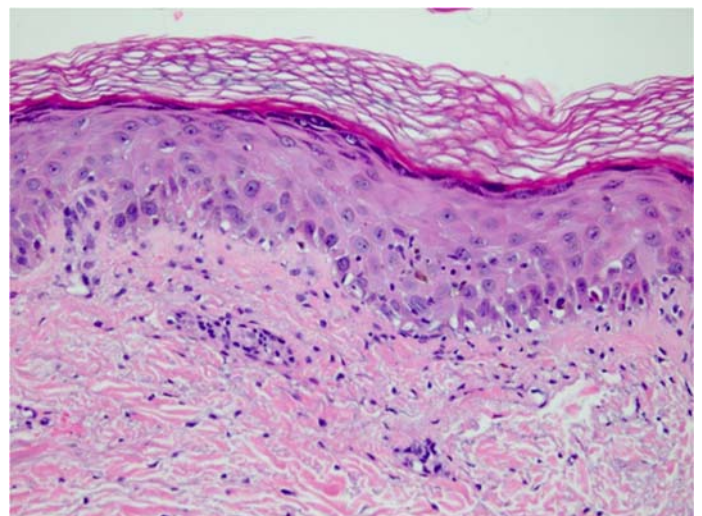
$0.4 \times 10^3/\mu\text{L}$ , elevated BUN (52mg/dL), and depressed liver function enzymes (ALT 5U/L; AST 12U/L).

Microbiology results (viral, bacterial, atypical mycobacterial, and fungal cultures of blood and tissue) showed no growth. Two punch biopsies (from the mid back and thigh) were performed given initial concern for drug induced hypersensitivity syndrome, SJS/TEN and early graft versus host disease (GVHD). Biopsies revealed mild superficial perivascular mixed-inflammatory infiltrate, with notable absence of eosinophils (**Figure 2**). Scattered apoptotic foci and keratinocyte and eccrine sweat gland necrosis accompanied consistent epidermal dysmaturation. No intracellular inclusions were seen. Thus, based on clinical and histopathologic evaluation, a diagnosis of thiotepa-induced malignant intertrigo was made.

Given the self-healing nature of the condition, no further treatment was recommended. Over the subsequent three weeks, the skin desquamated and then re-epithelialized.

## Case Discussion

Thiotepa is a common alkylating agent for the treatment of lymphomas, central nervous system tumors, and pediatric solid tumors long identified as



**Figure 2.** Hematoxylin-eosin skin biopsy pathology revealed interface dermatitis with epidermal dysmaturation and foci of keratinocyte necrosis consistent with a thiotepa-induced drug reaction, 200x.

a cause of dermatologic cytotoxicity, or toxic erythema of chemotherapy (TEC), [1]. One retrospective study of 38 pediatric patients revealed a distinct sequence and distribution to the skin reactions, which progress from mild erythema to generalized erythema, hyperpigmentation, and desquamation in intertriginous areas; truncal and occluded areas may also be involved [3]. This constellation of painful erythema, maceration, and subsequent erosion and desquamation localizing to intertriginous and occluded regions defines the unique pattern of TEC known as malignant intertrigo [6]. Our patient followed the well-documented natural course of thiotepa-induced malignant intertrigo. However, in addition to the intertriginous distribution of affected skin the patient also had involvement of occluded areas and more broad involvement of 25% of his BSA. Hyperpigmented patches, edematous plaques, and scaly surface changes have been noted in other reports but were not prominent in this case.

Preferential destruction at occluded zones is believed to reflect accumulation and excretion of various chemotherapeutics through eccrine sweat glands [2]. Consistent with this feature is the eccrine gland necrosis noted on histologic examination. Described in the context of various underlying malignancies and chemotherapeutics (most notably doxorubicin), malignant intertrigo is a self-limited condition appropriately managed with symptomatic control, wound care, and in severe cases, adjustment of the chemotherapy regimen [6, 7]. Our patient was treated with supportive care alone utilizing xeroform

gauze and his eruption resolved over the ensuing weeks.

Initial concern for SJS/TEN and GVHD was high in this patient given the mucosal involvement atypical of classic malignant intertrigo. Unlike toxic erythema of chemotherapy, Stevens-Johnson syndrome-spectrum disorders follow a malignant course with up to 34% mortality reported in some studies and necessitates immediate withdrawal of offending agent(s), [8]. Thus, the histopathologic distinction between thiotepa-induced skin reactions and SJS or TEN is crucial for maintaining optimal drug regimens and evaluating patient prognosis. Herein, a lack of partial-to-full thickness epidermal necrosis or satellite lymphocyte necrosis made SJS or GVHD unlikely diagnoses, respectively.

## Conclusion

This case highlights a presentation of thiotepa-induced toxic erythema, including synchronous malignant intertrigo and mucositis, that mimicked early SJS. Malignant intertrigo from thiotepa should be distributed predominantly in occluded areas such as the neck, axillae, inner thighs, and, for critically-ill patients in supine position, the back, and thus may cover an extensive BSA. Similarly, the presence of mucosal lesions and stomatitis should not deter clinical consideration for chemotherapy toxicity.

## Potential conflicts of interest

The authors declare no conflicts of interests.

## References

1. Bologna JL, Cooper DL, Glusac EJ. Toxic erythema of chemotherapy: a useful clinical term. *J Am Acad Dermatol*. 2008;59:524-9. [PMID: 18694683].
2. Horn TD, Beveridge RA, Egorin MJ, Abeloff MD, Hood AF. Observations and proposed mechanism of N,N',N''-triethylenethiophosphoramidate (thiotepa)-induced hyperpigmentation. *Arch Dermatol*. 1989;125:524-7. [PMID: 2539058].
3. Rosman IS, Lloyd BM, Hayashi RJ, Bayliss SJ. Cutaneous effects of thiotepa in pediatric patients receiving high dose chemotherapy with autologous stem cell transplantation. *J Am Acad Dermatol*. 2008;58:575-8. [PMID: 18249465].
4. Przepiorka D, Dimopoulos M, Smith T, et al. Thiotepa, busulfan, and cyclophosphamide as a preparative regimen for marrow transplantation: risk factors for early regimen-related toxicity. *Ann Hematol*. 1994;68:183-8. [PMID: 8003559].
5. Finlay JL, August C, Packer R, et al. High-dose multi-agent chemotherapy followed by bone marrow "rescue" for malignant astrocytomas of childhood and adolescence. *J Neurooncol*. 1990;9:239-48. [PMID: 1964962].
6. Smith SM, Milam PB, Fabbro SK, Gru AA, Kaffenberger BH. Malignant intertrigo: a subset of toxic erythema of chemotherapy requiring recognition. *JAAD Case Rep*. 2016;2:476-81. [PMID: 27981223].
7. Totsuka M, Watanabe Y, Asai C, et al. Case of severe bullous erythema including intertrigo-like eruptions with angioedema induced by pegylated liposomal doxorubicin. *J Dermatol*. 2019;46:535-9. [PMID: 31021010].

8. Sekula P, Dunant A, Mockenhaupt M, et al.. Comprehensive survival analysis of a cohort of patients with Stevens-Johnson syndrome and toxic epidermal necrolysis. *J Invest Dermatol.* 2013;133:1197-204. [PMID: 23389396].