

# UC Davis

## Dermatology Online Journal

### Title

Secukinumab-associated localized granuloma annulare (SAGA): a case report and review of the literature

### Permalink

<https://escholarship.org/uc/item/1nd6p108>

### Journal

Dermatology Online Journal, 26(8)

### Authors

Fox, JD  
Aramin, H  
Ghiam, N  
et al.

### Publication Date

2020

### DOI

10.5070/D3268049888

### Copyright Information

Copyright 2020 by the author(s). This work is made available under the terms of a Creative Commons Attribution-NonCommercial-NoDerivatives License, available at <https://creativecommons.org/licenses/by-nc-nd/4.0/>

Peer reviewed

# Secukinumab-associated localized granuloma annulare (SAGA): a case report and review of the literature

JD Fox<sup>1</sup> MD, H Aramin<sup>2</sup> MD, N Ghiam<sup>1</sup> MD MHSc, JB Freedman<sup>1</sup> MD, P Romanelli<sup>1</sup> MD

Affiliations: <sup>1</sup>Dr. Phillip Frost Department of Dermatology and Cutaneous Surgery, University of Miami, Miller School of Medicine, Miami, Florida, USA, <sup>2</sup>Department of Pathology, Danbury Hospital, Danbury, Connecticut, USA

Corresponding Author: Dr. Paolo Romanelli, 1600 NW 10<sup>th</sup> Avenue, RMSB Building, Room 2023 C, Miami, FL, 33136, Tel: 305-243-5523, Fax: 305-243-5810, Email: [promanelli@med.miami.edu](mailto:promanelli@med.miami.edu)

## Abstract

Granuloma annulare (GA) is a benign, usually self-limited inflammatory skin dermatosis characterized clinically by pink-red to brown dermal papules or annular plaques. The main histologic feature is the presence of palisading or interstitial granulomas composed of necrobiotic collagen, elastic fibers, and mucin surrounded by a lymphohistiocytic infiltrate. Granuloma annulare is commonly associated with trauma, infections, diabetes mellitus, dyslipidemia, malignancy, thyroid disease, and a variety of medications. Two cases of GA have been reported in association with the use of secukinumab, a monoclonal antibody directed against interleukin 17A (IL17A), for the treatment of moderate-to-severe plaque psoriasis. We report the third case of secukinumab-associated GA in a 52-year-old woman with a history of diabetes mellitus type II, dyslipidemia, and non-alcoholic steatohepatitis. After four months of therapy with secukinumab, she presented with pink papules coalescing to plaques involving the antecubital fossae. Histology demonstrated a lymphohistiocytic palisading granuloma with central necrobiotic collagen and mucin, consistent with GA. Physicians should be aware of the possibility of GA developing in patients receiving secukinumab, especially in those with predisposing factors for GA. A better understanding of secukinumab-associated GA may lead to discoveries in GA pathogenesis and reveal broader immunomodulatory effects of secukinumab.

*Keywords: psoriasis, secukinumab, granuloma annulare*

## Introduction

Granuloma annulare (GA) is a benign, self-limited, inflammatory skin dermatosis. It is characterized clinically by pink-red to brown or violaceous papules or annular plaques. It was first described in 1895 by Dr. Colcett Fox, but was named by Dr. Radcliffe Crocker in 1902 and is more prevalent among women [1]. Granuloma annulare is classified into clinical variants including localized (75% of cases, typically on dorsal hands or feet), [1], generalized annular, papular and atypical, subcutaneous, patch, and perforating. Histologically, interstitial (three times more common) or palisading granuloma with focal degeneration of collagen and elastic fibers, mucin, and a lymphohistiocytic infiltrate are seen [2,3]. Granuloma annulare associations include trauma, infections (human immunodeficiency virus, Epstein-Barr Virus, varicella zoster virus, hepatitis B and C viruses, and tuberculosis), diabetes mellitus (DM), dyslipidemia, various malignancies, thyroid disease, and medications (including tumor necrosis factor (TNF) inhibitors), [2-5]. Granuloma annulare has also been associated with the use of secukinumab, a human immunoglobulin G1 monoclonal antibody targeting interleukin 17A, **Table 1** [6,7]. Herein, we report the third case of secukinumab-associated GA (SAGA).

## Case Synopsis

A 52-year-old woman with a past medical history of psoriasis, psoriatic arthritis, DM type II, dyslipidemia, and non-alcoholic steatohepatitis was seen for

**Table 1.** Reported Cases of Secukinumab Associated Granuloma Annulare

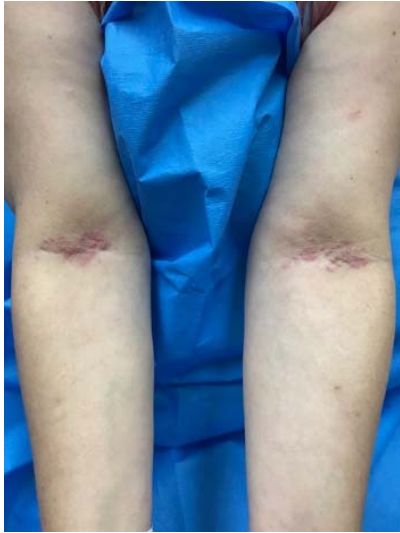
	Author Year	Sex, Race	Age	Comorbidities	Medications	Duration of Secukinumab treatment prior to GA onset	GA type Distribution	Granuloma Pathology	Follow up
Case 1	Bonomo et al. 2017 [6]	Woman White Hispanic	60	Hypothyroid fibromyalgia Meniere's disease	Methotrexate Levothyroxine Omeprazole Duloxetine	2 weeks	Disseminated Tan-pink papules Shoulders, back, neck	Interstitial Granuloma	Mild improvement with clobetasol propionate 0.05% after two weeks, and marked improvement 8 months after discontinuing Secukinumab
Case 2	Clark et al. 2018 [7]	Woman White	69	DM Hyperlipidemia	Lisinopril Metformin Pravastatin Citalopram Alprazolam	5 months	Disseminated Pink papules and annular plaques Trunk and proximal lower extremities	Palisading granuloma	No improvement with 3 months of rifampin, levofloxacin and minocycline. Secukinumab was discontinued and Etanercept started with resolution of GA at 6 weeks.
Case 3	Current study	Woman White Hispanic	52	DM, dyslipidemia, and non-alcoholic steatohepatitis		1 month	Localized Antecubital fossae	Palisading Granuloma	Worsening of GA with continued secukinumab and topical hydrocortisone 2.5% cream at 6 months follow-up

follow up four months after starting secukinumab for psoriasis. She complained of a new pruritic rash on the antecubital fossae for one month. The patient denied any other recent changes to her medications. On physical examination, symmetric blanching, pink, smooth papules coalescing to plaques were noted on antecubital fossae (**Figure 1**).

Biopsy demonstrated a palisading lymphocytic and histiocytic infiltrate surrounding necrobiotic collagen (**Figure 2A**). Colloidal iron stain was positive for mucin (**Figure 2B**).

Granuloma annulare was diagnosed and treated with hydrocortisone 2.5% cream. At six months follow up, the lesions had progressed to annular and



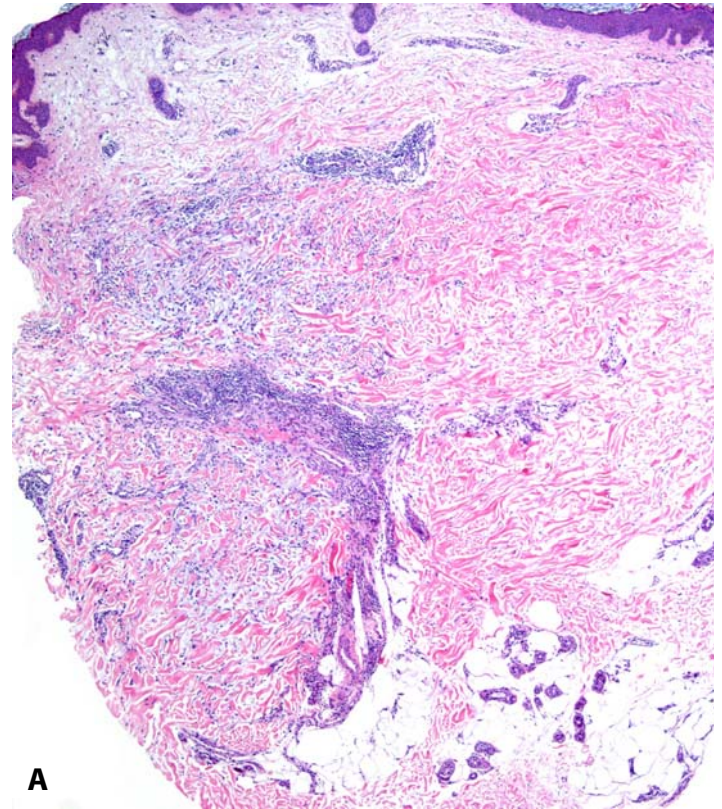


**Figure 1.** Pink blanching papules on antecubital fossae coalescing into plaques.

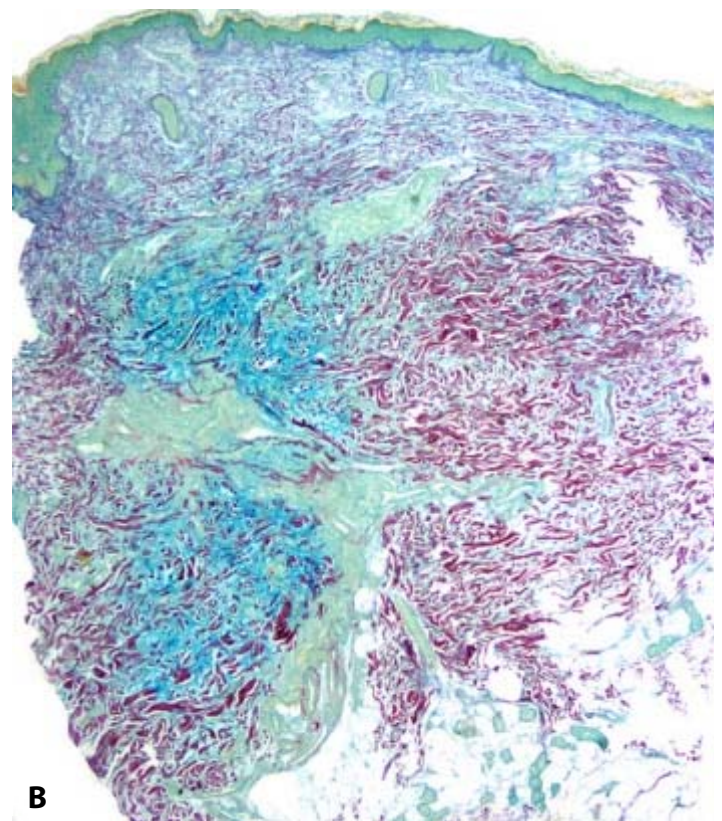
arcuate pink plaques on the forearms and the right dorsal hand (**Figure 3**). This plaque was treated with 0.5ml of intralesional triamcinolone 10mg/ml. Secukinumab was continued owing to excellent clearance of psoriatic lesions. The patient returned six months after the first injection and received two cc of 20mg/ml intralesional triamcinolone because of induration and itching of the lesion. At six-month follow up, there was improvement of the itch and the patient did not require additional injections, although the pink-red and indurated plaque on the hand remained. She has been treated with secukinumab for a total of 20 months thus far with complete response of her psoriasis.

### Case Discussion

There are various theories as to the underlying etiology of GA. Histologic findings support a delayed T-helper one (Th1) cell-mediated hypersensitivity reaction. CD3+ T-cells expressing interferon gamma and macrophages producing TNF (both Th1 cytokines) and cytokine-regulated matrix metalloproteinases (MMPs) 2 and 9 are seen in GA [8]. This suggests that Th1-driven inflammation leads to activation of MMPs causing tissue destruction. Additionally, IL2 transcription is upregulated in GA [9], further supporting the role of a T-cell mediated process [1].

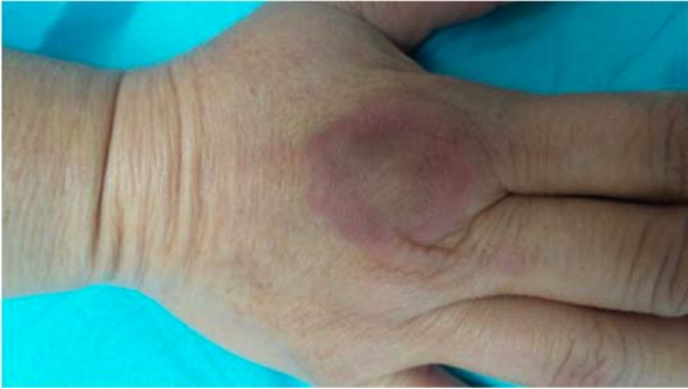


**A**



**B**

**Figure 2.** Antecubital skin biopsy reveals palisading of histiocytes and lymphocytes around a focus of necrobiosis and increased mucin deposition. **A)** H&E, 4x. **B)** Colloidal iron highlights the increased connective tissue mucin, 4x.



**Figure 3.** Later progression of lesions in the same patient. Pink papules coalesced into annular plaques on the dorsum of one hand.

Counterintuitively, anti-TNF agents have been reported to be associated with GA [10]. Patients in two separate studies developed GA after receiving infliximab, adalimumab, or etanercept for rheumatoid arthritis [10]. It was suggested that anti-TNF agents induce autoreactive Th1 cells to cause tissue destruction via unknown “autoimmune mechanisms” owing to an unknown trigger [10,11]. Conversely, infliximab has been shown to significantly improve recalcitrant disseminated GA [12].

The underlying mechanism of SAGA remains elusive. Th17 cells are pro-inflammatory and produce IL17A and IL17F. The Th1-Th17 interaction is complex—

they upregulate each other and can independently cause autoimmune disease [13]. Therefore, targeting one may still allow for upregulation of the other, resulting in various, sometimes paradoxical, disease manifestations [13]. It is conceivable that blocking IL17A may result in upregulation of Th1 reactions and the development of GA [13].

Secukinumab was approved in 2015 for the treatment of moderate-to-severe plaque psoriasis by selectively binding to IL17A and preventing its interaction with the IL17 receptor. The most common adverse events are nasopharyngitis, diarrhea, and upper respiratory infection, with urticaria and infection being the most common cutaneous adverse reactions [14,15].

## Conclusion

In this article, we report a third case of GA in a patient treated with secukinumab. All reported cases have had predisposing factors such as DM, dyslipidemia, and thyroid disease. Physicians should be aware of this important reactive phenomenon and its associations. A better understanding of SAGA will improve our understanding of the pathophysiology of GA and may lead to discovery of novel therapeutic solutions for GA.

## Potential conflicts of interest

The authors declare no conflicts of interests.

## References

1. Wang J, Khachemoune A. Granuloma Annulare: A Focused Review of Therapeutic Options. *Am J Clin Dermatol*. 2018;19:333-44. [PMID: 29230666].
2. Thornsberry LA, English JC. Etiology, diagnosis, and therapeutic management of granuloma annulare: an update. *Am J Clin Dermatol*. 2013;14:279-90. [PMID: 23696233].
3. Mangold AR, Cumsy HJ, Costello CM, et al. Clinical and histopathologic features of paraneoplastic granuloma annulare in association with solid organ malignancies: A case-control study. *J Am Acad Dermatol*. 2018;79:913-20. e1. [PMID: 29920319].
4. Vazquez-Lopez F, Gonzalez-Lopez MA, Raya-Aguado C, Perez-Oliva N. Localized granuloma annulare and autoimmune thyroiditis: a new case report. *J Am Acad Dermatol*. 2000;43:943-5. [PMID: 11044830].
5. Willemsen MJ, de Coninck AL, Jonckheer MH, Roseeuw DI. Autoimmune thyroiditis and generalized granuloma annulare: remission of the skin lesions after thyroxine therapy. *Dermatology*. 1987;175:239-43. [PMID: 3678551].
6. Bonomo L, Ghoneim S, Levitt J. A case of granuloma annulare associated with secukinumab use. *Case Rep Dermatol Med*. 2017;2017. [PMID: 28611928].
7. Clark ML, Tobin CA, Sutton A, Missall TA. Granuloma Annulare in the Setting of Secukinumab. *Case Rep Dermatol Med*. 2018;2018. [PMID: 29805815].
8. Fayyazi A, Schweyer S, Eichmeyer B, et al. Expression of IFN $\gamma$ , coexpression of TNF $\alpha$  and matrix metalloproteinases and apoptosis of T lymphocytes and macrophages in granuloma annulare. *Arch Dermatol Res*. 2000;292:384-90. [PMID: 10994772].
9. Mempel M, Musette P, Flageul B, et al. T-cell receptor repertoire and cytokine pattern in granuloma annulare: defining a particular type of cutaneous granulomatous inflammation. *J Invest Dermatol*. 2002;118:957-66. [PMID: 12060389].
10. Voulgari PV, Markatseli TE, Exarchou SA, et al. Granuloma annulare induced by anti-tumour necrosis factor therapy. *Ann Rheum Dis*. 2008;67:567-70. [PMID: 17728330].
11. Exarchou S, Voulgari P, Markatseli T, et al. Immune-mediated skin lesions in patients treated with anti-tumour necrosis factor alpha inhibitors. *Scand J Rheumatol*. 2009;38:328-31. [PMID: 19579151].
12. Hertl MS, Haendle I, Schuler G, Hertl M. Rapid improvement of recalcitrant disseminated granuloma annulare upon treatment

- with the tumour necrosis factor-alpha inhibitor, infliximab. *Br J Dermatol*. 2005;152:552-5. [PMID: 15787827].
13. Damsker JM, Hansen AM, Caspi RR. Th1 and Th17 cells: adversaries and collaborators. *Ann N Y Acad Sci*. 2010;1183:211-21. [PMID: 20146717].
  14. US FDA. Fda approves new psoriasis drug cosentyx: 2015, January 21 Available from: <https://wayback.archive-it.org/7993/20170112023818/http://www.fda.gov/NewsEvents/Newsroom/PressAnnouncements/ucm430969.htm>.. Accessed on January 22, 2020.
  15. Novartis Pharmaceuticals Corporation. Highlights of prescribing information 2018, January. Available from: <https://www.pharma.us.novartis.com/sites/www.pharma.us.novartis.com/files/cosentyx.pdf>. Accessed on January 22, 2020.