

UC Davis
Dermatology Online Journal

Title

Skin wrinkling of the upper arms: a case of mid-dermal elastolysis

Permalink

<https://escholarship.org/uc/item/1ws2x7fg>

Journal

Dermatology Online Journal, 26(4)

Authors

Hoang, Nguyen
Jibbe, Atieh
Fraga, Garth
et al.

Publication Date

2020

DOI

10.5070/D3264048350

Copyright Information

Copyright 2020 by the author(s). This work is made available under the terms of a Creative Commons Attribution-NonCommercial-NoDerivatives License, available at <https://creativecommons.org/licenses/by-nc-nd/4.0/>

Peer reviewed

Skin wrinkling of the upper arms: a case of mid-dermal elastolysis

Nguyen Hoang BS, Atieh Jibbe MD, Garth Fraga MD, Anand Rajpara MD

Affiliations: Department of Dermatology, University of Kansas Medical Center, Kansas City, Kansas, USA

Corresponding Author: Anand Rajpara MD, Department of Dermatology, University of Kansas Medical Center, 3901 Rainbow Boulevard, Mail Stop #2025, Kansas City, KS 66160, Tel: 913-588-6028, Fax: 913-588-8300, Email: arajpara@kumc.edu

Abstract

Mid-dermal elastolysis is a rare acquired elastic tissue disorder with about 100 cases reported in the literature. It is characterized by localized patches of finely wrinkled skin on the shoulder and upper extremities and a band-like loss of elastic tissue in the mid-dermal layer on biopsy. Some patients may have symptoms of discomfort, erythema, and/or pruritis. Mid-dermal elastolysis is predominantly seen in young to middle-aged Caucasian females and extensive skin involvement may lead to cosmetic concerns. Furthermore, it is important to rule out other disorders of elastic fiber that are associated with systemic involvement. We present a case of MDE, discuss the differential diagnosis, and describe characteristic clinical features and histology findings of each condition.

Keywords: mid-dermal elastolysis, disorders of elastic fibers, elastophagocytosis, elastic tissue disorders

Introduction

Mid-dermal elastolysis (MDE) is a rare acquired elastic tissue disorder characterized by a localized area of fine papules appearing as wrinkled skin. The lesions mainly affect the shoulders, trunk, and upper extremities; the condition is predominantly seen in Caucasian females. The clinical presentation is variable and can present as finely wrinkled skin, perifollicular papular protrusions, or reticular erythematous patches with telangiectasia. Although MDE has a good prognosis, a biopsy is essential to rule out other elastic fiber disorders that are potentially dangerous. Characteristic biopsy findings

for each elastic fiber disorder can be subtle and difficult to distinguish from one another. We describe a case of MDE with characteristic findings on biopsy to help confirm the diagnosis. Because of the rarity of MDE, our goal is to provide awareness of the condition and familiarize clinicians with the characteristic findings that distinguish MDE from other similar conditions.

Case Synopsis

A 28-year-old woman presented to the dermatology clinic with a one-year history of progressive wrinkling of her skin on both sides of her shoulders. It initially started as multiple small papules but had been slowly spreading. The lesions were occasionally erythematous and pruritic, but pruritus was only mild and quickly resolved on its own. Past medical history was unremarkable and family history was negative for autoimmune disorders. She followed a healthy lifestyle and enjoyed being active outdoors. Physical examination revealed tiny discrete, skin-colored perifollicular papules localized on both shoulders (**Figure 1**). The papules were soft with no scaling or induration. Biopsy with hematoxylin-eosin revealed a normal epidermis with mild perivascular lymphocytic infiltrates (**Figure 2**). Verhoeff-van Gieson stain showed marked loss of elastic tissue in a band-like distribution in the mid reticular dermis. Elastic fibers were unaffected in the papillary and lower reticular dermis, as well as around appendages (**Figure 3**). These findings are characteristic for the diagnosis of mid-dermal elastolysis. After discussing the lack of efficacious treatment for the condition, the patient agreed on a trial of clobetasol cream and close follow up.

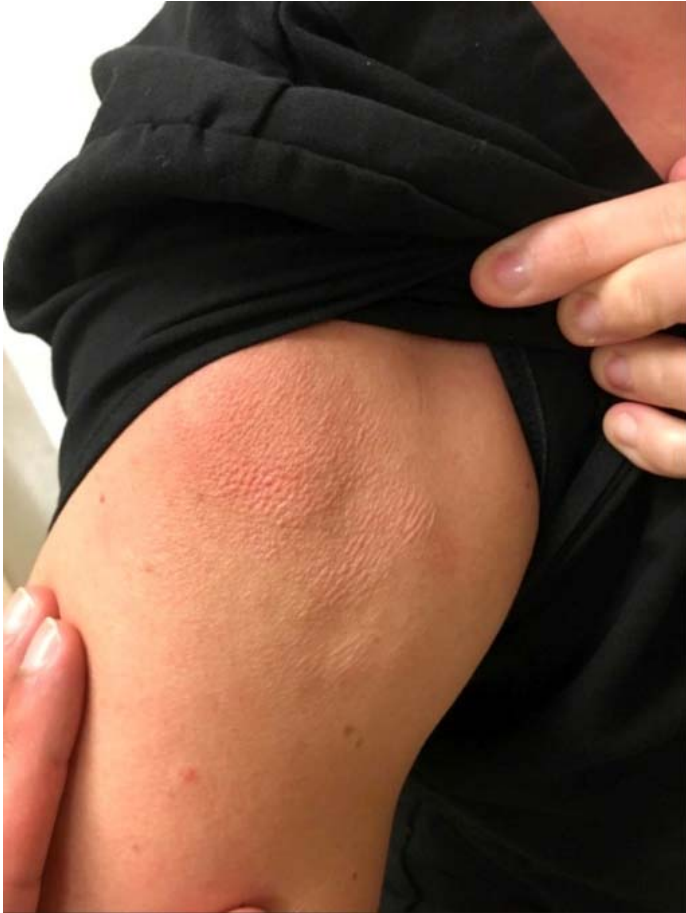

Figure 1. Small, flesh-colored papules of fine wrinkling appearance of the right shoulder. Similar lesions were noted on the left shoulder.

Case Discussion

Since the first reported case described by Wood in 1977, around 100 cases of MDE have been reported in the literature [1]. Mid-dermal elastolysis is characterized by the loss of elastic fiber in the mid-dermal layer seen clinically as small, flesh-colored papules of finely wrinkled skin primarily affecting the shoulders, trunk, and upper extremities [2]. Mid-dermal elastolysis can be subcategorized into three types based on the distribution of the lesions clinically. Type I is the most common variant and presents as symmetrically fine wrinkling following the lines of cleavage. Discrete protrusions of perifollicular papules are seen in Type II lesions. The recently discovered Type III variant are characterized by erythematous reticular patches with telangiectasia. Patients are generally asymptomatic, although about half of cases have mild intermittent erythema, pruritis, and/or burning. Approximately

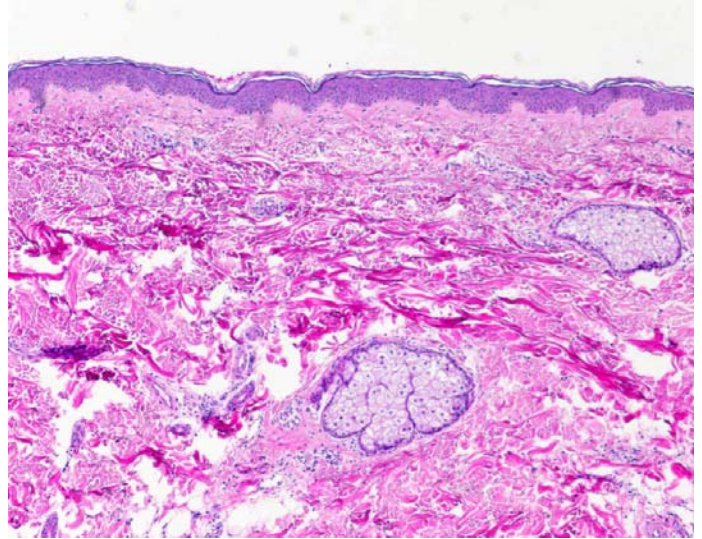


Figure 2. Hematoxylin-eosin stained revealed mild perivascular inflammation, otherwise benign findings; original magnification, 40x.

87% of cases had lesions involving the trunk and proximal extremities whereas the face was generally spared. Additionally, the majority of cases were seen in Caucasian females between the ages of 30 and 50 [2, 3]. Mid-dermal elastolysis has been linked with other autoimmune disorders, such as lupus erythematosus, antiphospholipid syndrome, rheumatoid arthritis, autoimmune thyroid disorders, type I diabetes, and dermatitis herpetiformis [2, 3]. Other risk factors include pregnancy, use of oral contraceptives, and smoking. Furthermore, half of

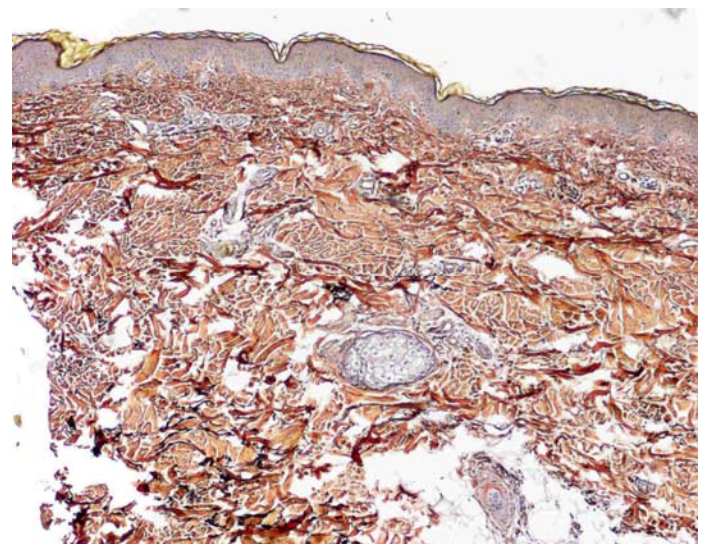


Figure 3. Immunohistochemical staining with Verhoeff-van Gieson Stain showing band-like loss of elastic fibers in the mid-dermis. The papillary and deep reticular dermis were unaffected; original magnification, 40x.

the cases reported had significant sun-exposure [2, 3]. However, the role of sun-exposure as a risk factor remains unknown, as the face is rarely affected.

Histopathologic findings of a band-like absence of elastic fibers in the mid-dermis and normal elastic tissue present in the papillary dermis, lower reticular dermis, and perifollicular areas. An early stage lesion shows perivascular lymphocytic infiltrations with histiocytes and multinucleated giant cells scattered throughout. Elastophagocytosis occasionally can be seen [4]. Older lesions are characterized by absence of inflammatory cells and slightly thickened dermal collagen [5]. Specimen staining for elastic fiber is required to confirm the diagnosis of MDE. In our case we performed a Verhoeff-van Gieson stain, but other common stains include orcein, aldehyde-fuchsin, and Weigert stain. Immunohistochemistry demonstrates increased concentration of CD34+ and CD68+ cells. Multiple studies have reported increased levels of matrix metalloproteinases and reduced expression of lysyl oxidase-like 2 protein, suggesting abnormal degradation of elastic fibers and impaired synthesis of new ones likely plays a role of pathogenesis [2, 5-7].

The differential diagnosis includes other elastic tissue disorders such as anetoderma, pseudoxanthoma elasticum (PXE), PXE-like papillary dermal elastolysis (PXE-PDE), and cutis laxa. Anetoderma presents as flaccid skin lesions on the trunk and upper extremity, but the lesions are smaller and more localized compared to MDE. Additionally, anetoderma primarily damages the papillary and mid-reticular dermis. Pseudoxanthoma elasticum presents as yellow papules with "cobblestoning" that develops on the lateral neck and flexural folds. Ocular and cardiovascular symptoms are common. A von Kossa stain for calcium is used to diagnose PXE by characteristic findings of basophilic substance containing calcium

deposits and clumps of irregular elastic fiber. Pseudoxanthoma elasticum-PDE clinically resembles PXE, but systemic involvement is absent. Histopathology reveals a band-like loss of elastic fibers in the papillary dermis, whereas MDE affects the mid-dermal layer. Calcium deposition does not occur in PXE-PDE. Cutis laxa exhibits a generalized loose, saggy skin resembling the skin of the elderly. Systemic symptoms are common and can involve any organ. Widespread loss of elastic fibers throughout the dermis on histopathology is characteristic of cutis laxa [2, 4, 8].

Currently, there are no proven treatments for mid-dermal elastolysis. Use of topical and systemic corticosteroids, tretinoin, colchicine, chloroquine, and clofazimine have been tried but showed no benefits. Proper sun protection is highly recommended. Soybean extract and eicosapentanoic acid were shown to prevent degradation of elastic tissue and may be beneficial for patients with MDE [3]. A recent case described a 15-year-old patient with MDE who was successfully treated with mycophenolate mofetil [9].

Conclusion

Besides the increased risk of autoimmune disorders MDE is considered to be benign. However, because MDE has a predilection for young females and affects the shoulder and upper extremities, the development of extensive lesions may have a strong negative impact for patients psychosocially. Therefore, providers should continue to follow and monitor for disease progression as well as assess for signs of psychiatric distress.

Potential conflicts of interest

The authors declare no conflicts of interests.

References

1. Shelley WB, Wood MG. Wrinkles due to idiopathic loss of mid-dermal elastic tissue. *Br J Dermatol*. 1977;97:441-5. [PMID: 588454].
2. Gambichler T. Mid-dermal elastolysis revisited. *Arch Dermatol Res*. 2010;302:85-93. [PMID: 19936772].
3. Hardin J, Dupuis E, Haber RM. Mid-dermal elastolysis: A female-centric disease; case report and updated review of the literature. *Int J Womens Dermatol*. 2015;1:126-30. [PMID: 28491975].
4. Andres-Ramos I, Alegria-Landa V, Gimeno I, et al. Cutaneous Elastic Tissue Anomalies. *Am J Dermatopathol*. 2019;41:85-117. [PMID: 30688725].

5. Patroi I, Annessi G, Girolomoni G. Mid-dermal elastolysis: a clinical, histologic, and immunohistochemical study of 11 patients. *J Am Acad Dermatol.* 2003;48:846-51. [PMID: 12789173].
6. Gambichler T, Stucker M, Kreuter A, et al. Expression of extracellular matrix proteins in reticular variant of mid-dermal elastolysis. *J Eur Acad Dermatol Venereol.* 2010;24:1481-4. [PMID: 20456556].
7. Gambichler T, Skrygan M. Decreased lysyl oxidase-like 2 expression in mid-dermal elastolysis. *Arch Dermatol Res.* 2013;305:359-63. [PMID: 23238607].
8. Lewis KG, Bercovitch L, Dill SW, Robinson-Bostom L. Acquired disorders of elastic tissue: Part II. decreased elastic tissue. *J Am Acad Dermatol.* 2004;51:165-85; quiz 86-8. [PMID: 15280835].
9. Smithson SL, Orchard D, Scardamaglia L. Mycophenolate mofetil to treat mid-dermal elastolysis. *Pediatr Dermatol.* 2018;35:e221-e3. [PMID: 29683223].