

UC Davis

Dermatology Online Journal

Title

Danazol-induced Stevens-Johnson syndrome in a patient with systemic lupus erythematosus

Permalink

<https://escholarship.org/uc/item/24v513b9>

Journal

Dermatology Online Journal, 21(1)

Authors

Koh, WL
Tay, YK
Koh, MJA

Publication Date

2015

DOI

10.5070/D3211025452

Copyright Information

Copyright 2015 by the author(s). This work is made available under the terms of a Creative Commons Attribution-NonCommercial-NoDerivatives License, available at <https://creativecommons.org/licenses/by-nc-nd/4.0/>

Letter

Danazol-induced Stevens-Johnson syndrome in a patient with systemic lupus erythematosus

WL Koh¹, YK Tay¹, MJA Koh²

Dermatology Online Journal 21 (1): 17

¹Department of Dermatology, Changi General Hospital, Singapore

²Dermatology Service, KK Women's and Children's Hospital, Singapore

Correspondence:

Dr Wei Liang Koh

E-mail address: Koh_Wei_Liang@hotmail.com

Address: Department of Dermatology, Changi General Hospital, 2 Simei Street 3 Singapore 529889

Telephone number: +6593697325

Fax number: +6567816202

Abstract

A patient with Stevens-Johnson syndrome related to danazol is presented.

Keywords: Stevens-Johnson syndrome, Danazol, Systemic lupus erythematosus

Letter to the Editor

Case synopsis

A 19-year-old woman with a 5-year history of systemic lupus erythematosus (SLE), presented with 2 days of facial rash and oral ulcers. This eruption was significantly different from the malar erythema that characterized her earlier SLE flares. Her long-term medications included oral tacrolimus 2 mg/day and prednisolone 15 mg/day. Significantly, she had been started on oral danazol 200 mg/day for autoimmune haemolytic anaemia, 2 weeks prior to the current admission.

On examination, the patient was febrile. There were discrete to confluent, dusky purpuric macules, papules, and targetoid lesions, over the forehead, cheeks, neck, and arms. Similar papules and plaques with central bullae were seen on the palms (Figure 1). Erosions were noted on the lips, hard palate, and vulvae. The conjunctivae were normal. The cutaneous lesions affected 3% of her body surface area. Systemic examination was unremarkable except

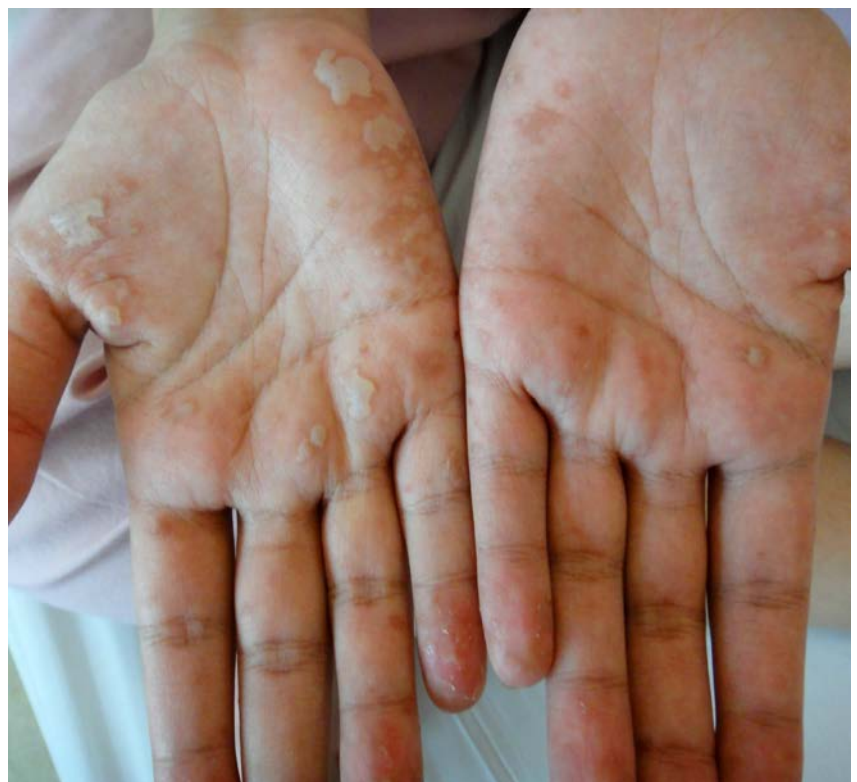

Figure 1. Bullae, erosions and atypical targets on the palms

for mild conjunctival pallor. Lesional skin biopsy from the right arm showed a subepidermal blister with full thickness epidermal necrosis with interface changes adjacent to the blister (Figure 2). Alcian blue stain did not show increased dermal mucin. These changes were consistent with Stevens-Johnson syndrome (SJS). Direct immunofluorescence (DIF) from perilesional skin was negative.

A diagnosis of danazol-induced SJS was made and danazol was stopped. She was started on intravenous methylprednisolone 1 g/day for 3 days followed by intravenous hydrocortisone 100 mg 8 hourly for 3 days. The eruption was also treated with betamethasone valerate 0.1%/ clioquinol 3% cream. Re-epithelisation was noted 10 days later. She was discharged on oral prednisolone 30mg/day, presently tapered to 10 mg/day.

Danazol is an attenuated androgen indicated for treating endometriosis, fibrocystic breast disease, and hereditary angioedema [1]. It has been used successfully as a second-line agent for the treatment of SLE-associated hematological abnormalities such as thrombocytopenia and autoimmune hemolytic anemia. [2, 3] Its mechanism of action is unknown but androgens appear to display potent immunoregulatory and anti-inflammatory properties in modulating the development of SLE in animal studies [2]. The main reported side effects include weight gain, virilization, hepatitis, and rashes.

Although SJS has been listed as a rare reaction in the product insert, causal relation has not been confirmed

[1]. We believe this is the first case report of danazol-induced SJS. It has been suggested that SJS/ toxic epidermal necrolysis (TEN) happens at a higher frequency in patients with collagen-vascular disorders [4]. However, there is no clear evidence at present that SLE by itself is a risk factor. SJS/TEN-like SLE was a possible consideration in the differential diagnosis in our patient but the clear drug relationship, acute clinical course, genital involvement, and rapid improvement upon cessation of drug suggest otherwise [5]. Both drug-induced SJS/TEN and SJS/TEN-like SLE can present with similar clinical and histological findings. DIF is negative in drug-induced SJS/TEN and may or may not be positive in SJS/TEN-like SLE [5]. Indeed, some authors consider Rowell's syndrome (erythema multiforme with SLE), SJS/TEN-like SLE, and SJS/TEN as part of a same clinical spectrum, which may exhibit full-thickness necrosis of the epidermis (acute syndrome of apoptotic pan-epidermolysis) [4, 5]. It is important to be cognizant of this rare, but severe cutaneous adverse reaction when prescribing danazol.

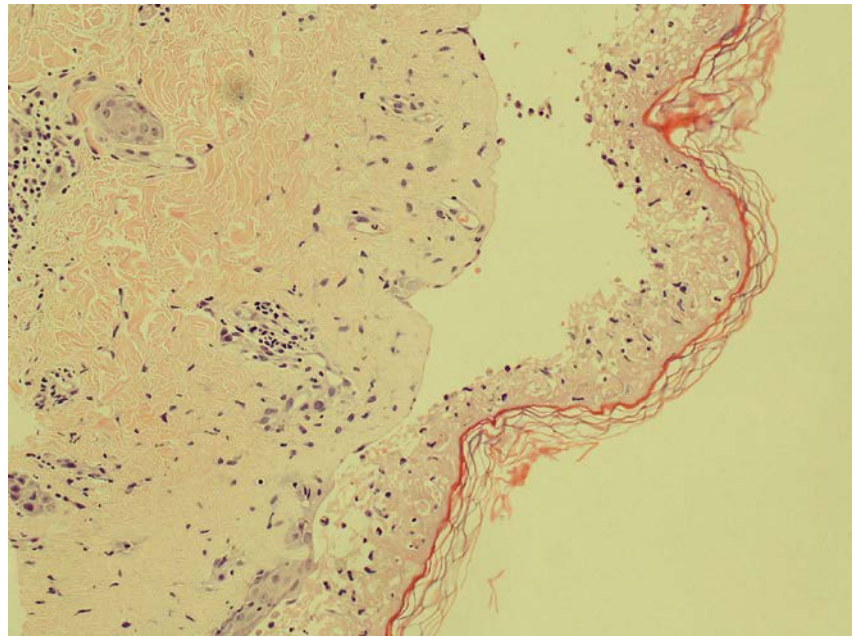


Figure 2. Lesional biopsy showing subepidermal blister with full thickness epidermal necrosis and adjacent interface changes: basal vacuolar alteration, necrotic keratinocytes and exocytosis of lymphocytes. (Haematoxylin and eosin, original magnification x 40)

References

1. Danazol capsule – detailed prescribing information. In: Danazol capsule full prescribing information, dosage and side effects. MIMS.com USA. Available at: <http://www.mims.com/USA/drug/info/Danazol%20Capsule/?type=full>. Accessed Aug 23, 2014.
2. Letchumanan P, Thumboo J. Danazol in the treatment of systemic lupus erythematosus: a qualitative systemic review. *Semin Arthritis Rheum* 2011 Feb; 40 (4):298-306. [PMID: 20541792]
3. Avina-Zubieta JA, Galindo-Rodriguez G, Robledo I, et al. Long term effectiveness of danazol, corticosteroids and cytotoxic drugs in the treatment of hematologic manifestations of systemic lupus erythematosus. *Lupus* 2003; 12(1):52-7. [PMID: 12587827]
4. Ziemer M, Kardaun SH, Liss Y, Mockenhaupt M. Stevens-Johnson syndrome and toxic epidermal necrolysis in patients with lupus erythematosus: a descriptive study of 17 cases from a national registry and review of the literature. *Br J Dermatol* 2012 Mar; 166(3):575-600. [PMID: 22014091]
5. Lee HY, Tey HL, Pang SM, Thirumoorthy T. Systemic lupus erythematosus presenting as Stevens-Johnson syndrome and toxic epidermal necrolysis: a report of three cases. *Lupus* 2011 May; 20(6):647-52. [PMID: 21148602]