

UC Davis

Dermatology Online Journal

Title

Necrolytic acral erythema

Permalink

<https://escholarship.org/uc/item/2dn7w0nv>

Journal

Dermatology Online Journal, 19(12)

Authors

Yost, John Montgomery
Boyd, Kevin P
Patel, Rishi R
[et al.](#)

Publication Date

2013

DOI

10.5070/D31912020709

Copyright Information

Copyright 2013 by the author(s). This work is made available under the terms of a Creative Commons Attribution-NonCommercial-NoDerivatives License, available at <https://creativecommons.org/licenses/by-nc-nd/4.0/>

Peer reviewed

Case Presentation

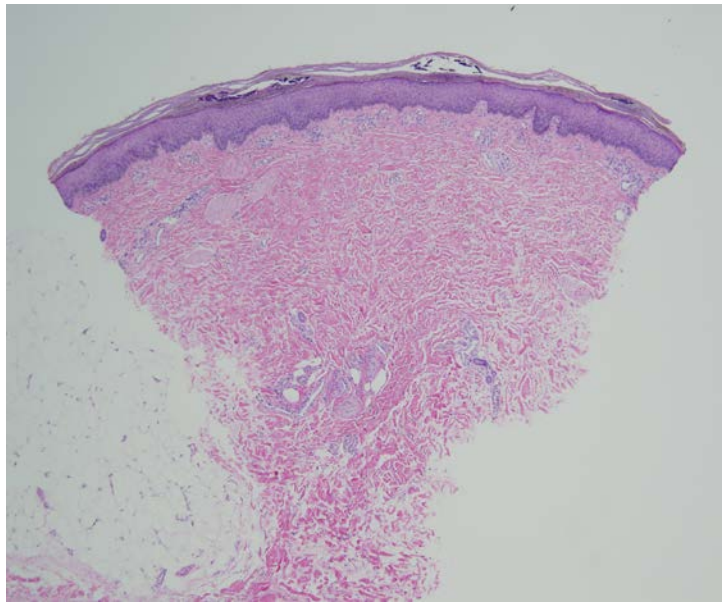
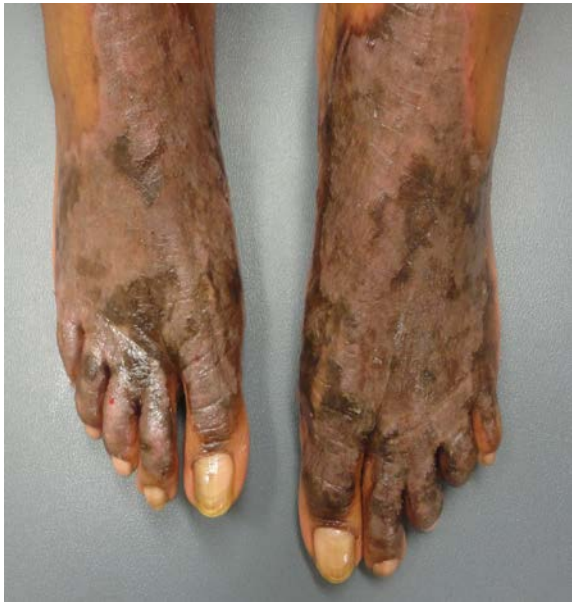John Montgomery Yost, MD, MPH, Kevin P. Boyd, MD, Rishi R. Patel, MD, Sarika Ramachandran, MD, and Andrew G. Franks, Jr., MD

Dermatology Online Journal 19 (12): 5

New York University School of Medicine

Abstract

Necrolytic acral erythema is a rare, cutaneous manifestation of hepatitis C virus infection that is characterized by erythematous, violaceous or dusky papules, blisters, and/or erosions in the early stages and by well-demarcated, hyperkeratotic, targetoid plaques with a peripheral rim of macular erythema, secondary lichenification and hyperpigmentation, and overlying fine micaceous or necrotic-appearing scale in the later stages. Because most topical modalities prove ineffective, treatment of the underlying viral infection or therapeutic zinc supplementation are required for clinical improvement.



Case synopsis

A 56-year-old woman with a past medical history of hepatitis C virus infection presented to the Skin and Cancer Unit for evaluation of a pruritic eruption for 10 years that affected the dorsal aspects of the feet, ankles, and left calf. Because the patient also had a long-standing history of dermatomyositis, therapy of hepatitis C virus infection with all types of interferon was contraindicated. Treatment with super-high potency topical glucocorticoids in the past had yielded minimal improvement. A punch biopsy specimen of a representative lesion on the left calf was obtained.

Physical Examination: Confluent, well-demarcated, hyperpigmented, lichenified plaques with scalloped borders and overlying, thick, necrotic-appearing scale were present on the dorsal aspects of the feet and extended onto the medial aspects of the ankles.

Laboratory Data: Hepatitis C virus RNA PCR was 17603860 IU/mL (normal < 43 IU/mL), hepatitis C genotype was 1a, Zinc 53 mcg/dL (60 to 130 mcg/dL)

Histopathology: There is slight epidermal hyperplasia, pallor in the superficial portions of the epidermis, and mild spongiosis, in addition to confluent parakeratosis with focal collections of neutrophils. There are thin-walled blood vessels within some papillae.

Diagnosis: Necrolytic acral erythema

Discussion: Initially described among a cohort of seven Egyptian patients in 1996, necrolytic acral erythema (NAE) represents a rare, clinical manifestation of hepatitis C virus (HCV) infection and is considered to be pathognomonic for infection [1, 2]. With less than 100 cases reported, the epidemiologic data regarding NAE are limited although the results from one recent cohort study suggest a prevalence of 1.7% among HCV-infected individuals, with individuals over 40 years of age and of African descent being proportionately overrepresented [2].

Clinically, NAE shares many features with necrolytic migratory erythema, with early lesions characterized as erythematous, violaceous, or dusky papules, blisters, and/or erosions. Later lesions often develop into well-demarcated, hyperkeratotic, targetoid plaques with a peripheral rim of macular erythema, secondary lichenification and hyperpigmentation with overlying fine micaceous or necrotic-appearing scale. In almost all cases, the distribution of the lesions includes the dorsal aspects of the feet and toes, with the Achilles tendon, malleoli, legs, and knees also often affected. Less commonly, NAE may involve the hands, elbows, buttocks, genitals, nails, and oral mucosa [3]. Whereas the constellation of associated symptoms may vary, most reports describe accompanying pruritus, burning, dysesthesias, or pain [2].

Histopathologic features of acute NAE include acanthosis, epidermal spongiosis, and a superficial, perivascular infiltrate; psoriasiform hyperplasia, prominent papillomatosis with parakeratosis, subcorneal pustules, epidermal pallor, and keratinocyte necrosis occur in chronic lesions [3, 4]. Because most histopathologic findings of NAE are non-specific, a high degree of clinical suspicion is required for diagnosis.

Although the underlying pathophysiologic mechanisms of NAE remain unclear, some evidence suggests that there is an association with HLA type DRB1 [5]. Other data also indicate that the severity of the cutaneous disease may mirror the degree of hepatic involvement, with increasing levels of HCV viremia correlated with worsening NAE [6, 7]. Supporting this association, NAE often resolves in patients successfully treated for HCV with ribavirin and/or interferon- α [8, 9].

Furthermore, zinc deficiency may also be involved in the pathogenesis of NAE, just as it is in the clinically similar, acrodermatitis enteropathica. Improvement or clearance of NAE may be achieved with zinc sulfate supplementation [10, 11]. Although the exact pharmacologic mechanism for this therapeutic response remains unclear, some evidence suggests that zinc supplementation in therapeutic doses exerts anti-inflammatory, immunostimulatory, antiviral, and antioxidant effects in addition to enhancing the response to HCV treatment [12, 13]. Therapeutic zinc supplementation also has been effective in patients with normal serum zinc levels; low serum zinc levels are believed to represent a late manifestation of zinc deficiency [10].

Owing to the dearth of reported cases, no definitive treatment recommendations exist for NAE. Treatment of the underlying HCV infection and/or supplementation with zinc sulfate continue to be the primary therapies for NAE. Few patients garner any improvement with the use of topical glucocorticoids [14].

References

1. El-Darouti M, *et al.* Necrolytic acral erythema: a cutaneous marker of viral hepatitis C. *Int J Dermatol* 1996;35:252
2. Raphael BA, *et al.* Low prevalence of necrolytic acral erythema in patients with chronic hepatitis C virus infection. *J Am Acad Dermatol* 2012;67:962
3. Bentley D, *et al.* Lack of classic histology should not prevent diagnosis of necrolytic acral erythema. *J Am Acad Dermatol* 2009;60:504
4. Wu YH, *et al.* Necrolytic acral erythema without hepatitis C infection. *J Cutan Pathol* 2009;36:355
5. Badra G, *et al.* Some immunological studies and HLA-DRB1 in hepatitis C virus related necrolytic acral erythema. *J Pan Arab Dermatol* 2004;15:29
6. El-Darouti M, *et al.* Leukocytoclastic vasculitis and necrolytic acral erythema in patients with hepatitis C infection: do viral load and viral genotype play a role? *J Am Acad Dermatol* 2010;63:259
7. Abdallah M, *et al.* Necrolytic acral erythema: a cutaneous sign of hepatitis C virus infection. *J Am Acad Dermatol* 2005;53:247
8. Khanna VJ, *et al.* Necrolytic acral erythema associated with hepatitis C: effective treatment with interferon alpha and zinc. *Arch Dermatol* 2000;136:755
9. Hivnor CM, *et al.* Necrolytic acral erythema: response to combination therapy with interferon and ribavirin. *J Am Acad Dermatol* 2004;50:S121
10. Najaran DJ, *et al.* Zinc deficiency associated with necrolytic acral erythema. *J Am Acad Dermatol* 2006;55:S108
11. Moneb HA, *et al.* Evaluation of zinc levels in skin of patients with necrolytic acral erythema. *Br J Dermatol* 2010;163:476
12. Abdallah MA, *et al.* Necrolytic acral erythema: a patient from the United States successfully treated with oral zinc. *Arch Dermatol* 2005;141:85
13. Takagi H, *et al.* Zinc supplementation enhances the response to interferon therapy in patients with chronic hepatitis C. *J Viral Hepat* 2001;8:3671