

UC Davis

Dermatology Online Journal

Title

Linear IgA bullous dermatosis associated with immunotherapy

Permalink

<https://escholarship.org/uc/item/2v904494>

Journal

Dermatology Online Journal, 29(6)

Authors

Momin, Bahar

Nguyen, Tue F

Glade, Daniel

et al.

Publication Date

2023

DOI

10.5070/D329662995

Copyright Information

Copyright 2023 by the author(s). This work is made available under the terms of a Creative Commons Attribution-NonCommercial-NoDerivatives License, available at

<https://creativecommons.org/licenses/by-nc-nd/4.0/>

Peer reviewed

Linear IgA bullous dermatosis associated with immunotherapy

Bahar Momin¹ BBA, Tue F Nguyen¹ BS, Daniel Glade² MD, Alison Messer² MD

Affiliations: ¹Long School of Medicine, University of Texas Health Science Center at San Antonio, San Antonio, Texas, USA,

²Department of Dermatology, University of Texas Health San Antonio, San Antonio, Texas, USA

Corresponding Author: Alison Messer MD, Department of Dermatology, University of Texas Health San Antonio, 7979 Wurzbach Road, San Antonio, TX 78229, Email: messera@uthscsa.edu

Abstract

Linear IgA bullous dermatosis (LABD) is a rare mucocutaneous blistering autoimmune disease caused by IgA autoantibodies. Its clinical manifestation can be indistinguishable from bullous pemphigoid (BP), a similar autoimmune bullous disease caused by IgG and IgE autoantibodies. Although BP has been reported as an adverse cutaneous effect of immunotherapy, LABD has rarely been associated with immunotherapy in the literature. We present the case of a 67-year-old woman with metastatic ovarian cancer receiving anti-PD1 and anti-CTLA4 with new onset pruritic tense bullae to the trunk, hands, elbows (in annular distribution) that occurred after immunotherapy. Skin biopsy showed subepidermal blister with abundant neutrophils on H&E histology, and linear IgA staining at the basement membrane on direct immunofluorescence consistent with the diagnosis of LABD. The condition did not improve on initial prednisone taper, but blisters rapidly resolved a few days after initiation of dapsons therapy. We favor that our patient's LABD is secondary to her immunotherapy. Our case highlights the importance of both H&E histology and direct immunofluorescence in diagnosis of blistering disorders in patients on immunotherapy to help in choosing the most effective treatment option in an attempt to avoid discontinuation of immunotherapy.

Keywords: bullous pemphigoid, dermatopathology, endometrial cancer, immunotherapy, linear IgA, ovarian cancer

Introduction

Linear immunoglobulin A (IgA) bullous dermatosis (LABD) is a rare mucocutaneous autoimmune

disorder caused by IgA autoantibodies directed against antigens in the basement membrane of the skin and mucosa. Linear IgA bullous dermatosis can be idiopathic, drug-induced, or associated with systemic diseases such as systemic lupus erythematosus and dermatomyositis. Rarely, it can be related to malignancies and infections such as B-cell lymphoma and varicella-zoster [1]. Most cases of drug-induced LABD resolve within two to 6 weeks after cessation of the drug. Linear IgA bullous dermatosis presents as clear or hemorrhagic vesicles or bullae with erythematous or urticarial bases, often in an annular distribution, especially in the groin [1]. The clinical manifestation of LABD can be indistinguishable from bullous pemphigoid (BP), a similar autoimmune bullous disease that is related to the production of IgG and IgE autoantibodies against hemidesmosome proteins, BP180 and BP230, that anchor the epidermis to the basement membrane.

Laboratory findings are crucial to diagnosing and distinguishing LABD and BP. Histological examination, direct immunofluorescence assay (DIF), and indirect immunofluorescence assay are commonly used, as shown in **Table 1**.

Case Synopsis

A 67-year-old woman with a history of metastatic ovarian and endometrial cancer was evaluated by a dermatology consultant for evaluation of blisters. She took a programmed cell death protein (PD1) inhibitor every two weeks and an anti-cytotoxic T lymphocyte-associated-protein-4 (CTLA4) monoclonal antibody every six weeks to manage her malignancies as part of a study; thus, we are not able to report the specific names of the agents used. After

Table 1. Laboratory findings.

Test type	Linear IgA bullous dermatosis	Bullous pemphigoid
H&E Patient skin + Light microscope	Subepidermal blister + neutrophils	Subepidermal blister + eosinophils, neutrophils sometimes
Direct immunofluorescence Patient skin + immunofluorescent microscope	Linear IgA in 100% of cases	Linear IgG and/or C3
Indirect immunofluorescence Patient serum + Healthy patient skin control + immunofluorescent Microscope	IgA staining, sensitivity 30% [2]	IgG staining (on roof of blister if salt-split), sensitivity 60-80% [3]
ELISA Patient serum only	Rarely used to detect circulating IgA autoantibodies against BP180 [4]	Sensitivity 70% in detecting antibodies to BP180 and/or BP230 antigens [5]

taking three doses of anti-PD1 and one dose of anti-CTLA4, the patient developed a widespread pruritic rash with blisters that began on the hands and spread to the trunk and extremities. She also noted associated sores in the mouth, eye irritation, and vomiting. Of note, other medical issues include primary hypertension managed with enalapril. Physical examination revealed pruritic tense bullae on the palmar and dorsal hands (**Figure 1A**), groups of flaccid bullae and erosions on the chest, abdomen, flanks, proximal arms, and elbows (**Figure 1B**), and a

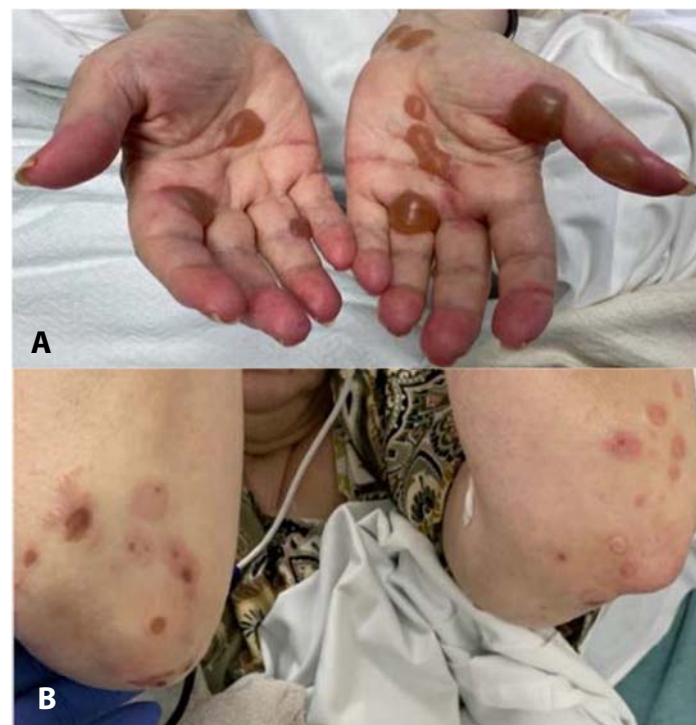

Figure 1. A) Pruritic tense bullae on the palmar hands. **B)** Flaccid bullae and erosions on bilateral elbows.

few bleeding ulcers on the inferior surface of the tongue. The differential diagnoses included drug-induced BP and LABD associated with anti-PD1 or anti-CTLA4 immunotherapies. A biopsy taken from the left proximal arm showed a subepidermal blister with abundant neutrophils on H&E (**Figure 2**) and DIF histologies yielded linear IgA staining at the basement membrane (**Figure 3**). Indirect immunofluorescence assay did not demonstrate linear deposits of IgA on salt-split skin, and serology for BP 180/230 antibodies was negative. The patient initially took prednisone 1mg/kg/day for one week without improvement, but the blisters rapidly resolved a few days after starting dapsone 25mg PO daily, which was continued for about one month. The patient also discontinued participating in the PD1 inhibitor and anti-CTLA4 treatment trial and has not developed a recurrence of the rash.

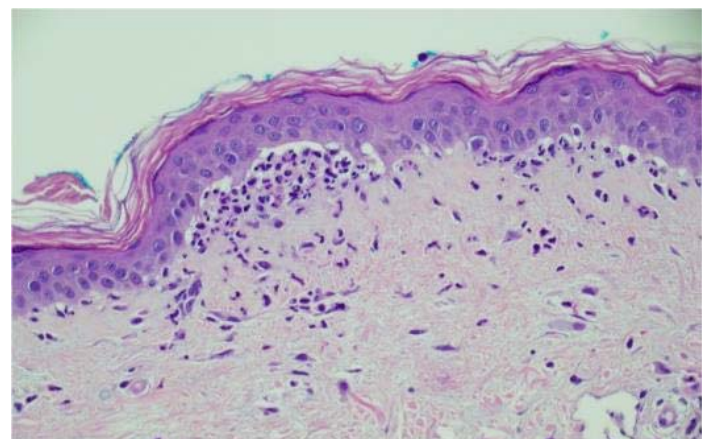


Figure 2. H&E stain depicting subepidermal blister with neutrophilic infiltration, 400x.

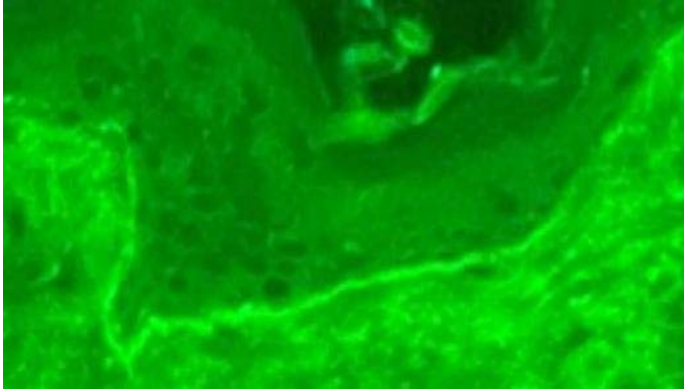


Figure 3. Positive direct immunofluorescence for linear IgA staining along the basement membrane, 400x.

Case Discussion

Cytotoxic T lymphocyte-associated-protein-4 (CTLA4) and programmed cell death protein (PD1) inhibitors target negative regulators of T-cell activation. When blocked, T cell response is promoted, leading to both anti-tumor activity and proliferation of self-reactive T cells. Thus, they are commonly used to treat various cancers. Anti-CTLA4 monotherapy has a higher incidence of cutaneous adverse events (44-59%) compared to anti-PD1 monotherapy (34-42%), but combination therapy increases the incidence to 59-79% [6]. Skin biopsy can play a crucial role in evaluating cutaneous adverse events associated with immune checkpoint inhibitor to not only confirm or diagnose but to differentiate when other skin immune-related events are being considered. [7].

Our findings were more suggestive of LABD versus BP, as the patient's H&E histology exhibited more neutrophils than eosinophils and DIF showed linear IgA deposition along the basement membrane. Indirect immunofluorescence assay testing for LABD is only 30% sensitive, as a minority of patients with drug-induced LABD have circulating antibodies [8]. Therefore, the negative immunofluorescence assay

result did not rule out LABD. Additionally, the patient did not respond to prednisone but rapidly responded to dapsons, the first-line therapy for LABD. However, the cessation of her immunotherapy may also explain her improvement. She has not yet been rechallenged with immunotherapy.

The etiology of our patient's LABD was most likely secondary to her immunotherapy. She had few other risk factors; she did not have an autoimmune disease or lymphoma and currently takes enalapril which may cause drug-induced LABD. However, captopril is more associated with LABD and our patient has taken enalapril for years without any negative reactions [9]. Although we are unsure which anti-tumor agent induced the blister formation, anti-PD1 has been shown to be more associated with BP than anti-CTLA4. One other case suggested that anti-PD1 therapy may trigger LABD, although the patient described was also receiving vancomycin, which was the more likely cause [10].

Conclusion

Drug-induced LABD has rarely been reported in the literature. Close clinical monitoring, especially in patients receiving combination therapy, is paramount because of the increased risk of adverse cutaneous events. Our case highlights the importance of examining H&E and DIF histologies in diagnosing blistering skin disorders in patients receiving immunotherapy. An accurate diagnosis enables providers to initiate the most appropriate treatment option, which may allow patients to continue their immunotherapy regimens.

Potential conflicts of interest

The authors declare no conflicts of interest.

References

1. Chen S, Mattei P, Fischer M, Gay JD, Milner SM, Price LA. Linear IgA bullous dermatosis. *Eplasty*. 2013;13:ic49. [PMID: 23882302].
2. Angiero F, Benedicenti S, Crippa R, Magistro S, Farronato D, Stefani M. A rare case of desquamative gingivitis due to linear IgA disease: morphological and immunofluorescence features. *In Vivo*. 2007;21:1093-1098. [PMID: 18210762].
3. Di Zenzo G, Della Torre R, Zambruno G, Borradori L. Bullous pemphigoid: from the clinic to the bench. *Clin Dermatol*. 2012;30:3-16. [PMID: 22137222].
4. Zillikens D, Herzele K, Georgi M, et al. Autoantibodies in a subgroup of patients with linear IgA disease react with the NC16A domain of BP1801. *J Invest Dermatol*. 1999;113:947-953. [PMID: 10594735].
5. Miyamoto D, Santi CG, Aoki V, Maruta CW. Bullous pemphigoid.

- An Bras Dermatol.* 2019;94:133-146. [PMID: 31090818].
6. Quach HT, Johnson DB, LeBoeuf NR, Zwerner JP, Dewan AK. Cutaneous adverse events caused by immune checkpoint inhibitors. *J Am Acad Dermatol.* 2021;85:956-966. [PMID: 34332798].
 7. Cohen PR. Letter to the Editor: The Role of Skin Biopsy in the Management of Immune Checkpoint Inhibitor Toxicity. *J Natl Compr Canc Netw.* 2022;20:xxxii. [PMID: 36240842].
 8. Pastuszczak M, Lipko-Godlewska S, Jaworek AK, Wojas-Pelc A. Drug-induced linear IgA bullous dermatosis after discontinuation of cefuroxime axetil treatment. *J Dermatol Case Rep.* 2012;6:117-119. [PMID: 23329991].
 9. Lammer J, Hein R, Roenneberg S, Biedermann T, Volz T. Drug-induced Linear IgA Bullous Dermatitis: A Case Report and Review of the Literature. *Acta Derm Venereol.* 2019;99:508-515. [PMID: 30809685].
 10. Siegel J, Totonchy M, Damsky W, et al. Bullous disorders associated with anti-PD1 and anti-PDL1 therapy: A retrospective analysis evaluating the clinical and histopathologic features, frequency, and impact on cancer therapy. *J Am Acad Dermatol.* 2018;79:1081-1088. [PMID: 30025829].