

UC Irvine

Clinical Practice and Cases in Emergency Medicine

Title

Blinking Bug Bite

Permalink

<https://escholarship.org/uc/item/2zw9b4k3>

Journal

Clinical Practice and Cases in Emergency Medicine, 2(4)

Authors

Miller, Joseph
Walsh, Mark
Magyar, Jessica
et al.

Publication Date

2018

DOI

10.5811/cpcem.2018.9.39466

Supplemental Material

<https://escholarship.org/uc/item/2zw9b4k3#supplemental>

Copyright Information

Copyright 2018 by the author(s). This work is made available under the terms of a Creative Commons Attribution License, available at <https://creativecommons.org/licenses/by/4.0/>

Peer reviewed

Blinking Bug Bite

Joseph Miller, MD*
 Mark Walsh, MD†
 Jessica Magyar, PA-C†
 Nuha Zackariya‡
 John Rice, MD§
 Katherine Rice†
 Dawn Ziegelmaier, RN**
 Patrick Hanlon, MD*
 Joseph Dynako, BS¶
 David Zimmer, DVM¶
 Faadil Shariff‡
 Michael T. McCurdy, MD||
 Shane Kappler, MD#
 Paul Guentert, MD**

*Henry Ford Hospital, Department of Emergency Medicine, Detroit, Michigan
 †St. Joseph Regional Medical Center, Department of Emergency Medicine, Mishawaka, Indiana
 ‡Indiana University, Bloomington, Indiana
 §South Bend Clinic, Michiana Pediatrics, South Bend, Indiana
 ¶Indiana University School of Medicine, South Bend, Indiana
 ||University of Maryland School of Medicine, Department of Emergency Medicine, Baltimore, Maryland
 #Cambridge Health Alliance, Cambridge, Massachusetts
 **Pulmonary and Critical Care Associates PC, South Bend, Indiana

Section Editor: Rick A. McPheeters, DO

Submission history: Submitted June 24, 2018; Revision received August 27, 2018; Accepted September 6, 2018

Electronically published October 9, 2018

Full text available through open access at http://escholarship.org/uc/uciem_cpem

DOI: 10.5811/cpcem.2018.9.39466

[Clin Pract Cases Emerg Med. 2018;2(4):382–383.]

CASE PRESENTATION

A three-year-old female presented to a community emergency department with a one-day pruritic rash on her knee. The patient and the parents noted that the rash blanched intermittently and that this blanching appeared to be what they called a “blinking” bug bite. Physical examination revealed a normal child with no heart murmur and two bullous lesions around the left knee that blanched in a pulsatile fashion, corresponding to the femoral pulse (Images 1 and 2, Video).

DIAGNOSIS

A review of the medical literature revealed a single “Images in Clinical Medicine” from the *New England Journal of Medicine*, which revealed a severe dermatitis of the lower extremities that had similar presentation.¹ No other cases were noted in the literature. The wounds were anesthetized and debrided for concern of a staph infection. The patient was placed on antibiotics and healed uneventfully. The case presented here represents an example of a physical manifestation of Quincke’s sign, not related to aortic insufficiency but to the rarely-noted effect of intense arterial dilatation in the bullous inflammation of the affected subcutaneous area. Quincke’s pulse is a physical finding of aortic insufficiency and, as in this case, focal arterial dilatation. Here, the arterial dilatation in the area of the bite led to an inability of arterioles to maintain sufficient pressure during diastole, resulting in the pulsating blanching and flushing that produced a “blinking” bug bite.

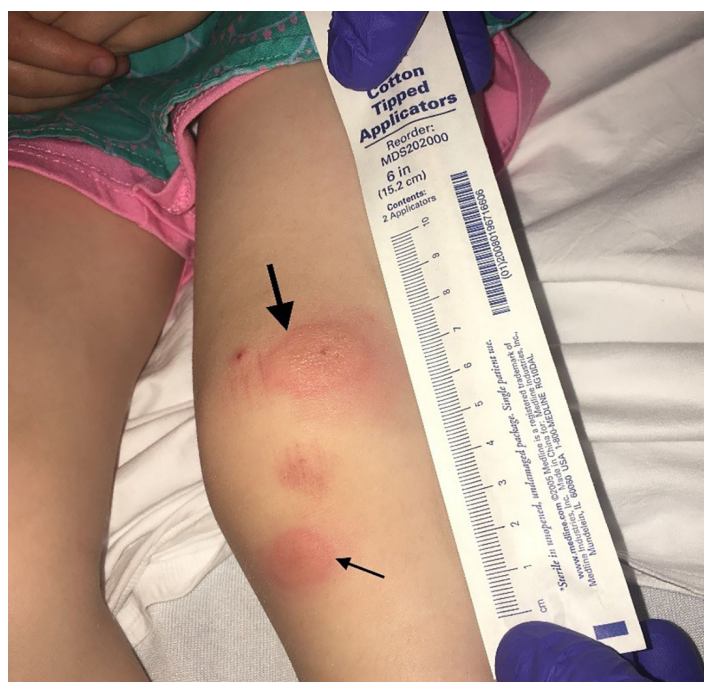

Image 1. The insect bite skin lesions on the knee varying in size (arrows).

Video. This recording demonstrates the blinking bug bite, a manifestation of Quincke’s pulse.

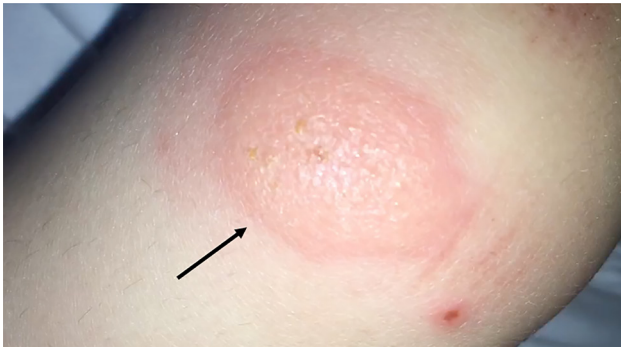


Image 2. Close-up of skin lesion (arrow).

Documented patient informed consent and/or Institutional Review Board approval has been obtained and filed for publication of this case report.

Address for Correspondence: Joseph Miller, MD, MS, Henry Ford Hospital, Department of Emergency Medicine, 2799 W Grand Blvd, Detroit, Michigan 48202. E-mail: jmiller6@hfhs.org.

Conflicts of Interest: By the *CPC-EM* article submission agreement, all authors are required to disclose all affiliations, funding sources and financial or management relationships that could be perceived as potential sources of bias. The authors disclosed none.

Copyright: © 2018 Miller et al. This is an open access article distributed in accordance with the terms of the Creative Commons Attribution ([CC BY 4.0](https://creativecommons.org/licenses/by/4.0/)) License. See: <http://creativecommons.org/licenses/by/4.0/>

CPC-EM Capsule

What do we already know about this clinical entity?

Google Scholar and PubMed reveal only one case report of a “blinking” bug bite. However, searchable online blog posts reveal similar descriptions of these bites.

What is the major impact of the image(s)?

The images here demonstrate a classic example of the “blinking” bug bite, which has not been well described in the medical literature.

How might this improve emergency medicine practice?

These images and video may act as a reference for emergency physicians to more easily diagnose this benign condition.

REFERENCES

1. Lazar JD and Willis LK. A blinking knee. *N Engl J Med.* 2014;370(24):e36.