

UC Davis

Dermatology Online Journal

Title

Vulvar and perineal verrucous changes complicating hidradenitis suppurativa after wide excision: a case and literature review

Permalink

<https://escholarship.org/uc/item/3d37n310>

Journal

Dermatology Online Journal, 26(7)

Authors

Ward, Rachael A
Udechukwu, Nneka S
Selim, Maria A
et al.

Publication Date

2020

DOI

10.5070/D3267049559

Copyright Information

Copyright 2020 by the author(s). This work is made available under the terms of a Creative Commons Attribution-NonCommercial-NoDerivatives License, available at <https://creativecommons.org/licenses/by-nc-nd/4.0/>

Peer reviewed

Vulvar and perineal verrucous changes complicating hidradenitis suppurativa after wide excision: a case and literature review

Rachael A Ward¹ MD, Nneka S Udechukwu² MD, Maria A Selim³ MD, Tarannum Jaleel² MD

Affiliations: ¹Division of Dermatology, University of Washington, Seattle, Washington, USA, ²Department of Dermatology, Duke University Medical Center, Durham, North Carolina, USA, ³Department of Pathology and Department of Dermatology, Duke University Medical Center, Durham, North Carolina, USA

Corresponding Author: Nneka S. Udechukwu, MD, Department of Dermatology, Duke University Medical Center, 40 Duke Medicine Circle, Durham NC 27710, Tel: 919-684-8111, Email: Nneka.udchukwu@duke.edu

Abstract

Poorly controlled and long-standing hidradenitis suppurativa (HS) increases the risk of squamous cell carcinoma (SCC). We report a 54-year-old woman with an over 20-year history of HS, who had previously undergone wide perineal excision with secondary intention healing and presented with a painful verrucous vulvar plaque and proximal non-healing perineal wound. The patient had four perineal scouting biopsies performed and excisional biopsy with no evidence of high-grade dysplasia or carcinoma on histology. Chromogenic in situ hybridization was negative for HPV 16 and 18 mRNA; the patient's HIV and HSV PCR were also negative. Our patient was treated with interferon alfa-2b with notable clinical improvement. There is currently no standardized stepwise approach to monitoring verrucous lesions in HS patients with significant risk factors for SCC. Our report highlights a vigilant approach to monitoring. If scouting biopsies are negative, complete testing for high risk HPV strains (HPV 16 and 18) is warranted. If negative, we recommend follow up every 6 months with no further biopsies except if overt clinical changes are observed. We also recommend treatment of verrucous changes to decrease risk of possible malignant conversion. Interferon alfa-2b was effective in decreasing the verrucous lesion burden in our patient and may be considered.

Keywords: acne inversa, condyloma acuminatum, hidradenitis suppurativa, squamous cell carcinoma, skin cancer prevention

Introduction

Hidradenitis suppurativa (HS), also known as acne inversa, is a chronic inflammatory follicular occlusive skin disease primarily involving the intertriginous skin areas of the axillary, groin, perianal, and inframammary regions [1]. The clinical manifestations of the disease vary but can involve the development of recurrent inflamed nodules, abscesses, sinus tracts, and severe diffuse scarring [2, 3]. Repeated episodes of profound inflammation in HS can lead to a number of complications, including lymphatic obstruction and sinus tract formation. Less commonly, HS can lead to proliferative skin changes as well as malignancy [2, 4, 5].

Malignant transformation of HS lesions is a rare but feared complication of the disease owing to the high morbidity risk and poorly established management criteria [3]. Clinically, proliferative epidermal changes may also be seen in HS patients, which may mimic malignant transformation. When these occur, important diagnoses to consider include condyloma acuminatum and various types of squamous cell carcinoma (SCC), such as verrucous SCC and Marjolin ulcer. We report a woman with a long-standing history of HS who presented with severe pain and vulvar and perineal verrucous changes after wide excision with no evidence of SCC on pathology. There is always a clinical concern that these patients may be at risk of developing SCC in the setting of chronic inflammation. As such, the authors allude to potential monitoring strategies to prevent and detect this complication.

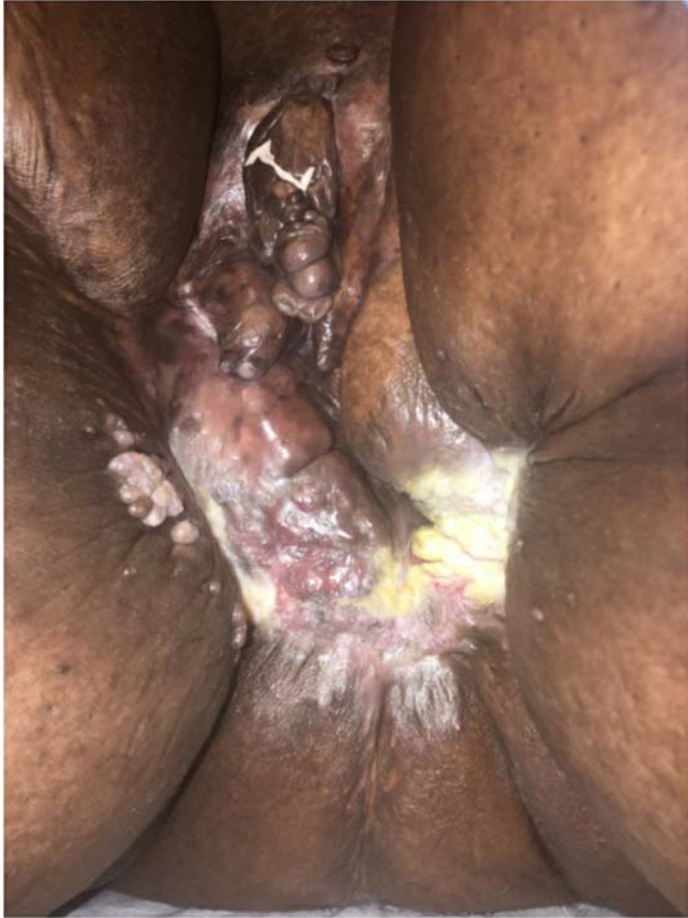

Figure 1. Extensive scarring, maceration, and distortion of vulva region, 2cm verrucous plaque on right medial thigh, and verrucous papules near perianal region.

Case Synopsis

We present a 54-year-old peri-menopausal woman with a history of hidradenitis suppurativa, Hurley Stage III, of greater than 20 years. Additionally, she had other pertinent medical co-morbidities including morbid obesity (status post Roux-en-Y gastric bypass surgery), hypertension, and diabetes mellitus type II. She presented to our dermatology clinic in 2014 upon referral from her primary care physician owing to persistent severe pain in her groin around prior surgical sites despite being on chronic pain medications.

She had undergone multiple wide perineal excisions after initially failing topical, intralesional, and oral HS treatments in the past. During her last surgery at a different institution about 20 years prior, areas around the vulva and inner thigh were excised and left to heal by secondary intention. However, the

area never completely healed and she had persistent areas of ulceration with no associated draining sinuses or abscess formation. During her initial evaluation at our facility, there was extensive scarring and ulceration with overlying verrucous plaque concerning for verrucous squamous cell carcinoma (**Figure 1**). She was referred to the plastic surgery department for excisional biopsy evaluation because of concern for SCC with wide anatomical involvement. She was not deemed a surgical candidate and was referred back to our clinic for management. In the interim, she was seen by her gynecologist who completed a right vulvar lesion biopsy that showed superficial lymphangioma with no evidence of malignancy (**Figure 2**). She was lost to follow up for three years owing to recurrent inpatient admissions from her other medical co-morbidities.

Additional vulvar biopsies were performed on her return to dermatology clinic three years later as the patient remained in severe pain with poor wound healing. However, the biopsies from two separate sites showed pseudoepitheliomatous hyperplasia and lichen simplex chronicus, respectively. Nevertheless, there was persistent provider desire for further clarification of diagnosis and consideration for further biopsies to rule out malignancy. She was evaluated by a surgical oncology consultant who recommended and

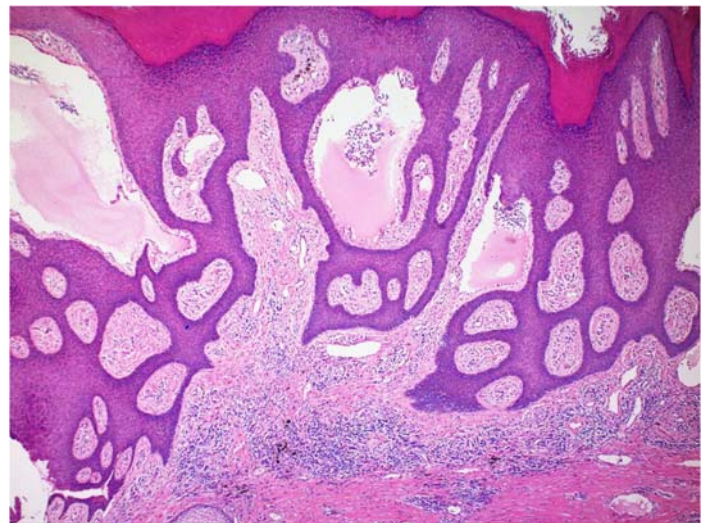


Figure 2. Initial vulvar biopsy with histologic features showing dilated lymphatics in dermal papillae with absent erythrocytes consistent with lymphangioma.

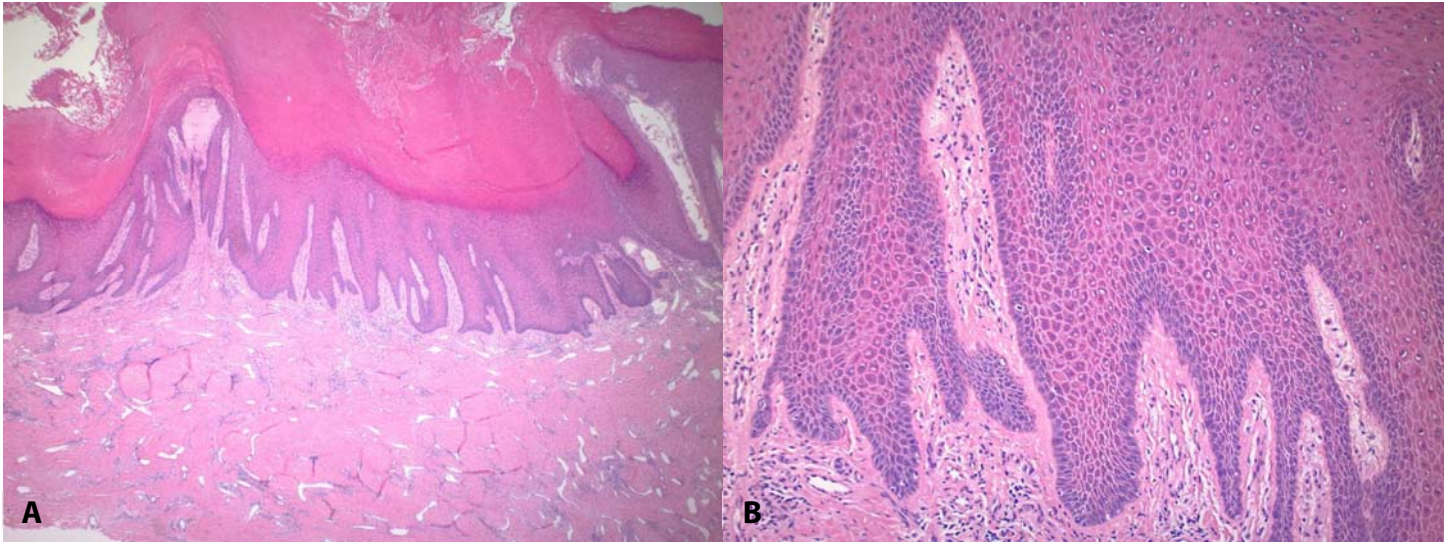


Figure 3. Histologic findings on excisional biopsy show epithelial hyperplasia with features suggestive of condyloma acuminatum with no evidence of high-grade dysplasia or carcinoma. H&E, **A)** 10x; **B)** 40x.

completed excisional biopsy evaluating the right anterolateral perianal aspect, left posterolateral perianal aspect, right posterolateral perianal aspect, and left lateral perianal aspect.

The surgical pathology of the excisional biopsy showed findings of hyperkeratosis with histologic features suggestive of condyloma acuminatum with no evidence of high-grade dysplasia or carcinoma. There were varying degrees of pseudoepitheliomatous hyperplasia with hyperkeratosis and parakeratosis. Scattered cells showed slight peri-nuclear clearing and possible viropathic change (**Figure 3**). Several sections also contained a dense lymphoplasmacytic inflammatory cell infiltrate, thus spirochete immunohistochemical stains were performed and were negative. Chromogenic in situ hybridization was negative for HPV 16 and 18 mRNA. The patient also had negative HIV test and HSV PCR.

She commenced treatment with interferon alfa-2b, 18million unit/ml (1ml) by subcutaneous injection three times per week for four weeks. After completion of interferon therapy, our patient showed significant clinical improvement of her genital warts and mildly improved genital pain (**Figure 4**).

Case Discussion

Hidradenitis suppurativa is a chronic follicular occlusive inflammatory disease involving the intertriginous areas [1]. There have been many reports of its association with SCC and in these patients there is a higher likelihood of metastasis and mortality [3].

Our case underlines the importance of early and aggressive evaluation of verrucous skin changes in patients with HS. The clinical concern arises from prior case presentations that have shown SCC emerging from chronic inflammation in the

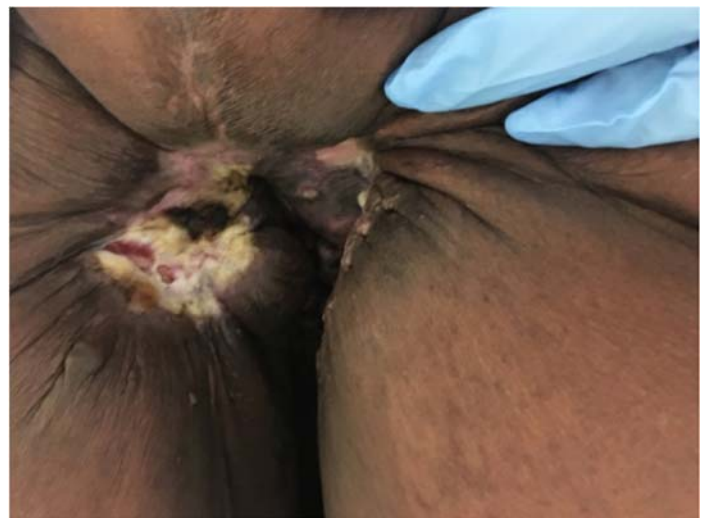

Figure 4. Clinical improvement after excisional biopsy and interferon alfa-2b treatment.

perineum [3, 6-8]. It is also more likely that cutaneous SCC will occur if risk factors including smoking, chronic wounds, prior scarring, exposure to radiation, HPV infection, or immunosuppression are present [6, 7]. In the case of the presented patient, severe scarring with evident vulvar disfigurement and history of chronic non-healing surgical wounds place her at a higher risk of SCC compared to the general population. Owing to these prominent risks, verrucous plaques overlying HS lesions signal immediate concern for SCC, especially when pain is noted. Patient-reported warning signs have been studied and showed positive correlation of pain intensity and duration of pain with risk of biopsy-proven SCC [9, 10]. In HS patients at increased risk for SCC, we recommend monitoring patients with diligent scouting biopsies if lesions are non-healing, tender, and/or increasing in size. If scouting biopsies are negative, testing for high risk HPV strains would be recommended. Highest risk HPV strains for vulva cancers are HPV 16 and 18 whereas others with lower oncogenic risk include 31, 33, 45, 52, and 58 [11]. At the minimum, we would recommend following HPV 16 and 18. Overall, these patients with higher SCC risk should be followed closely at least every 6 months for full skin examination to allow early identification of SCC even when high risk HPV strains are not identified. In addition, treatment of condyloma is recommended as it may potentially decrease the risk of malignant conversion especially in a high-risk HPV type positive patient. In our patient, we opted for treatment with intralesional interferon because of the evidence of condyloma acuminatum despite HPV 16 and 18 immunostaining since several other HPV phenotypes exist that can cause the viropathic changes seen on histology that are not readily available for immunostaining. Our patient responded very positively to treatment with

interferon alfa-2b, which has been reported as an effective treatment in condyloma acuminatum in anatomically challenging areas; as such the treatment served as management and partial prophylaxis [12, 13].

Conclusion

Close clinical monitoring of patients with HS is advised because of their increased risk of SCC secondary to chronic inflammatory wound state. There are no standardized monitoring guidelines for patients with HS regarding prevention of SCC and monitoring. We recommend a vigilant approach to monitoring and management. We suggest that in an HS patient with a chronic ulcer and/or verrucous changes, as a first step in evaluation, scouting biopsies should be completed to rule out SCC. If biopsies are negative, we propose obtaining a minimum of HPV 16 and 18 testing via immunostaining of biopsied skin or other cytologic sampling. In addition, if there is evidence of verrucous changes on examination or on histology, despite negative HPV results, we encourage prophylactic treatment to decrease the risk of malignant conversion with possible use of interferon alfa-2b, 18million unit/ml (1ml) subcutaneous injections three times per week for four weeks. After treatment, the patient should continue close clinical skin evaluation.

Potential conflicts of interest

Dr. Tarannum Jaleel is a consultant for Eli Lilly and Chemocentryx as well as a recipient of research grant from Dermatology Foundation and Skin of Color Society. The remaining authors declare no conflicts of interests.

References

1. von Laffert M, Stadie V, Wohlrab J, Marsch WC. Hidradenitis suppurativa/acne inversa: bilocated epithelial hyperplasia with very different sequelae. *Br J Dermatol*. 2011;164:367-371. [PMID: 20831631].
2. Scheinfeld N. An atlas of the morphological manifestations of hidradenitis suppurativa. *Dermatol Online J*. 2014;20:22373. [PMID: 24746309].
3. Jourabchi N, Fischer AH, Cimino-Mathews A, Waters KM, Okoye GA. Squamous cell carcinoma complicating a chronic lesion of hidradenitis suppurativa: a case report and review of the literature. *Int Wound J*. 2017;14:435-438. [PMID: 27681476].
4. Makris GM, Poulakaki N, Papanota AM, Kotsifa E, Sergentanis TN, Psaltopoulou T. Vulvar, Perianal and Perineal Cancer After Hidradenitis Suppurativa: A Systematic Review and Pooled Analysis. *Dermatol Surg*. 2017;43:107-115. [PMID: 27755170].
5. Sims SM, McLean FW, Davis JD, Morgan LS, Wilkinson EJ. Vulvar

- lymphangioma circumscriptum: a report of three cases, two associated with vulvar carcinoma and one with hidradenitis suppurativa. *J Low Genit Tract Dis.* 2010;14:234-237. [PMID: 20592561].
6. Belli S, Colakoglu T, Parlakgumus A, et al. Squamous cell carcinomas on the basis of chronic inflammatory perianal lesions. *Turk J Gastroenterol.* 2012;23:192-193. [PMID: 22706755].
 7. Zaesim A, Jackson AC, Lee SW, Price SA. Squamous Cell Carcinoma Arising within Verruca Vulgaris on the Nipple. *Case Rep Dermatol Med.* 2018;2018:1984593. [PMID: 30026989].
 8. Park BS, Shin DH, Kim SH, Jung HJ, Son GM, Kim HS. Perineal squamous cell carcinoma arising from an epidermal cyst: a case report. *World J Surg Oncol.* 2018;16:155. [PMID: 30055637].
 9. Bouwes Bavinck JN, Harwood CA, Genders RE, et al. Pain identifies squamous cell carcinoma in organ transplant recipients: the SCOPE-ITSCC PAIN study. *Am J Transplant.* 2014;14:668-676. [PMID: 24730051].
 10. Mills KC, Kwatra SG, Feneran AN, et al. Itch and pain in nonmelanoma skin cancer: pain as an important feature of cutaneous squamous cell carcinoma. *Arch Dermatol.* 2012;148:1422-1423. [PMID: 23247491].
 11. Manini I, Montomoli E. Epidemiology and prevention of Human Papillomavirus. *Ann Ig.* 2018;30:28-32. [PMID: 30062377].
 12. Suarez-Ibarrola R, Heinze A, Sanchez-Sagastegui F, et al. Giant Condyloma Acuminatum in the Genital, Perineal and Perianal Region in a Pediatric Patient. Literature Review and Case Report. *Urol Case Rep.* 2016;7:14-16. [PMID: 27335781].
 13. Eron LJ, Judson F, Tucker S, Prawer S, Mills J, Murphy K, et al. Interferon therapy for condylomata acuminata. *N Engl J Med.* 1986;315:1059-64. [PMID: 3531860].