

# UC Davis

## Dermatology Online Journal

### Title

Lichen planus secondary to rabies vaccination

### Permalink

<https://escholarship.org/uc/item/3hr3t4hs>

### Journal

Dermatology Online Journal, 23(3)

### Authors

An, Isa  
Demir, Vasfiye  
İbiloğlu, İbrahim  
et al.

### Publication Date

2017

### DOI

10.5070/D3233034295

### Copyright Information

Copyright 2017 by the author(s). This work is made available under the terms of a Creative Commons Attribution-NonCommercial-NoDerivatives License, available at <https://creativecommons.org/licenses/by-nc-nd/4.0/>

Peer reviewed

# Lichen planus secondary to rabies vaccination

Isa An<sup>1</sup>, Vasfiye Demir<sup>2</sup>, İbrahim İbiloğlu<sup>3</sup>, Sedat Akdeniz<sup>1</sup>

Affiliations: <sup>1</sup>Department of Dermatology, Dicle University Faculty of Medicine, Diyarbakır, Turkey, <sup>2</sup>Department of Family Medicine, Dicle University Faculty of Medicine, Diyarbakır, Turkey, <sup>3</sup>Department of Pathology, Dicle University Faculty of Medicine, Diyarbakır, Turkey

Corresponding Author: Isa An, Dicle University, Sur /Diyarbakır, Turkey, E-mail: is\_an89@hotmail.com

## Abstract

Lichen planus (LP) is a papulosquamous disease with distinctive clinical manifestations. The etiology of LP remains unknown. Recently, numerous cases of LP developing after hepatitis B, influenza, and combined DTaP-IPV-MMR vaccine have been described. In this report, we present the second case of LP after rabies vaccination.

*Keywords: lichen planus, vaccination induced eruptions, rabies vaccination*

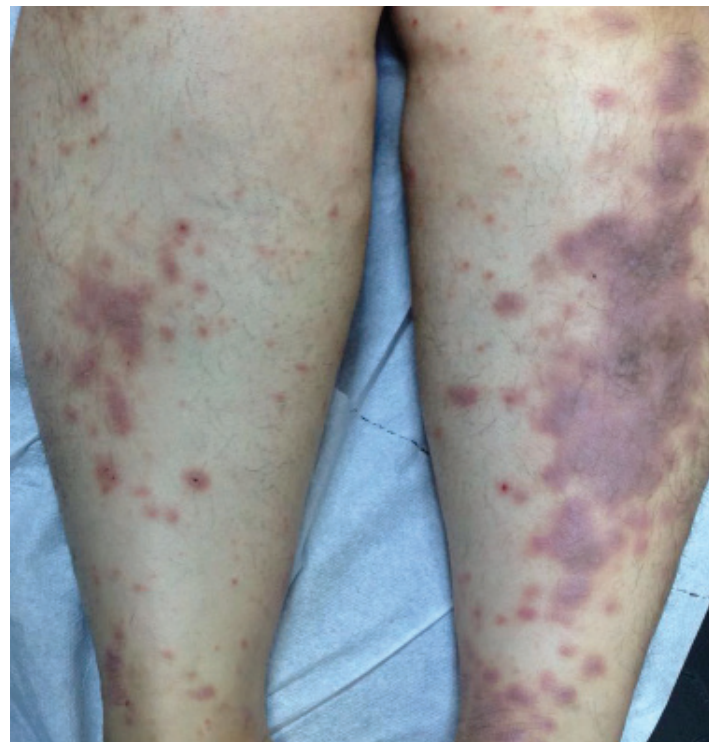
## Introduction

Lichen planus (LP) is a papulosquamous disease with distinctive clinical manifestations. Recently, numerous cases of LP developing after various vaccines have been reported [1]. However, whether the mechanism of the relationship between vaccines and LP is incidental or results from cell-mediated autoimmunity induced by the virus remains to be determined [2]. In this report, we present a patient who developed LP three weeks after rabies vaccination.

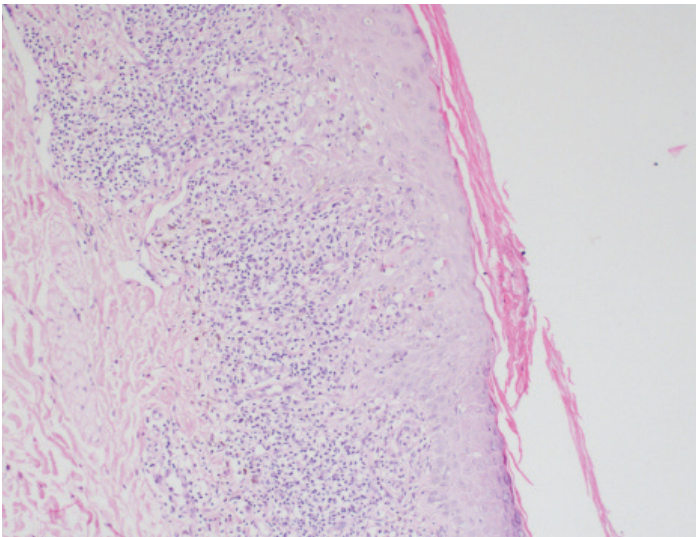
## Case Synopsis

A 32-year-old previously healthy woman presented with a two-week history of a pruritic skin eruption on the left forearm extensor surface, the extensor surfaces of both lower extremities, and the abdominal skin. The patient noticed the skin eruption three weeks after the first dose of rabies vaccination. No history of infection or drug use was reported two months before the skin eruption. The patient also had no history of systemic disease. Physical examination

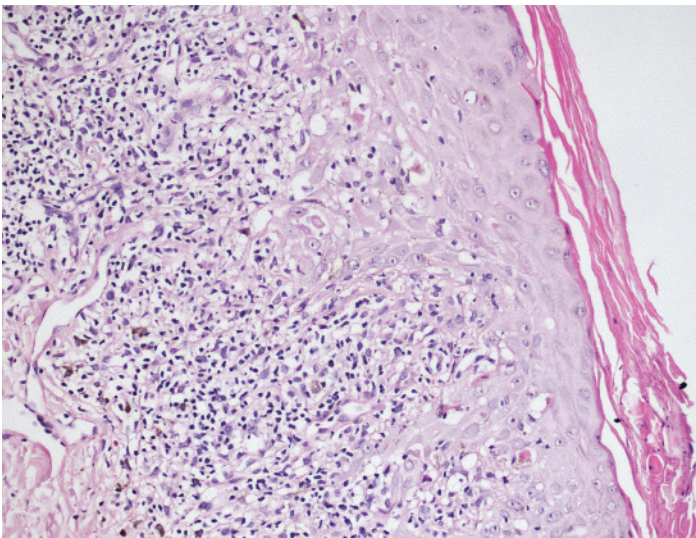
revealed numerous violaceous and erythematous polygonal papules and plaques of varying sizes distributed on the trunk and the lower extremities (**Figure 1**). No lesions in oral mucosa or in the genital region and the nails were detected. Punch biopsy was taken from the lesions on the anterior abdominal skin. Histopathologic examination revealed band-like lymphocytic infiltration in the upper dermis, wedge-shaped hypergranulosis, lymphocytic infiltration and vacuolar changes in the basal layer, civatte bodies, and melanin incontinence in the papillary dermis (**Figures 2, 3**). Based on the clinical and histopathologic findings, the patient was diagnosed as having lichen planus. Laboratory tests including



**Figure 1.** Numerous violaceous and erythematous polygonal papules and plaques of varying sizes distributed on the lower extremities.



**Figure 2.** Band-like lymphocytic infiltration in the upper dermis, wedge-shaped hypergranulosis, lymphocytic infiltration and vacuolar changes in the basal layer (H&E, 100x).



**Figure 3.** Lymphocyte exocytosis, Civatte bodies in the basal layer and the lower zones of the stratum malpighi, and melanin incontinence in the papillary dermis (H&E, 400x).

whole blood count and liver function tests were normal and HBV, HCV, HIV, VDRL serologies were also negative. Mometasone furoate was administered topically twice daily for four weeks. The lesions resolved with hyperpigmentation.

### Case Discussion

Lichen planus (LP) is an inflammatory dermatosis that involves mucosal membranes and hair follicles [3]. Although the exact etiology of LP remains unknown, immunological mechanisms are considered to play a role in the development of LP [2]. This theory is supported by the coexistence of

LP with numerous immune system diseases such as chronic hepatitis C and by the histopathologic evidence of the lymphocytic infiltration of LP in the dermis [4]. LP is also associated with a number of factors including exposure to drugs such as beta-blockers, streptomycin, D-penicillamine, mercury, dental restoration materials, infective agents, and environmental triggers [5]. Moreover, LP is considered as a dermatologic side effect of some vaccines [6]. Cases of LP developing after hepatitis B vaccination in adults and children have been commonly reported in the literature [1,2]. Recently, numerous cases of LP and lichenoid reactions developing after influenza and combined DTaP-IPV-MMR, and TDaP vaccine have been reported [6,7]. There is only one case report, which described lichenoid dermatitis that appeared at the vaccine injection site after pneumococcal vaccination [8]. To our knowledge, there has been only one case reported in the literature of LP developing after rabies vaccination [9].

Although the relationship between vaccines and lichenoid reactions remains unknown, this mechanism is considered to be associated with cell-mediated autoimmunity induced by the virus [9]. In addition, molecular mimicry is considered to be another alternative potential mechanism [7]. An immunologic response of the vaccine to some proteins may be a result of the cross-reaction with similar epitopes expressed on keratinocytes as in graft versus host disease [6,9]. T lymphocytes are considered to play a key role in this inflammatory reaction. This theory is supported by the frequent presence of lymphocytic infiltration in the dermis in histopathological sections [5,9]. Vaccine-induced LP may not be distinguished histopathologically from the classical LP [6]. The time period between vaccination and the onset of eruptions may vary from a few days to 6 months [7]. In our patient, the vaccine was administered on days 0, 3, 7, 14, and 28 after the first exposure to the putative causative drug and the lesions were noticed 3 weeks after the introduction of the first dose. The time of onset may provide an important clue to the diagnosis of the reactions related to the vaccine [4]. Since more severe lesions might occur in the patients that develop LP before the completion of the vaccination series, further vaccinations are not recommended. In our patient, the lesions occurred after the administration of the

fourth dose and the patient petitioned the physician in order to fully complete the vaccination series.

The case presented in this study is the second observation of LP after rabies vaccination in the literature. We consider that clinicians should be aware of the cutaneous side effects developing after rabies vaccination.

## References

1. Al-Khenaizan S. Lichen planus occurring after hepatitis B vaccination: a new case. *J Am Acad Dermatol*. 2001 Oct;45(4):614-5. [PMID:11568757]
2. Criado PR, de Oliveira Ramos R, Vasconcellos C, Jardim Criado RF, Valente NY. Two case reports of cutaneous adverse reactions following hepatitis B vaccine: lichen planus and granuloma annulare. *J Eur Acad Dermatol Venereol*. 2004 Sep;18(5):603-6. [PMID:15324406]
3. Ferrando MF, Doutre MS, Beylot Barry M, Durand I, Beylot C. Lichen planus following hepatitis B vaccination. *Br J Dermatol* 1998;139:350. [PMID:9767265]
4. Geier MR, Geier DA. Immunologic reactions and hepatitis B vaccine. *Ann Intern Med* 2001;134:1155. [PMID:11412070]
5. Kanwar AJ, De D. Lichen planus in childhood: report of 100 cases. *Clin Exp Dermatol* 2010; 35: 257–262. [PMID:19874373]
6. Ghasri P, Roehmholdt BF, Young LC. A case of lichen planus following Tdap vaccination. *J Drugs Dermatol* 2011; 10: 1067–1069. [PMID:22052280]
7. Sato NA, Kano Y, Shiohara T. Lichen planus occurring after influenza vaccination: report of three cases and review of the literature. *Dermatology* 2010; 221: 296–299. [PMID:21051866]
8. Cohen PR. Injection Site Lichenoid Dermatitis Following Pneumococcal Vaccination: Report and Review of Cutaneous Conditions Occurring at Vaccination Sites. *Dermatol Ther (Heidelb)*. 2016 Jun;6(2):287-98. doi: 10.1007/s13555-016-0105-x. Epub 2016 Mar 17. [PMID:26988991]
9. Ozbacivan O, Akarsu S, Ilknur T, Ozer E, Fetil E. Lichen planus after rabies vaccination. *Int J Dermatol*. 2015 Dec;54(12):e558-9. [PMID:26547616]