

# UC Davis

## Dermatology Online Journal

### Title

Linear verrucous hemangioma of the upper limb: a rare case

### Permalink

<https://escholarship.org/uc/item/3jj8k6pb>

### Journal

Dermatology Online Journal, 23(6)

### Authors

Nargis, Thansiha  
Pinto, Malcolm  
Bhat, Satish  
[et al.](#)

### Publication Date

2017

### DOI

10.5070/D3236035378

### Copyright Information

Copyright 2017 by the author(s). This work is made available under the terms of a Creative Commons Attribution-NonCommercial-NoDerivatives License, available at <https://creativecommons.org/licenses/by-nc-nd/4.0/>

Peer reviewed

# Linear verrucous hemangioma of the upper limb: a rare case

Thansiha Nargis<sup>1</sup> MBBS, Malcolm Pinto<sup>1</sup> MD, Satish Bhat<sup>2</sup> MS DNB-Mch DNB MRCS, Manjunath Shenoy M<sup>1</sup> MD DNB

Affiliations: <sup>1</sup>Department of Dermatology, Venereology and Leprosy, Yenepoya Medical College, Yenepoya University, Karnataka, India, <sup>2</sup>Department of Plastic surgery, Yenepoya Medical College, Yenepoya University, Mangalore, Karnataka, India

Corresponding Author: Dr. Thansiha Nargis, Department of Dermatology, Yenepoya Medical College, Yenepoya University, Deralakatte, Mangalore 575 018, Karnataka, India, Email: thansiha@yahoo.com

## Abstract

Verrucous hemangioma is a rare, congenital vascular malformation of the cutaneous and subcutaneous tissue. It is usually present at birth and gradually increases in size and number with age; occasionally it presents in later adulthood. It has a predilection for the lower extremity and usually presents as warty or hyperkeratotic, bluish and partly confluent papules and plaques. Verrucous hemangioma occurring in a linear pattern is an even more uncommon presentation and very few cases have been reported. We report a boy with verrucous hemangioma localized to the left upper extremity in a linear pattern. We also discuss management.

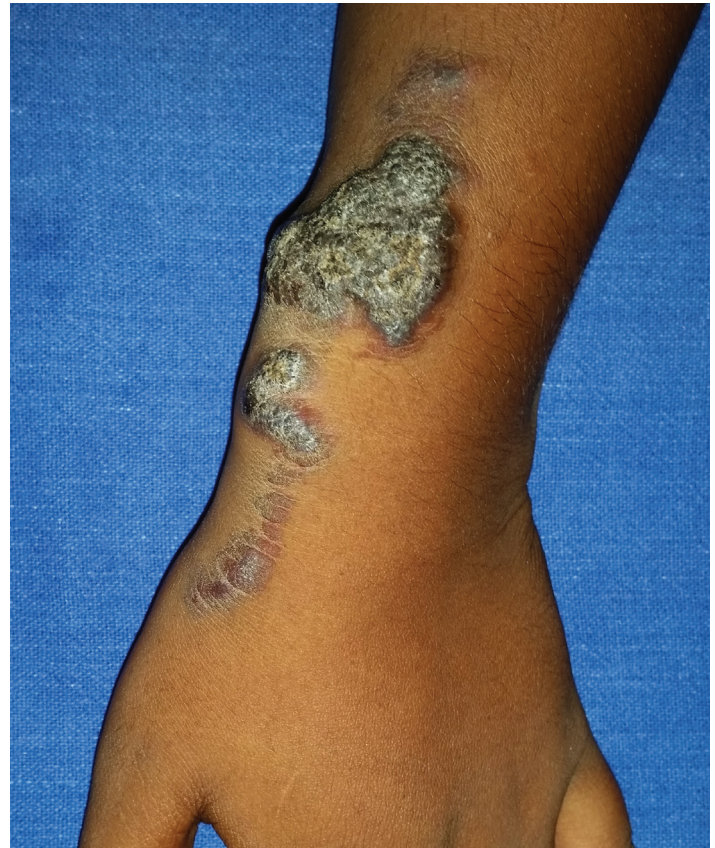*Keywords: verrucous hemangioma, blaschkoid, linear hemangioma*

## Introduction

Verrucous hemangioma is an uncommon capillary vascular malformation, often clinically mistaken for angiokeratoma circumscriptum [1]. Its onset is generally at birth or early childhood as a macule. This tends to grow proportionally to body development in the following years [2]. It characteristically presents as bluish hyperkeratotic papules or plaques over the legs and may be multiple, disseminated, or at times confined to digits [3]. These tumors tend to recur when treated by conventional cryotherapy or electrocoagulation methods. We report a boy with verrucous hemangioma showing a linear pattern [4, 5, 6].

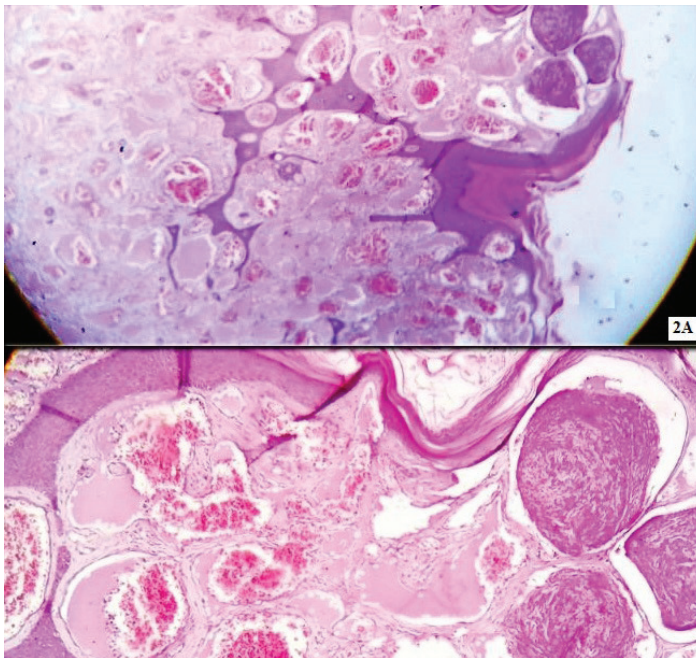
## Case Synopsis

A 7-year-old boy presented with multiple warty



**Figure 1.** Well-circumscribed, hyperkeratotic, erythematous plaques present in a linear pattern over the medial aspect of the left forearm extending to the hand.

plaques on an erythematous background over the left upper extremity. These lesions had been present since birth when it was noted to be a reddish macule. The lesions increased in size and number and became warty as the boy grew older. Cutaneous examination revealed well-circumscribed, hyperkeratotic, erythematous plaques present in a linear pattern over the medial aspect of the left upper extremity extending from the dorsum of hand to much of the forearm (**Figure 1**). Both upper limbs were of equal length and girth. The diagnoses of linear verrucous hemangioma and angiokeratoma circumscriptum



**Figure 2.** A) Histopathology showing epidermal hyperkeratosis, papillomatosis, irregular acanthosis and multiple vascular channels extending deep into the dermis and subcutis. (H&E, 10x). B) Histopathology showing multiple dilated vascular spaces in the dermis. (H&E, 40x).

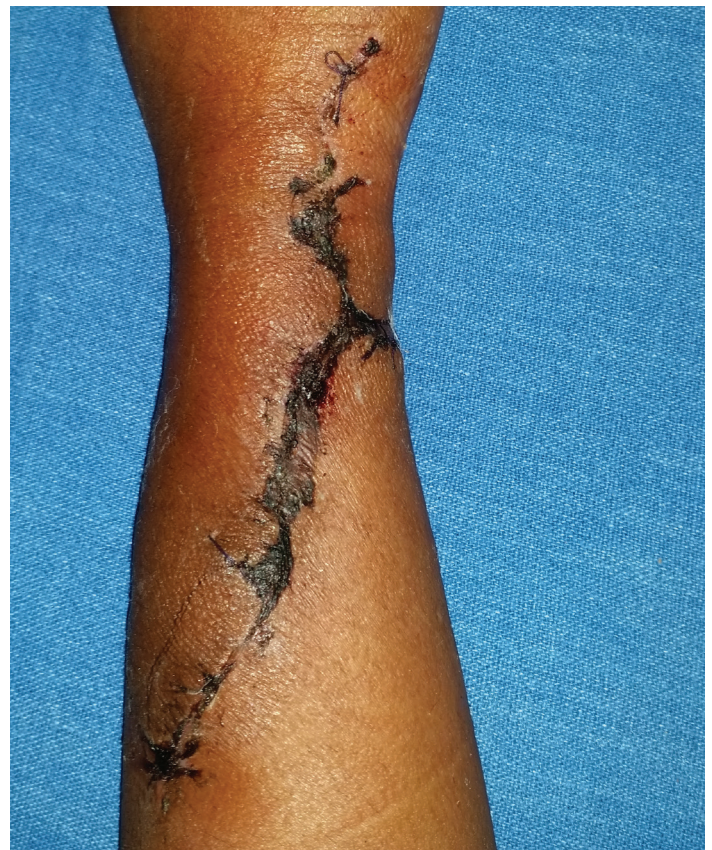were considered.

Skin biopsy was taken from the plaque. Histopathological examination showed epidermal hyperkeratosis, papillomatosis, and irregular acanthosis. The dermis showed numerous dilated blood vessels of various sizes extending down into the subcutaneous tissues (**Figure 2**). A diagnosis of blaschkoid verrucous hemangioma was made. The lesion was completely excised by the plastic surgeon (**Figure 3**) and no recurrence was noticed during the follow-up period of six months.

### Case Discussion

The International Society for the Study of Vascular Anomalies scheme classifies vascular anomalies into vascular malformations and vascular tumors. Verrucous hemangioma is a misnomer and has been classified as a slow flow venous malformation based on radiologic, histologic, and immunohistochemical studies [7, 8]. Verrucous hemangiomas are clinically and histopathologically distinct and can be distinguishable from other vascular malformations [1].

In a majority of the cases (around 95%), the site of occurrence is the lower extremity and these are mostly



**Figure 3.** Post operative photography following excision & flap reconstruction surgery.

unilateral [2]. It may also involve unusual anatomic locations such as the abdomen, arm, and glans penis [7]. The lesions in the early phase of evolution present as non-keratotic, soft, blue-red macules and plaques, which gradually become hyperkeratotic and verrucous. It has to be differentiated from infantile haemangioma, venous and/or lymphatic malformation, and angiokeratoma. Our case showed a linear configuration, which has been reported by a few authors and has been discussed in **Table 1** [3-6]. It has been proposed that these lesions may actually be following dermatomal patterns or that the linear arrangement represents genetic mosaicism [3].

Histopathologically it should be differentiated from other vascular anomalies by the presence of epidermal hyperplasia along with dilated vascular spaces extending deep into the dermis and subcutis. The abnormal vessels are separated by dermal fibrous tissue and have round, thick walls and a multilamellated basement membrane. A lymphatic specific endothelial marker such as podoplanin (D2-40) has been found to be elevated in verrucous hemangioma. The endothelial cells in verrucous

**Table 1:** Literature review of linear verrucous hemangiomas.

Article	Age	Sex	Race	Location	Morphology	Treatment	Follow up
Wenchester et al. (2000)	16 years	Male	Caucasian	Left shoulder, external part of the left arm, left hand	Multiple hyperkeratotic plaques of different sizes	Surgical excision and electrocautery	Loss of sensation of one finger and recurrence
Jain et al. (2008)	30 years	Female	Indian	Left lower leg	Multiple hyperkeratotic, bluish red plaques of different sizes	Surgical excision	-
Kaliyadan et al. (2009)	30 years	Male	Indian	Left lower leg	Multiple discrete, verrucous, bluish-black plaques	Surgical excision	-
Nupur et al. (2014)	7 years	Male	Indian	Right upper extremity (from tip of fingers to axilla)	Multiple hyperkeratotic, erythematous plaques	Surgical excision	-
Present Case	7 years	Male	Indian	Left upper extremity (from the dorsum of hand to forearm)	Multiple hyperkeratotic, erythematous plaques	Surgical excision and flap reconstruction	No recurrence on 6 month follow up

hemangioma are flat and stain strongly for CD34 [9]. There is currently no specific immunohistochemical marker for verrucous hemangioma and thus the diagnosis should be considered after careful clinicopathological correlation [10].

Various therapeutic options such as cryotherapy, ultrasonography, electrocautery, NdYAG laser for plaques, and pulsed dye laser for patches can be considered when excision is not possible [11-14]. Our case was surgically excised and showed no recurrence at 6 months, indicating that the surgery may be a good choice for treatment of a localized linear plaque.

In conclusion, our case was a verrucous hemangioma with classical clinical features. The plaque had a linear arrangement suggesting possible blaschkoid dermatosis. It also had a rare location on the upper limb. These features of blaschkoid pattern and upper limb involvement have rarely been reported in the literature [4].

## References

- Imperial R, Helwig EB. Verrucous hemangioma. A clinicopathologic study of 21 cases. *Arch Dermatol* 1967; 96: 247. [PMID:6038751]
- Rossi A, Bozzi M, Barra E. Verrucous hemangioma and angiokeratoma circumscriptum: clinical and histologic differential characteristics. *J Dermatol Surg Oncol* 1989; 15: 88-91. [PMID:2910968]
- Wentscher U, Happle R. Linear verrucous hemangioma. *J Am Acad Dermatol* 2000; 42: 516. [PMID:10688730]
- Jain VK, Aggarwal K, Jain S. Linear verrucous hemangioma on the leg. *Indian J Dermatol Venereol Leprol* 2008; 74: 656-8. [PMID:19172000]
- Kaliyadan F, Dharmaratnam AD, Jayasree MG, Sreekanth G. Linear verrucous hemangioma. *Dermatol Online J.* 2009; 15: 15. [PMID:19624993]
- Nupur P, Savant SS, Kumar P, Hassan S. Linear verrucous hemangioma. *Indian Dermatol Online J* 2014; 5: 136-7. [PMID:25593808]
- Prabhakar V, Kaliyadan F. A case of verrucous hemangioma and its dermoscopic features. *Indian Dermatology Online Journal.* 2015; 6(Suppl 1): S56-S58. [PMID:26904455]
- Moss C, Shahidullah H. Naevi and other Developmental Defects. In: Burns T, Breathnach S, Cox N, Griffiths C, editors. *Rook's Textbook of Dermatology*. 8th edition. West Sussex: Blackwell Publishing Ltd; 2010: 18.74.
- Schacht V, Dadras SS, Johnson L, Jackson D, Hong YK, Detmar M. Upregulation of the lymphatic marker podoplanin, a mucin-type transmembrane glycoprotein, in human squamous cell carcinomas and germ cell tumors. *Am J Pathol* 2005; 166: 913. [PMID:15743802]
- Clairwood MQ, Bruckner AL, Dadras SS. Verrucous hemangioma: a report of two cases and review of the literature. *J Cutan Pathol* 2011; 38: 740-46. [PMID:21649690]
- Wang G, Li C, Gao T. Verrucous hemangioma. *Int J Dermatol* 2004; 43: 745-746. [PMID:15485532]
- Maejima H, Katsuoka K, Sakai N, Uchinuma E. Verrucous hemangioma successfully treated using 13-MHz ultrasonography. *Eur J Dermatol* 2008; 18: 597. [PMID:18843800]
- Fatani M, Al Otaibi H, Mohammed M, Hegazy O. Verrucous Hemangioma Treated with Electrocautery. *Case Rep Dermatol.* 2016; 8: 112-7. [PMID: 27462218]
- Segura Palacios JM, Boixeda P, Rocha J, Alcántara González J, Alonso Castro L, de Daniel Rodríguez C. Laser treatment for verrucous hemangioma. *Lasers Med Sci* 2012; 27: 681-684. [PMID:21975688]