

# UC Davis

## Dermatology Online Journal

### Title

Cosmetic tattoo pigment reaction

### Permalink

<https://escholarship.org/uc/item/3rc114rg>

### Journal

Dermatology Online Journal, 22(7)

### Authors

Greywal, Tanya  
Cohen, Philip R

### Publication Date

2016

### DOI

10.5070/D3227031663

### Copyright Information

Copyright 2016 by the author(s). This work is made available under the terms of a Creative Commons Attribution-NonCommercial-NoDerivatives License, available at <https://creativecommons.org/licenses/by-nc-nd/4.0/>

Peer reviewed

## Case Presentation

### Cosmetic tattoo pigment reaction

Tanya Greywal, BA <sup>1</sup> and Philip R. Cohen, MD <sup>2</sup>

Dermatology Online Journal 22 (7): 9

<sup>1</sup> School of Medicine and <sup>2</sup> Department of Dermatology, University of California, San Diego, San Diego, California

### Correspondence:

Tanya Greywal, BA  
9767 Alto Drive  
La Mesa, CA 91941  
Email: tgreywal@gmail.com

Philip R. Cohen, MD  
10991 Twinleaf Court  
San Diego, CA 92131  
email: mitehead@gmail.com

---

## Abstract

### Background

Cutaneous reactions to tattoos are most commonly granulomatous or lichenoid.

### Purpose

We describe a woman who developed a lymphocytic reaction following a cosmetic tattoo procedure with black dye. The reaction occurred not only at the site of the tattoos (eyebrows and eyelash lines), but also in non-tattooed skin (bilateral malar cheeks).

### Methods and Materials

We reviewed PubMed for the following terms: cosmetic, dye, granuloma, granulomatous, lichenoid, lymphocytic, perivascular, pigment, pseudolymphoma, reaction, and tattoo. We also reviewed papers containing these terms and their references.

### Results

Histopathologic examination of the left eyebrow and left cheek punch biopsies showed predominantly a perivascular lymphocytic reaction secondary to exogenous tattoo pigment.

### Conclusions

Perivascular lymphocytic reaction is an uncommonly described complication of tattooing. Our patient had an atypical presentation since she had no prior tattoos, became symptomatic only a few days after the procedure, reacted to black dye, and involved skin both within and outside the confines of the tattoos. Her symptoms and lesions resolved after treatment with systemic and topical corticosteroids and oral antihistamines.

**Key words: cosmetic, dye, granuloma, granulomatous, lichenoid, lymphocytic, perivascular, pigment, pseudolymphoma, reaction, and tattoo**

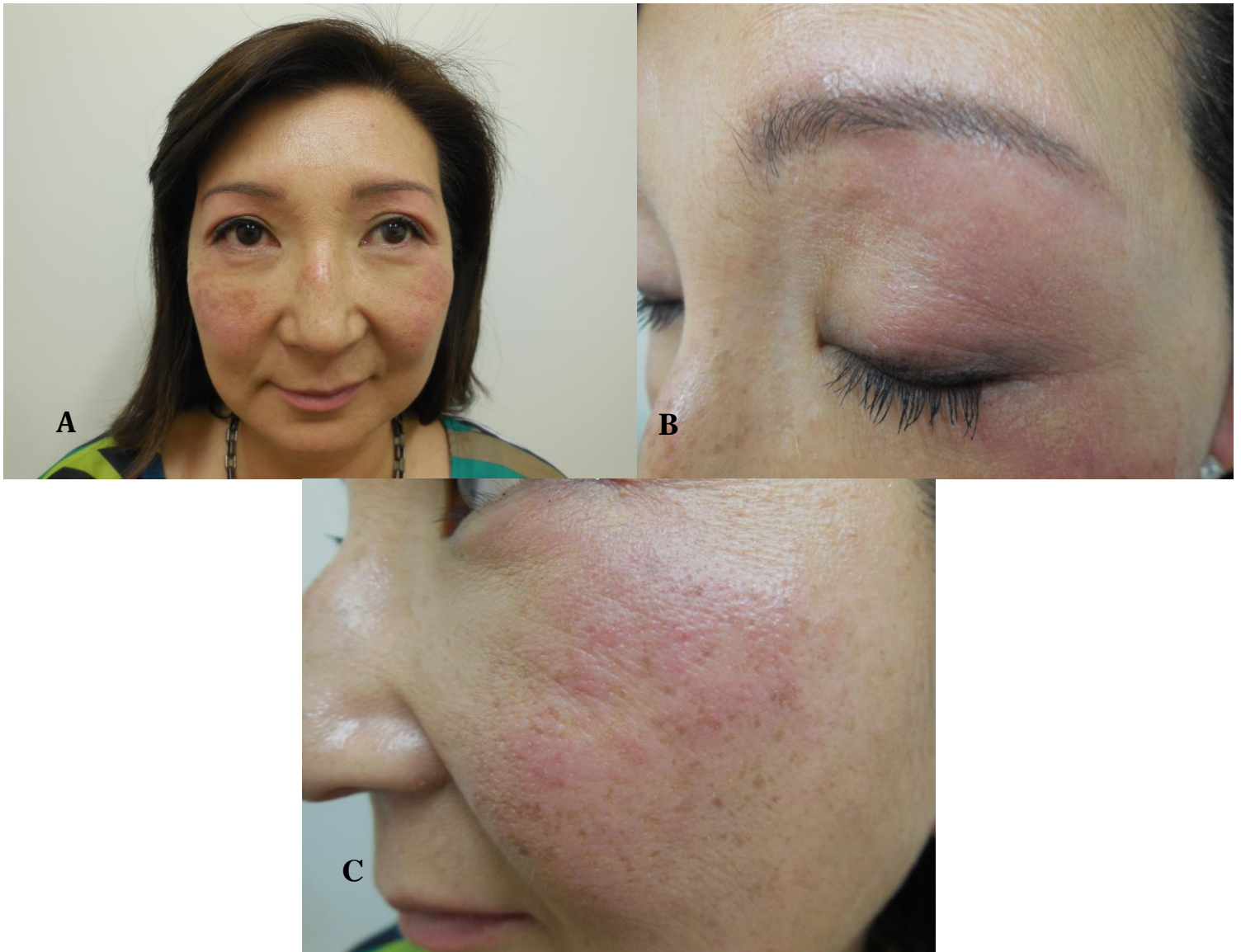## Introduction

Micropigmentation, a form of tattooing, has become a popular modality for the application of permanent cosmetic makeup. However, similar to tattooing, these procedures can result in inflammatory, infectious, and functional complications [1-7]. We describe a woman who underwent black tattooing of her eyebrows and eyelash lines. She subsequently developed a lymphocytic reaction that presented as pruritic, inflammatory papules and nodules both at the sites of the tattoos and distal, non-tattooed skin.

## Case Synopsis

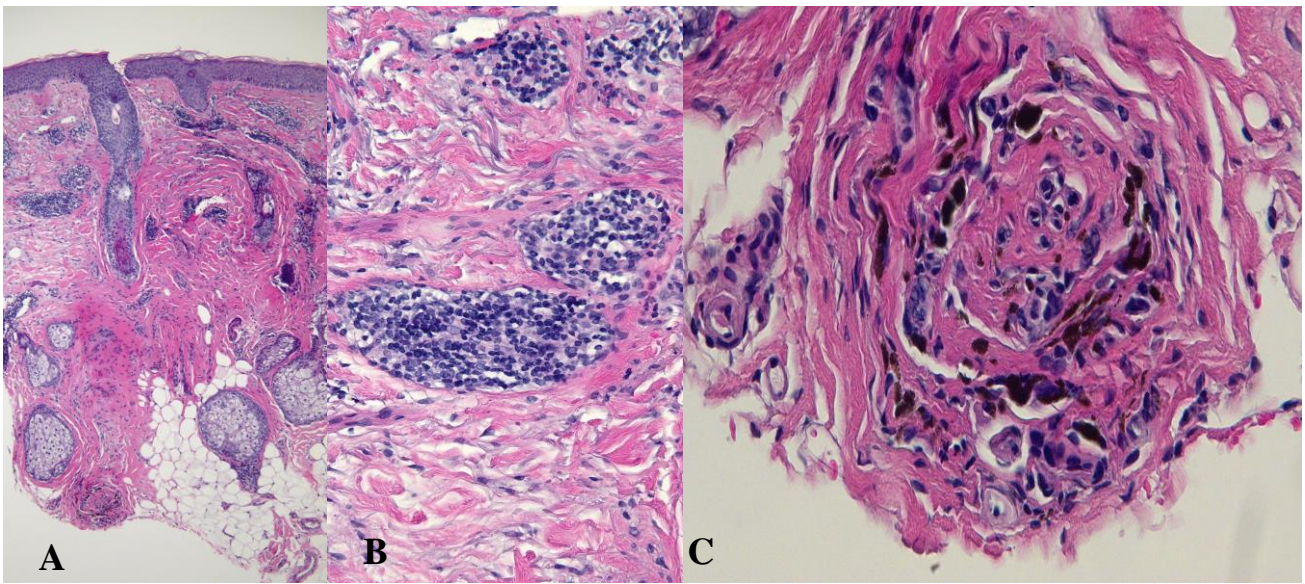
A 46-year-old woman developed a pruritic rash on her cheeks, eyelids, and eyebrows that appeared three days after a micropigmentation procedure of the eyebrows and upper eyelash lines. After the procedure, the involved areas became progressively more pruritic and developed red dermal papules and nodules. The patient was initially evaluated in a medical clinic and treated with prednisone 30 mg for 2 days and then 20 mg for 3 days. She experienced minimal improvement; within 1 week after completing the treatment, her facial lesions recurred.

She subsequently presented to a dermatology office for evaluation 3.5 weeks after receiving the tattoo. This corresponded to 5 days after completing a short course of low-dose corticosteroids and subsequent persistence and progression of her skin lesions. Cutaneous examination of the face showed not only red plaques with scale on the upper eyelids and extending to the eyebrows, but also erythematous dermal plaques on the bilateral malar cheeks (Figure 1).



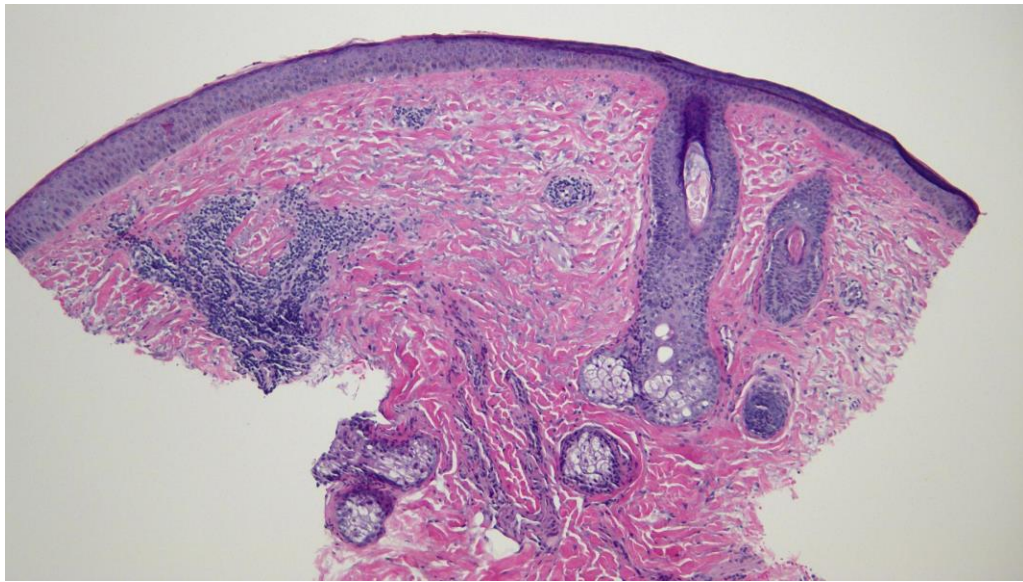**Figure 1 (a, b, and c).** Distant (a) and closer (b and c) views of erythematous plaques not only on the upper eyelids and eyebrows (a and b), but also on the bilateral cheeks (a and c).

A punch biopsy of left eyebrow and left cheek was performed. Histopathologic examination of the left eyebrow showed brown pigment in the deep dermis; in addition, a benign-appearing, sparse and dense, lymphocytic inflammation was noted around blood vessels and adnexal structures (Figure 2).



**Figure 2 (a, b and c).** Distant (a) and closer (b and c) views of the left eyebrow punch biopsy. There is perivascular and periadnexal benign-appearing lymphocytic inflammation (a and b). Brown pigment from the tattoo is present in the deep dermis (a and c) (Hematoxylin and eosin; a=4x, b=20x, c=40x).

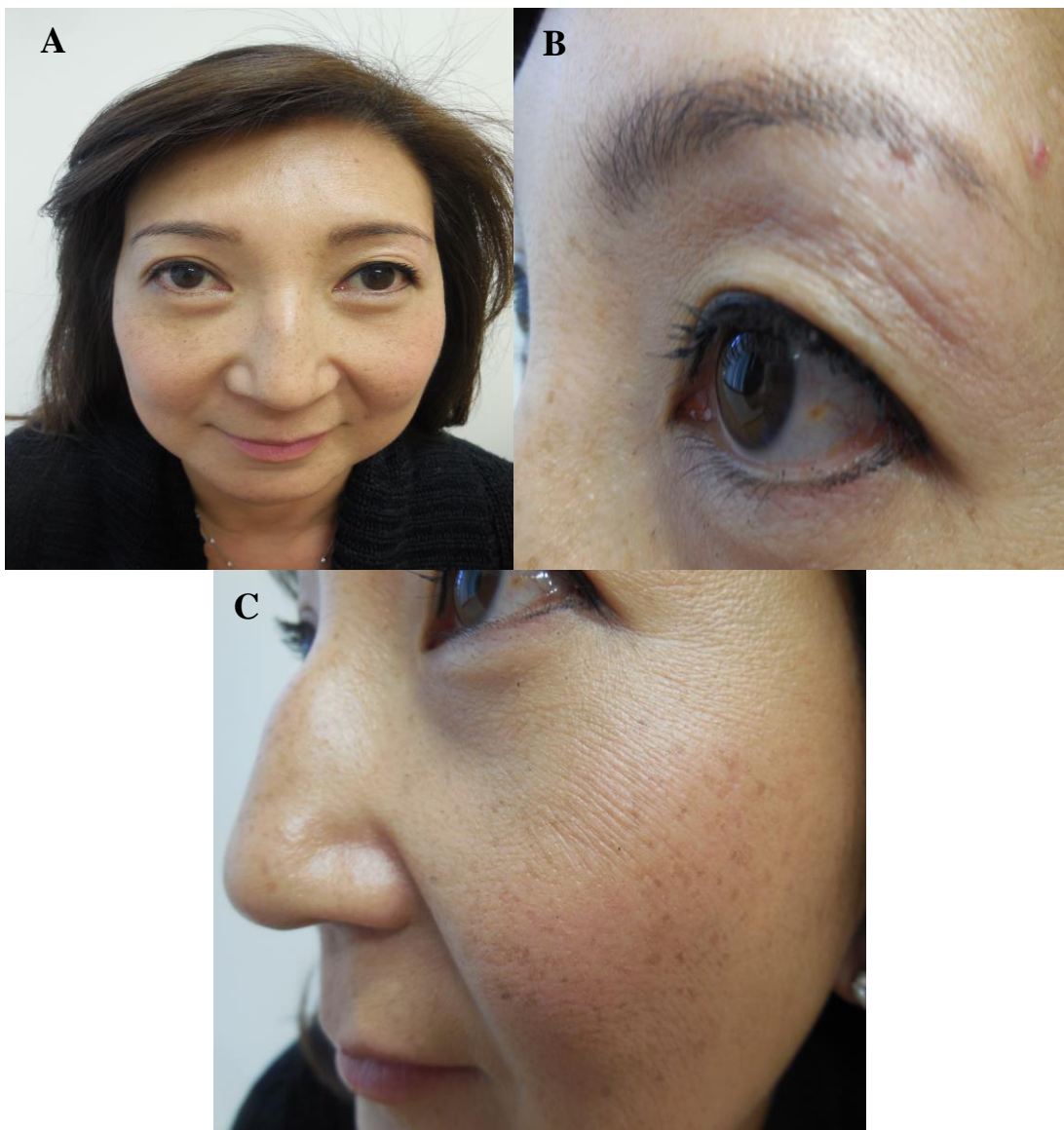
Tissue from the left cheek also revealed cells with the appearance of benign lymphocytes around blood vessels in the superficial and mid-dermis (Figure 3).



**Figure 3.** The left cheek punch biopsy shows cells with the appearance of benign lymphocytes around blood vessels in the superficial and mid-dermis (Hematoxylin and eosin; 10x).

Correlation of the clinical history and presentation with histopathologic analysis established the diagnosis of a lymphocytic reaction to exogenous tattoo pigment. She was treated with a higher dose of systemic corticosteroids for a longer duration, and with a more gradual tapering of the prednisone: 60 mg for 5 days, followed by 40 mg for 5 days and then 20 mg for 5 days. In addition, she also received fexofenadine 180 mg each morning and hydroxyzine 50 mg each evening. Topical management included fluocinonide 0.05% ointment twice daily.

Within 5 days, the pruritus resolved and the erythema and scaling diminished. Her cheek lesions also began to flatten. All of her skin lesions had resolved when she returned for follow-up after 3 weeks (Figure 4).



**Figure 4 (a, b, and c).** Distant (a) and closer (b and c) views show resolution of the tattoo-induced reaction on the upper eyelids and eyebrows (a and b) and bilateral cheeks (a and c) following treatment with corticosteroids (oral and topical) and oral antihistamines.

## Discussion

Cosmetic tattoos may result in cutaneous reactions to the pigment; these are most commonly either granulomatous or lichenoid [1,5,8-12]. The inflammatory component may consist of histiocytes in granulomatous reactions or lymphocytes in lichenoid reactions. A variety of granulomatous reactions have been described including granuloma annulare-like, perforating, tuberculoid, necrobiotic, and sarcoidal reaction or sarcoidosis [4,13-17].

Other tissue reactions have also been observed to tattoo pigment including eczematous reactions (such as allergic contact dermatitis and photodermatitis), pseudoepitheliomatous hyperplasia, and pseudolymphoma [1,8,9,18-23]. Rarely discoid lupus erythematosus, vasculitis, and sclerodermitis or morphea-like reactions have been described [18,24-26]. Mixed inflammatory reactions, consisting of lichenoid infiltrates with either granulomatous or pseudolymphomatous inflammation have also been described [21,27]. We are unaware of previous reports of a perivascular, and to a less extent periadnexal, lymphocytic inflammatory reaction following cosmetic tattoo to the eyebrows and eyelash lines, as observed in our patient.

Tattoos may also represent an immunocompromised cutaneous district enabling the development of other conditions or malignancies to occur at that location [28,29]. Warts, dermatologic disorders (psoriasis and vitiligo), cutaneous infections (such as community-acquired methicillin-resistant *Staphylococcus aureus*, Hansen's disease, human papillomavirus infection, molluscum contagiosum, superficial fungal infections, and non-tuberculous mycobacteria), and milia have been observed in tattoos [1,30,31]. In addition, cancers localized to tattoos include basal cell carcinoma, keratoacanthoma, lymphoma, and melanoma [17,32-35].

Tattoo-associated reactions usually occur over the tattoo itself [1,9,20]. However, as presented in our patient, the reaction can occur on non-tattooed skin [20]. Indeed, albeit less commonly, a generalized reaction to tattoo pigment can occur [36].

There is an extremely variable latency period between the time of the tattoo placement and the onset of symptoms, ranging from a few months to several years [9,18,20,37]. Yet, a 49-year-old man developed a rapid reaction within weeks of tattooing; the investigators attributed the rapidity of his reaction to prior sensitization to tattoo pigment [37]. Our patient had no prior tattoos; therefore, it is unusual that she began experiencing symptoms and skin lesions only days after receiving her tattoo.

Tattoo reactions often occur in response to red tattoo pigment [9,11,12,16-18,20,21,24,38-40]. Blue, green, and purple pigments are also common culprits [16,18,20,27,38-40]. Black tattoo, as used in our patient, is rarely reported [8,36].

The pathogenesis of tattoo-induced lymphocytic reaction is likely the result of an immunologic response to the tattoo pigment salts and metals. The tattoo dye in the dermis acts as an antigen that stimulates a local inflammatory reaction with lymphocyte proliferation [9,11,12,18,20,21,39]. Our patient may have been previously sensitized to one of the ingredients in her tattoo, thereby resulting in her prompt reaction following her tattooing.

Spontaneous resolution of cosmetic tattoo reaction has been observed [7,41]. However, the treatment of tattoo-induced reactions usually requires the application of a potent topical corticosteroid [9,18,20]. In addition, intralesional or systemic corticosteroids, as in our patient, may also be necessary [9,18,20]. Individual reports also describe successful management with other topical (tacrolimus) or systemic (hydroxychloroquine) agents [6,20,42].

Laser may be helpful in the management of pseudolymphoma caused by tattoo. Carbon dioxide and Q switched Nd:YAG lasers may aid in reducing pigment [20,21,38]. Yet, laser treatment of tattoo-induced inflammation may exacerbate the immunologic reaction by spreading the pigment [37].

## Conclusion

Tattoo-associated cutaneous reactions typically present as erythematous and pruritic papules, plaques, and nodules that develop months to years after tattooing with red, green, blue, or purple pigment. Our patient had perivascular lymphocytic inflammation. Her presentation was unusual since she had no prior tattoos, became symptomatic only a few days after the procedure, reacted to black dye, and involved skin both within and outside the confines of her tattoos. Our patient initially received inadequate treatment with systemic corticosteroids; the dose was insufficient to resolve the reaction and the duration of therapy was too brief to prevent recurrence. Her tattoo-induced reaction was successfully managed without relapse when she received oral prednisone at a higher dose, for a longer period of treatment, and with a slower taper of the medication. Topical therapy with a high potency corticosteroid ointment and systemic antihistamines also promoted reduction of her tattoo-associated symptoms and lesions. Early diagnosis and intervention of tattoo-associated cutaneous reaction should be considered in individuals who have previously received a tattoo and subsequently develop new skin lesions that involve the tattooed skin, the non-tattooed skin, or both.

## References

1. Bassi A, Campolmi P, Cannarozzo G, Conti R, Bruscinò N, Gola M, Ermini S, Massi D, Moretti S. Tattoo-associated skin reaction: the importance of an early diagnosis and proper treatment. *Biomed Res Int*. 2014;2014:1-7. PMID: 25147796.
2. Ortiz AE, Alster TS. Rising concern over cosmetic tattoos. *Dermatol Surg*. 2012;38(3):424-429. PMID: 22093105.
3. Vagefi MR, Dragan L, Hughes SM, Klippenstein KA, Seiff SR, Woog JJ. Adverse reactions to permanent eyeliner tattoo. *Ophthal Plast Reconstr Surg*. 2006;22(1):48-51. PMID: 16418666.
4. Matsumura W, Ito K, Fujita Y, Watanabe E, Iitani MM, Nomura T, Sasaki M, Kobayashi H. Tuberculoid reaction to a cosmetic tattoo on the lips. *Eur J Dermatol*. 2015;25(5):485-487. PMID: 25961172.
5. Quint KD, Genders RE, Vermeer MH. A delayed granulomatous reaction to a cosmetic tattoo of the eyebrows: a report of total regression after intralesional corticosteroid injections. *Dermatol Surg*. 2012;38(6):951-953. PMID: 22380714.
6. Wylie G, Gupta G. Lip-enhancing tattoo reaction resolving with topical tacrolimus. *Clin Exp Dermatol*. 2008;33(4):505-506. PMID: 18498403.
7. Jones B, Oh C, Egan CA. Spontaneous resolution of a delayed granulomatous reaction to cosmetic tattoo. *Int J Dermatol*. 2008;47(1):59-60. PMID: 18173605.
8. Shinohara MM, Nguyen J, Gardner J, Rosenbach M, Elenitsas R. The histopathological spectrum of decorative tattoo complications. *J Cutan Pathol*. 2012;39:1110-1118. PMID: 23046178.
9. Simunovic C, Shinohara MM. Complications of decorative tattoos: recognition and management. *Am J Clin Dermatol*. 2014;15:525-536. PMID: 25385257.

10. Guerra JR, Alderuccio JP, Sandhu J, Chaudhari S. Granulomatous tattoo reaction in a young man. *Lancet*. 2013;382(9888):284. PMID: 23870530.
11. Høgsberg T, Thomsen GM, Serup J. Histopathology and immune histochemistry of red tattoo reactions. Interface dermatitis is the lead pathology, with increase in T-lymphocytes and Langerhans cells suggesting an allergic pathomechanism. *Skin Res Technol*. 2015;21(4):449-458. PMID: 26031754.
12. Garcovich S, Carbone T, Avitabile S, Nasorri F, Fucci N, Cavani A. Lichenoid red tattoo reaction: histological and immunological perspectives. *Eur J Dermatol*. 2012;22(1):93-96. PMID: 22237036.
13. Ali SM, Gilliam AC, Brodell RT. Sarcoidosis appearing in a tattoo. *J Cutan Med Surg*. 2008;12(1):43-48. PMID: 18258148.
14. Kashyap S, Shanker V, Khopkar U. Granuloma annulare-like palisading as a histological reaction to a tattoo. *Indian J Dermatol Venereol Leprol*. 2014;80(5):465-467. PMID: 25201856.
15. Wood A, Hamilton SA, Wallace WA, Biswas A. Necrobiotic granulomatous tattoo reaction: report of an unusual case showing features of both necrobiosis lipoidica and granuloma annulare patterns. *Am J Dermatopathol*. 2014;36(8):e152-155. PMID: 24335518.
16. Sanghavi SA, Dongre AM, Khopkar US. Tattoo reactions—an epidemic on the surge: a report of 3 cases. *Indian J Dermatol Venereol Leprol*. 2013;79(2):231-234. PMID: 23442464.
17. Sweeney SA, Hicks LD, Ranallo N, Snyder N 4<sup>th</sup>, Soldano AC. Perforating granulomatous dermatitis reaction to exogenous tattoo pigment: a case report and review of the literature. *Am J Dermatopathol*. 2013;35(7):754-756. PMID: 21986232.
18. Pasolini G, Ghidini P, Arisi M, Pedretti A, Ungari M, Pinton PC. Pseudolymphoma tattoo-induced. *Dermatol Reports*. 2011;3:e47. PMID: 25386299.
19. Walter JB, Bailey D. Neoplasms of lymphoid, mononuclear, hematopoietic systems (chapter 27). Section: Pseudolymphomas: Tattoo reaction. In: Okun MR, Edelman LM, Fisher BK, eds. *Gross and microscopic pathology of the skin*. 2<sup>nd</sup> edition. Boston, MA: Dermatopathology Foundation Press, Inc; 1988:1265-1347(1296-1297).
20. Patrizi A, Raone B, Savoia F, Bacci F, Pileri A, Gurioli C, Neri I. Tattoo-associated pseudolymphomatous reaction and its successful treatment with hydroxychloroquine. *Acta Derm Venereol*. 2009;89:327-328. PMID: 19479145.
21. Kuo WE, Richwine EE, Sheehan DJ. Pseudolymphomatous and lichenoid reaction to a red tattoo: a case report. *Cutis*. 2011;87:89-92. PMID: 21416776.
22. Kazlouskaya V, Junkins-Hopkins JM. Pseudoepitheliomatous hyperplasia in a red pigment tattoo: a separate entity or hypertrophic lichen planus-like reaction? *J Clin Aesthet Dermatol*. 2015;8(12):48-52. PMID: 26705448.
23. Breza TS Jr, O'Brien AK, Glavin FL. Pseudoepitheliomatous hyperplasia: an unusual tattoo reaction. *JAMA Dermatol*. 2013;149(5):630-631. PMID: 23677107.
24. Kluger N, Mathelier-Fusade P, Moguelet P. Scleroderma-like reaction restricted to the red parts of a tattoo. *Acta Derm Venereol*. 2009;89(1):95-96. PMID: 19197555.
25. Mahalingam M, Kim E, Bhawan J. Morphea-like tattoo reaction. *Am J Dermatopathol*. 2002;24(5):392-395. PMID: 12357198.
26. Deeken A, Jefferson J, Hawkinson D, Fraga GR. Localized chronic fibrosing vasculitis in a tattoo: a unique adverse tattoo reaction. *Am J Dermatopathol*. 2014;36(4):e81-83. PMID: 24736671.
27. Feldstein S, Jagdeo J. Successful treatment of a lichenoid-like granulomatous reaction to purple tattoo pigment with intralesional kenalog. *J Drugs Dermatol*. 2015;14(6):638-640. PMID: 26091391.
28. Piccolo V, Baroni A, Russo T, Schwartz RA. Ruocco's immunocompromised cutaneous district. *Int J Dermatol*. 2015;55(2):135-141. PMID: 26475059.
29. Ruocco V, Ruocco E, Piccolo V, Brunetti G, Guerrero LP, Wolf R. The immunocompromised district in dermatology: a unifying pathogenic view of the regional immune dysregulation. *Clin Dermatol*. 2014;32(5):569-576. PMID: 25160098.
30. Huynh TN, Jackson JD, Brodell RT. Tattoo and vaccination sites: Possible nest for opportunistic infections, tumors, and dysimmune reactions. *Clin Dermatol*. 2014;32(5):678-684. PMID: 25160110.
31. Miller LM, Schwartz JT, Cho S. Milia: a unique reaction to tattoos. *Cutis*. 2011;87(4):195-196. PMID: 21644494.
32. Sanguenza OP, Yadav S, White CR Jr, Brazier RM. Evolution of B-cell lymphoma from pseudolymphoma: a multidisciplinary approach using histology, immunohistochemistry, and Southern blot analysis. *Am J Dermatopathol*. 1992;14:408-413. PMID: 1415958.
33. Kluger N, Minier-Thoumin C, Plantier F. Keratoacanthoma occurring within the red dye of a tattoo. *J Cutan Pathol*. 2008;35(5):504-507. PMID: 17976209.
34. Joyce CW, Duff G, McKenna D, Regan PJ. Malignant melanoma arising in red tattoo ink. *Arch Plast Surg*. 2015;42(4):475-477. PMID: 26217569.
35. Nolan KA, Kling M, Birge M, Kling A, Fishman S, Phelps R. Melanoma arising in a tattoo: case report and review of the literature. *Cutis*. 2013;93(5):227-230. PMID: 24343207.
36. Jacks SK, Zirwas MJ, Mosser JL. A case of a generalized lichenoid tattoo reaction. *J Clin Aesthet Dermatol*. 2014;7(8):48-50. PMID: 25161761.
37. Gaudron S, Ferrier-Le Bouedec MD, Franck F, D'Incan M. Azo pigments and quinacridone induced delayed hypersensitivity in red tattoos. *Contact Dermatitis*. 2015;72:97-105. PMID: 25441375.

38. Cruz FAM, Frigério RM, Arruda LHF, Lage D, Zaniboni MC. Reactions to the different pigments in tattoos: a report of two cases. *An Bras Dermatol*. 2010;85:708-711. PMID: 21152800.
39. Juhas E, English JC III. Tattoo-associated complications. *J Pediatr Adolesc Gynecol*. 2013;26:125-129. PMID: 23287600.
40. Blumental G, Okun MR, Ponitch JA. Pseudolymphomatous reaction to tattoos. Report of three cases. *J Am Acad Dermatol*. 1982;6:485-488. PMID: 7076903.
41. Gutermuth J, Hein R, Fend F, Ring J. Cutaneous pseudolymphoma arising after tattoo placement. *J Eur Acad Dermatol Venereol*. 2007;21:536-578. PMID: 17374006.
42. Campbell FA, Gupta G. Lichenoid tattoo reaction responding to topical tacrolimus ointment. *Clin Exp Dermatol*. 2006;31(2):293-294. PMID: 16487120.

Figures: Need Advice on Where to place/how to label within article please: