

UC Davis

Dermatology Online Journal

Title

Atypical propylthiouracil-induced ANCA-positive vasculitis: report of a case with unusual clinical and histopathologic findings

Permalink

<https://escholarship.org/uc/item/3v22b88d>

Journal

Dermatology Online Journal, 21(8)

Authors

Mull, Jamie L
Solus, Jason F
Mutizwa, Misha M
[et al.](#)

Publication Date

2015

DOI

10.5070/D3218028433

Copyright Information

Copyright 2015 by the author(s). This work is made available under the terms of a Creative Commons Attribution-NonCommercial-NoDerivatives License, available at <https://creativecommons.org/licenses/by-nc-nd/4.0/>

Peer reviewed

Case presentation

Atypical propylthiouracil-induced ANCA-positive vasculitis: report of a case with unusual clinical and histopathologic findings

Jamie L Mull MD¹, Jason F Solus MD², Misha M Mutizwa MD³, Herbert C Chiang MD¹, Ilana S Rosman MD², Amy Musiek MD¹

Dermatology Online Journal 21 (8): 9

¹Washington University School of Medicine, Division of Dermatology, and Barnes-Jewish Hospital, Saint Louis, MO.

²Washington University School of Medicine, Division of Dermatology and Department of Pathology and Immunology, Saint Louis, MO.

³Temple University School of Medicine, Department of Dermatology, and Temple University Hospital, Philadelphia, PA.

Correspondence:

Jamie L. Mull, MD
Address: 4961 Laclede Ave #202 Saint Louis, MO 63108
Phone: 812-459-1543
E-mail: jmull@dom.wustl.edu

Abstract

The side effects of propylthiouracil, including cytopenia and vasculitis, are well established. We present an interesting case in which cytopenia and cutaneous vasculopathy occurred concomitantly in a critically ill patient. The patient was initially treated for suspected infection until dermatologic and rheumatologic workup revealed ANCA-positivity and vasculopathy on histopathology, most consistent with an atypical presentation of ANCA-positive vasculitis. Upon initiation of immunosuppressive therapy, the patient's condition rapidly improved emphasizing the importance of early recognition of this condition.

Keywords: propylthiouracil, ANCA vasculitis, vasculopathy

Introduction

Propylthiouracil (PTU), used in the treatment of hyperthyroidism, has been implicated in a variety of dermatological conditions, most notably an anti-neutrophil cytoplasmic antibody (ANCA)-positive vasculitis. Additionally, PTU-induced agranulocytosis and pancytopenia are known to occur [1]. We present a case of a PTU-induced pancytopenia occurring concomitantly with a clinically-consistent cutaneous ANCA-positive vasculitis with an unusual histologic presentation of vasculopathy.

Case synopsis

A 44-year-old woman with Graves' disease treated with PTU for four years presented with a three-week history of pharyngitis, fatigue and anorexia with a 25-pound weight loss. Her TSH level was 0.27. She was afebrile and pancytopenic. After a

hematologic workup, the pancytopenia was attributed to PTU and the drug was discontinued, although her blood cell and platelet counts continued to decline over the next few days with a white blood cell count as low as 500, hemoglobin of 6.2 g/dL and platelet count of 17,000. During this time, the patient developed upper eyelid edema and purpuric plaques on her forehead and distal extremities, some of which progressed to hemorrhagic bullae (Figure 1). She was started on broad-spectrum antibiotics, although an extensive infectious workup was negative.

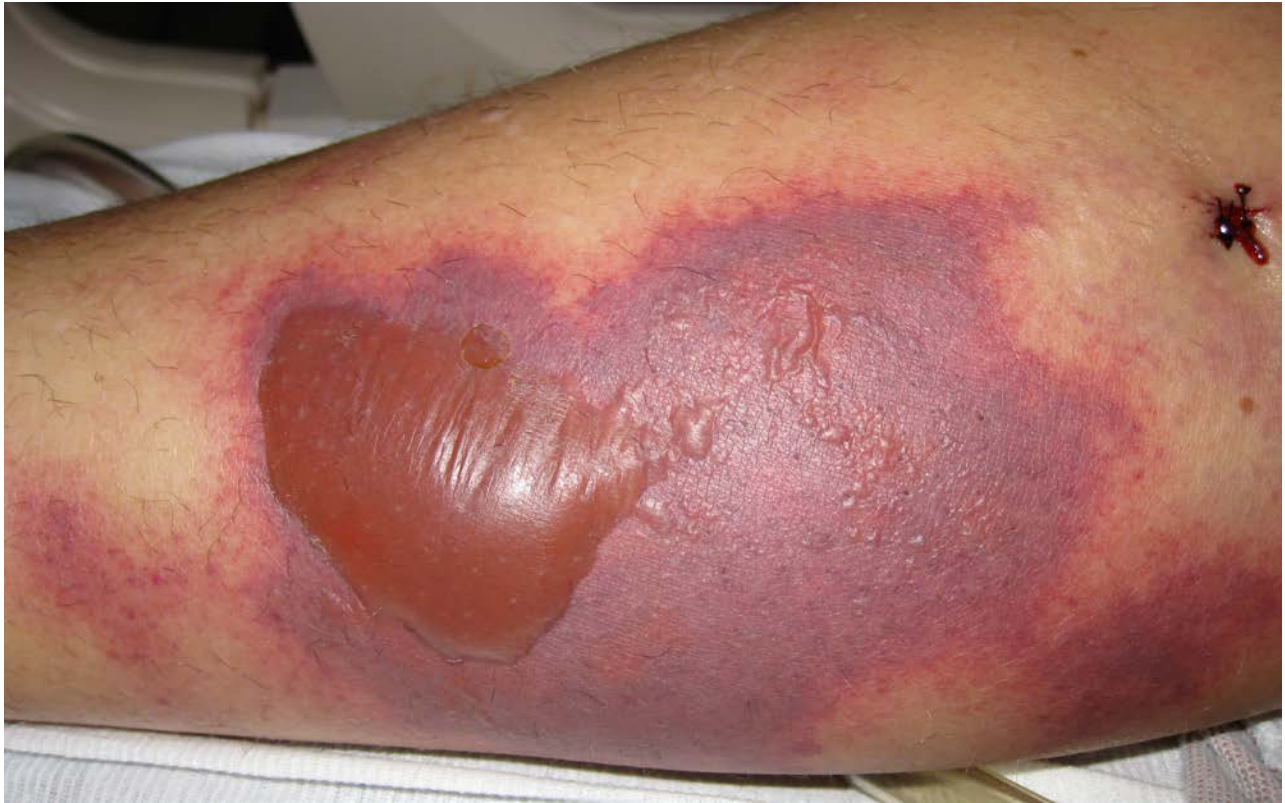

Figure 1. Purpuric plaque with hemorrhagic bulla on lower extremity

A dermatology consultation was requested and the histologic examination of a skin biopsy from the right lower extremity revealed numerous fibrin thrombi and focal vascular injury with rare neutrophils in vessel walls, compatible with vasculopathy (Figure 2, 3).

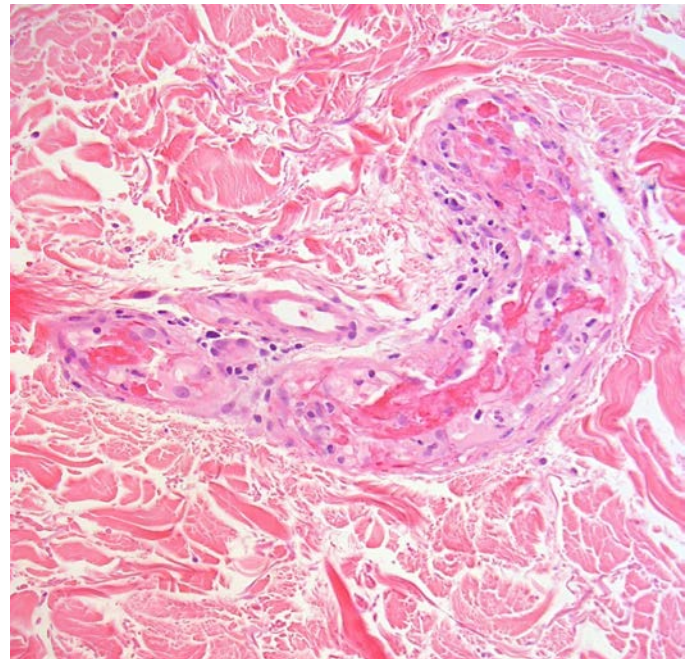
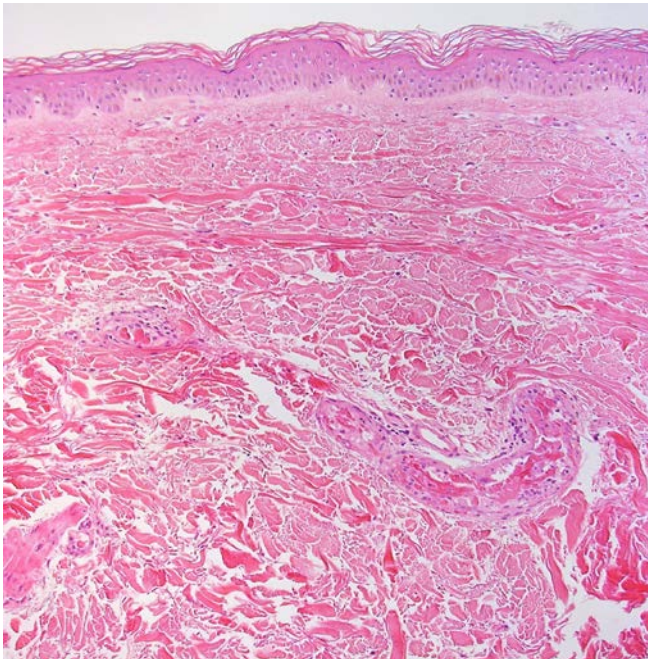


Figure 2. (Low power H&E – 100X) There are fibrin thrombi present within blood vessel lumens. **Figure 3.** (High power H&E – 200X) There is focal vascular injury with fibrin thrombi and neutrophils present within the vascular wall.

Disseminated intravascular coagulation was not suspected as there was no elevation in the activated partial thromboplastin time (27.4), only mild elevation of the INR (1.4), a normal fibrinogen level (350), and no schistocytes on peripheral blood smear. The d-dimer level was elevated (4,999) but was considered to be an acute phase reactant. The erythrocyte sedimentation rate and C-reactive protein level were elevated at 95 and 132, respectively. Urinalysis demonstrated leukocytes, red blood cells, and protein. A serologic workup revealed ANCA positivity (1:80). The C3 level was within normal range and the C4 level was low at 7.8. Tests for anti-nuclear antibody, anti-histone antibody, and cryoglobulins were negative.

Based on the clinical picture, a diagnosis of PTU-induced vasculitis was made despite no signs of leukocytoclastic vasculitis on biopsy. The patient also developed respiratory failure, presumably secondary to vasculitis, and required intubation for a brief time. She was initially treated with high-dose methylprednisolone and after four days was switched to oral prednisone 60mg daily as her condition began to improve. The pancytopenia was treated with G-CSF. Her symptoms, purpura, and cell counts continued to improve and she was discharged on a corticosteroid taper.

Discussion

Even though our biopsy did not demonstrate vasculitis, based on the clinical presentation and ANCA positivity, this case is best categorized as PTU-induced vasculitis with atypical histologic findings. Propylthiouracil is the most common medication associated with drug-induced ANCA-positive vasculitis [2]. The pathogenesis has not been elucidated, although accumulation of the drug in neutrophils is thought to play a role [3]. The onset of symptoms is quite broad, beginning weeks to years after starting the medication [4]. Like other small-vessel vasculitides, the presentation can be quite variable, ranging from minimal cutaneous involvement to widespread systemic disease. It should be noted that PTU-induced vasculitis does not always involve the skin. In fact, renal involvement is the most common finding with cutaneous involvement seen in approximately 30 % of cases [3].

Although leukocytoclastic vasculitis is the typical pattern of vascular injury in PTU-induced vasculitis, extensive intravascular thrombosis, as is seen in our case, has been reported and may be under-recognized in cases of PTU-induced vasculitis [5,6]. This case was unusual in that there were no features of vasculitis on histologic exam, only vasculopathy. This may be attributed to sampling bias based on the timing or location of the skin biopsy as the primary process is understood to be a vasculitis with secondary vasculopathic changes. Disseminated intravascular thrombosis without histologic evidence of vasculitis has been seen in levamisole-induced vasculopathy, which is also an ANCA-mediated condition with a similar pathogenesis to PTU-induced vasculitis [7]. Further study may confirm whether intravascular thrombosis is a common finding in other cases of PTU-induced vasculitis. Vasculopathy may be an underreported or unusual feature of PTU-induced vasculitis, and in the proper clinical setting, this finding should alert the physician to the diagnosis.

Patients with this condition generally do well following cessation of the anti-thyroid medication, supportive measures, and immunosuppressive therapy [4]. Anti-neutrophil cytoplasmic antibody titers usually fall but may remain positive [3]. The impact that the coexisting drug-induced pancytopenia may have on prognosis is unclear, although based on this patient's clinical improvement we would expect most to do quite well with rapid withdrawal of the causative drug. Dermatologists can be helpful in distinguishing between infectious and inflammatory conditions in these cases; rapid recognition of PTU-associated vasculitis is essential to minimizing complications. Our patient experienced life-threatening pancytopenia and respiratory failure and was treated for several days with antibiotics before a dermatology consultation was requested.

References

1. Cooper DS. The side effects of antithyroid drugs. *The Endocrinologist*. 1999; 9(6): 457-467.
2. Gao Y, Zhao MH. Review article: Drug-induced anti-neutrophil cytoplasmic antibody-associated vasculitis. *Nephrology* 2009; 14: 33-41. [PMID: 19335842]
3. Gunton JE, Stiel J, Caterson RJ, McElduff A. Anti-thyroid drugs and antineutrophil cytoplasmic antibody positive vasculitis. A case report and review of the literature. *J Clin Endocr Metab* 1999; 84(1): 13-16. [PMID 9920055]
4. Chastain MA, Russo GG, Boh EE, Chastain JB, Falabella A, Millikan LE. Propylthiouracil hypersensitivity: Report of two patients with vasculitis and review of the literature. *JAAD* 1999; 41(5): 757-764. [PMID 10534640]
5. Park KEJ, Chippis DR, Benson EM. Necrotizing vasculitis secondary to Propylthiouracil presenting as purpura fulminans. *Rheumatology* 1999; 38(8): 790-792. [PMID 10501437]
6. Mahmood T, Delacerda A, Fiala K. Painful purpura on bilateral helices. *JAMA Dermatol* 2015; 151(5): 551-52. [PMID 25549349].
7. Tran H, Tan D, Marnejon TP. Cutaneous vasculopathy associated with levamisole-adulterated cocaine. *Clin Med Res* 2013; 11(1): 26-30. [PMID 22723468].