

UC Irvine

Clinical Practice and Cases in Emergency Medicine

Title

Point-of-care Ultrasound in the Diagnosis of Calciphylaxis

Permalink

<https://escholarship.org/uc/item/46s6s7nz>

Journal

Clinical Practice and Cases in Emergency Medicine, 4(3)

Authors

Tobarran, Natasha
Collin, Mark

Publication Date

2020

Copyright Information

Copyright 2020 by the author(s). This work is made available under the terms of a Creative Commons Attribution License, available at <https://creativecommons.org/licenses/by/4.0/>

Peer reviewed

Point-of-care Ultrasound in the Diagnosis of Calciphylaxis

Natasha Tobarran, DO
Mark Collin, MD

Wellspring York Hospital, Department of Emergency Medicine, York, Pennsylvania

Section Editor: Rick A. McPheeters, DO

Submission history: Submitted April 25, 2020; Revision received June 12, 2020; Accepted July 3, 2020

Electronically published July 30, 2020

Full text available through open access at http://escholarship.org/uc/uciem_cpem

DOI: 10.5811/cpem.2020.7.47886

Case Presentation: A 63-year-old male with a past medical history of end stage renal disease presented to the emergency department with painful, lower-extremity necrotic ulcerations. Ultrasound and computed tomography imaging showed concerns for calcium deposits. Biopsy confirmed the diagnosis of calciphylaxis, a rare lethal disease.

Discussion: Emergency physicians should keep this disease on their differential due to the high mortality rate. [Clin Pract Cases Emerg Med. 2020;4(3):495–496.]

Keywords: *Point-of-care ultrasound; calciphylaxis; necrotic skin ulcer.*

CASE PRESENTATION

A 63-year-old male with end-stage renal disease (ESRD) presented to the emergency department with severe, bilateral lower-extremity pain with black necrotic ulcerations (Image 1). The symptoms began five weeks prior, and review of systems was negative for fevers or trauma. The patient was previously treated with antibiotics, prednisone, and oxycodone without improvement. Further evaluation via point-of-care ultrasound

focusing on the necrotic areas revealed calcium deposits and shadowing (Image 2). Computed tomography confirmed soft tissue calcifications (Image 3).

DISCUSSION

The findings were concerning for calciphylaxis. Punch biopsy showed extensive skin necrosis and calcifications confirming the diagnosis. The patient was treated with sodium thiosulfate and was discharged home but ultimately was transitioned to hospice care.

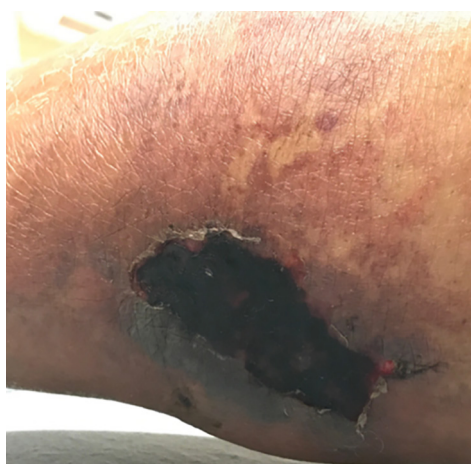

Image 1. Physical examination revealing lower extremity skin necrosis due to calciphylaxis in the setting of end-stage renal disease.

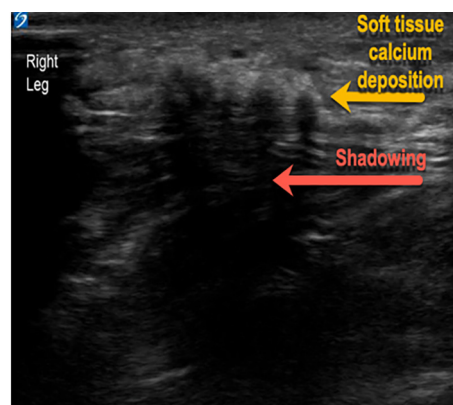


Image 2. Soft tissue point-of-care ultrasound identifying soft tissue calcium deposits with shadowing diagnostic of calciphylaxis in a patient with end-stage renal disease.

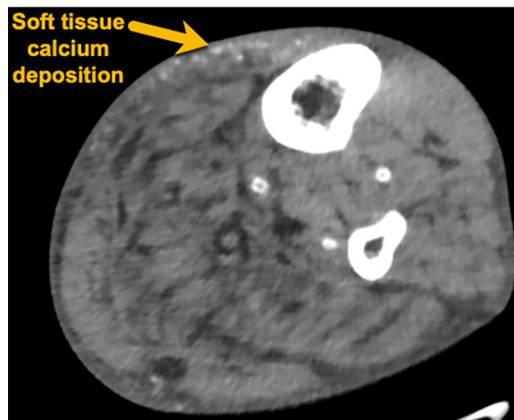


Image 3. Computed tomography with axial view demonstrating soft tissue calcium deposits diagnostic of calciphylaxis in a patient with end-stage renal disease.

Calciphylaxis is rare and lethal disease, presenting with skin ischemia and necrosis caused by total occlusion of blood vessels secondary to calcification of arterioles and capillaries in the dermis and adipose tissue.¹ The estimated six-month survival rate is 50%.² It has been linked to ESRD, hyperparathyroidism, hypercalcemia, and hyperphosphatemia.³ Patients present with non-healing, painful necrotic skin lesions in areas with increased adiposity such as distal lower extremities.² The diagnosis is clinical; however, biopsy can be used for confirmation. The treatment involves wound care, pain management, and correcting electrolyte abnormalities.¹ Wound infection is a common complication. A trial of sodium thiosulfate, which blocks the calcification of vascular smooth muscle, may be implemented.¹ It is important for emergency physicians to keep calciphylaxis on their differential for non-healing painful wounds, especially in high-risk patient populations. Point-of-care ultrasound is a useful tool in aiding with diagnosis.

The authors attest that their institution requires neither Institutional Review Board approval, nor patient consent for publication of this image in emergency medicine. Documentation on file.

REFERENCES

1. Chang JJ. Calciphylaxis: diagnosis, pathogenesis, and treatment. *Adv Skin Wound Care*. 2019;32(5):205-5.
2. Nigwekar SU, Thadani R, Brandenburg VM. Calciphylaxis. *N Engl J*

CPC-EM Capsule

What do we already know about this clinical *Calciphylaxis is a rare disease with high morbidity and mortality presenting with painful necrotic lesions due to calcium deposits in the fat and skin.*

What is the major impact of the image(s)? *Soft tissue calcium deposits with associated shadowing can be seen with ultrasound of the necrotic lesions, aiding in diagnosis of calciphylaxis.*

How might this improve emergency medicine practice? *Point-of-care ultrasound may be useful for an astute clinician in the diagnosis of calciphylaxis, which should be considered when evaluating painful skin lesions.*

Address for Correspondence: Natasha Tobarran, DO, Wellspan York Hospital, Department of Emergency Medicine, 1001 S. George Street, York, PA 17403. Email: Natasha.tobarran@gmail.com.

Conflicts of Interest: By the *CPC-EM* article submission agreement, all authors are required to disclose all affiliations, funding sources and financial or management relationships that could be perceived as potential sources of bias. The authors disclosed none.

Copyright: © 2020 Tobarran et al. This is an open access article distributed in accordance with the terms of the Creative Commons Attribution ([CC BY 4.0](http://creativecommons.org/licenses/by/4.0/)) License. See: <http://creativecommons.org/licenses/by/4.0/>

Med. 2018;378(18):1704-14

3. Udomkarnjananum S, Kongnatthasate K, Praditpornsilpa K, et al. Treatment of calciphylaxis in CKD: a systematic review and meta-analysis. *Kidney Int Rep*. 2018;4(2):231-44.