

# UC Davis

## Dermatology Online Journal

### Title

Cranial fasciitis

### Permalink

<https://escholarship.org/uc/item/46z82844>

### Journal

Dermatology Online Journal, 20(12)

### Authors

Ginsberg, Brian  
Ng, Elise  
Hu, Stephanie W  
et al.

### Publication Date

2015

### DOI

10.5070/D32012025056

### Copyright Information

Copyright 2015 by the author(s). This work is made available under the terms of a Creative Commons Attribution-NonCommercial-NoDerivatives License, available at <https://creativecommons.org/licenses/by-nc-nd/4.0/>

Peer reviewed

**Case Presentation**

**Cranial fasciitis**

**Brian Ginsberg MD, Elise Ng MD, Stephanie W. Hu MD, and Shane A. Meehan MD**

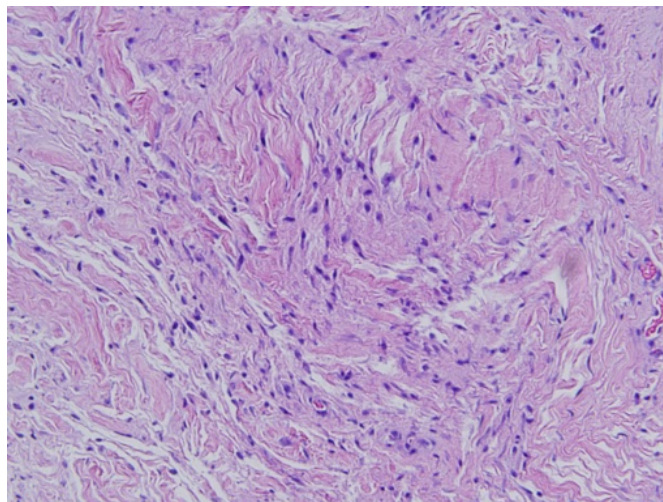
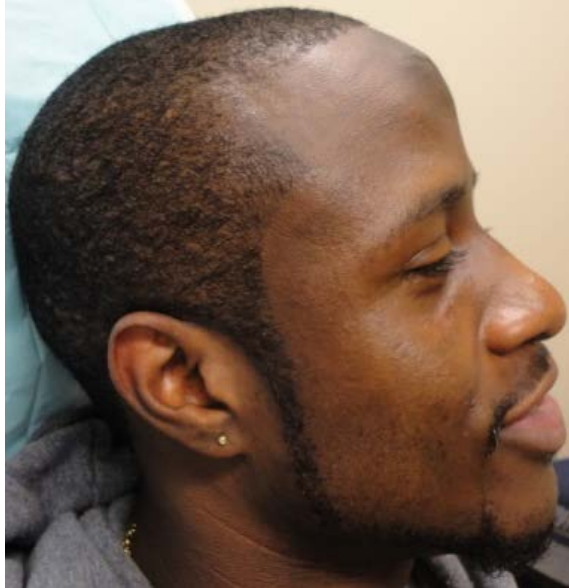**Dermatology Online Journal 20 (12): 8**

**New York University School of Medicine**

**Special Guest Editor: Nicholas A. Soter, MD**

**Abstract**

A 26-year-old man presented with an 18-month history of a subcutaneous mass on his forehead that occurred shortly after being struck by a blunt object. Histopathologic examination showed a proliferation of bland spindle cells and a collagenous stroma that was consistent with cranial fasciitis. Cranial fasciitis, which is a variant of nodular fasciitis, is a benign fibroblastic neoplasm that overlies the skull and often is associated with trauma. Although its rapid onset may give the clinical impression of a malignant condition, cranial fasciitis typically is cured by simple excision without further sequelae.



## Case synopsis

**History:** A 26-year old man was referred to the Skin and Cancer Unit for the evaluation of a mass on the forehead. Eighteen months prior, he was involved in a domestic dispute during which he was hit on the forehead with a broom. The next day, he noticed a tender, large bump on his forehead that continued to grow and swell. There was no bleeding from the site and it did not look like a bruise. Prior to the trauma, his forehead was completely normal with no obvious mass present.

One month after the incident, he had the mass excised by an outside dermatologist. Shortly thereafter, the mass recurred and he had another excision six months later, which again resulted in a recurrence within months. The mass has been stable now for several months, smaller than it was prior to the second surgical procedure, but still present. It is completely asymptomatic. He is otherwise well, without systemic symptoms, which include headache or vision changes.

**Physical examination:** On the central forehead, there is a 5 by 4-cm soft, spongy, non-mobile subcutaneous tumor. There is overlying hyperpigmentation and a well-healed, linear scar at the site of prior surgery.

**Laboratory data:** None

**Histopathology:** There is a proliferation of predominantly bland spindle cells, which are set within a somewhat myxoid and collagenous stroma. An increased number of thin-walled blood vessels are noted. By report, some of the spindle cells react for CD34, but there is no reactivity for S100, desmin, smooth muscle actin, muscle-specific actin, caldesmon, and calponin.

## Discussion

**Diagnosis:** Cranial fasciitis

**Comment:** Cranial fasciitis is a rare variant of nodular fasciitis, which affects the fascial plain that overlies the skull. With less than 50 cases in the literature, cranial fasciitis is characteristically a male-predominant disease of young children, with an average onset at 24 months of age, although adult cases have been reported [1-3]. Most cases occur on the temporoparietal area and arise from the deep fascia or cranial periosteum [4]. They almost always remained extracranial, with one report of an intracranial occurrence [5]. Extracranial lesions may, however, destroy the underlying skull.

Aside from location and age-predilection, cranial fasciitis behaves similarly to nodular fasciitis. Nodular fasciitis is a benign, fibroblastic tumor with such rapid growth that it was first described as a pseudosarcomatous fibromatosis [6]. Although the precise cause is unknown, trauma is the most commonly cited predecessor [7]. Typically affecting individuals in their third to fifth decade of life without any sex predilection, adult nodular fasciitis is most commonly found on the upper extremities and trunk. Three major subtypes exist – subcutaneous, intramuscular, and fascial – but less common variants may be seen, which include cranial, intravascular, ossifying, proliferative and, intradermal (one case) [8-10].

The histopathologic features of cranial fasciitis and nodular fasciitis are identical. Classically present are spindle-shaped, stellate fibroblasts with occasional mitotic figures within a loose collagenous stroma [11]. One may also observe increased vascularity or an inflammatory cell infiltrate, which includes foamy histiocytes, multinucleated giant cells, and osteoclast-like giant cells [12]. Immunohistochemical staining frequently is positive for vimentin and smooth muscle actin, as opposed to the findings in our case.

Owing to the possibility of cranial involvement, radiologic evaluation with magnetic resonance imaging often is recommended [4]. Treatment with local excision of the visualized tumor is usually curative. However, if radiologic evidence of cranial involvement is present, some advocate curettage of the underlying bone [13]. In the end, cranial fasciitis, like the other forms of nodular fasciitis, is a readily curable condition. This condition should be remembered when evaluating a patient with a rapidly growing, seemingly aggressive subcutaneous nodule of scalp or face.

## References

1. Keyserling HF, et al. Cranial fasciitis of childhood. *Am J Neuroradiol* 2003; 24: 1465 [PMID: 12917148]
2. Ester du Toit L, et al. Cranial fasciitis presenting as a frontotemporal mass. *J Craniofacial Surg* 2009; 20: 1197 [PMID: 19553842]
3. SantaCruz K, et al. A case of cranial fasciitis originating within the diploic space of an adult: case report. *Neurosurgery* 2007; 61: E1338 [PMID: 18162867]
4. Garza L, et al. Cranial fasciitis of childhood: a lytic skull lesion. *J La State Med Soc* 2012; 164: 347 [PMID: 23431678]

5. Agozzino M, et al. Cranial fasciitis and exclusive intracranial extension in an 8-year-old girl. *Acta Neuropathol* 2006; 111: 286 [PMID: 16465530]
6. Tarren V, et al. Nodular fasciitis of the zygoma: a case report. *Can J Plast Surg* 2008; 16: 241 [PMID: 19949508]
7. Han W, et al. Nodular fasciitis in the orofacial region. *Int J Oral Maxillofac Surg* 2006; 35: 924 [PMID: 16965901]
8. Hideki K, et al. Nodular fasciitis of the cheek. *Eur J Dermatol* 2003; 13: 189 [PMID: 12695137]
9. Martinez BJV, et al. Maxillofacial nodular fasciitis: a report of 3 cases. *J Oral Maxillofac Surg* 2002; 60: 1211 [PMID: 12378503]
10. Chaithanyaa N, et al. Nodular fasciitis over the anterior wall of the maxillary sinus: a case report and review of the literature. *Oral Surg Oral Pathol Oral Radiol* 2013; 115: e10 [PMID: 23217546]
11. Lauer DH, Enzinger FM. Cranial fasciitis of childhood. *Cancer* 1980; 45: 401 [PMID: 7351023]
12. Sarangarajan R, Dehner LP. Cranial and extracranial fasciitis of childhood: a clinicopathologic and immunohistochemical study. *Hum Pathol* 1999; 30: 87 [PMID: 9923933]
13. Sajben PF, et al. Cranial fasciitis of childhood. *Pediatric dermatol* 1999; 16: 232 [PMID: 10383784]