

# UC Davis

## Dermatology Online Journal

### Title

Congenital trichofolliculoma: a very rare presentation

### Permalink

<https://escholarship.org/uc/item/4g69d9zc>

### Journal

Dermatology Online Journal, 26(7)

### Authors

El-Komy, Mohamed HM  
Abdelkader, Heba A

### Publication Date

2020

### DOI

10.5070/D3267049564

### Copyright Information

Copyright 2020 by the author(s). This work is made available under the terms of a Creative Commons Attribution-NonCommercial-NoDerivatives License, available at <https://creativecommons.org/licenses/by-nc-nd/4.0/>

Peer reviewed

# Congenital trichofolliculoma: a very rare presentation

Mohamed HM El-Komy MD, Heba A Abdelkader MD

Affiliations: Department of Dermatology, Kasr Alainy Faculty of Medicine, Cairo University, Cairo, Egypt

Corresponding Author: Heba A. Abdelkader MD, Mailing address: Dermatology Department, Kasr Al Aini Hospital, Cairo University, Kasr Al Aini Street, Cairo, Egypt 11562, Tel: 20-1222868716, Email: [h\\_abdelkader2007@yahoo.com](mailto:h_abdelkader2007@yahoo.com)

## Abstract

Trichofolliculoma is an uncommon hair follicle hamartoma. It usually appears during adulthood on the face or scalp as a single, asymptomatic, skin-colored papule/nodule with small protruding hairs. Histopathological features are diagnostic. Very rare congenital cases have been reported. Herein, we report a congenital trichofolliculoma in a 15-year-old girl.

*Keywords: trichofolliculoma, congenital, hair follicle tumors, hamartoma*

## Introduction

Trichofolliculoma is an uncommon hair follicle hamartoma. It usually appears during adulthood on the face or scalp as an isolated, skin-colored papule or nodule and exhibits a central umbilication from which small hairs may protrude [1]. The lesion may be confused clinically with an epidermal inclusion cyst, dilated pore of Winer, or basal cell carcinoma [2]. Histopathologically it reveals a central dilated follicle, containing keratin and hair shafts with multiple hair follicles in different stages of development [3].

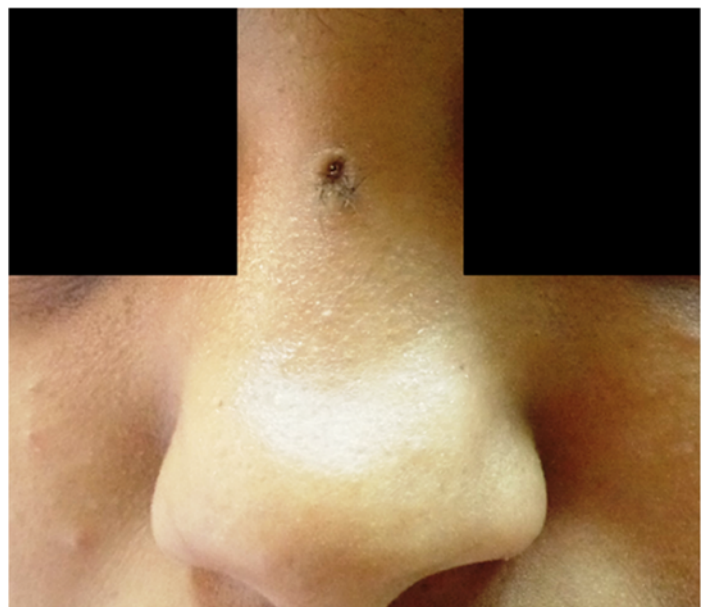## Case Synopsis

A 15-year-old girl presented with an asymptomatic hairy papule on her nose since birth. Examination revealed a skin-colored papule with a central umbilication and small protruding hairs (**Figure 1**). The lesion was excised and histopathological examination demonstrated a central dilated

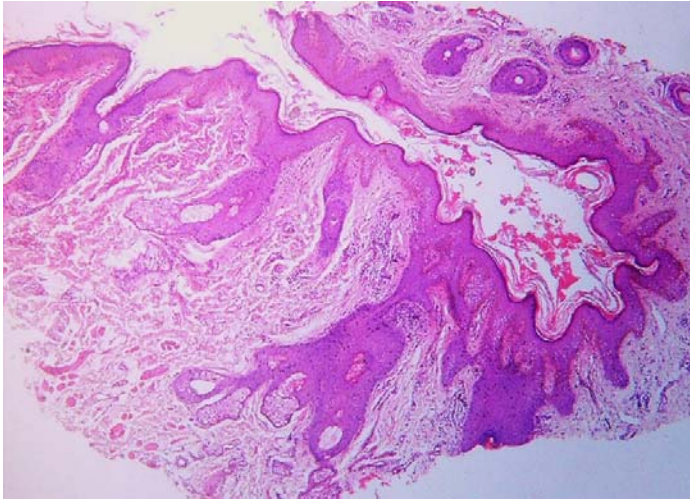
follicular cavity with radially arranged hair follicles in different stages of development consistent with trichofolliculoma (**Figure 2**).

## Case Discussion

Trichofolliculoma is a rare hair follicle hamartoma/tumor. It is considered by most authors to be a hamartoma rather than a neoplasm as it has all components of the hair follicle in an aberrant distribution [4]. Its differentiation is midway between a hair follicle nevus and a trichoepithelioma [5]. It usually presents in adulthood as a single lesion on the face especially around the nose. However, it is reported to occur in other sites such as the external auditory meatus, intranasal area, genitalia, lip, and vulva [6]. Rare cases of congenital trichofolliculoma have been reported in the literature [7-11]. There are



**Figure 1:** Trichofolliculoma. A skin-colored papule on the nose with a central umbilication and small protruding hairs.



**Figure 2:** Histopathology of trichofolliculoma. A central dilated follicular cavity with radially arranged hair follicles in different stages of development (H&E, original magnification X40).

no reported systemic or skin abnormalities associated with trichofolliculoma [2].

Histopathologically, fully developed trichofolliculoma appears as a well-circumscribed lesion consisting of a central dilated cavity lined by stratified squamous epithelium with an infundibular keratinization pattern that is continuous with the surface epidermis. The cavity usually contains keratin and sometimes vellus hair shafts. Numerous vellus hair follicles, in different stages of development, radiate from the wall of this central cavity [3]. These follicles may in turn give rise to secondary or even tertiary follicles [5]. Rupture of the cystic space can lead to a granulomatous reaction in response to the extruded keratin in the surrounding dermis. Incidentally, trichofolliculomas may show epidermolytic hyperkeratosis or acantholytic dyskeratosis [12]. These findings may vary according to the age of the lesion. Schulz and Hartschuh suggested that trichofolliculoma undergoes changes corresponding to the stages of the normal follicle cycle [13]. In older lesions, catagen and telogen follicles are seen [5]. Merkel cells can be visualized in the outer sheath of

the small follicles [14]. Sebaceous differentiation may be seen within the follicles or the rudimentary structures. Sebocytes are seen more often in late stage lesions. A variant of trichofolliculoma in which large sebaceous follicles connect to a central cavity has been reported as a sebaceous trichofolliculoma [15]. It has some similarities to the folliculosebaceous cystic hamartoma (FSCH) which has been argued to be a later stage in the evolution of trichofolliculoma [16].

Misago and his colleagues studied the chronological changes of 40 trichofolliculoma lesions and found that the regressing secondary follicles were not replaced by sebaceous elements. They considered that FSCH is a distinct entity, not a very late stage of trichofolliculoma [17]. Trichofolliculoma with a well-developed stroma may be mistaken for a fibrofolliculoma, the most common skin lesion seen in Birt Hogg Dube syndrome. Fibrofolliculoma is characterized by epithelial cords radiating from the main infundibular wall, not secondary hair follicles as seen in trichofolliculoma [18]. Clinically, the differential diagnosis of trichofolliculoma includes dilated pore of Winer, epidermoid cyst, and basal cell carcinoma [2].

## Conclusion

Trichofolliculoma is a benign hamartoma with a nearly stationary course. Excision may be performed for aesthetic purposes and is curative. It has no malignant potential although a single case of trichofolliculoma with perineural invasion has been reported in the literature [19].

## Potential conflicts of interest

The authors declare no conflicts of interests/[the following potential conflicts].

## References

1. Gokalp H, Gurer MA, Alan S. Trichofolliculoma: a rare variant of hair follicle hamartoma. *Dermatol Online J*. 2013;19:19264. [PMID: 24021443].
2. Howard MS. Trichofolliculoma. 2017. <https://emedicine.medscape.com/article/1060303-overview>. Accessed on February 2, 2020.

3. Misago N, Kimura T, Toda S, Mori T, Narisawa Y. A reevaluation of trichofolliculoma: the histopathological and immunohistochemical features. *Am J Dermatopathol*. 2010;32:35-43. [PMID: 19730084].
4. Hausteil UF. Remarks on the differential diagnosis and histogenesis of trichofolliculoma (hair follicle nevus). *Arch Klin Exp Dermatol*. 1966;226:199-211. [PMID: 5984217].
5. Patterson W. Tumors of cutaneous appendages. In: Weedon's skin pathology. Patterson W. 4th ed. Elsevier Limited; 2016. p. 911.
6. Choi CM, Lew BL, Sim WY. Multiple trichofolliculomas on unusual sites: A case report and review of the literature. *Int J Dermatol*. 2013;52:87-9. [PMID: 22640019].
7. Ishii N, Kawaguchi H, Takahashi K, Nakajima H. A case of congenital trichofolliculoma. *J Dermatol*. 1992;19:195-6. [PMID: 1640026].
8. Al-Ghadeer H, Edward DP. Congenital Sebaceous Trichofolliculoma of the Upper Eyelid. *Ophthalmic Plast Reconstr Surg*. 2017;33:S60-1. [PMID: 27097063].
9. Romero-Pérez D, García-Bustinduy M, Cribier B. Clinicopathologic study of 90 cases of trichofolliculoma. *J Eur Acad Dermatol Venereol*. 2016;31:e141-2. [PMID: 27608202].
10. Iraj F, Fatemi F. Congenital trichofolliculoma: a case report. *Med J Islam Repub Iran*. 1999;13:81. [URL: <http://mjiri.iiums.ac.ir/article-1-977-en.html>]. Accessed on July 24, 2020.
11. Aloï F, Tomasini C, Pippione M. Congenital trichofolliculoma with perifollicular mucinosis. *Am J Dermatopathol*. 1994;16:106. [DOI: 10.1097/00000372-199402000-00068].
12. Requena L, Sangüeza O. Neoplasms with follicular differentiation. In: Cutaneous Adnexal Neoplasms. Requena L, Sangüeza O. 1st ed. Springer International Publishing; 2017. p. 471-81.
13. Schulz T, Hartschuh W. The trichofolliculoma undergoes changes corresponding to the regressing normal hair follicle in its cycle. *J Cutan Pathol*. 1998;25:341-53. [PMID: 9765019].
14. Hartschuh W, Schulz T. Immunohistochemical investigation of the different developmental stages of trichofolliculoma with special reference to the Merkel cell. *Am J Dermatopathol*. 1999;21:8-15. [PMID: 10027518].
15. Plewig G. Sebaceous trichofolliculoma. *J Cutan Pathol*. 1980;7:394-403. [PMID: 7451702].
16. Schulz T, Hartschuh W. Folliculo-sebaceous cystic hamartoma is a trichofolliculoma at its very late stage. *J Cutan Pathol*. 1998;25:354-64. [PMID: 9765020].
17. Misago N, Ansai SI, Fukumoto T, et al. Chronological changes in trichofolliculoma: Folliculosebaceous cystic hamartoma is not a very-late-stage trichofolliculoma. *J Dermatol*. 2017;44:1050-4. [PMID: 28370423].
18. Tellechea O, Cardoso JC, Reis JP, et al. Benign follicular tumors. *An Bras Dermatol*. 2015;90:780-98. [PMID: 26734858].
19. Stern JB, Stout DA. Trichofolliculoma showing perineural invasion. Trichofolliculocarcinoma? *Arch Dermatol*. 1979;115:1003-4. [PMID: 464613].