

# UC Davis

## Dermatology Online Journal

### Title

Cutaneous toxicity associated with enfortumab vedotin treatment of metastatic urothelial carcinoma

### Permalink

<https://escholarship.org/uc/item/4j44w7w6>

### Journal

Dermatology Online Journal, 25(2)

### Authors

Wu, Sam  
Adamson, Adewole S

### Publication Date

2019

### DOI

10.5070/D3252042890

### Copyright Information

Copyright 2019 by the author(s). This work is made available under the terms of a Creative Commons Attribution-NonCommercial-NoDerivatives License, available at <https://creativecommons.org/licenses/by-nc-nd/4.0/>

Peer reviewed

# Cutaneous toxicity associated with enfortumab vedotin treatment of metastatic urothelial carcinoma

Sam Wu MD, Adewole S Adamson MD MPP

Affiliations: University of North Carolina at Chapel Hill, Department of Dermatology, Chapel Hill, North Carolina, USA

Corresponding Author: Sam Wu MD, University of North Carolina at Chapel Hill, Department of Dermatology, 410 Market Street, Suite 400, Chapel Hill, NC 27516, Tel: 984-974-3900, Email: [sam.wu@unchealth.unc.edu](mailto:sam.wu@unchealth.unc.edu)

## Abstract

Enfortumab vedotin is an antibody-drug conjugate targeting nectin-4 and is being studied in the treatment of various epithelial carcinomas including urothelial carcinoma; early data suggests efficacy and tolerability. Rash has been described as an adverse event associated with treatment with enfortumab vedotin, but has not been characterized to date. We report a patient with metastatic urothelial carcinoma treated with enfortumab vedotin who developed erythematous, scaly papules and plaques on his torso and extremities with corresponding histologic features of vacuolar interface dermatitis and maturation disarray of keratinocytes. He was successfully treated with topical corticosteroids. Cutaneous toxicity appears to be a common adverse reaction in this growing class of antibody-drug conjugates.

Keywords: drug rash, adverse drug reaction

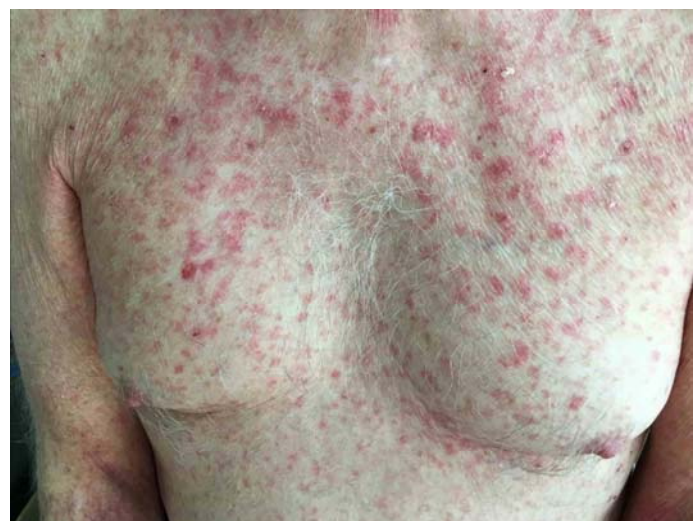## Introduction

Enfortumab vedotin is an antibody-drug conjugate comprised of an anti-nectin-4 antibody joined to monomethyl auristatin E (MMAE), an antimetabolic agent that inhibits microtubule assembly. Early phase clinical trials are currently underway to study the use of enfortumab vedotin in advanced urothelial carcinoma, ovarian cancer, and non-small cell lung cancer [1]. Clinical and histopathological features of cutaneous toxicity owing to enfortumab vedotin have not been previously characterized. We report a case of a papulosquamous drug eruption developing in a patient undergoing treatment with

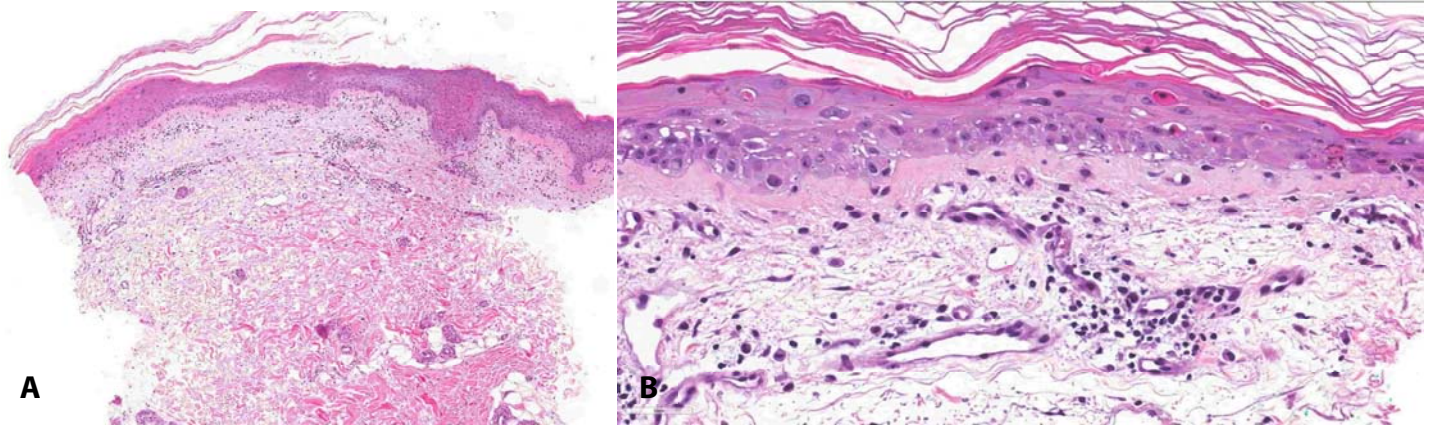
enfortumab vedotin for metastatic urothelial carcinoma.

## Case Synopsis

A man in his 70s with a history of metastatic urothelial carcinoma involving the right ureter, lymph nodes, and lungs presented to outpatient dermatology clinic for evaluation of a scaly, pruritic rash involving the torso and extremities. Two weeks prior to presentation he received an infusion of enfortumab vedotin as part of a phase I clinical trial. He subsequently developed the eruption within days of his first dose and noted minimal improvement with triamcinolone 0.1% cream. Of note, the patient was previously on a clinical trial of pembrolizumab, which was discontinued two



**Figure 1.** Clinical image of rash due to enfortumab vedotin. Erythematous, scaly, pruritic papules on the chest and upper abdomen in a patient treated with enfortumab vedotin for metastatic urothelial carcinoma. Similar lesions were present on the back and extremities.



**Figure 2.** Punch biopsy demonstrated a vacuolar interface dermatitis with dermal edema and maturation disarray of epidermal keratinocytes. **A)** H&E, 40 $\times$ ; **B)** 400 $\times$ .

months earlier because of progression of disease. He also developed a rash while on pembrolizumab, which was morphologically distinct from his current eruption and had resolved prior to enrollment in the enfortumab vedotin trial. He furthermore denied mucosal involvement, fevers, chills, or malaise.

On examination, he was found to have erythematous, scaly, variably excoriated pink papules involving the extremities, neck, chest, back, and abdomen with sparing of the face (**Figure 1**). No oral or conjunctival mucosal erosions were noted. A punch biopsy was performed and revealed a vacuolar interface dermatitis with maturation disarray of keratinocytes and a sparse perivascular lympho-eosinophilic infiltrate, which was interpreted to be consistent with a drug eruption (**Figure 2**). Review of his medication timeline did not identify any other recent medications or other possible causative agents. He was prescribed clobetasol 0.05% cream for his rash and oral antihistamines for the associated pruritus. His rash was noted to be significantly improved at his oncology follow up two weeks later. Additional cycles of enfortumab vedotin resulted in recurrences of his rash which similarly responded to topical corticosteroids and oral antihistamines.

## Case Discussion

Enfortumab vedotin targets nectin-4, a member of a family of calcium-dependent, immunoglobulin-like adhesion molecules found in adherens junctions and expressed in various epithelial malignancies

including bladder, breast, lung, ovarian, head/neck, and esophageal cancers [1]. Nectin-4 is important in the skin, as defects in nectin-4 have been linked to cases of ectodermal dysplasia-syndactyly syndrome characterized by hair, nail, and teeth abnormalities, syndactyly, and palmoplantar keratoderma [2].

We hypothesize that nectin-4 expression in the skin may contribute to its cutaneous toxicity. However, rash also appears to be a common adverse reaction in studies involving other antibody-drug conjugates that incorporate MMAE, occurring in 27 to 31% of patients treated with brentuximab vedotin, 45% of patients treated with glemtutumumab vedotin, and 13-31% of patients treated with polatumumab vedotin, suggesting the cutaneous toxicity of these drugs may not be solely mediated by the antibody component [3-5]. Phase 1 data for enfortumab vedotin in the treatment of metastatic urothelial carcinoma is promising and suggests the drug is overall well tolerated; the most commonly reported treatment-related adverse events are fatigue, rash, nausea, and decreased appetite [6, 7]. Grade 3 or higher adverse events reported include anemia, hyponatremia, urinary tract infections, and hyperglycemia, each of which occurred in  $\leq 7\%$  of patients [8]. To our knowledge, our report is the first to characterize the clinical and histopathological features of the rash associated with treatment with enfortumab vedotin. As many other antibody-MMAE conjugates including tisotumab vedotin, pintuzumab vedotin, sofituzumab vedotin, and lifastuzumab vedotin are also under investigation for treatment of various malignancies, it is important to

be aware of toxicities that may be common to this class of medications.

## Conclusion

Enfortumab vedotin is an investigational agent that shows promise in the treatment of urothelial carcinoma. Development of a rash has been described as an adverse reaction to enfortumab vedotin, which morphologically is comprised of erythematous, scaly papules and plaques

corresponding histologically to a vacuolar interface dermatitis with maturation disarray of keratinocytes. Cutaneous toxicity may be common to multiple members this class of antibody-drug conjugates, which are being studied in the context of multiple different malignancies.

## Potential conflicts of interest

The authors declare no conflicts of interests.

## References

1. Challita-Eid PM, Satpayev D, Yang P, et al. Enfortumab Vedotin Antibody-Drug Conjugate Targeting Nectin-4 Is a Highly Potent Therapeutic Agent in Multiple Preclinical Cancer Models. *Cancer Res.* 2016;76(10):3003-3013. [PMID: 27013195].
2. Fortugno P, Josselin E, Tsiakas K, et al. Nectin-4 mutations causing ectodermal dysplasia with syndactyly perturb the rac1 pathway and the kinetics of adherens junction formation. *J Invest Dermatol.* 2014;134(8):2146-2153. [PMID: 24577405].
3. de Claro RA, McGinn K, Kwitkowski V, et al. U.S. Food and Drug Administration approval summary: brentuximab vedotin for the treatment of relapsed Hodgkin lymphoma or relapsed systemic anaplastic large-cell lymphoma. *Clin Cancer Res.* 2012;18(21):5845-5849. [PMID: 22962441].
4. Yardley DA, Weaver R, Melisko ME, et al. EMERGE: A Randomized Phase II Study of the Antibody-Drug Conjugate Glembatumumab Vedotin in Advanced Glycoprotein NMB-Expressing Breast Cancer. *J Clin Oncol.* 2015;33(14):1609-1619. [PMID: 25847941].
5. Palanca-Wessels MCA, Czuczman M, et al. Safety and activity of the anti-CD79B antibody–drug conjugate polatuzumab vedotin in relapsed or refractory B-cell non-Hodgkin lymphoma and chronic lymphocytic leukaemia: a phase 1 study. *Lancet Oncol.* 2015;16(6):704-715. [PMID: 25925619].
6. Petrylak DP, Smith DC, Flaig TW, et al. Enfortumab vedotin (EV) in patients (Pts) with metastatic urothelial carcinoma (mUC) with prior checkpoint inhibitor (CPI) failure: A prospective cohort of an ongoing phase 1 study. *J Clin Oncol.* 2018;36(6\_suppl):431-431.
7. Rosenberg JE, Heath EI, O'Donnell PH, et al. EV-201 Study: A single-arm, open-label, multicenter study of enfortumab vedotin for treatment of patients with locally advanced or metastatic urothelial cancer who previously received immune checkpoint inhibitor therapy. *J Clin Oncol.* 2018;36(15\_suppl):TPS4590-TPS4590.
8. Rosenberg JE, Sridhar SS, Zhang J, et al Updated results from the enfortumab vedotin phase 1 (EV-101) study in patients with metastatic urothelial cancer (mUC). *J Clin Oncol.* 2018;36(15\_suppl):4504-4504.