

UC Davis

Dermatology Online Journal

Title

Tender finger nodule

Permalink

<https://escholarship.org/uc/item/4n58b3m8>

Journal

Dermatology Online Journal, 24(4)

Authors

Klapperich, Marki E
Buhalog, Brittany A
Hinshaw, Molly A

Publication Date

2018

DOI

10.5070/D3244039378

Copyright Information

Copyright 2018 by the author(s). This work is made available under the terms of a Creative Commons Attribution-NonCommercial-NoDerivatives License, available at <https://creativecommons.org/licenses/by-nc-nd/4.0/>

Peer reviewed

Tender finger nodule

Marki E Klapperich BS, Brittany A Buhalog MD, Molly A Hinshaw MD

Affiliations: Department of Dermatology, University of Wisconsin-Madison, Wisconsin, USA

Corresponding Author: Marki E. Klapperich, Department of Dermatology, University of Wisconsin, Madison, 1 S Park St, Seventh Floor, Madison, WI 53715, Tel: (920) 948-2188, Email: mklapperich@wisc.edu

Abstract

A male in his twenties presented with a tender finger nodule that had been present for 3 months. Histopathological examination revealed a dermis with nodules of necrotic, atypical epithelial cells with high nuclear to cytoplasmic ratios. Glandular formation was present with lumens lined by columnar epithelium, consistent with digital papillary adenocarcinoma. Digital papillary adenocarcinoma is a rare malignant adnexal tumor arising from sweat glands and requires further work-up.

Keywords: adnexal tumor, digital papillary adenocarcinoma, oncology

Introduction

Digital papillary adenocarcinoma is a rare malignant adnexal tumor arising from sweat glands. The tumor is most commonly found on the fingers, toes, and hands. We report a man in his twenties who presented with a 3-month history of a painful nodule

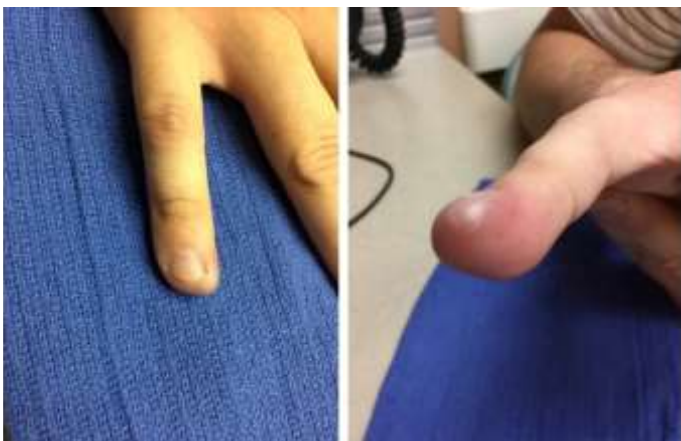

Figure 1. Right 5th finger with firm, erythematous, mildly tender nodule on the medial aspect of hyponychium extending to the medial nail fold.

on the distal volar aspect of the right fifth finger.

Case Report: A man in his twenties presented to the dermatology clinic in consultation for a 3-month history of a painful nodule on the distal volar aspect of the right fifth finger. He reported neither prior trauma to the digit nor any bleeding or drainage from the lesion. Upon examination, a firm, erythematous, tender nodule was present on the distal volar aspect of the right 5th finger (Figure 1). There were neither satellite lesions nor nail changes. Punch biopsy through the center of the lesion was performed at which point yellow necrotic material poured out of the biopsy site (Figures 2-5). Bacterial culture of this material was negative.

In the dermis were nodules of variably necrotic, atypical epithelial cells with high nuclear to cytoplasmic ratios, finely distributed chromatin, scattered mitoses, and small nucleoli. Glandular formation was present with lumens lined by

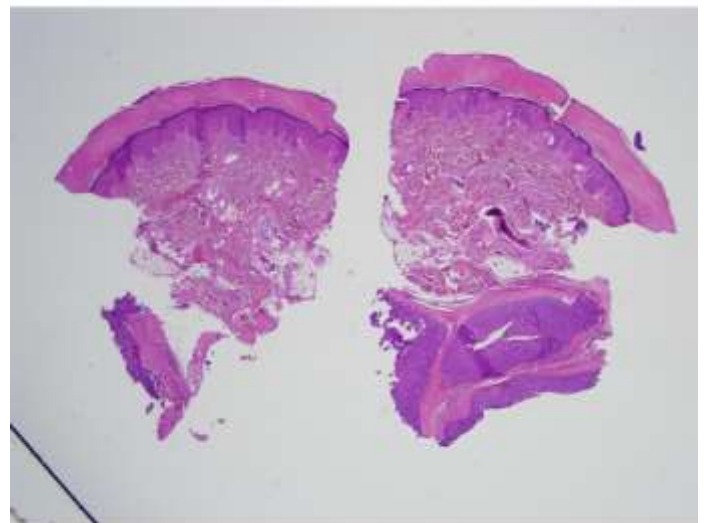


Figure 2. Microscopic findings showing dermis with nodules of variably necrotic, atypical epithelial cells with high nuclear to cytoplasmic ratios (H&E, 2x).

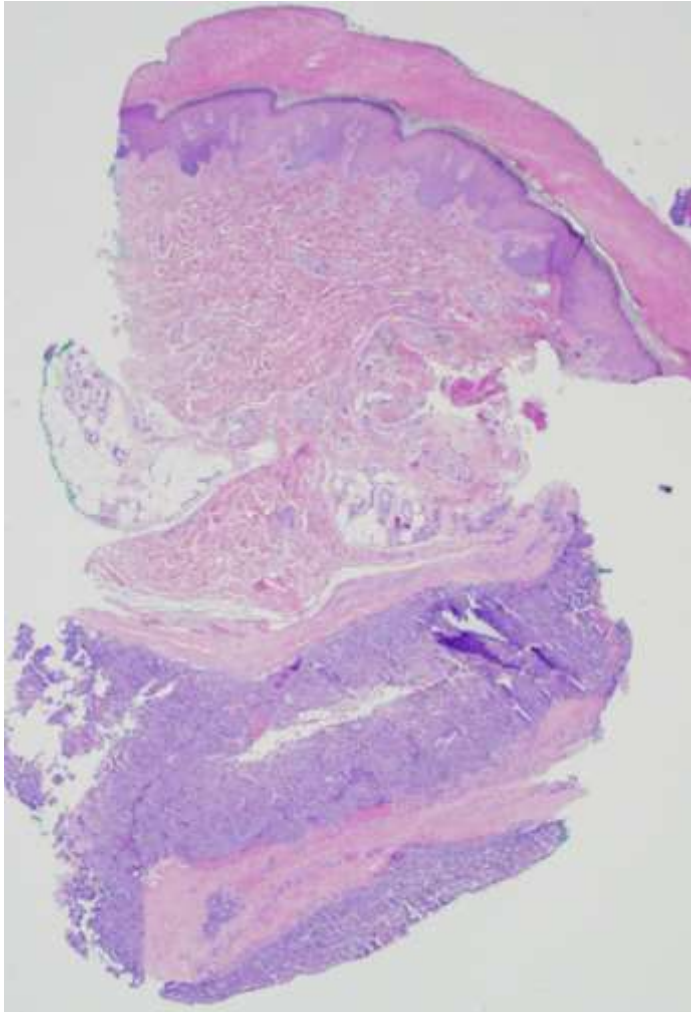


Figure 3. *Finely distributed chromatin, scattered mitoses, and small nucleoli. Glandular formation is present with lumens lined by columnar epithelium, occasionally forming apocrine-like snouts (H&E, 20x).*

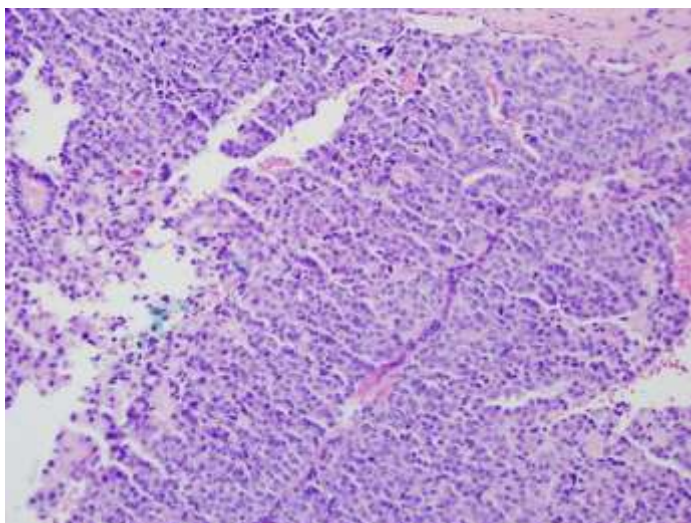


Figure 4. *Characteristic tubuloalveolar structures with papillary projections protruding into a cystic lumina are seen. H&E, 200x.*

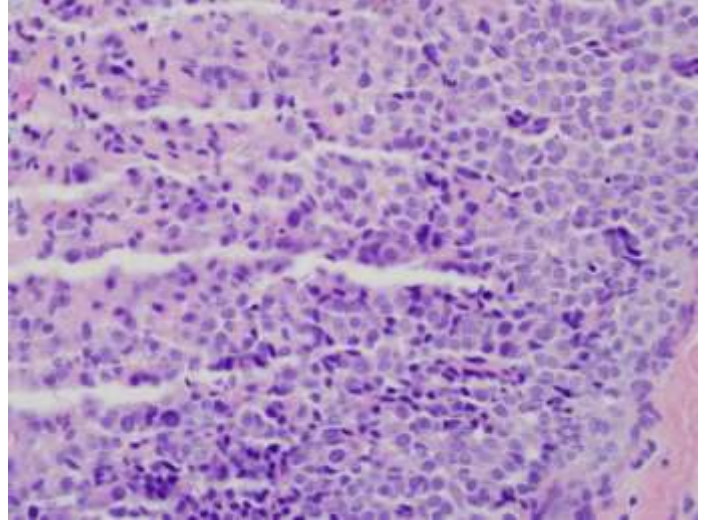


Figure 5. *Nuclear pleomorphism, high mitotic activity and single cell necrosis can be seen. H&E, 400x.*

columnar epithelium occasionally forming apocrine-like snouts confirming the diagnosis of digital papillary adenocarcinoma.

Our patient underwent evaluation for systemic involvement. PET/CT showed no evidence of metastatic disease. The right 5th finger was partially amputated 1cm proximal to the volar DIP crease. Sentinel lymph node biopsy was performed and was negative for in-transit disease. The amputation specimen revealed residual tumor with clear margins. During evaluation for metastatic disease, a thyroid nodule was identified. Ultrasound guided FNA revealed a follicular neoplasm. Surgical resection confirmed a benign follicular adenoma that required no further treatment. At the time of publication, our patient was disease-free for 12 months.

Discussion

Digital papillary adenocarcinoma is a rare malignant adnexal tumor arising from sweat glands, most commonly found on the fingers, toes, and hands [1-3]. Approximately 100 cases have been reported in the literature. Males are more commonly affected than females, with the peak age of occurrence in the fifth and sixth decades of life [1-4]. Racial or ethnic preponderance is unknown [5]. Presenting symptoms often include a firm, tan, gray, or pink rubbery subcutaneous nodule on the volar aspect of

fingers more often than toes. The tumors are generally between the nail bed and DIP joint; restriction of range of motion is not observed [1, 2]. The lesions may be tender or exhibit bleeding. Initial clinical impressions were coded to be, in descending order, mass/cyst, ganglion cyst, foreign body granuloma, pyogenic granuloma, epithelial inclusion cyst, squamous cell carcinoma, hemangioma, giant cell tumor, osteomyelitis, and soft tissue infection.

Histopathology of lesions reveals a multinodular, solid, or cystic mass with papillary projections in the cystic spaces [1-3]. A grenz zone may be present. All studied lesions had back-to-back fused glands lined by cuboidal to low columnar epithelial cells in the solid portion of the tumor [2]. Mitotic rate is variable, ranging from 0-60 per 10 high power fields [2]. Cytologic atypia is usually mild [1-4]. Interestingly, in one review, the majority of digital papillary adenocarcinomas stained positively for SMA and calponin of myoepithelial cells around glandular structures, traditionally believed to be a sign of banality. However, some of these tumors recurred or metastasized, so it is thought that SMA/calponin positivity should not be a sign of benignity. Rather, these tumors should be considered as malignant, with potential for metastasis [3].

Treatment of digital papillary adenocarcinoma is controversial. Two common approaches are wide local excision with negative margins and partial or complete amputation of the digit. Tumor recurrence was seen in 50% of reported cases without adequate

primary excision versus only 5% of cases treated with wide local excision or amputation within 6 months of diagnosis [2]. Given the rarity of this neoplasm, there is no consensus regarding margins recommended for excision. It is not clear if complete local control is necessary when there is in-transit disease [7].

Wildemore, Lee, and Humphreys reported success of Mohs micrographic surgery in other malignant eccrine carcinomas excluding microcystic adnexal carcinoma with non-inferiority with regard to recurrence [6]. There are no reported cases of digital papillary adenocarcinoma treated with Mohs. Perhaps Mohs could be employed in the future as a tissue sparing means to achieve local disease control. Metastatic disease is variable, seen in 14% of **reported cases in Duke's study [2] and 26% of those in Suchak's report [3].** The most common site of metastasis is the lungs [1-3]. Owing to the risk of metastasis, it is recommended that patients have annual examinations and chest X-ray for at least 10 years after diagnosis [1]. Interestingly, there is no correlation between metastasis or recurrence with patient age, tumor size, duration of the tumor, or histologic features in their analyses. There are currently no recommendations regarding the benefit of sentinel lymph node biopsy or adjuvant treatment given the rare nature of this entity. Nonetheless, given the potential of this tumor for aggressive behavior, sentinel lymph node biopsies are not uncommonly performed [1-3].

References

1. Kao GF, Helwig EB, Graham JH. Aggressive digital papillary adenoma and adenocarcinoma. A clinicopathological study of 57 patients, with histochemical, immunopathological, and ultrastructural observations. *J Cutan Pathol.* 1987;14(3):129-46. [PMID: 3301927].
2. Duke WH, Sherrod TT, Lupton GP. Aggressive digital papillary adenocarcinoma (aggressive digital papillary adenoma and adenocarcinoma revisited). *Am J Surg Pathol.* 2000;24(6):775-84. [PMID: 10843279].
3. Suchak R, Wang WL, Prieto VG, Ivan D, Lazar AJ, Brenn T, et al. Cutaneous digital papillary adenocarcinoma: a clinicopathologic study of 31 cases of a rare neoplasm with new observations. *Am J Surg Pathol.* 2012;36(12):1883-91. [PMID: 23026931].
4. LeBoit PE, editor. Pathology and genetics of skin tumours. IARC; 2006.
5. Frey J, Shimek C, Woodmansee C, Myers E, Greer S, Liman A, et al. Aggressive digital papillary adenocarcinoma: a report of two diseases and review of the literature. *J Am Acad Dermatol.* 2009;60(2):331-9. Epub 2008/09/25. [PMID: 18819728].
6. Wildemore JK, Lee JB, Humphreys TR. Mohs surgery for malignant eccrine neoplasms. *Dermatol Surg.* 2004;30(12 Pt 2):1574-9. [PMID: 15606845].
7. Carter K, Yao JJ, Melton SD, Lopez J, Huerta S. Digital Papillary Adenocarcinoma: Presentation, Natural History and Management. *Rare Tumors.* 2015;7(2):5867. Epub 2015/06/25. PubMed PMID: 26266016; [PMCID: PMC4508647].