

# UC Davis

## Dermatology Online Journal

### Title

Nivolumab reactivation of hypertrophic lichen planus, a case report and review of published literature.

### Permalink

<https://escholarship.org/uc/item/4xf465w6>

### Journal

Dermatology Online Journal, 24(1)

### Authors

Maarouf, Melody  
Alexander, Christina  
Shi, Vivian Y

### Publication Date

2018

### DOI

10.5070/D3241037930

### Copyright Information

Copyright 2018 by the author(s). This work is made available under the terms of a Creative Commons Attribution-NonCommercial-NoDerivatives License, available at <https://creativecommons.org/licenses/by-nc-nd/4.0/>

Peer reviewed

# Nivolumab reactivation of hypertrophic lichen planus, a case report and review of published literature.

Melody Maarouf<sup>1</sup> MHS, Christina Alexander<sup>2</sup> MD, Vivian Y Shi<sup>2</sup> MD

Affiliations: <sup>1</sup>College of Medicine, University of Arizona, Tucson, Arizona, <sup>2</sup>Division of Dermatology, Department of Medicine, University of Arizona, Tucson, Arizona

Corresponding Author: Vivian Y. Shi MD, Assistant Professor of Medicine (Dermatology Division), Arizona Cancer Center, 1515 N. Campbell Avenue (PO Box 245024), Building #222, Levy Building., 1906E, Tucson, AZ 85724-5024, Tel: (520) 626-6024, Fax: (520) 626-6033, Email: [vshi@Email.arizona.edu](mailto:vshi@Email.arizona.edu)

## Abstract

We report a case of nivolumab-induced lichen planus (LP) reactivation that was previously in remission following chemotherapy for non-small-cell lung cancer (NSCLC). Chemotherapy-induced immunosuppression allowed for complete resolution of the patient's pre-existing LP, a T-cell mediated autoimmune process. When the patient was switched to nivolumab immunotherapy owing to progression of NSCLC, PD-1 inhibition led to an overwhelming T-cell response that seemed to have provoked a severe LP reactivation. Although lichenoid reactions have been reported with nivolumab, to our knowledge, this is the first reported case of nivolumab monotherapy causing LP reactivation in a patient with a strong personal and family history of the disease that was previously in remission after chemotherapy.

*Keywords: PD-1 inhibitor; nivolumab; lichen planus*

## Introduction

Nivolumab is a humanized monoclonal antibody that competitively binds to T-cell Programmed Death 1 (PD-1) receptors and PD-Ligand 1 (PDL-1) on tumor cells. This interaction impedes T-cell anergy, enhancing immunogenic response against malignant cells [1, 2]. Cutaneous reactions from PD-1 inhibitors are believed to relate to T-lymphocyte activation. They occur in 30-40% of patients on PD-1 inhibitors [2] and include maculopapular rash, pruritus, psoriasis, oral mucositis, and bullous pemphigoid [1], with lichenoid reactions, eczema, and vitiligo being

the most common [3].

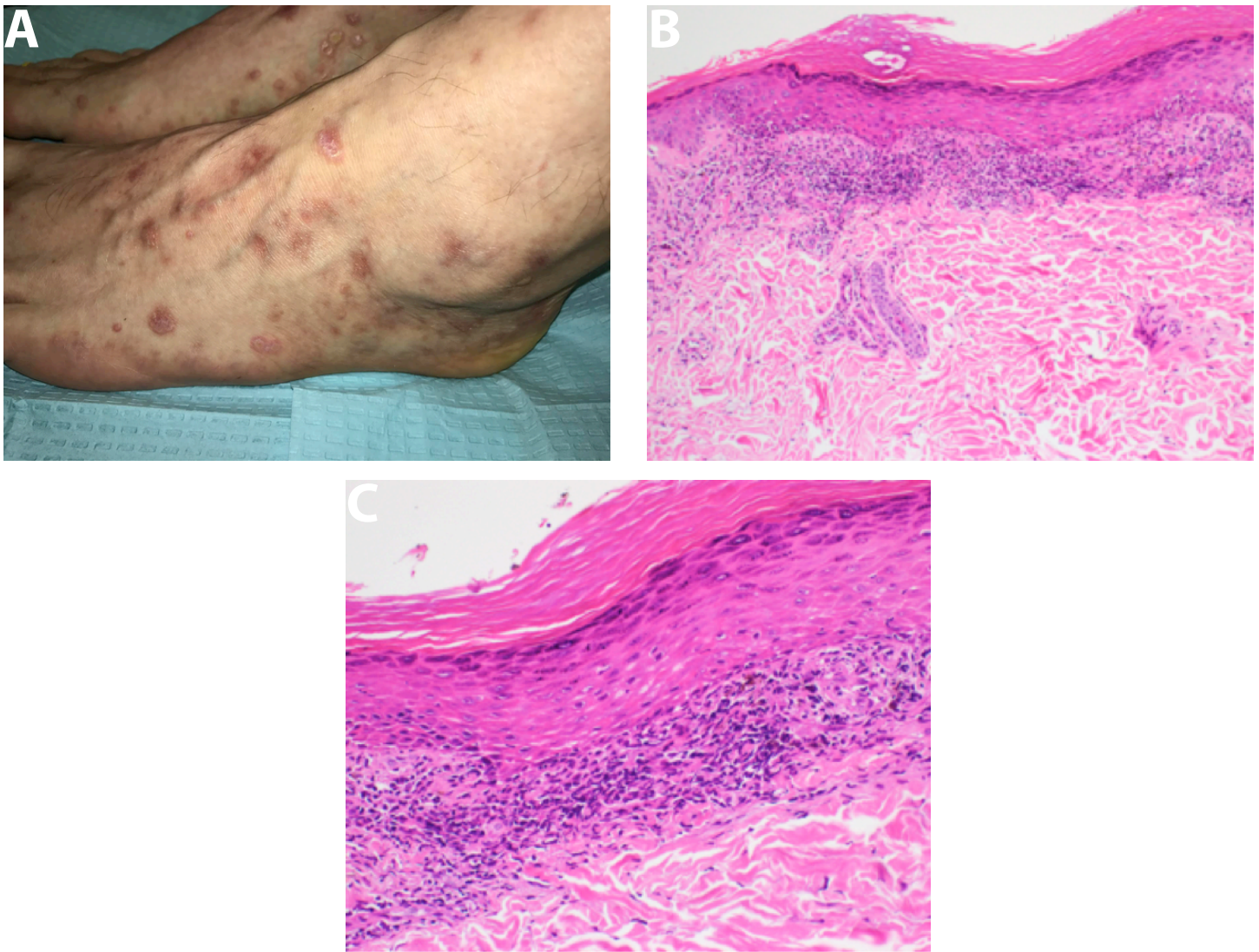
## Case Synopsis

A 51-year-old man treated with nivolumab for stage IV non-small-cell lung cancer (NSCLC) presented with multiple pruritic hypertrophic purple-red polygonal papules with lichenification over ankles and feet. Two years prior to NSCLC diagnosis, he reported a biopsy-proven lichen planus (LP) eruption, partially controlled with fluocinonide ointment. Two infusions of cisplatin, pemetrexed, and bevacizumab coincided with LP resolution. As NSCLC progressed, he was switched to nivolumab monotherapy. Within two weeks, LP recurred aggressively on his hands, feet (**Figure 1A**), and genitals. Histopathologic examination of skin biopsy confirmed the diagnosis (**Figure 1B, C**). Within 1 month, clobetasol ointment therapy made lesions thinner and minimally pruritic, allowing for uninterrupted nivolumab therapy.

## Case Discussion

Hofmann et al. reported that primary adverse dermatologic events occur within 1-75 weeks after treatment initiation in 8.7% of patients receiving anti-PD-1 therapy for melanoma [4]. Mild cutaneous adverse reactions include vitiligo, alopecia, pruritus, eczema, lichen sclerosis; moderate reactions include lichen planus mucosae, erysipelas-like inflammation, hyperkeratosis; severe reactions include lichenoid skin reaction, lichen ruber mucosae, and Sweet syndrome [4].

Shi et al. reported that new-onset lichenoid interface dermatitis occurs in 94% of patients treated with nivolumab for lung carcinoma [5]. Hwang et al.



**Figure 1.** Clinical and histopathological images of lichen planus reactivation. A) Reactivation of previously dormant lichen planus following nivolumab. Multiple variably sized discrete and coalescing purple-red papules with lichenification and hyperkeratotic scale over the bilateral medial plantar arches with extension onto dorsal feet and medial ankles. B) Lichen planus: Orthohyperkeratosis, hypergranulosis, prominent lichenoid infiltrate with destruction of the basal layer and sawtoothing of the rete ridges. H&E, 40%. C) Lichenoid interface dermatitis with associated necrotic keratinocytes and dermal melanophages. Note the absence of parakeratosis and eosinophils that are usually seen in drug-induced lichenoid reactions. H&E, 100%.

reported lichenoid reactions in 17.1% of metastatic melanoma patients receiving pembrolizumab [3]. The 5-fold difference in the incidence of lichenoid reactions between lung cancer and melanoma patients may be due to PD-1 drug variability, or the varying immunogenic responses of malignancies.

More severe cutaneous cases presented earlier (at 1-21 weeks) following initiation of pembrolizumab, whereas mild cutaneous reactions occurred later (at 40 or more weeks), **Table 1**. Twenty-five percent of Hwang et al.'s cohort developed lichenoid reactions within 8.3 months [3]. Our patient's LP reaction occurred 2 weeks after initiating nivolumab. This

short latency period may be attributed to a strong personal and family history of mucosal and cutaneous LP in his mother and brother.

Lichenoid eruptions are generally tolerable and rarely require interruption of therapy. Several treatment modalities have been effective in treating cutaneous reactions, including topical corticosteroids, topical antiseptic therapy, urea- and acetylsalicylic acid-containing ointments, analgesic and antihistamine therapy. Pausing or discontinuing the PD-1 inhibitor has occasionally been required. Topical corticosteroids were most effective in clearing mild reactions. For severe reactions, addition of prednisolone (1 mg/kg)

**Table 1.** Cutaneous side-effects of PD-1 inhibitors for treatment of metastatic melanoma and lung cancer.

Patient	Drug	Cancer	Occurrence after initiation	Treatment	Outcome of side effect	Clinical tumor response to anti-PD-1
Current Case	N	NSCLC	0.5 months	Topical corticosteroids	Improved	Complete resolution
1: Lichenoid interface dermatitis	N	Lung cancer	12.8 months	Topical corticosteroids	Improved	Complete resolution
2: Lichenoid interface dermatitis	N	Lung cancer	1.8 months	Topical corticosteroids	Improved	Partial response
3: Lichenoid interface dermatitis	N	Lung cancer	1.2 months	Topical corticosteroids + minocycline	Improved	Progression of disease
4: Lichenoid interface dermatitis	N	Lung cancer	4.6 months	Topical corticosteroids	Improved	Partial response
5: Lichenoid interface dermatitis	N	Lung cancer	0.8 months	Topical corticosteroids	Improved	Complete resolution
6: Lichenoid interface dermatitis	N	Lung cancer	10.2 months	Topical corticosteroids + Valcyclovir	Improved	Partial response
7: Lichenoid interface dermatitis	N	Lung cancer	2.5-6 months	Topical corticosteroids	Improved	Partial response
8: Lichenoid interface dermatitis	N	Lung cancer	4.5 months	Topical corticosteroids	Improved	Partial response
9: Lichenoid interface dermatitis	N	Lung cancer	1.5 months	Topical corticosteroids	Improved	Progression of disease
10: Lichenoid interface dermatitis	N	Lung cancer	1.3-2.3 months	Topical corticosteroids	Improved	Partial response
11: Lichenoid interface dermatitis	N	Lung cancer	3.1 months	Topical corticosteroids	Improved	Partial response
12: Lichenoid skin reaction	P	MM	0.25 months	Prednisolone 1 mg/kg/d; pause of PD-1	Resolved	Progression of disease
13: Lichenoid skin reaction	P	MM	13.5 months	No treatment	Resolved	Partial response
14: Lichenoid skin reaction	P	MM	9.5 months	Topical corticosteroids	Not resolved	Partial response
15: Lichen Planus	P	MM	5.25 months	Topical corticosteroids and urea-and acetylsalicylic acid-containing ointments; systemic levocetirizine 5mg/d	Improved	Partial response
16: Lichen mucosae	P	MM	0.25 months	Prednisolone 60 mg/d PO over 3 days; cetirizine PO	Improved	N/A

**N: Nivolumab**

**P: Pembrolizumab**

**MM: malignant melanoma**

was sufficient [4].

New-onset LP occurs in 0.4% patients undergoing pembrolizumab treatment for stage III/IV melanoma [4]. Despite reports of PD-1 inhibitor-induced lichenoid reaction in the literature, there is only one case of LP related to nivolumab with concurrent radiation therapy. The authors suggested that combination therapy predisposes to more adverse autoimmune reactions. LP is a T-cell-mediated cutaneous condition. LP-affected keratinocytes strongly express PD-L1 [6]. Anti-PD-1 therapy may trigger an LP flare through T-cell recruitment, contributing to increased incidence in patients using PD-1 inhibitors. In our patient, chemotherapy-induced immunosuppression likely prevented T-cell recruitment and subsequent remission of LP.

## Conclusion

To our knowledge, this is the first reported case of LP reactivation related to nivolumab monotherapy. Specifically, LP manifestation closely followed the patient's immune status: chemotherapy-induced immunosuppression led to LP resolution, whereas immune activation by PD-1 inhibitors triggered LP recurrence. Clinicians should be aware of the potential for new-onset and recurrent LP in patients undergoing immunotherapy.

## References

1. Joseph RW, Cappel M, Goedjen B, et al. Lichenoid dermatitis in three patients with metastatic melanoma treated with anti-PD-1 therapy. *Cancer Immunol Res.* 2015;3(1):18-22. [PMID: 25287118].
2. Wolner ZJ, Marghoob AA, Pulitzer MP, Postow MA, Marchetti MA. A case report of disappearing pigmented skin lesions associated with pembrolizumab treatment for metastatic melanoma. *Br J Dermatol.* 2017. [PMID: 28132411].
3. Hwang SJ, Carlos G, Wakade D, et al. Cutaneous adverse events (AEs) of anti-programmed cell death (PD)-1 therapy in patients with metastatic melanoma: A single-institution cohort. *J Am Acad Dermatol.* 2016;74(3):455-461 e451. [PMID: 26793994].
4. Hofmann L, Forschner A, Loquai C, et al. Cutaneous, gastrointestinal, hepatic, endocrine, and renal side-effects of anti-PD-1 therapy. *Eur J Cancer.* 2016;60:190-209. [PMID: 27085692].
5. Shi VJ, Rodic N, Gettinger S, et al. Clinical and Histologic Features of Lichenoid Mucocutaneous Eruptions Due to Anti-Programmed Cell Death 1 and Anti-Programmed Cell Death Ligand 1 Immunotherapy. *JAMA Dermatol.* 2016;152(10):1128-1136. [PMID: 27411054].
6. Komori T, Honda T, Irie H, Otsuka A, Kabashima K. Lichen Planus in Irradiated Skin During Nivolumab Treatment. *Acta Derm Venereol.* 2017;97(3):391-392. [PMID: 27722767].