

# UC Davis

## Dermatology Online Journal

### Title

A simplified minimally invasive technique for the treatment of venous lakes

### Permalink

<https://escholarship.org/uc/item/50q499fg>

### Journal

Dermatology Online Journal, 20(1)

### Authors

Weiss, Jonathan  
Weiss, Kathleen D  
Ross, Andrew L  
[et al.](#)

### Publication Date

2014

### DOI

10.5070/D3201021257

### Copyright Information

Copyright 2014 by the author(s). This work is made available under the terms of a Creative Commons Attribution-NonCommercial-NoDerivatives License, available at <https://creativecommons.org/licenses/by-nc-nd/4.0/>

Peer reviewed

## Surgical Pearl

### A simplified minimally invasive technique for the treatment of venous lakes

Jonathan Weiss MD<sup>2</sup>, Kathleen D. Weiss BA<sup>1</sup>, Andrew L. Ross MD<sup>2</sup>, Eduardo Weiss MD FAAD<sup>2,3,4</sup>

Dermatology Online Journal 20 (1): 16

<sup>1</sup>University of Miami Miller School of Medicine, <sup>2</sup>Department of Dermatology and Cutaneous Surgery

<sup>3</sup>Hollywood Dermatology & Cosmetic Specialists

<sup>4</sup>Florida International University Herbert Wertheim College of Medicine, Department of Dermatology

### Correspondence:

Eduardo Weiss, MD, FAAD [Corresponding Author]  
University of Miami Miller School of Medicine  
Department of Dermatology and Cutaneous Surgery  
Hollywood Dermatology & Cosmetic Specialists  
3850 Hollywood Blvd; Suite 201  
Hollywood, FL 33021  
eweiss1401@aol.com

## Abstract

A simplified approach to treat venous lakes of the vermilion lip is presented. Our method involves the use of a 30 gauge hypodermic needle to deliver a low-powered, high-frequency electrical current from a hyfrecator power source into the venous lake lesion.

## Introduction

Venous lakes are cutaneous vascular ectasias formed from dilated venules located in the upper dermis [1]. They are most frequently located on the vermilion lips, but can also develop in other parts of the face or the hands. Most patients seek treatment primarily for improvement of cosmetic appearance, although in some cases bleeding may be the main concern.

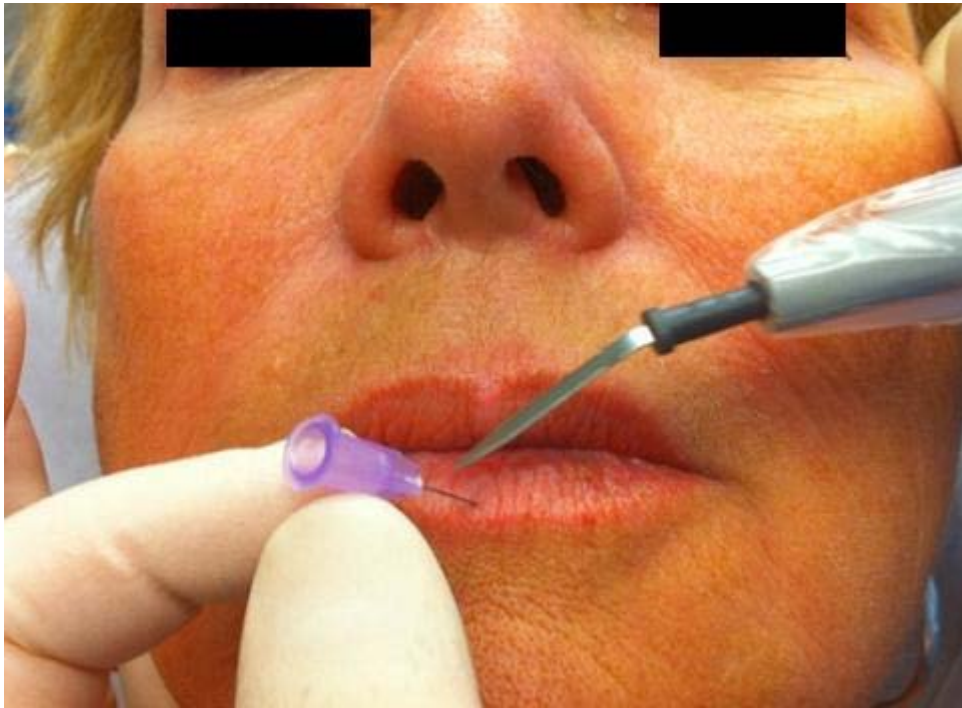Although there are no comprehensive comparative therapeutic trials, multiple case reports have been published describing the successful use of various modalities to treat venous lakes. These include surgical excision [2], cryosurgery [3], infrared coagulation [4], argon lasers [5], intense pulsed light [6], pulsed dye lasers [7-9], Nd:YAG laser [10], diode lasers [11, 12], carbon dioxide lasers [13], and sclerosing agents [14]. The goal of these modalities is to deliver localized therapy to eradicate the venous lake malformation. However, many of these modalities require experience and expensive or specialized equipment that is not readily available in many offices.

**Keywords:** venous lake, hyfrecator, elctrosurgery

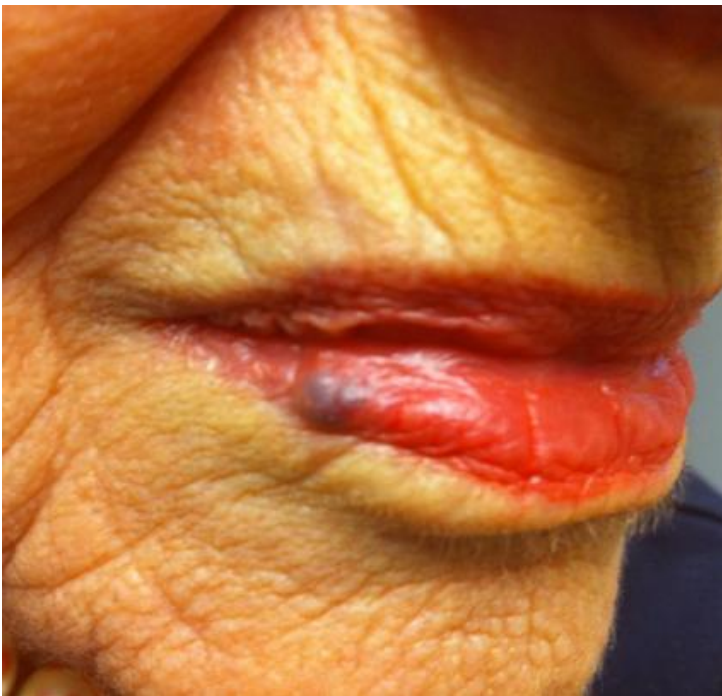## Method

Guarneri et al [15] described a minimally invasive method using a modified intravenous infusion cannula to deliver diathermocoagulation intralesionally from an electroscalpel. Herein, we describe a similar but simplified approach to successfully treat venous lakes of the vermilion lip. Our method involves the use of a 30 gauge hypodermic needle to deliver a low-powered, high-frequency electrical current from a hyfrecator power source into the venous lake lesion. After anesthetizing the area with topical 4% lidocaine, the needle is inserted deep into the vascular lesion. The hyfrecator blade (McKesson 22-940™; monopolar setting; power level of 2.0) is brought into contact with the needle (Figure 1) and an electrical current is continuously delivered while the needle is slowly withdrawn towards the superficial portion of the lesion. This technique is effective in desiccating all

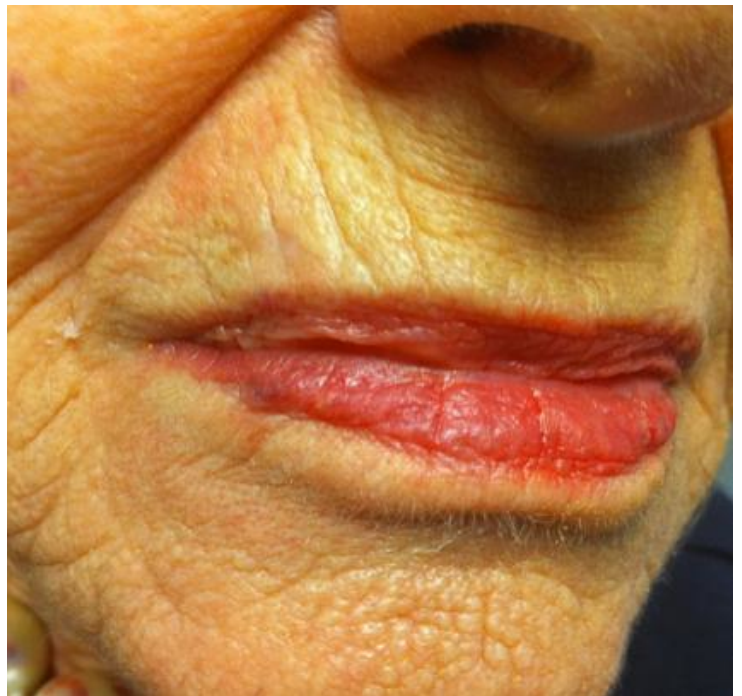
levels of the venous lake. In order to avoid damage to the superficial mucosa, it is important to discontinue delivering current prior to complete withdrawal of the needle.



**Figure 1.** The venous lake is desiccated by conducting electrical current intralesionally through the 30 gauge needle.



**Figure 2A.** 78 year-old woman prior to treatment of venous lake on the lower vermilion lip.



**Figure 2B.** Immediately after treatment using the described method.

## Conclusion

We have observed excellent cosmetic improvement using this method to eradicate venous lake malformations of the vermilion lip. The results are immediate, with the added benefit of minimal recovery time (Figure 2). The use of a 30 gauge needle minimizes pain and discomfort for the patient, and the small diameter reduces the risk of collateral damage to surrounding tissue. No scarring or other adverse effects have been observed or reported at three-month follow up in our clinical experience of over eight patients treated with this method. Our simplified therapeutic approach is inexpensive, minimally invasive, effective, and requires equipment that is readily available in the offices of most dermatologists. Nonetheless, prospective trials comparing our

method to other treatment modalities are warranted to evaluate efficacy, cosmetic outcomes, and risks of adverse events such as scarring.

## References

1. Bean WB, Walsh JR. Venous lakes. *AMA Arch Derm* 1956;74(5):459-63. [PMID:13361527]
2. Huang CC, Arpey CJ. The lips. Excision and repair. *Dermatol Clin* 1998;16(1):127-43. [PMID:9460582]
3. Suhonen R, Kuflik EG. Venous lakes treated by liquid nitrogen cryosurgery. *Br J Dermatol* 1997;137(6):1018-9. [PMID:9470931]
4. Ah-Weng A, Natarajan S, Velangi S, Langtry JA. Venous lakes of the vermilion lip treated by infrared coagulation. *Br J Oral Maxillofac Surg* 2004;42(3):251-3. [PMID:15121273]
5. Neumann RA, Knobler RM. Venous lakes (Bean-Walsh) of the lips – treatment experience with the argon laser and 18 months follow-up. *Clin Exp Dermatol* 1990;15(2):115-8. [PMID:2347101]
6. Jay H, Borek C. Treatment of a venous-lake angioma with intense pulsed light. *Lancet* 1998;351:112. [PMID:9439501]
7. Gonzalez E, Gange RW, Momtaz KT. Treatment of telangiectases and other benign vascular lesions with the 577 nm pulsed dye laser. *J Am Acad Dermatol* 1992;27(2 Pt 1):220-6. [PMID:1430360]
8. Cheung ST, Lanigan SW. Evaluation of the treatment of venous lakes with the 595-nm pulsed-dye laser: a case series. *Clin Exp Dermatol* 2007;32(2):148-50. [PMID:17244345]
9. Roncero M, Canueto J, Blanco S, Unamuno P, Boixeda P. Multiwavelength laser treatment of venous lakes. *Dermatol Surg* 2009;35(12):1942-6. [PMID:19889006]
10. Bekhor PS. Long-pulsed Nd:YAG laser treatment of venous lakes: report of a series of 34 cases. *Dermatol Surg* 2006;32(9):1151-4. [PMID:16970696]
11. Wall TL, Grassi AM, Avram MM. Clearance of multiple venous lakes with an 800-nm diode laser: a novel approach. *Dermatol Surg* 2007;33(1):100-103. [PMID:17214688]
12. Azevedo LH, Galletta VC, de Paula Eduardo C, Migliari DA. Venous lake of the lips treated using photocoagulation with high-intensity diode laser. *Photomed Laser Surg* 2010;28(2):263-5. [PMID:19811083]
13. Del Pozo J, Pena C, Garcia Silva J, Goday JJ, Fonseca E. Venous lakes: a report of 32 cases treated by carbon dioxide laser vaporization. *Dermatol Surg* 2003;29(3):308-10. [PMID:12614431]
14. Hung-Wen K, Chih-Hsun Y. Venous lake of the lip treated with a sclerosing agent: report of two cases. *Dermatol Surg* 2003;39(4):425-8. [PMID:12656828]
15. Guarneri GF, De Biasio F, Semprini G, Cracco S, Parodi P. A simple method to treat venous lakes. *Dermatol Surg* 2010;36(10):1586-7. [PMID:20840497]