

UC Davis

Dermatology Online Journal

Title

Primary anetoderma with undifferentiated connective tissue disease

Permalink

<https://escholarship.org/uc/item/57z528kx>

Journal

Dermatology Online Journal, 23(12)

Authors

Tong, Lana X
Beasley, Jenna
Meehan, Shane
et al.

Publication Date

2017

DOI

10.5070/D32312037676

Copyright Information

Copyright 2017 by the author(s). This work is made available under the terms of a Creative Commons Attribution-NonCommercial-NoDerivatives License, available at <https://creativecommons.org/licenses/by-nc-nd/4.0/>

Peer reviewed

Primary anetoderma with undifferentiated connective tissue disease

Lana X Tong MD MPH, Jenna Beasley MD, Shane Meehan MD, Evan Rieder MD, Miriam Pomeranz MD, Kristen Lo Sicco MD, Alisa Femia MD, Randie Kim MD PhD, Andrew G Franks Jr MD

Affiliations: New York University Health, New York

Abstract

Anetoderma is a rare benign elastolytic disorder that is characterized by focal loss of elastin fibers on histopathology and is often recalcitrant to treatment. We present a case of a patient with a 20-year history of pruritic and painful hyperpigmented atrophic papules clustered on the neck, axillae, inframammary folds, and right medial thigh. Although the histopathology of her axillary lesions was consistent with anetoderma, her clinical presentation is unusual given the extent of involvement, reported pain and pruritus, and sharp demarcation of the distribution. The diagnostic uncertainty of this case led to added difficulty in management of a disease that is already notoriously difficult to treat and may significantly impact patient's quality of life.

Keywords: anetoderma, medical dermatology, macular atrophy

Introduction

HISTORY: A 46-year-old Sudanese woman with a history of diabetes presented to the Bellevue Dermatology Clinic for evaluation of numerous painful and pruritic skin lesions on her trunk. The patient stated that this eruption initially began after she gave birth to her first child in Sudan and had persisted for the past 20 years. Recently, she noticed new lesions developing on her neck. She denied any preceding erythematous or symptomatic skin lesions. Full review of systems was positive for neck and low back pain. Although she was uncertain of the names, she noted having tried numerous topical therapies without success, including camphor 0.5%-menthol 0.5% lotion and hydroquinone 3% solution. Three months prior to her presentation, she was seen by a rheumatologist and was started

on hydroxychloroquine 200 mg twice daily. She also reported no family history of dermatologic or autoimmune diseases, although she has had multiple second trimester miscarriages.

PHYSICAL EXAMINATION: There were numerous soft, atrophic, hyperpigmented, nontender papules coalescing into sharply demarcated, depressed plaques on the neck. She also had hyperpigmented patches on the cheeks, as well as a few scattered sac-like protrusions of flaccid skin on the inframammary folds, axillae, inguinal folds, and right medial thigh.

LABORATORY DATA: An antinuclear antibody (ANA) test was positive at a titer of 1:640 and speckled pattern. The anti-Ro/La antibody test was negative. Testing for human immunodeficiency virus was negative. A rapid plasma reagin test was negative. Testing for an antiphospholipid antibody was negative, which included a negative lupus anticoagulant, a negative anti-beta-2 glycoprotein antibody, and a negative anti-cardiolipin antibody.

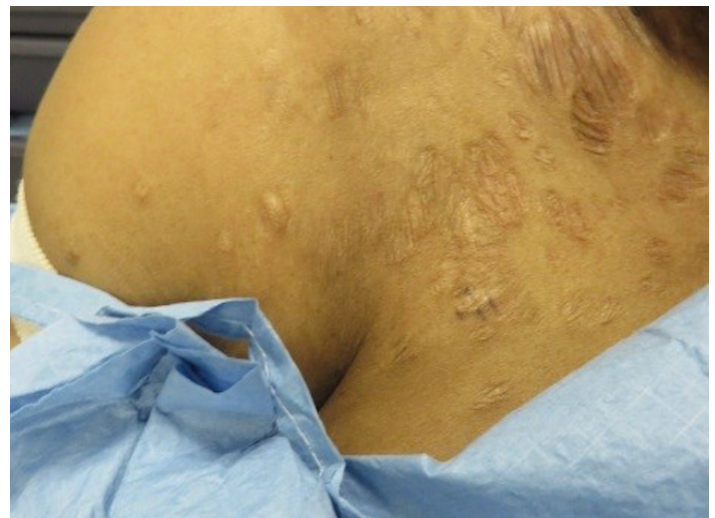

Figure 1.: Numerous soft, atrophic, hyperpigmented, nontender papules coalescing into sharply demarcated, depressed plaques on the neck and axillae.

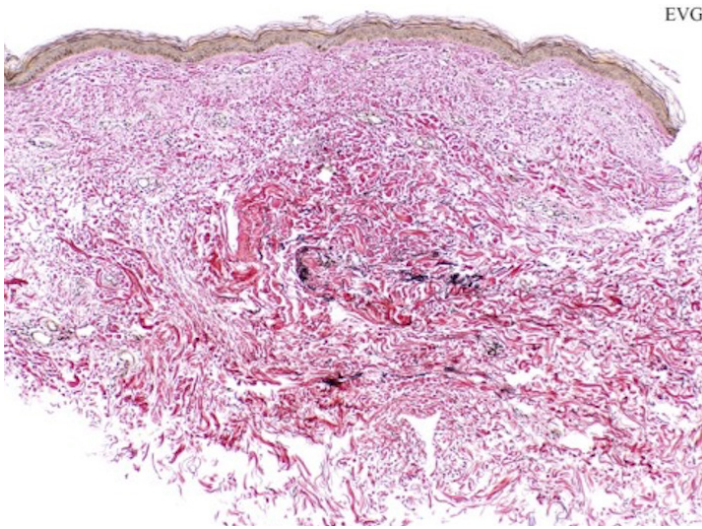


Figure 2. After 7 months of oral pentoxifylline 400 mg t.i.d. with meals. While there are remaining small hemorrhages and minor microvascular proliferation, the overall retinal vascular healing parallels the visual and neurological improvements.

The patient also had a normal coagulation profile. Testing for an anti-ribonucleoprotein antibody is pending at the time of this writing.

HISTOPATHOLOGY: A 4 mm punch biopsy was performed at Bellevue on an atrophic papule in the right axillary vault. Within the dermis, there are thin collagen bundles with loss of elastic fibers as highlighted by an EVG stain.

Conclusion

Anetoderma is a rare benign elastolytic dermatosis. This condition typically affects middle-aged women, though the prevalence is unknown [1]. It presents with erythematous or flesh-colored, sac-like atrophic papules that herniate on palpation. Anetoderma can be primary or secondary. Primary anetoderma occurs in areas without preceding primary dermatoses, although it may have preceding inflammatory lesions, and has been associated with HIV and autoimmune diseases including systemic lupus erythematosus, systemic sclerosis and thyroiditis [2, 3, 4]. Primary anetoderma may also be a clue to the presence of an antiphospholipid antibody, and in some, antiphospholipid antibody syndrome [3, 4].

Secondary anetoderma presents in areas of a previous skin disorder or infection, most commonly acne or varicella. Secondary anetoderma is associated with infectious diseases, such as herpes zoster, tuberculosis, and syphilis; and neoplasms,

such as lymphoma [5, 6, 7], mycosis fungoides, and juvenile xanthogranuloma [8, 9, 10, 11]. Histologically, anetoderma demonstrates focal loss of elastin fibers in the reticular or papillary dermis [12]. The pathogenesis is unclear, and it is thought to be enzymatically mediated by elastases and matrix metalloproteinases secreted by inflammatory cells [6]. Degeneration of elastin may also be caused by local ischemia secondary to vasculitis [13, 14].

The clinical and histopathological findings in this case, as well as the lack of any preceding inflammatory lesions, made primary anetoderma the leading diagnosis for our patient. However, the extent of her skin involvement, the sharp demarcation of the eruption particularly on the neck, and the hyperpigmentation and shiny wrinkling of the lesions is suggestive of a superimposed, or possibly different, elastolytic disorder such as mid dermal elastolysis, atrophoderma, or an iatrogenic etiology such as steroid striae. In addition, the significant pruritus and pain experienced by the patient is atypical for classic anetoderma, which is usually asymptomatic. Additional biopsies may be helpful to clarify the diagnosis in this case. This can include a biopsy of the neck, which has a different morphology, or a biopsy of her normal-appearing skin to evaluate for atrophoderma.

Given the reported associations, typical workup for patients diagnosed with primary anetoderma includes an ANA titer, HIV, and an anti-phospholipid antibody panel, i.e. lupus anticoagulant, anti-cardiolipin antibody, and anti-beta-2-glycoprotein antibody [3]. Although our patient had an elevated ANA titer, her autoimmune laboratory workup was otherwise negative. She reported a history of miscarriages but had an unremarkable hypercoagulability workup. Further laboratory workup or careful monitoring is recommended as primary anetoderma may be a harbinger of future disease [15].

The uncertainty of diagnosis in this case also leads to difficulty in management. Topical corticosteroids should be avoided in our patient given the noted skin atrophy on exam, although intralesional triamcinolone has been reported to treat anetoderma with limited effectiveness. In cases where preceding inflammatory lesions are observed, topical corticosteroids may be

helpful [15]. Our patient reported some improvement with hydroxychloroquine, but she was also very motivated to seek further treatment for relief of tenderness and pruritus, as well as for cosmesis. Risk of dyspigmentation should additionally be considered given that our patient has a darker Fitzpatrick skin type.

There is no established treatment for anetoderma, though topical corticosteroids, systemic medications, surgery and laser therapies have been used. Treatment options should address the loss of elastic fibers seen on histology. Several groups have reported varying efficacy utilizing neutrophilic chemotactic inhibitors such as colchicine and dapsone [1, 16]. Other treatments include cryotherapy, oral epsilon-aminocaproic acid, oral vitamin E, penicillin G, niacin, phenytoin and aspirin [17]. Surgical excision may be a consideration in patients with limited involvement. Case reports have been published showing efficacy with ablative carbon dioxide fractional lasers with minimal adverse effects and no recurrence [11, 18]. Fractional laser systems are thought to stimulate collagen production, thus inducing neolastogenesis [19]. Another case report demonstrated benefit with combination 595-nm pulsed-dye laser and 1550-nm non-ablative fractionated laser [20]. Laser therapy may be a helpful, minimally invasive treatment modality for anetoderma, although further research is warranted to determine the extent of clinical improvement that can be achieved.

References

1. Venencie PY, Winkelmann RK, Moore BA. Anetoderma. Clinical findings, associations, and long-term follow-up evaluations. *Arch Dermatol*. 1984;120(8):1032-9. [PMID: 6465909].
2. Jeong NJ, Park SB, Im M, Seo YJ, Lee JH, Lee Y. Eruptive anetoderma in a patient with systemic lupus erythematosus. *Ann Dermatol*. 2014;26(5):621-3. [PMID: 25324656].
3. Hodak E, Feuerman H, Molad Y, Monselise Y, David M. Primary anetoderma: a cutaneous sign of antiphospholipid antibodies. *Lupus*. 2003;12(7):564-8. [PMID: 12892400].
4. Thornsberry LA, LoSicco KI, English JC, 3rd. The skin and hypercoagulable states. *J Am Acad Dermatol*. 2013;69(3):450-62. [PMID: 23582572].
5. Varshney A, Goyal T, Zawar V, Tinguely M, Kempf W. Disseminated anetoderma in a patient with nodal Epstein-Barr virus-associated classical Hodgkin lymphoma: Anetodermic form of a concurrent discordant cutaneous marginal zone lymphoma. *Int J Dermatol*. 2016;55(7):739-44. [PMID: 26945704].
6. Uchiyama A, Motegi S, Okada E, Hirai N, Nagai Y, Tamura A, Ishikawa O. Cutaneous marginal zone B-cell lymphoma evolving into anetoderma: a role of matrix metalloproteinases? *Acta Derm Venereol*. 2015;95(4):499-500. [PMID: 25350822].
7. Zattra E, Pigozzi B, Bordignon M, Marino F, Chiarion-Sileni V, Alaibac M. Anetoderma in cutaneous marginal-zone B-cell lymphoma. *Clin Exp Dermatol*. 2009;34(8):e945-8. [PMID: 19778307].
8. Hodak E, Shamaï-Lubovitz O, David M, Hazaz B, Katzenelson-Weissman V, Lahav M, Sandbank M. Immunologic abnormalities associated with primary anetoderma. *Arch Dermatol*. 1992;128(6):799-803. [PMID: 1599266].
9. Ang P, Tay YK. Anetoderma in a patient with juvenile xanthogranuloma. *Br J Dermatol*. 1999;140(3):541-2. [PMID: 10233285].
10. Gamo R, Ortiz-Romero P, Sopena J, Guerra A, Rodriguez-Peralto JL, Iglesias L. Anetoderma developing in juvenile xanthogranuloma. *Int J Dermatol*. 2005;44(6):503-6. [PMID: 15941443].
11. Lee SM, Kim YJ, Chang SE. Pinhole carbon dioxide laser treatment of secondary anetoderma associated with juvenile xanthogranuloma. *Dermatol Surg*. 2012;38(10):1741-3. [PMID: 22861121].
12. Venencie PY, Winkelmann RK. Histopathologic findings in anetoderma. *Arch Dermatol*. 1984;120(8):1040-4. [PMID: 6465910].
13. Stephansson EA, Niemi KM. Antiphospholipid antibodies and anetoderma: are they associated? *Dermatology*. 1995;191(3):204-9. [PMID: 8534938].
14. Herrero-Gonzalez JE, Herrero-Mateu C. Primary anetoderma associated with primary Sjogren's syndrome. *Lupus*. 2002;11(2):124-6. [PMID: 11958576].
15. Xia FD, Hoang MP, Smith GP. Anetoderma before development of antiphospholipid antibodies: delayed development and monitoring of antiphospholipid antibodies in an SLE patient presenting with anetoderma. *Dermatol Online J*. 2017;23(3). [PMID: 28329518].
16. Braun RP, Borradori L, Chavaz P, Masouye I, French L, Saurat JH. Treatment of primary anetoderma with colchicine. *J Am Acad Dermatol*. 1998;38(6 Pt 1):1002-3. [PMID: 9632017].
17. Kineston DP, Xia Y, Turiansky GW. Anetoderma: a case report and review of the literature. *Cutis*. 2008;81(6):501-6. [PMID: 18666393].
18. Cho S, Jung JY, Lee JH. Treatment of anetoderma occurring after resolution of Stevens-Johnson syndrome using an ablative 10,600-nm carbon dioxide fractional laser. *Dermatol Surg*. 2012;38(4):677-9. [PMID: 22251221].
19. Manstein D, Herron GS, Sink RK, Tanner H, Anderson RR. Fractional photothermolysis: a new concept for cutaneous remodeling using microscopic patterns of thermal injury. *Lasers Surg Med*. 2004;34(5):426-38. [PMID: 15216537].
20. Wang K, Ross NA, Saedi N. Anetoderma treated with combined 595-nm pulsed-dye laser and 1550-nm non-ablative fractionated laser. *J Cosmet Laser Ther*. 2016;18(1):38-40. [PMID: 25968163].