

# UC Davis

## Dermatology Online Journal

### Title

Disseminated cutaneous mycobacterium avium complex in a person with AIDS

### Permalink

<https://escholarship.org/uc/item/5v0968f2>

### Journal

Dermatology Online Journal, 20(5)

### Authors

Endly, DC  
Ackerman, LS

### Publication Date

2014

### DOI

10.5070/D3205022616

### Copyright Information

Copyright 2014 by the author(s). This work is made available under the terms of a Creative Commons Attribution-NonCommercial-NoDerivatives License, available at <https://creativecommons.org/licenses/by-nc-nd/4.0/>

Peer reviewed

## Case Presentation

### Disseminated cutaneous mycobacterium avium complex in a person with AIDS

Endly DC<sup>1</sup>, Ackerman LS<sup>1,2</sup>

Dermatology Online Journal 20 (5): 10

<sup>1</sup>Department of Internal Medicine, Banner Good Samaritan Medical Center, Phoenix, AZ

<sup>2</sup>Medical Dermatology Specialists, Phoenix, AZ

## Correspondence:

Dawnielle Endly, DO  
10602 W Harmony Lane  
Peoria, AZ 85382  
Email: DawnielleEndly@hotmail.com  
Phone: (720) 427-0740  
Fax: (602) 354-5607

## Abstract

A cutaneous *Mycobacterium avium complex* (MAC) infection is a rare infection that can occur through direct inoculation or via dissemination to the skin. We report an interesting case of disseminated cutaneous MAC infection in a 45-year-old man with acquired immunodeficiency syndrome (AIDS), currently treated with highly active antiretroviral therapy (HAART) and MAC prophylaxis.

**Key words:** Disseminated, cutaneous, *Mycobacterium avium intracellulare*, *Mycobacterium avium complex*, human immunodeficiency virus, acquired immunodeficiency syndrome

## Introduction

*Mycobacterium avium* and *Mycobacterium intracellulare* are nontuberculous mycobacterial (NTM) pathogens that are often grouped together as *Mycobacterium avium intracellulare* (MAI) or *Mycobacterium avium complex* (MAC). The NTM pathogen most commonly associated with disease in the United States and Australia is MAC with pulmonary disease as the most common clinical presentation [1, 2].

Cutaneous MAC infections are very rare and until the late 1990's, dissemination of MAC to the skin appeared to be more frequent than primary, localized skin infections [3,4]. Disseminated cutaneous MAC usually affects persons whom are immunocompromised secondary to human immunodeficiency virus (HIV) infection [5]. Since the late 1990's, reports of cutaneous MAC are very limited and usually describe primary cutaneous MAC infections [6,7]. The advent of HAART in 1996 likely attributes to the extraordinary decrease in reports of disseminated cutaneous MAC infections [8].

## Case synopsis

A 45-year-old man with AIDS, reportedly compliant on HAART and MAC prophylaxis, was admitted to an inpatient medicine ward in October 2013 for his fourth hospitalization within two months for recurrent diarrhea. At the time of his first hospitalization, he was found to have retroperitoneal lymphadenopathy that was confirmed histologically and microbiologically to be caused by disseminated MAC infection. It was at that time that anti-mycobacterial medications including azithromycin 250mg by mouth daily, ethambutol 450mg by mouth twice daily, and rifabutin 300mg by mouth daily were initiated.

Several weeks later, he was re-admitted with diarrhea and stool *Clostridium difficile* toxin results were positive. He completed two weeks of oral metronidazole 500mg by mouth three times daily, but diarrhea continued. After being stabilized during his third hospitalization, he was discharged home with 3 weeks of vancomycin 125mg by mouth every six hours, but this was also unsuccessful. Upon the most recent admission, anti-mycobacterial medications were held and the patient was treated with oral vancomycin 250mg by mouth every six hours, despite negative stool *Clostridium difficile* toxin results. The patient complained of ongoing diarrhea, chills, malaise, and decreased appetite.

Physical exam upon admission revealed a very thin man with a body mass index of 17, but the examination was otherwise unremarkable. A CD4 T-cell panel completed 12 days prior to admission revealed a mild leukocytosis ( $11.3 \times 10^3$  white blood cells per microliter) and an absolute CD4 T-cell count of 16 (normal 365-2100). A complete blood count upon admission revealed anemia with hemoglobin of 7.5 g/dL and hematocrit of 23.6% with an ongoing mild leukocytosis ( $12.5 \times 10^3$  white blood cells per microliter). Complete metabolic panel was normal, except for hyponatremia of 128 mEq/L. Several colonic biopsies were obtained during a flexible sigmoidoscopy that identified multiple small areas of erythema and erosions. Pathology of colonic mucosa revealed a focal histiocytic infiltrate containing numerous intracellular acid fast bacillus (AFB) positive mycobacteria consistent with MAC colitis. Chest x-ray was unremarkable.

Five days after admission, the patient spiked a fever of 39.2 C (102.6 F) and he reported new onset of diffuse pruritus with a rapidly evolving cutaneous eruption across his lumbosacral area and right lateral arm. A dermatology consultation was requested and cutaneous examination revealed mildly tender, erythematous, juicy papules scattered on his ears, neck, back, arms, and hands (Figures 1,2, and 3). The patient had not started any new medications other than the recently completed courses of oral metronidazole and vancomycin. Mild leukocytosis remained at  $11.3 \times 10^3$  white blood cells per microliter. Erythrocyte sedimentation rate and C-reactive protein values were not assessed. Blood specimens collected at the onset of the eruption revealed a positive AFB stain and MAC was identified on blood cultures.

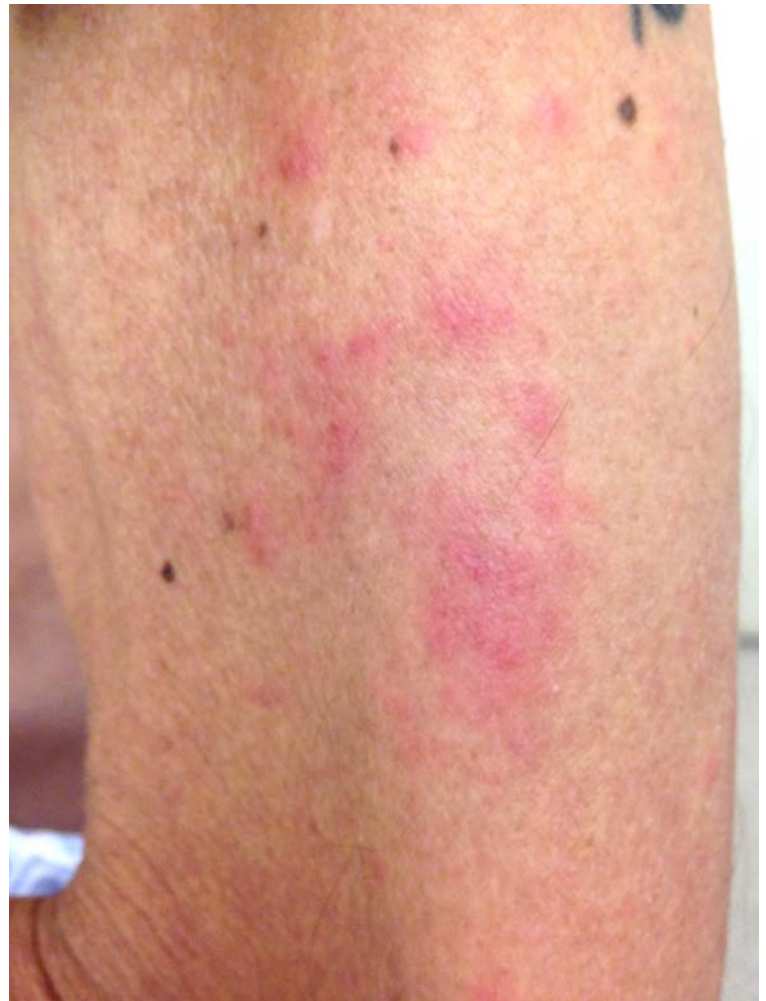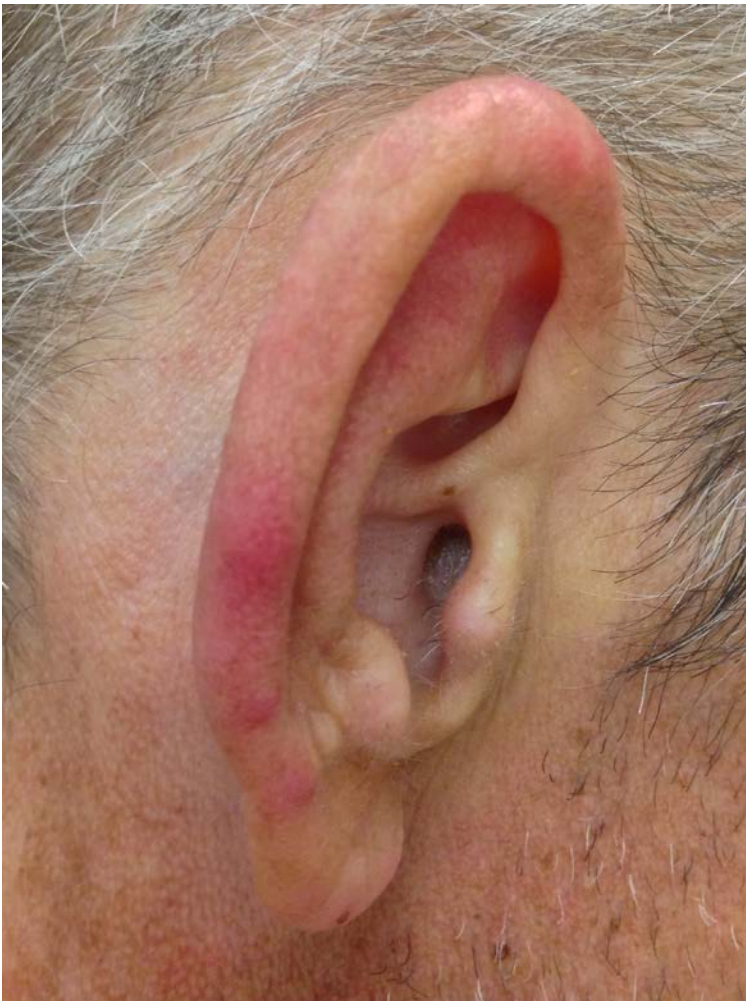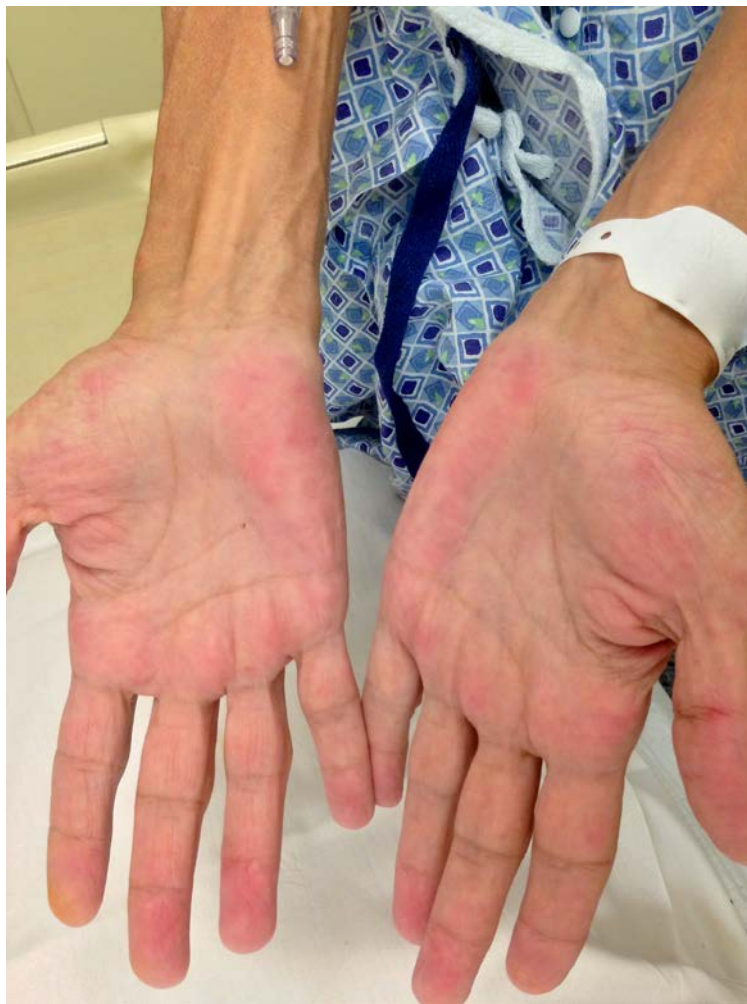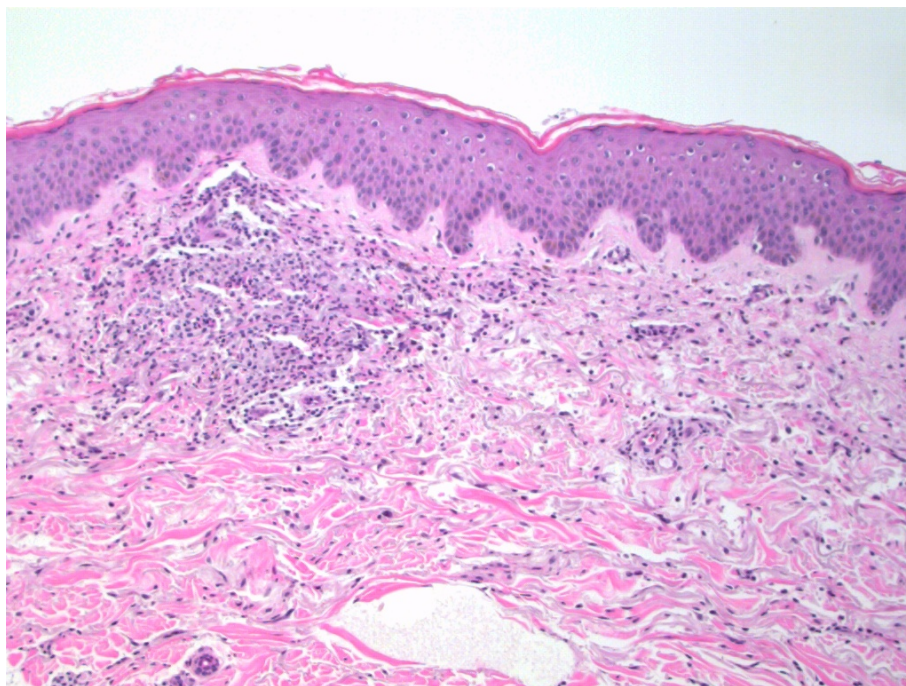


Figure 1,2. Erythematous papules on day 1

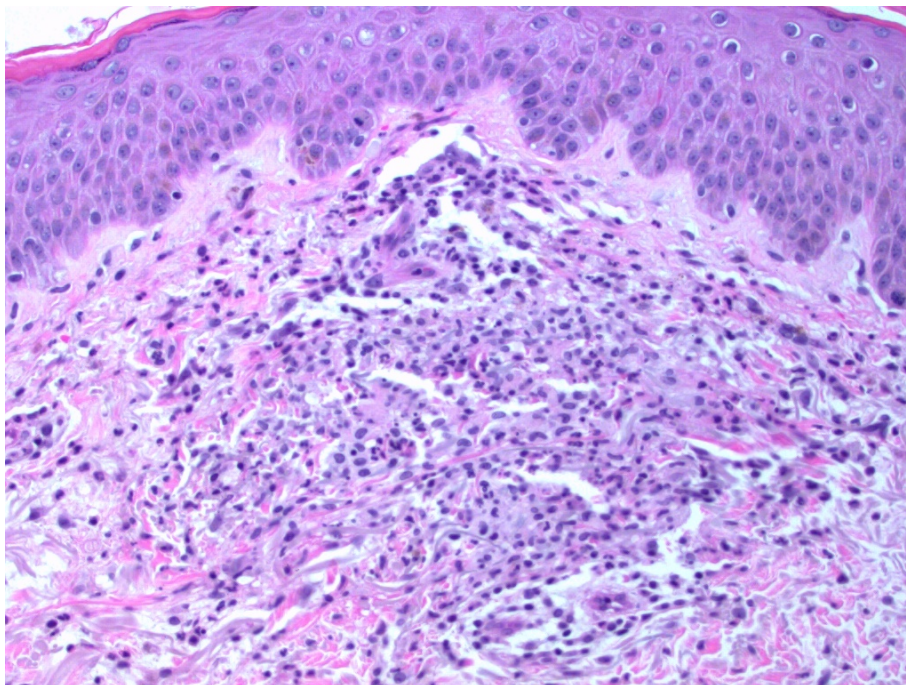


**Figure 3.** Palmar hands on day 1 of cutaneous eruption demonstrate several scattered juicy, erythematous papules.

Two 6mm punch biopsies were performed on unexcoriated papules on the left arm for histologic evaluation and tissue cultures. Histopathologic findings revealed neutrophilic eccrine inflammation and very focal granulomatous inflammation around a nerve. Grocott's methenamine silver (GMS), AFB, and Fite stains were all negative, but cutaneous tissue cultures were positive for MAC. The above history and physical support a diagnosis of disseminated cutaneous MAC infection.



**Figure 4. Granulomatous infiltration**



**Figure 5.** Histopathological findings from a punch biopsy reveal neutrophilic eccrine inflammation and granulomatous inflammation.

Upon discharge, oral vancomycin was discontinued and the patient was again placed on anti-mycobacterial medications including azithromycin 500mg by mouth daily, ethambutol 500mg by mouth twice daily, and rifabutin 300mg by mouth daily in conjunction with his ongoing HAART regimen. At last assessment, the diarrhea and pruritus resolved within a few days of re-instituting anti-mycobacterial medications.

## Discussion

Infections caused by MAC are unusual and when present, affected patients are usually immunocompromised. Disseminated disease usually describes infection involving the blood, bone marrow, lymph nodes, spleen, and bone; skin involvement is very rare. In 1988, Friedman et al [4] reported that younger individuals in their 20's were most prone to cutaneous involvement with disseminated MAC.

The clinical presentation, histopathological findings, and culture results from a skin biopsy should all be considered when making a diagnosis of disseminated cutaneous MAC infection. Clinically, patients with disseminated disease generally appear very ill and have associated weight loss, fever, and chills, as in our case. A myriad of cutaneous lesions are possible and include papules as seen in our case, nodules, pustules, ulcers, abscesses, folliculitis, panniculitis, and even soft tissue swelling [4]. Histopathologically, there is a wide spectrum of patterns that may be seen with cutaneous MAI infections including a diffuse histiocytic infiltrate, panniculitis, nonspecific inflammatory infiltrate, and granulomas [5,9].

Ultimately, the diagnosis of cutaneous MAC depends on a positive culture of the specific pathogen from a skin biopsy [1]. Tissue biopsy is the most sensitive means of obtaining a specimen for culture [1]. Despite histopathological AFB stains being negative in our case, cultures from the patient's skin biopsy grew MAC. Also, disseminated cutaneous MAC rarely occurs without concomitant bacteremia, which is considered presumptive evidence of a disseminated infection [3]. Blood cultures collected in our case indeed verify presence of MAC bacteremia and further support a diagnosis of disseminated cutaneous MAC infection.

Unfortunately, despite anti-mycobacterial agents, the median survival of individuals suffering disseminated MAC infections is around 4 months [2,10]. Patients given HAART concurrently with anti-mycobacterial agents in an attempt to restore their immune system may have improved survival [2].

## Conclusion

Although disseminated cutaneous MAC infections are increasingly rare since the advent of HAART, clinicians should have an increased awareness of the vast array of possible cutaneous findings. When cutaneous MAC infection is a possibility, it is important to collect a skin biopsy for tissue culture because tissue AFB stains may be insensitive. Early recognition of potential cutaneous MAC will enable prompt initiation of anti-mycobacterial treatments and may permit better patient outcomes.

## References

1. Griffith DE, Askamit T, Brown-Elliot BA, Catanzaro A, Daley C, Gordin F, Holland SM, Horsburgh R, Huitt G, Iademarco MF, Iseman M, Olivier K, Ruoss S, von Reyn CF, Wallace RJ Jr, Winthrop K. ATS Mycobacterial Diseases Subcommittee, American Thoracic Society, Infectious Disease Society of America: An official ATS/IDSA statement: diagnosis, treatment, and prevention of nontuberculous mycobacterial diseases. *Am J Respir Crit Care Med*. 2007;175:367-416. [PMID: 17277290].
2. O'Brien DP, Currie BJ, Krause VL. Nontuberculous mycobacterial disease in northern Australia: a case series and review of the literature. *Clin Infect Dis*. 2000;31:958-967. [PMID: 11049777].
3. Inwald D, Nelson M, Cramp M, Francis N, Gazzard B. Cutaneous manifestations of mycobacterial infection in patients with AIDS. *Br J Dermatol*. 1994;130:111-114. [PMID: 8305299].
4. Friedman BF, Edwards D, Kirkpatrick CH. *Mycobacterium avium* intracellulare: cutaneous presentations of disseminated disease. *Am J Med*. 1988;85:257-263. [PMID: 3400704].
5. Sanderson TL, Moskowitz L, Hensley GT, Cleary TJ, Penneys N. Disseminated *Mycobacterium avium*-intracellulare infection appearing as a panniculitis. *Arch Pathol Lab Med*. 1982;106:112-114. [PMID: 6895835].
6. Aboutalebi A, Shen A, Katta R, Allen SE. Primary cutaneous infection by *Mycobacterium avium*: a case report and literature review. *Cutis* 2012;89:175-179. [PMID: 22611745].
7. Pietras TA, Baum CL, Swick BL. Coexistent Kaposi sarcoma, cryptococcosis, and *Mycobacterium avium* intracellulare in a solitary cutaneous nodule in a patient with AIDS: report of a case and literature review. *J Am Acad Dermatol*. 2010;62:676-680. [PMID: 20227582].
8. Coelho L, Veloso VG, Grinsztejn B, Luz PM. Trends in overall opportunistic illnesses, *Pneumocystis carinii* pneumonia, cerebral toxoplasmosis and *Mycobacterium avium* complex incidence rates over 30 years of the HIV epidemic: a systematic review. *Braz J Infect Dis*. 2013; Epub ahead of print. [PMID: 24275372].
9. Santa Cruz DJ, Strayer DS. The histological spectrum of the cutaneous mycobacteriosis. *Hum Pathol*. 1982;13:485-495. [PMID: 6804365].
10. Shafran SD, Singer J, Zaroway DP, Phillips P, Salit I, Walmsley SL, Fong IW, Gill MJ, Rachlis AR, Lalonde RG, Fanning MM, Tsoukas CM. A comparison of two regimens for the treatment of *Mycobacterium avium* complex bacteremia in AIDS: rifabutin, ethambutol, and clarithromycin vs. rifampin, ethambutol, clofazimine, and ciprofloxacin. Canadian HIV Trials Network Protocol 010 Study Group. *N Engl J Med*. 1996;335:377-383. [PMID: 8676931].