

UC Davis

Dermatology Online Journal

Title

Folliculotropic mycosis fungoides

Permalink

<https://escholarship.org/uc/item/5w68b51g>

Journal

Dermatology Online Journal, 24(12)

Authors

Feng, Hao
Beasley, Jenna
Meehan, Shane
et al.

Publication Date

2018

DOI

10.5070/D32412042458

Copyright Information

Copyright 2018 by the author(s). This work is made available under the terms of a Creative Commons Attribution-NonCommercial-NoDerivatives License, available at <https://creativecommons.org/licenses/by-nc-nd/4.0/>

Peer reviewed

Folliculotropic mycosis fungoides

Hao Feng MD MHS, Jenna Beasley MD, Shane Meehan MD, Tracey N. Liebman MD

Affiliations: The Ronald O. Perelman Department of Dermatology, New York University Langone Health, New York, New York, USA

Corresponding Author: Hao Feng MD, 240 East 38th Street, 11th Floor, New York, NY 10016, Tel: 212-263-5889, Email: haofeng625@gmail.com

Abstract

Folliculotropic mycosis fungoides (MF) is a distinct subset of cutaneous T cell lymphoma (CTCL). The disease is typically marked by an aggressive course and is often recalcitrant to skin-direct therapy. We report a case of an 83-year-old woman with folliculotropic MF characterized by erythematous, scaly plaques on the forehead along with poliosis and alopecia of the right medial eyebrow.

Keywords: mycosis fungoides, cutaneous T-cell lymphoma

Introduction

Folliculotropic mycosis fungoides is a subset of MF that is often marked by an aggressive course. There is a predilection for follicular units in the head and neck region with typical eyebrow involvement. The clinical presentation can vary and may include patches, plaques, nodules, acneiform lesions, comedones, cysts, alopecia, and prurigo-like nodules. The etiology of disease development is not completely understood. Treatment is usually more aggressive than that for classic mycosis fungoides. Remission usually requires systemic therapies such as psoralen with ultraviolet A, acitretin, bexarotene, total skin electron beam, romidepsin, or interferon.

Case Synopsis

An 83-year-old woman presented to New York University Dermatologic Associates for evaluation of forehead “bumps” that had developed over the past year. She denied pruritus or pain and also denied rubbing or scratching of the area. She initially presented to an outside dermatologist who prescribed topical hydrocortisone cream, which

helped briefly when used for two weeks. In addition, the patient reported many years of asymptomatic, mild, diffuse hair thinning of the scalp without discrete areas of loss. She denied fever, chills, weight loss, and other skin eruptions. Her medications included escitalopram and bupropion. She had no other relevant past medical history or history of any malignancies.

The patient was well appearing, alert, oriented, and in no acute distress. There was a skin-colored-to-mildly-erythematous plaque involving the right medial eyebrow and right mid forehead. There was induration, hypopigmented hairs, and decreased hair density involving the medial aspect of the right eyebrow and extending to the mid-eyebrow down the mid-pupillary line (**Figure 1**). The left eyebrow showed no erythema, edema, scaling, hypopigmented hairs, decreased hair density, or induration. There was mild hair thinning but no distinct pattern of alopecia, perifollicular scaling, or erythema of the scalp. The conjunctivae were non-injected, and her oral mucous membranes were moist. There was no submandibular, cervical, axillary, or inguinal lymphadenopathy. Complete metabolic panel, complete blood count, and Quantiferon-gold were within normal limits. Hepatitis C virus antibody was non-reactive. Hepatitis B surface antigen and core antibody were non-reactive. Positron emission tomography - computed tomography scan without contrast showed no frank evidence of fluorodeoxyglucose-avid disease or lymphadenopathy.

A 4mm punch biopsy was performed over the peripheral edge of the indurated, skin-colored-to-mildly-erythematous plaque over the patient’s right medial eyebrow. This revealed a perivascular and

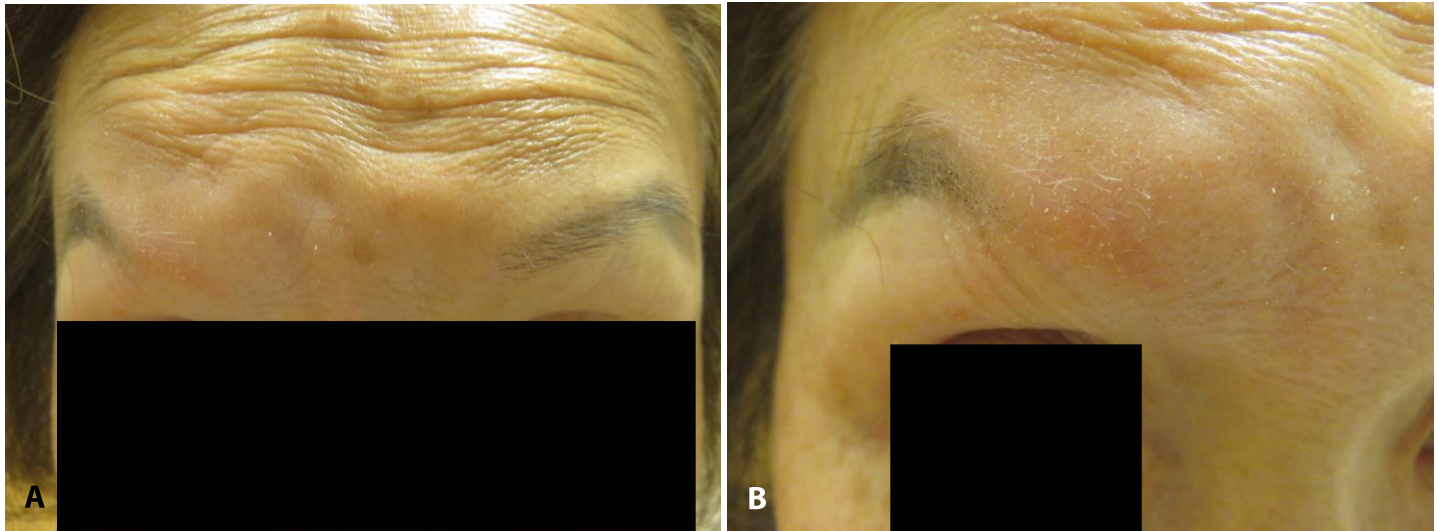


Figure 1. A) Skin-colored-to-mildly-erythematous plaque involving the right medial eyebrow and right mid forehead with induration, hypopigmented hairs, and **B)** decreased hair density involving the medial aspect of the right eyebrow and extending to the mid-eyebrow down the mid-pupillary line.

perifollicular infiltrate of lymphocytes. Lymphocytes extended into follicular epithelium and the overlying epidermis where there was increased epithelial mucin as highlighted by a colloidal-iron stain. Many lymphocytes within the follicular epithelium and

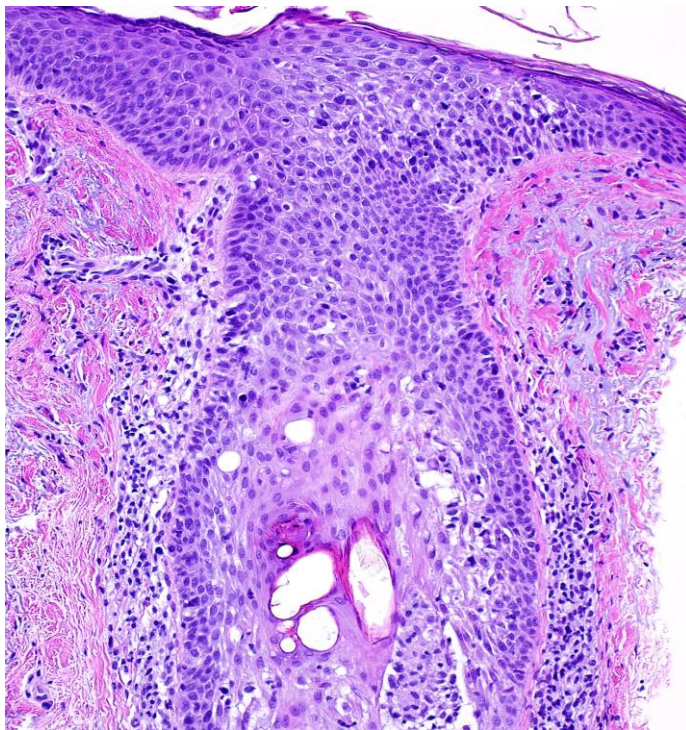


Figure 2: Perivascular and perifollicular infiltrate of lymphocytes with lymphocytes extending into follicular epithelium and the overlying epidermis. Many lymphocytes within the follicular epithelium and epidermis have enlarged hyperchromatic nuclei with irregular nuclear contours. H&E, 20x.

epidermis exhibited enlarged hyperchromatic nuclei with irregular nuclear contours (**Figure 2**). Immunoperoxidase studies revealed the lymphocytes to react for CD3 with co-expression of CD5 and no significantly decreased expression of CD7. The ratio of CD4+:CD8+ lymphocytes was >2:1. Only rare lymphocytes reacted for CD20. Many of the enlarged lymphocytes within the follicular epithelium and overlying epidermis reacted for CD30. A PAS-D stain failed to reveal a thickened basement membrane or evidence of fungi.

Case Discussion

Folliculotropic mycosis fungoides (FMF) is a subtype of mycosis fungoides (MF). It is categorized as a separate clinical variant by the World Health Organization – European Organization for Research and Treatment of Cancer owing to its distinctive clinical and histopathologic features [1-3]. FMF has a high male-to-female ratio. An older age of onset is seen in women than men, with rare cases reported in children [4-6].

The clinical features of FMF can be quite variable but tend to occur at cutaneous sites with rich pilosebaceous units. The classical presentations are hairless, indurated, scaly, erythematous patches, plaques, or tumors that preferentially involve the head and neck with eyebrow involvement [2, 3]. Other presentations include grouped follicular

papules, alopecia, and cystic lesions, with some of these lesions bearing the resemblance of an acneiform eruption, lichen spinulosus, milia en plaque, and keratosis pilaris [2, 7-11]. Frequently, there is pruritus and secondary bacterial infections with crust formation and impetiginization [4, 7, 10, 12]. Generalized erythroderma, which can be seen in classic MF, is rarely observed in FMF. Mucinorrhoea, which is manifested by the expression of a clear, gelatinous substance through follicular orifices upon palpation of an indurated lesion, is rare but highly characteristic. Head and neck involvement is characteristic of advanced stage FMF, whereas early-stage lesions involve mainly the trunk and limbs [2]. The clinical differential diagnosis for FMF includes acneiform lesions (adult-onset comedocystic acne, acne conglobata, papulopustular or granulomatous rosacea, folliculitis, chloracne), alopecia (alopecia areata, trichotillomania, cicatricial alopecia), keratosis pilaris, lichen spinulosus, idiopathic follicular mucinosis, and leprosy [4].

Histologically, FMF demonstrates the presence of a folliculotropic instead of epidermotropic neoplastic infiltrate with or without follicular mucinosis [7-9, 12]. The five pathologic patterns, which may be concomitant or exist in isolation, include mucinous deposits in the follicular unit, granulomatous reaction with destruction of follicular epithelium, eosinophilic folliculitis-like presentation, cystic and comedonal changes, and basaloid folliculolymphoid hyperplasia with folliculotropism [4, 12, 13]. The immunophenotype of FMF tend to be similar to classic MF with atypical lymphocytes that are CD3+, CD4+, and CD7- [13, 14]. T cell receptor gene rearrangement clonality is frequently detectable.

The etiology and mechanism that attract the neoplastic T cells to follicular units are not completely understood. It is postulated that the FMF T cells are a distinctive T cell subset with the ability to localize to the follicular units [4, 15]. Alternative explanations posit a localized, chronic, antigenic stimulation induced by the high density of CD1a+ antigen-presenting cells at the follicular unit [12, 13].

The FMF variant of MF is typically considered a worse prognostic factor and serves as an independent risk factor for disease progression and lower survival [5, 12, 13]. Existing survival data for FMF patients were similar to patients with tumor-stage MF and

significantly worse than those with classic, plaque-stage MF [5, 12, 13], although these data have been challenged [2, 16-18]. One study showed that FMF has two distinct patterns and different prognostic implications depending on whether the disease is early stage (patches, plaques, acneiform lesions on trunk and extremities) or tumor-stage/advanced-stage (plaques and tumors on head and neck with heavier perifollicular infiltrates), with estimated patients' five-year survival rate of 94 percent and 69 percent, respectively [2].

Laboratory and imaging workup should be considered in patients with FMF in addition to a complete medical history and physical exam. Laboratory tests may include complete blood count, complete metabolic panel, lactate dehydrogenase, and flow cytometry. If there is palpable lymphadenopathy, biopsy should be undertaken to determine whether the lymphadenopathy is benign or malignant. Radiological imaging may be performed to evaluate the extent of the lymphoma and includes computerized tomography and positron emission tomography-computerized tomography.

Patients with FMF are less responsive to several first-line skin-directed therapies, such as narrow-band ultraviolet B, topical nitrogen mustard, and topical corticosteroids, which are used in classic MF. Poor response may relate to the depth of the malignant infiltrate [7-9, 12, 17, 19]. Systemic therapies usually are required to induce remission as monotherapy or combination therapy. They include psoralen with ultraviolet A, acitretin, bexarotene, total skin electron beam radiation, romidepsin, and interferon [4, 7, 17, 20, 21]. Patients with more advanced disease may require more aggressive therapies including irradiation, allogeneic stem cell transplantation, and conventional chemotherapies such as gemcitabine, liposomal doxorubicin, cyclophosphamide, doxorubicin, vincristine, and prednisone.

Conclusion

In conclusion, we report a case of folliculotropic mycosis fungoides. It is important for dermatologists and other clinicians to understand its distinct clinical presentation and disease course than traditional mycosis fungoides.

References

1. Willemze R, et al. WHO-EORTC classification for cutaneous lymphomas. *Blood* 2005; 105:3768. [PMID: 15692063].
2. Hodak E, et al. New insights into folliculotropic mycosis fungoides (FMF): A single-center experience. *J Am Acad Dermatol* 2016; 75:347. [PMID: 27245278].
3. Jawed SI, et al. Primary cutaneous T-cell lymphoma (mycosis fungoides and Sezary syndrome): part I. Diagnosis: clinical and histopathologic features and new molecular and biologic markers. *J Am Acad Dermatol* 2014; 70:205 e1. [PMID: 24438969].
4. Martinez-Escala ME, et al. Mycosis Fungoides Variants. *Surg Pathol Clin* 2014; 7:169. [PMID: 26837197].
5. Lehman JS, et al. Folliculotropic mycosis fungoides: single-center study and systematic review. *Arch Dermatol* 2010; 146:607. [PMID: 20566923].
6. Alikhan A, et al. Pediatric follicular mucinosis: presentation, histopathology, molecular genetics, treatment, and outcomes over an 11-year period at the Mayo Clinic. *Pediatr Dermatol* 2013; 30:192. [PMID: 23278316].
7. van Santen S, et al. Clinical Staging and Prognostic Factors in Folliculotropic Mycosis Fungoides. *JAMA Dermatol* 2016; 152:992. [PMID: 27276223].
8. Marschalko M, et al. Folliculotropic mycosis fungoides: clinicopathological analysis of 17 patients. *J Eur Acad Dermatol Venereol* 2015; 29:964. [PMID: 25406034].
9. Demirkesen C, et al. The clinical features and histopathologic patterns of folliculotropic mycosis fungoides in a series of 38 cases. *J Cutan Pathol* 2015; 42:22. [PMID: 25376535].
10. Deonizio JM, et al. Folliculotropic mycosis fungoides: clinical and epidemiological evaluation in a single center in Brazil. *Int J Dermatol* 2016; 55:e256. [PMID: 26711732].
11. Iorizzo M, et al. Folliculotropic mycosis fungoides masquerading as alopecia areata. *J Am Acad Dermatol* 2010; 63:e50. [PMID: 20633789].
12. Gerami P, et al. Folliculotropic mycosis fungoides: an aggressive variant of cutaneous T-cell lymphoma. *Arch Dermatol* 2008; 144:738. [PMID: 18559762].
13. van Doorn R, et al. Follicular mycosis fungoides, a distinct disease entity with or without associated follicular mucinosis: a clinicopathologic and follow-up study of 51 patients. *Arch Dermatol* 2002; 138:191. [PMID: 11843638].
14. Gerami P, et al. The spectrum of histopathologic and immunohistochemical findings in folliculotropic mycosis fungoides. *Am J Surg Pathol* 2007; 31:1430. [PMID: 17721200].
15. Shin J, et al. Lesional gene expression profiling in cutaneous T-cell lymphoma reveals natural clusters associated with disease outcome. *Blood* 2007; 110:3015. [PMID: 17638852].
16. Hodak E, et al. Juvenile mycosis fungoides: cutaneous T-cell lymphoma with frequent follicular involvement. *J Am Acad Dermatol* 2014; 70:993. [PMID: 24629999].
17. Muniesa C, et al. Folliculotropic mycosis fungoides: clinicopathological features and outcome in a series of 20 cases. *J Am Acad Dermatol* 2010; 62:418. [PMID: 20079954].
18. Mantaka P, et al. Clinical and histopathological features of folliculotropic mycosis fungoides: a Norwegian patient series. *Acta Derm Venereol* 2013; 93:325. [PMID: 23053197].
19. Monopoli A, et al. Purely follicular mycosis fungoides without mucinosis: report of two cases with review of the literature. *J Am Acad Dermatol* 2003; 48:448. [PMID: 12637929].
20. Foss F, et al. Clinical Efficacy of Romidepsin in Tumor Stage and Folliculotropic Mycosis Fungoides. *Clin Lymphoma Myeloma Leuk* 2016; 16:637. [PMID: 27637428].
21. Jawed SI, et al. Primary cutaneous T-cell lymphoma (mycosis fungoides and Sezary syndrome): part II. Prognosis, management, and future directions. *J Am Acad Dermatol* 2014; 70:223 e1. [PMID: 24438970].