

UC Davis

Dermatology Online Journal

Title

Two small yellowish papules in a 1 year-old boy: cutaneous leishmaniasis

Permalink

<https://escholarship.org/uc/item/6357d3zm>

Journal

Dermatology Online Journal, 22(3)

Authors

Noguera-Morel, Lucero
Azorin, Daniel
Xirotagaros, Georgios

Publication Date

2016

DOI

10.5070/D3223030373

Copyright Information

Copyright 2016 by the author(s). This work is made available under the terms of a Creative Commons Attribution-NonCommercial-NoDerivatives License, available at <https://creativecommons.org/licenses/by-nc-nd/4.0/>

Peer reviewed

Case presentation

Two small yellowish papules in a 1 year-old boy: cutaneous leishmaniasis

Lucero Noguera-Morel MD¹, Daniel Azorín MD², Georgios Xirotagaros MD¹

Dermatology Online Journal 22 (3): 11

¹Dermatology and ²Pathology Departments, Hospital Universitario Infantil Niño Jesús; Madrid, Spain.

Correspondence:

Lucero Noguera-Morel
Attending Physician at the Hospital Universitario Infantil Niño Jesús
Avda. Menéndez Pelayo 65, 28009
Madrid, Spain
luceronoguera@hotmail.com

Abstract

Cutaneous leishmaniasis (CL) is zoonosis with a spectrum of cutaneous manifestations caused by protozoan parasites of the genus *Leishmania*.

Manifestation varies according to the parasite virulence and the host immune response. Pentavalent antimonials (sodium stibogluconate and meglumine antimoniate) have been used as a first-line therapy for the last 70 years around the world.

We report a case of a 1-year-old boy with two small yellowish papules mimicking juvenile xantogranuloma diagnosed with cutaneous leishmaniasis after a biopsy. Patient underwent treatment with 2 sessions of intralesional (IL) meglumine antimoniate (Glucantime®) with complete clearance of both lesions.

Conclusion: Cutaneous leishmaniasis treatment is difficult to standardize; treatment options in children include wound care and watchful waiting, intralesional pentavalent antimonials, topical paramomycin, or oral miltefosine.

Keywords: *Leishmania*, *L. infantum*, Cutaneous leishmaniasis, antimonial.

Introduction

Cutaneous leishmaniasis (CL) is zoonosis with a spectrum of cutaneous manifestations caused by protozoan parasites of the genus *Leishmania*.

Manifestation of leishmaniasis vary according to parasite virulence and host immune response. Most cases in Spain are caused by *L. infantum*, which is considered endemic on the península [1]. *L. infantum* is also endemic in the middle east, China, and central asia and manifests with atypical clinical features more frequently than other species [2]. Pentavalent antimonials (sodium stibogluconate and meglumine antimoniate) have been used as a first-line therapy for the last 70 years around the world [3].

Case synopsis

A 1-year-old boy, presented with a 3-month history of 2 crusted papules on the lower eyelid and on the right cheek. These were asymptomatic, but showed progressive growth over the 2 months.

Physical examination showed a 7 mm red yellowish papule on the lower right eyelid and smaller similar lesion on the right cheek (Figure1).

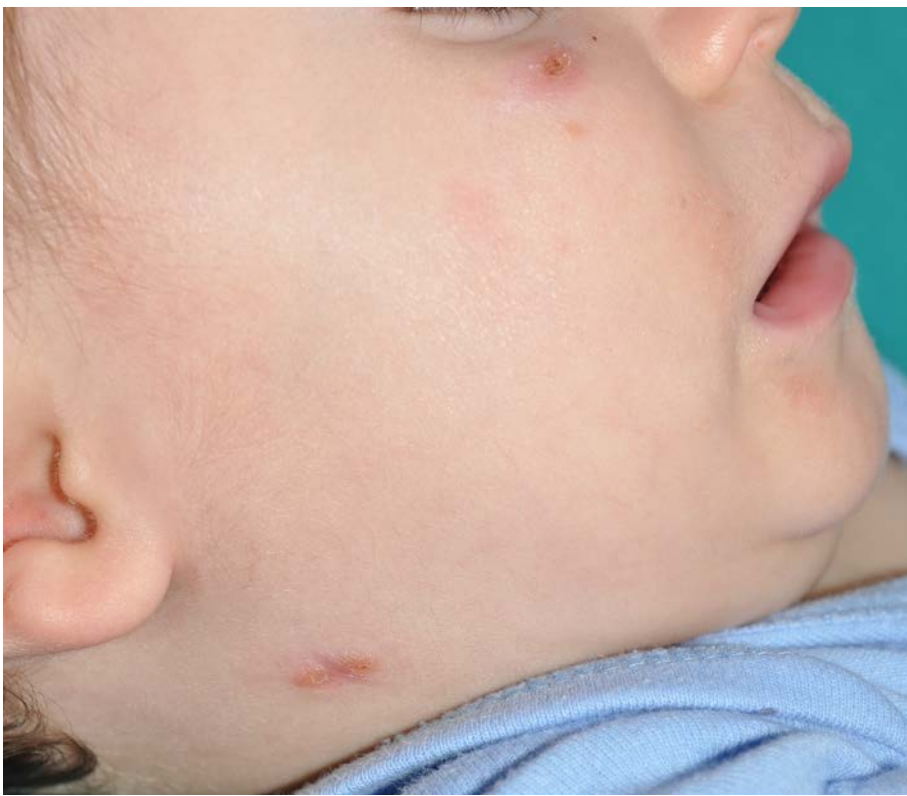

Figure 1. Two small red-yellowish papules on the lower right eyelid and the right submandibular area.

A 4 mm punch biopsy was performed; histologic findings are illustrated in Figures 2 and 3.

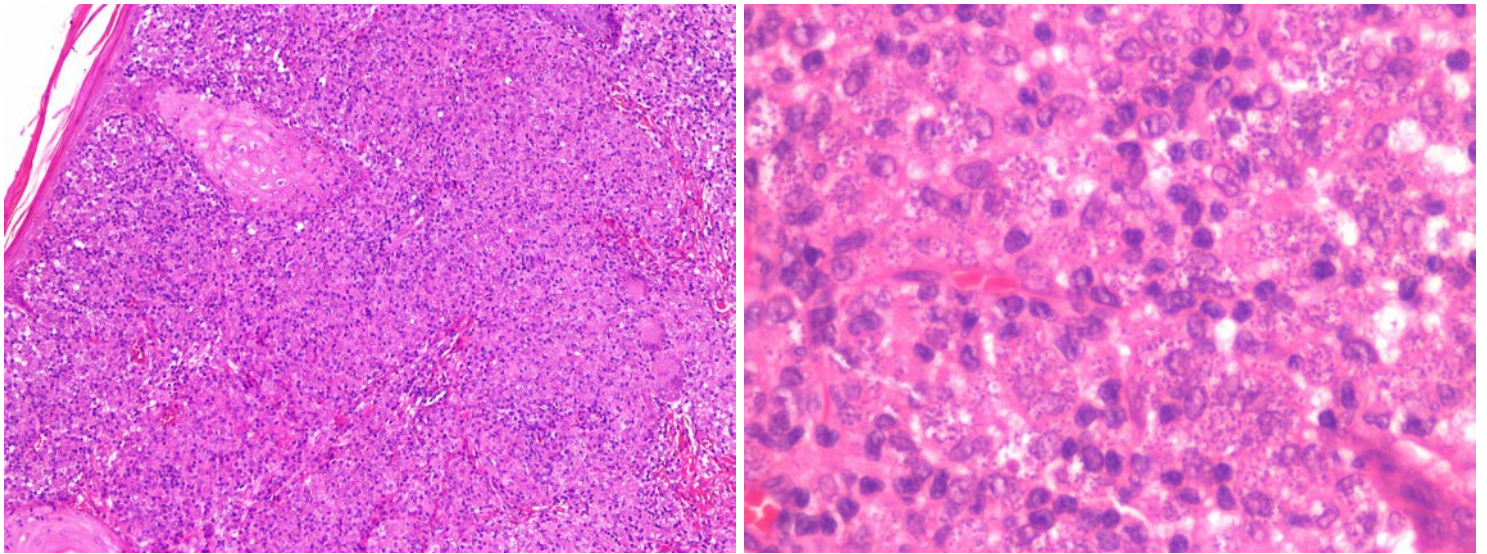


Figure 2. Skin biopsy showing a heavy dermal inflammatory infiltrate composed of lymphocytes, macrophages and several “Touton-like” giant cells. **Figure 3.** Numerous parasites are present in the cytoplasm of macrophages (H&E)

Histological examination showed epidermal hyperkeratosis with focal parakeratosis. In the dermis, there was a heavy inflammatory infiltrate composed of lymphocytes, plasma cells, and many histiocytes, with sparse multinucleated giant cells. Numerous parasites were noted inside the cytoplasm of the histiocytes, which were enhanced with Giemsa stain.

A diagnosis of cutaneous leishmaniasis was rendered.

The patient underwent treatment with 2 sessions of intralesional (IL) meglumine antimoniate (Glucantime®) with complete clearance of both lesions. Glucantime® was used undiluted; 1 ml (300 mg) was injected around the lesion and we repeated the injection at the same dose after one week.

Discussion

In children with cutaneous leishmaniasis the most common site affected is usually the face and the classic clinical picture is a small single papule or plaque that is usually asymptomatic; it may have surface erosion with crusting [4]. The presence of multiple lesions is extremely rare [2].

Because of the pink-yellowish color in our case the differential diagnosis included juvenile xanthogranuloma.

The diagnosis is made by identifying the parasite in the lesion; although a punch biopsy is the gold standard, a thick drop scraping of the base of the papule has a high sensitivity and good microscopic concordance when compared with a biopsy [5].

Polymerase chain reaction (PCR) to confirm the diagnosis can be done using the cytology or biopsy specimen in cases in which the biopsy is non-specific.

It is difficult to standardize treatment for cutaneous leishmaniasis because of many factors such as poor study design and the difficulty to define a “successful treatment” [3,6]. Treatment options include intralesional or intramuscular pentavalent antimonials. The major problem with the injection of antimonials in children is the pain, which is greater when administered intralesionally [3]. Other options that are being used safely in children are summarized in Table 1. It is important to remark that in immunocompetent patients with less than 3 lesions, which are small in size < 30 mm and non-disfiguring, wound care and watchful waiting are safe options because of several studies reporting spontaneous healing after 8-12 weeks [7-9].

Table 1. Current treatment options available for cutaneous leishmaniasis in children. Adapted from references 3,6-9.

Drug	Class	Mechanism of action	Route of administration	Dose/Frequency	Duration	Side effects	Comments
Topical PR_MBCl*	Aminoglycoside	Protein synthesis inhibitor, binds to 16S RNA	Topical	BID	10-20 days	Local inflammation	The association with Methylbenzethonium chloride has higher cure rates than with 10% urea, for unknown mechanism
Local Heat	Physical therapy	Cytokine mediated inflammation	Topical	50°C for 30 seconds	Single session	Local inflammation, Local pain	Requires special device (ie. Thermomed Device)
Photodynamic therapy with aminolevulinic acid	Photosensitizer	Light-induced reaction, cell damaged	Topical	Single application/weekly	8-10 weeks	Local inflammation, Local pain	Apply a thick layer of photosensitizer for 30 min with foil, and then expose the area to sunlight for 2.5 h
IL-AM**	Pentavalent antimony	Not yet completely elucidated	IL	300 mg/ml/weekly	Varies according to response. Up to 24 weeks	Local inflammation, Local pain	OWCL, healing takes up to one month. Large ulcers may take longer. Can be combined with cryotherapy for better cure rates.
IL-Amb	Polyene	Interferes with ergosterol synthesis	IL	2 mg/ml/weekly	12 weeks	Phlebitis, Pain and fibrosis at the injection site.	Second-line therapy for resistant organism.
Pentoxifylline	Xanthine derivative	Not yet completely elucidated	Oral	400 mg/8hs	10-20 days	Gastrointestinal, dizziness, Aseptic meningitis	Adjuvant therapy concomitant with IMAM
IM-AM**	Pentavalent antimony	Not yet completely elucidated	IM	20 mg/kg	10-20 days	Cardiac, hepatic, hematologic and pancreatic toxicities	NWCL, or several lesions or large ulcers in OWCL. Requires weekly labs and ECG.
S-Amb	Polyene	Interferes with ergosterol synthesis	IV	3 mg/kg/d	Days 1-5 and 10.	Renal toxicity, hypokalemia	Requires weekly creatinine and potassium levels
Fluconazole	Triazol	Interferes with ergosterol synthesis	Oral	200 mg/BID	6 weeks	Renal and hepatic toxicity. Prolonged QT (torsades de pointes)	Requires weekly CBC and hepatic enzymes
Miltefosine	Alkylphosphocholine	Protein kinase B (Akt) inhibitor	Oral	2.5-3 mg/kg/TID	28 days	Gastrointestinal, renal failure, hepatotoxicity	Patients not responding to ILAM†. Requires weekly creatinine and hepatic enzymes.

AM: Antimonials, AmB: Liposomal Amphotericin-B, IL: Intralesional, IM: Intramuscular, IV: intravenous, OWCL: Old-world cutaneous leishmaniasis, NWCL: New world cutaneous leishmaniasis, S: Systemic

*15% Paramomycin and 12% Methylbenzethonium chloride,

**Antimonials: sodium stibogluconate (SS) and meglumine antimoniate (MA)

†No reepithelization after 3 months.

Conclusion

Cutaneous leishmaniasis treatment is difficult to standardize. Treatment options in children include wound care and watchful waiting, intralesional pentavalent antimonials, topical paramomycin, or oral miltefosine.

References

1. Giavedoni P, Iranzo P, Fuertes I, Estrach T, Alsina Gibert M. Leishmaniasis cutánea. Experiencia de 20 años en un hospital español de tercer nivel. *Actas Dermosifiliogr.* 2015 May;106(4):310–6. [PMID: 25678133]
2. Paradisi a., Capizzi R, Zampetti a., Proietti I, De Simone C, Feliciani C, et al. Atypical multifocal cutaneous leishmaniasis in an immunocompetent patient treated by liposomal amphotericin B. *J Infect.* 2005;51(5):1–4. [PMID: 15936088]
3. González U, Pinart M, Reveiz L, Alvar J. Cochrane Database of Systematic Reviews. The Cochrane database of systematic reviews. Chichester, UK: John Wiley & Sons, Ltd; 2008. CD005067 p. [PMID: 18843677]
4. Agrawal S, Khandelwal K, Bumb RA, Oghumu S, Salotra P, Satoskar AR. Pediatric cutaneous leishmaniasis in an endemic region in India. *Am J Trop Med Hyg.* 2014 Nov;91(5):901–4. [PMID: 25294618]
5. Saab M, El Hage H, Charafeddine K, Habib RH, Khalifeh I. Diagnosis of cutaneous leishmaniasis: why punch when you can scrape? *Am J Trop Med Hyg.* 2015 Mar;92(3):518–22. [PMID: 25561563]
6. Copeland NK, Aronson NE. Leishmaniasis: treatment updates and clinical practice guidelines review. *Curr Opin Infect Dis.* 2015 Oct;28(5):426–37. [PMID: 26312442]
7. Burden-Teh E, Wootton CI, Williams HC. Can a simple outpatient-based treatment be used to treat cutaneous leishmaniasis in young children? A Critically Appraised Topic. *Br J Dermatol.* 2015 Apr;172(4):861–6. [PMID: 25354137]
8. Vakil NH, Fujinami N, Shah PJ. Pharmacotherapy for leishmaniasis in the United States: focus on miltefosine. *Pharmacotherapy.* 2015 May;35(5):536–45. [PMID: 25940658]
9. Blum J, Buffet P, Visser L, Harms G, Bailey MS, Caumes E, et al. LeishMan recommendations for treatment of cutaneous and mucosal leishmaniasis in travelers, 2014. *J Travel Med.* Jan;21(2):116–29. [PMID: 24745041]