

# UC Davis

## Dermatology Online Journal

### Title

Incisional biopsy critical in obtaining definitive diagnosis in a clinically challenging case

### Permalink

<https://escholarship.org/uc/item/67p594pt>

### Journal

Dermatology Online Journal, 25(4)

### Authors

Fernandez, Joan  
Ren, Vicky  
Cohen, Daniel  
et al.

### Publication Date

2019

### DOI

10.5070/D3254043573

### Copyright Information

Copyright 2019 by the author(s). This work is made available under the terms of a Creative Commons Attribution-NonCommercial-NoDerivatives License, available at <https://creativecommons.org/licenses/by-nc-nd/4.0/>

Peer reviewed

# Incisional biopsy critical in obtaining definitive diagnosis in a clinically challenging case

Joan Fernandez<sup>1</sup> BS, Vicky Ren<sup>2</sup> MD, Daniel Cohen<sup>3</sup> MD PhD, Ikue Shimizu<sup>2,4</sup> MD

Affiliations: <sup>1</sup>Baylor College of Medicine, Houston, Texas, USA, <sup>2</sup>Department of Dermatology, Baylor College of Medicine, Houston, Texas, USA, <sup>3</sup>Department of Pathology and Immunology, Baylor College of Medicine, Houston, Texas, USA, <sup>4</sup>Laboratory and Pathology Services, Michael E. DeBakey Veterans Affairs Medical Center, Houston, Texas, USA

Corresponding Author: Ikue Shimizu, Department of Dermatology, Baylor College of Medicine, 1977 Butler Boulevard, Suite E6.200, Houston, Texas 77030, Tel: 512-913-7163, Fax: 713-798-3252, Email: [ikue.shimizu@bcm.edu](mailto:ikue.shimizu@bcm.edu)

## Abstract

Tissue-sparing biopsy techniques are frequently used in clinical practice but can result in misdiagnosis of large, clinically challenging lesions. We present a case of a 70-year-old man with hidradenocarcinoma of the left chin, a diagnosis that was delayed owing to repeated superficial biopsies that were negative for disease. Diagnosis was ultimately obtained via an incisional biopsy. We discuss the clinical features of hidradenocarcinoma and why this diagnosis can be easily missed with superficial biopsies. It is important that dermatologists consider incisional biopsies in the workup of clinically challenging lesions for which malignancy is considered.

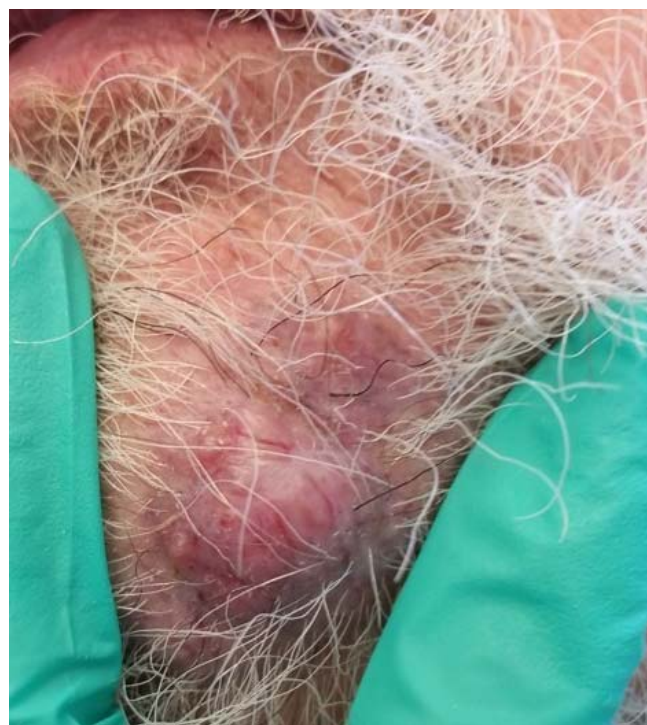Keywords: *incisional biopsy, hidradenocarcinoma*

## Introduction

There are a variety of biopsy techniques that dermatologists utilize. Often, the least invasive technique for adequate diagnosis is chosen to provide patients with the lowest risk for complications. Incisional biopsies, which sample down to the subcutaneous fat, provide pathologists with more tissue for histologic examination. In order to avoid delays in treatment, deeper biopsy techniques should be considered early in the management of clinically challenging cases in which initial superficial biopsy results do not correlate clinically.

## Case Synopsis

A 70-year-old man with type II diabetes, chronic obstructive pulmonary disease, hypertension, history of basal cell carcinoma, and 30-pack/year smoking history presented to the dermatology clinic with an enlarging mass of seven-to-eight years' duration on his left chin. On examination, the patient had a 3.5×3.5cm non-ulcerated, non-eroded,

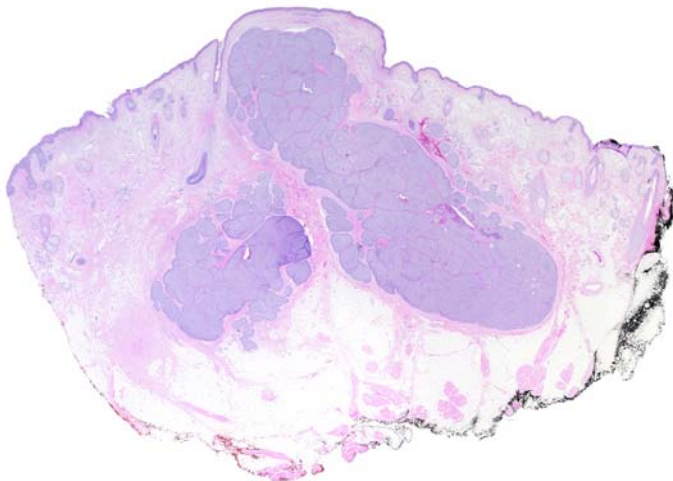


**Figure 1.** A 3.5×3.5cm non-ulcerated, non-eroded, indurated mass on the left chin consisting of two telangiectatic pink-violet nodularities.

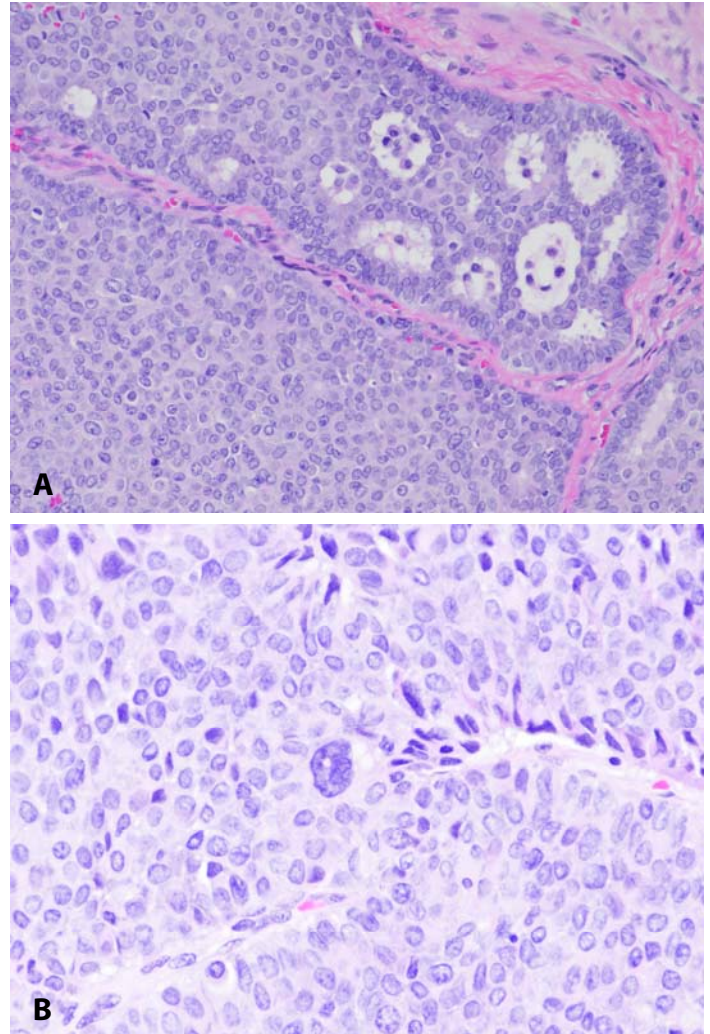
indurated mass on the left chin consisting of two telangiectatic pink-violet nodules (**Figure 1**). Shave biopsy revealed an apocrine hidradenoma with histologic findings concerning for malignancy. The patient returned one week later for repeat biopsy. At that time, a 4mm punch biopsy was performed and was negative for malignancy. However, given clinical concern, the patient was brought back to the clinic for incisional biopsy. Histologic examination of the incisional biopsy showed necrosis and multifocal muscle invasion; immunohistochemical stains were positive for desmin, Ki67, MSA, SMA, and CD31, all of which supported a diagnosis of nodular hidradenocarcinoma with multifocal muscle invasion and lymphovascular space invasion (**Figures 2-5**). The patient was referred to the otolaryngology department and underwent wide local excision and left neck dissection; lymph nodes were negative for tumor. His hidradenocarcinoma was staged as T3N0M0 and he subsequently completed radiation therapy.

### Case Discussion

Histopathologic examination of tissue biopsy specimens aids dermatologists in clinical diagnosis. There are a variety of biopsy techniques, each of which are better suited for particular types of lesions or for diagnostic versus therapeutic intervention. Shave biopsies are indicated when sampling epidermal or dermal lesions or elevated lesions [1].



**Figure 2.** A nodular dermal based tumor is present in the chin skin. H&E, 2× composite.



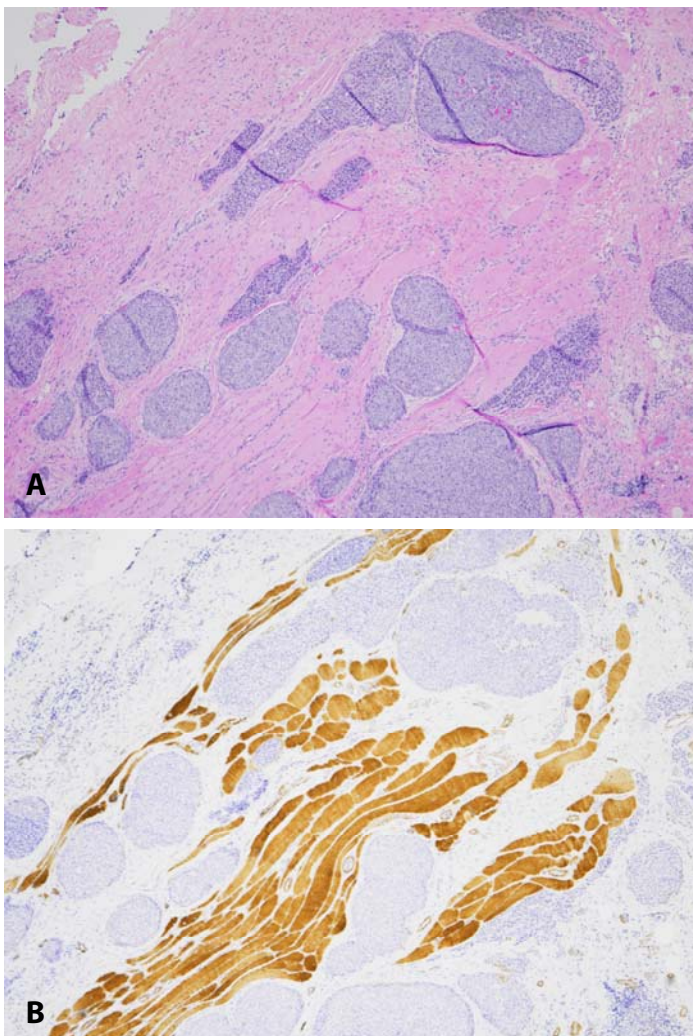
**Figure 3.** A gland-forming tumor with a fibrous capsule **A**), (H&E, 20×), with rare markedly atypical cells with nucleomegaly and irregular nuclear contours **B**), (H&E, 40×).

As opposed to shave biopsies, incisional biopsies sample down to the subcutaneous fat and are therefore better able to determine depth. This type of biopsy differs from an excisional biopsy, which goes to a similar depth but removes the specimen in its entirety [1]. Incisional biopsies preserve the lesion's lateral borders and are used for diagnostic purposes, whereas excisional biopsies serve a therapeutic purpose [1].

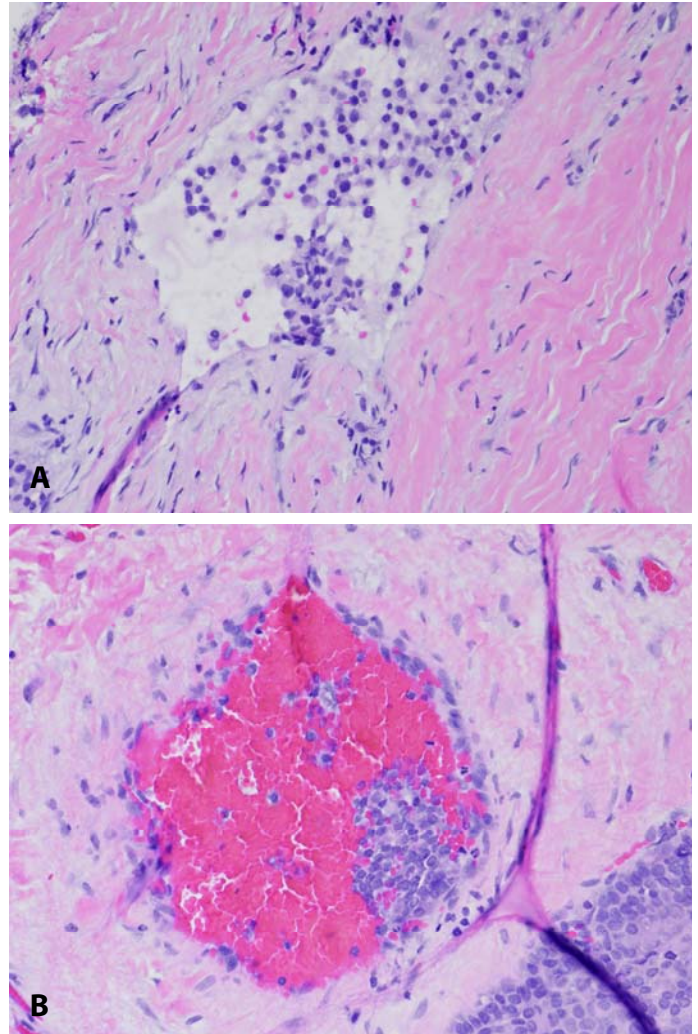
Hidradenocarcinomas are a rare form of eccrine gland tumor that tend to have an aggressive pattern [2, 3]. These tumors most commonly arise as nonspecific solitary dermal or subcutaneous nodules on the head, neck, or extremities and can be present for many years without change [2]. Owing to the lack of clinically distinguishing features, histopathologic

examination of biopsy specimens along with immunohistochemical staining is required for diagnosis. Findings on histology that support the diagnosis of hidradenocarcinomas include sheets of cells with glycogen-containing pale cytoplasm and distinct cell membranes, intracytoplasmic tubular vacuoles secondary to tumor necrosis, cellular pleomorphism, and brisk mitotic activity [2, 3]. Immunohistochemical staining will show strong positivity for Ki67, p53 and high molecular weight keratins [2, 3]. The risk for tumor invasion of underlying structures mandates a deep biopsy to determine tumor depth and stage.

Partial or superficial biopsies of hidradenocarcinomas frequently lead to misdiagnosis [4]. Mitamura et al. and Chang and



**Figure 4.** Muscle invasion by tumor. **A)** H&E, and **B)** muscle-specific actin immunohistochemical study. Both 10 $\times$ .



**Figure 5.** Lymphovascular space invasion by tumor cells in the deep dermis; lymphatic space **A)**, and medium sized vessel **B)**. Both H&E, 20 $\times$ .

hidradenocarcinomas were inaccurately diagnosed as pyogenic granulomas despite multiple superficial biopsies. The superficial biopsies in these cases only captured the exophytic granulation tissue overlying the tumor. In cases such as these, incisional biopsies are necessary to capture as much of the tumor base as possible. Specimens obtained using this biopsy technique are more likely to contain the malignant cells underlying potential exophytic tissue that can result from the tumor's secretion of various growth factors [4, 5]. In any case for which clinical suspicion is high for malignancy, and repeat superficial biopsies do not correlate with the clinical presentation, an incisional biopsy should be performed for complete analysis of the depth and histologic characteristics of the lesion.

## Conclusion

Our case serves as an important reminder for dermatologists to consider incisional over superficial biopsies early in the workup of lesions for which there is a clinical suspicion for malignancy, so as to

avoid a delay in diagnosis and appropriate treatment.

## Potential conflicts of interest

The authors declare no conflicts of interests.

## References

1. Soh J, Riemer C, Alkousakis T, Fathi R. Biopsy and Suture Methodology. *Physician Assist Clin* 2016; 1(2): 277-289. [DOI: 10.1016/j.cpha.2015.12.005].
2. Jinnah AH, Emory CL, Mai NH, Bergman S, Salih ZT. Hidradenocarcinoma presenting as soft tissue mass: Case report with cytomorphologic description, histologic correlation, and differential diagnosis. *Diagn Cytopathol* 2016; 44(5): 438-441. [PMID: 26876052].
3. Souvatzidis P, Sbano P, Mandato F, Fimiani M, Castelli A. Malignant nodular hidradenoma of the skin: report of seven cases. *J Eur Acad Dermatol Venereol* 2008; 22(5): 549-554. [PMID: 18410617].
4. Mitamura Y, Nakahara T, Furue M. Clear Cell Hidradenocarcinoma Mimicking Pyogenic Granuloma after Repeated Surgical Excision. *Dermatol Surg* 2014; 40(2): 211-212. [PMID: 24490986].
5. Chang CH, Chang KP, Huang SH, et al. Hidradenocarcinoma of the fingertip: a case report and literature review. *Dermatol Surg* 2011;37: 704–8. [PMID: 21489038].