

UC Davis

Dermatology Online Journal

Title

When a travel bug gets you down[SS1]: severe, hypotensive African tick bite fever and response to therapy

Permalink

<https://escholarship.org/uc/item/693825g7>

Journal

Dermatology Online Journal, 29(6)

Authors

Saxena, Sarthak Singh

Zeidan, Sofia

Meyer, Summer

et al.

Publication Date

2023

DOI

10.5070/D329662991

Copyright Information

Copyright 2023 by the author(s). This work is made available under the terms of a Creative Commons Attribution-NonCommercial-NoDerivatives License, available at

<https://creativecommons.org/licenses/by-nc-nd/4.0/>

Peer reviewed

When a travel bug gets you down: severe, hypotensive African tick bite fever and response to therapy

Sarthak Singh Saxena BS, Sofia Zeidan BS, Summer Meyer BS, Maxwell A Fung MD, Danielle M Tartar MD PhD

Affiliations: Department of Dermatology, University of California Davis Health, Sacramento, California, USA

Corresponding Author: Danielle M Tartar MD PhD, Department of Dermatology, University of California Davis Health, 3301 C Street, Sacramento, CA 95819, Email: DTartar@ucdavis.edu

Abstract

African tick bite fever, resulting from *Rickettsia africae* inoculation, is endemic in sub-Saharan Africa. We present a United States traveler with African tick bite fever 5 days after she returned from a mission trip to Zimbabwe. The patient exhibited symptomatic hypotension in addition to more typical findings, including fever, fatigue, and a necrotic eschar. The diagnosis was supported by histopathological findings and the patient's symptoms rapidly resolved with oral doxycycline therapy. We believe this case represents the first African tick bite fever diagnosis associated with symptomatic hypotension. This case additionally serves as a reminder of the importance of evaluating patient travel history.

Keywords: African tick bite fever, dermatology, international, *Rickettsia africae*

Introduction

African tick bite fever is an acute illness caused by the obligate intracellular bacterium *Rickettsia africae* (*R. africae*) of the *Amblyomma* genus. It is among the most prevalent rickettsial infections in international travelers returning from sub-Saharan Africa. As an obligate intracellular bacterium, *R. africae* induces localized necrotizing vasculitis with surrounding inflammation by attaching to endothelial cells [1]. Clinical manifestations typically appear two weeks after inoculation via tick bite and include local eschar at the inoculation site in addition to fever, regional lymphadenopathy, lymphangitis, rash, headache, and myalgia [2]. African tick bite fever typically

resolves with antibiotic monotherapy and no fatalities have been reported to date.

Herein, we present a patient with *R. africae* infection exhibiting symptomatic hypotension, a symptom that has not been reported to date, in addition to more typical clinical manifestations. We also provide a review of the relevant literature.

Case Synopsis

A 39-year-old woman presented with a painful lesion on her right thigh 5 days after returning from a mission trip to Zimbabwe. She additionally was experiencing fever, headaches, myalgia, chills, and extreme fatigue. The patient reported sleeping an additional 8 hours daily, in addition to her usual sleep schedule. Although she denied being aware of any tick bites during her travels, she confirmed observing multiple ticks on her body throughout the trip. Over-the-counter acetaminophen provided no relief and the patient reported no other prior treatments.

Physical examination was significant for a 5mm necrotic eschar with surrounding indurated erythema on her right upper medial thigh (**Figure 1**); no additional rash was present. Right inguinal lymphadenopathy was palpable. Vital signs showed hypotension at 80/53mm Hg, a mild fever at 99.6°F (101.8°F at-home per patient), and stable oxygen saturation levels at 95%. Two punch biopsies of the eschar site were performed: one for tissue culture and another for histopathological analysis. A blood analysis for parasitic infections was performed to

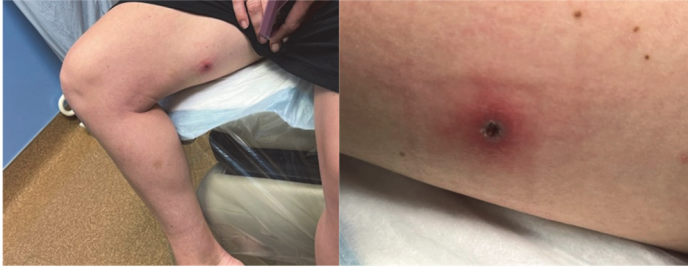

Figure 1. Painful, erythematous nodule with central necrotic eschar on right medial thigh.

further rule out African trypanosomiasis given the patient's extreme fatigue and travel history.

The patient was immediately started on doxycycline 100mg twice daily and sent to the emergency room for further management given her hypotension. Subsequent infectious disease consultation recommended serology for Rocky Mountain spotted fever, as African tick bite fever may cause a false positive IgM due to cross-reactivity with *R. Africae*.

Blood culture and serology for African trypanosomiasis and Rocky Mountain spotted fever were negative, so African trypanosomiasis was deemed less likely. Negative Rocky Mountain spotted fever serology does not exclude African tick bite fever. Tissue culture was negative for bacterial, fungal, and mycobacterial elements. Histopathology revealed perivascular and periadnexal dermatitis with predominantly lymphocytic vasculitis accompanied by neutrophils and eosinophils, compatible with a rickettsial infection (**Figure 2**). Histological gram, Fite, and viral staining were

negative for herpes simplex virus, cytomegalovirus, and Epstein-Barr virus, respectively.

A clinical diagnosis of African tick bite fever was made. The patient rapidly improved on oral doxycycline therapy, recovered without any complications, and was discharged with no long-term recurrence. To the best of our knowledge, this case report is the first to document an association between hypotension and African tick bite fever.

Case Discussion

About 92.6% of African tick bite fever cases occur after travel to sub-Saharan Africa, and travel to this region is a crucial risk factor for the occurrence of African tick bite fever in non-African travelers [2]. Prior studies indicate that 83% of reported cases involve individuals aged between 18-64 years, 15% were 65 or older, and 2% were between 0-17 years [2]. As the primary tick-borne rickettsiosis and second most common cause of acute febrile illness after malaria in travelers returning from sub-Saharan Africa [3,4], African tick bite fever must be considered in the differential diagnosis for travelers returning from endemic areas.

Rickettsia africae infection induces Th1-type immune responses including the cytokines interferon gamma and interleukin 12 during the acute febrile phase [5], which may lead to some of the common constitutional symptoms. Common features of *R. africae* infection include inoculation eschars, fever,

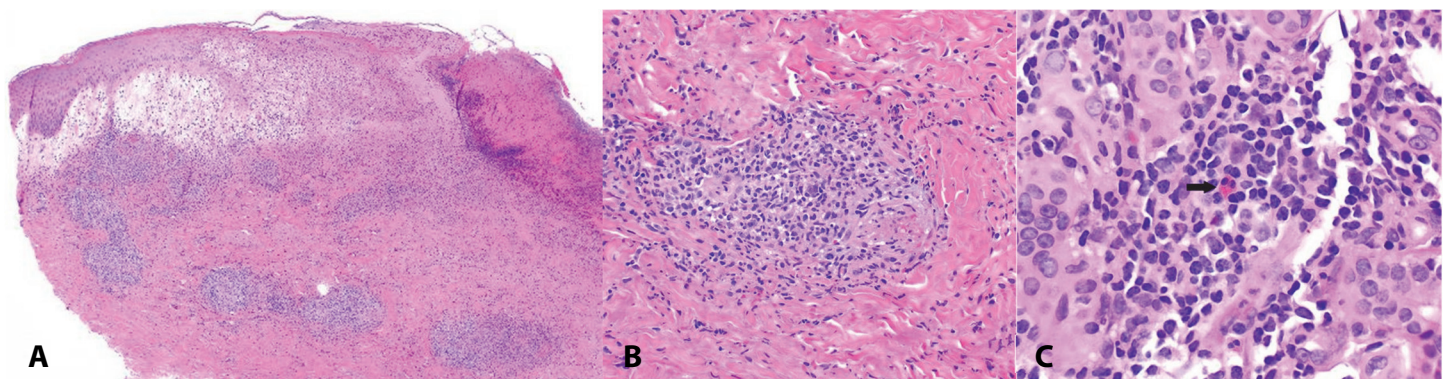


Figure 2. H&E histopathology. **A)** Low power view of tick bite eschar demonstrates an ulcer with epidermal necrosis, marked papillary dermal edema, and a dense superficial and deep perivascular and periadnexal lymphocytic infiltrate with neutrophils and eosinophils, 40x. **B)** High power view of tick bite eschar showing fibrinoid necrosis of the wall of a small vessel in the dermis surrounded by a lymphocytic infiltrate with leukocytoclasia (nuclear "dust") and extravasated erythrocytes, 200x. **C)** High power view of tick bite eschar showing sparse eosinophils (depicted by arrow) located in the deep dermis, 400x.

lymphadenopathy, rash, headache, and myalgia [1-3,6]. Atypical presentations including myocarditis, pericarditis, conjunctivitis, uveitis have been reported [6]. Our case report presents the first documented instance of hypotension associated with African tick bite fever. Variations in clinical manifestations of African tick bite fever patients (Table 1) highlight the need to recognize unique presentations to identify knowledge gaps and enhance diagnostics.

R. africae has been detected in ticks from *Amblyomma*, *Hyalomma*, and *Rhipicephalus*, though *Amblyomma variegatum* is the primary vector in sub-Saharan Africa whereas *Amblyomma hebraeum* is the primary vector in southern Africa [6,7].

Histopathological analysis can help differentiate African tick bite fever from other infectious diseases with similar clinical presentations, such as African trypanosomiasis or other tick-borne infections. *R. africae* is characterized by epidermal and superficial necrosis, lymphocytic vasculitis, and vascular thrombosis accompanied by granulocytes within the inflammatory infiltrate [1]. Our histopathological findings were consistent with a rickettsial infection, leading to the diagnosis of African tick bite fever.

Serology studies can be performed to further identify the *Rickettsia rickettsii* (the causative agent in Rock Mountain spotted fever), which may cross-react in

African tick bite fever, though this was negative in our patient.

Polymerase chain reaction can be performed as an alternative diagnostic method. Polymerase chain reaction can identify known *R. africae* genes such as *gltA*, *ompA*, and *ompB* in eschar biopsy or swab samples [1,6-8]. As these tests become more widely commercially available, this may allow for more targeted detection of African tick bite fever in returning travelers.

Conclusion

This case report highlights the importance of recognizing unique presentations to further characterize clinical manifestations of tick-borne bacterial infections. It serves as a reminder that clinicians must obtain a detailed travel history and consider diseases endemic to the region the patient visited. These details are crucial in making challenging diagnoses and evaluating treatment options. Although our patient exhibited a severe reaction, including a novel association of hypotension, she made a swift recovery with oral doxycycline due to the accurate clinical diagnosis of African tick bite fever.

Potential conflicts of interest

The authors declare no conflicts of interest.

References

1. Frean J, Grayson W. South African Tick Bite Fever: An Overview. *Dermatopathology (Basel)*. 2019;6:70-6. [PMID: 31700846].
2. Silva-Ramos CR, Faccini-Martinez AA. Clinical, epidemiological, and laboratory features of *Rickettsia africae* infection, African tick-bite fever: A systematic review. *Infez Med*. 2021;29:366-77. [PMID: 35146341].
3. Eldin C, Parola P. Update on Tick-Borne Bacterial Diseases in Travelers. *Curr Infect Dis Rep*. 2018;20:17. [PMID: 29789953].
4. Ledger KJ, Innocent H, Lukhele SM, Dorleans R, Wisely SM. Entomological risk of African tick-bite fever (*Rickettsia africae* infection) in Eswatini. *PLoS Negl Trop Dis*. 2022;16:e0010437. [PMID: 35576190].
5. Rauch J, Jochum J, Eisermann P, et al. Inflammatory cytokine profile and T cell responses in African tick bite fever patients. *Med Microbiol Immunol*. 2022;211:143-52. [PMID: 35543881].
6. Mazhetese E, Magaia V, Taviani E, Neves L, Morar-Leather D. *Rickettsia africae*: identifying gaps in the current knowledge on vector-pathogen-host interactions. *J Infect Dev Ctries*. 2021;15:1039-47. [PMID: 34516408].
7. Pillay A, Manyangadze T, Mukaratirwa S. Prevalence of *Rickettsia africae* in tick vectors collected from mammalian hosts in sub-Saharan Africa: A systematic review and meta-analysis. *Ticks Tick Borne Dis*. 2022;13:101960. [PMID: 35537238].
8. Harrison N, Burgmann H, Forstner C, et al. Molecular diagnosis of African tick bite fever using eschar swabs in a traveller returning from Tanzania. *Wien Klin Wochenschr*. 2016;128:602-5. [PMID: 27488618].
9. Tomasiewicz K, Krzowska-Firyeh J, Bielec D, Socolovschi C, Raoult D. First case of imported African tick-bite fever in Poland - Case report. *Ann Agric Environ Med*. 2015;22:412-3. [PMID: 26403104].
10. Cox JA, Visser LG. A family with African tick bite fever. *Travel Med Infect Dis*. 2015;13:274-5. [PMID: 25886872].
11. Bohaty BR, Hebert AA. Images in clinical medicine: African tick-bite fever after a game-hunting expedition. *N Engl J Med*. 2015;372. [PMID: 25738687].
12. Binder WD, Gupta R. African tick-bite fever in a returning traveler.

- J Emerg Med.* 2015;48:562-5. [PMID: 25795527].
13. Nilsson K, Wallmenius K, Rundlof-Nygren P, Stromdahl S, Pahlson C. African tick bite fever in returning Swedish travellers. Report of two cases and aspects of diagnostics. *Infect Ecol Epidemiol.* 2017;7:1343081. [PMID: 28815000].
 14. Ando N, Kutsuna S, Takaya S, Katanami Y, Ohmagari N. Imported African Tick Bite Fever in Japan: A Literature Review and Report of Three Cases. *Intern Med.* 2022;61:1093-8. [PMID: 35370251].
 15. Hauser N, Arzomand Z, Fournier J, et al. A case of African tick-bite fever in a returning traveler. *IDCases.* 2016;5:78-9. [PMID: 27516971].
 16. Bogovic P, Lotric-Furlan S, Korva M, Avsic-Zupanc T. African Tick-Bite Fever in Traveler Returning to Slovenia from Uganda. *Emerg Infect Dis.* 2016;22(1848-9. [PMID: 27648844].].
 17. Rae N, Nathwani D. African tick bite fever. *J R Coll Physicians Edinb.* 2016;46:100. [PMID: 27929573].
 18. Albizuri Prado F, Sanchez A, Feito M, et al. Fever and Multiple Eschars After an African Safari: Report of Three Cases. *Pediatr Dermatol.* 2017;34:e179-e81. [PMID: 28544092].
 19. Liao E, Carr D. A Tale of Black Eschar in a Returning Traveller. *J Emerg Med.* 2017;53:904-6. [PMID: 28988739].
 20. Menzer C, Fink C, Enk A, Haenssle HA. African tick-bite fever - a tantalizing souvenir from South Africa. *J Dtsch Dermatol Ges.* 2017;15:1027-8. [PMID: 28872753].
 21. Strand A, Paddock CD, Rinehart AR, et al. African Tick Bite Fever Treated Successfully With Rifampin in a Patient With Doxycycline Intolerance. *Clin Infect Dis.* 2017;65:1582-4. [PMID: 28505276].
 22. Angerami RN, Krawczak FS, Nieri-Bastos FA, et al. First report of African tick-bite fever in a South American traveler. *SAGE Open Med Case Rep.* 2018;6:2050313X18775301. [PMID: 29796268].
 23. Lee W, Seong H, Kim JH, et al. A Case of African Tick-Bite Fever in a Returning Traveler from Southern Africa. *Infect Chemother.* 2022;54:202-7. [PMID: 32757495].
 24. Mack I, Ritz N. African Tick-Bite Fever. *N Engl J Med.* 2019;380:960. [PMID: 30855745].
 25. Fralish MS, Mangalindan KE, Farris CM, et al. African Tick-Bite Fever. *Am J Med.* 2020;133:1051-3. [PMID: 32325042].
 26. Lowery K, Rosen T. Probable African Tick Bite Fever in the United States. *Yale J Biol Med.* 2020;93:49-54. [PMID: 32226336].
 27. Silva-Ramos CR, Bernal-Garcia EA, Gomez MC, et al. First case of *Rickettsia africae* rickettsiosis, African tick-bite fever, in a Colombian traveler. *Travel Med Infect Dis.* 2022;50:102463. [PMID: 36150644].

Table 1. African tick bite fever cases that have been published worldwide from 2015 to 2022.

Year	Country of origin	Sex & age (years)	Country of travel	Clinical presentation (location)	Diagnostic techniques	References
2010	Poland	M (51)	South Africa	Eschar (right nipple), generalized rash, fever, chills	Real-time polymerase chain reaction (PCR) of eschar swab	Tomasiewicz et al. [9]
2015	Netherlands	M (53)	South Africa	Eschar (left upper leg), rash (extremities) fever, pain (shoulders radiating to neck and head)	Travel history & clinical presentation	Cox et al. [10]
		F (51)		Eschar (left upper leg), rash (extremities), inguinal lymphadenopathy		
2015	United States	F (15)	South Africa	Eschar (left popliteal fossa), fever, headache, myalgia, inguinal lymphadenopathy	Histopathology & PCR of eschar punch biopsy	Bohaty et al. [11]
2015	United States	M (63)	India, South Africa	Eschar (left lateral hip), fever, myalgia, chills, night sweats, arthralgias, erythematous papules (neck)	Serum Immunoglobulin (Ig) IgM and IgG immunoassay	Binder et al. [12]
2015	Sweden	M (56)	South Africa	Eschar (thorax), fever	Real-time PCR of eschar swab	Nilsson et al. [13]
		M (41)	Zimbabwe	Fever, malaise, painful swelling (right groin), inguinal lymphadenopathy	Real-time PCR of eschar punch biopsy	
2015	Japan	F (41)	South Africa	Eschar (left dorsal foot), fever, inguinal lymphadenopathy	Serum IgM immunoassay	Ando et al. [14]
2016	United States	M (30)	Kenya	Eschar (anterior left foot), rash, inguinal lymphadenopathy, fever, fatigue, chills, sweats	Histopathology of eschar punch biopsy	Hauser et al. [15]
2016	Austria	F (30)	Tanzania	Eschar (right ankle), fever, chills, headache, myalgia, pain (right lower limb)	Real-time PCR of eschar swab	Harrison et al. [8]
2016	Slovenia	M (29)	Uganda	Eschar (left upper abdomen), fever, axillary lymphadenopathy	PCR and serum immunoassay of eschar swab	Bogovic et al. [16]
2016	United Kingdom	M (54)	South Africa, Zambia	Eschar (back, posterior to right axilla), fever, headache, generalized rash, axillary lymphadenopathy	Travel history & clinical presentation	Rae et al. [17]
2016	Japan	M (45)	South Africa	Eschar (right inner thigh), fever, myalgia, arthralgia, fatigue, inguinal lymphadenopathy	Serum IgM immunoassay	Ando et al. [14]
2017	Spain	M (7)	South Africa	Multiple eschars (back and inguinal folds), fever, headache, myalgia, inguinal and postauricular lymphadenopathy	Serum PCR	Albizuri Prado et al. [18]
		M (8)		Multiple eschars, fever, myalgia, regional lymphadenopathy	Serum IgM immunoassay	
		M (16)				

2017	Canada	M (51)	South Africa	Eschar (left shoulder), fever, headache, myalgia, arthralgia, chills, fatigue	Travel history, clinical presentation, and negative serology for malaria	Liao et al. [19]
2017	Germany	M (73)	South Africa	Multiple eschars (abdomen, arms, and legs), fever, malaise, inguinal lymphadenopathy	Serum IgM immunoassay	Menzer et al. [20]
2017	United States	M (53)	South Africa	Eschar (right popliteal fossa), inguinal and popliteal lymphadenopathy, myalgia, general malaise	Real-time PCR of eschar punch biopsy	Strand et al. [21]
2018	Japan	F (54)	South Africa	Eschar (right inner thigh), fever, rash (trunk), inguinal lymphadenopathy	Serum PCR	Ando et al. [14]
2018	Brazil	M (32)	South Africa	Eschar (right iliac crest region), inguinal lymphadenopathy, rash (trunk and arms), headache, myalgia, asthenia, diarrhea	Serum IgG immunoassay, tissue PCR, rickettsial culture	Angerami et al. [22]
2018	South Korea	M (36)	Eswatini	2 eschars (abdomen, left posterior thigh), inguinal lymphadenopathy, fatigue, myalgia, night sweats, sore throat	Real-time PCR and nested PCR of eschar sample	Lee et al. [23]
2019	Switzerland	M (12)	South Africa, Zambia, Mozambique	Eschar (calf), rash (wrists, legs, trunk), regional lymphadenopathy	Travel history and clinical presentation	Mack et al. [24]
		M (10)		Eschar (postauricular), rash (wrists, legs, trunk), regional lymphadenopathy		
2020	United States	M (41)	South Africa	Eschar (right medial ankle), fevers, headache, malaise, and chills)	Histopathology of eschar punch biopsy, positive RMSF serology, PCR of eschar tissue	Fralish et al. [25]
2020	United States	F (60)	Zimbabwe	Eschar (proximal right shin), inguinal lymphadenopathy, fever, headache, myalgia, rash (torso)	Pan- <i>Rickettsia</i> tissue biopsy PCR; IgG immunoassay	Lowery et al. [26]
2022	Columbia	M (63)	South Africa	3 eschars (right gluteal region, right calf, right dorsal foot), inguinal lymphadenopathy, rash (trunk and extremities), fever, myalgia	Real-time PCR of eschar swab and eschar tissue sample; serum IgG immunoassay	Silva-Ramos et al. [27]

RMSF, rocky mountain spotted fever.