

# UC Davis

## Dermatology Online Journal

### Title

Eccrine chromhidrosis secondary to hyperbilirubinemia

### Permalink

<https://escholarship.org/uc/item/6hz8s1mh>

### Journal

Dermatology Online Journal, 21(3)

### Authors

So, Jessica Kim  
Romero, Laura

### Publication Date

2015

### DOI

10.5070/D3213023603

### Supplemental Material

<https://escholarship.org/uc/item/6hz8s1mh#supplemental>

### Copyright Information

Copyright 2015 by the author(s). This work is made available under the terms of a Creative Commons Attribution-NonCommercial-NoDerivatives License, available at

<https://creativecommons.org/licenses/by-nc-nd/4.0/>

Peer reviewed

**Case presentation**

**Eccrine chromhidrosis secondary to hyperbilirubinemia**

**So JK , Romero L**

**Dermatology Online Journal 21 (3): 12**

**University of California San Diego Health System, Department of Medicine, Division of Dermatology**

**Correspondence:**

Jessica Kim So, MD  
UC San Diego – Dermatology  
8899 University Center Lane, Ste 350  
San Diego, CA 92121  
JSK085@ucsd.edu

---

**Abstract**

**Background:** Eccrine chromhidrosis, or colored eccrine sweating, may be caused by contamination of sweat by dyes, pigmentation from microorganisms, or more rarely, hyperbilirubinemia. Pigment usually affects the palms and soles, where abundant sweat glands are found.

**Purpose, Material and Methods:** We report a unique case of eccrine chromhidrosis in the setting of hyperbilirubinemia and review the current literature available on PubMed of previously reported cases.

**Results:** Six patients with chromhidrosis have been previously reported in the setting of significant hyperbilirubinemia, in association with fever and thickened stratum corneum.

**Conclusions:** Eccrine chromhidrosis secondary to hyperbilirubinemia is very rare, but can be diagnosed on the basis of classic clinical findings, dermoscopic examination, and negative tissue cultures.

**Keywords:** chromhidrosis, hyperbilirubinemia, colored sweating, liver disease

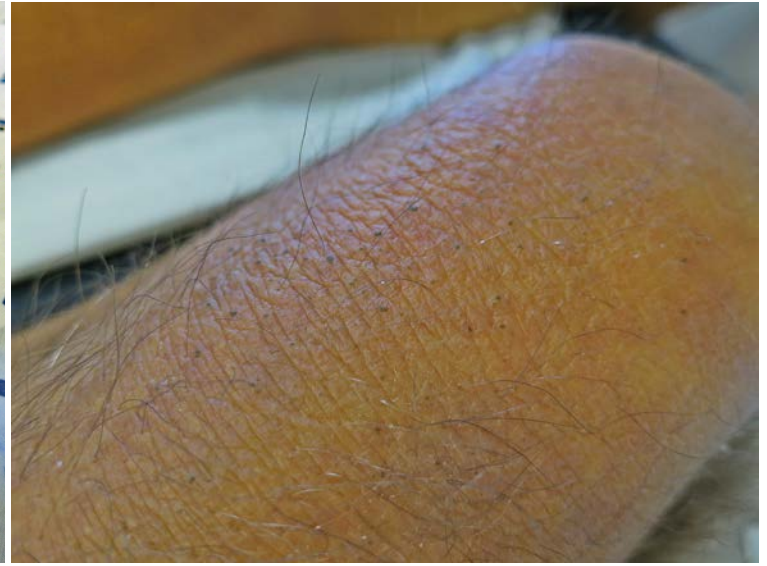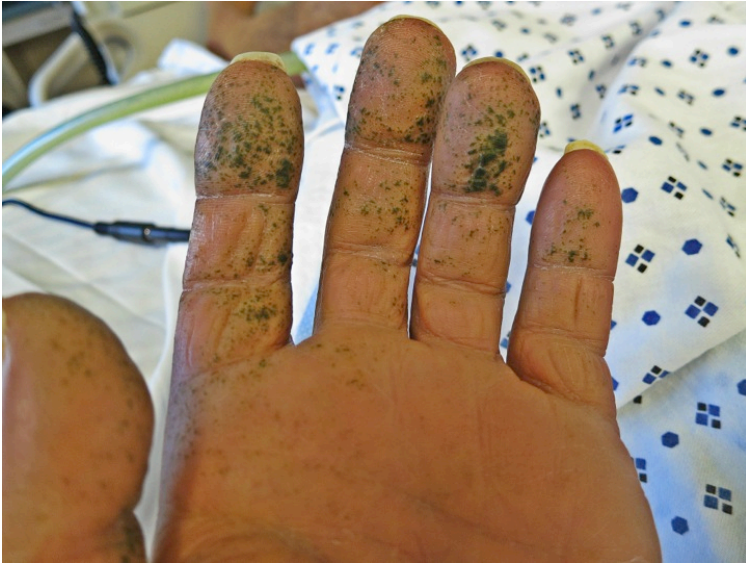**Introduction**

Eccrine chromhidrosis, or colored eccrine sweating, may be caused by contamination of sweat by dyes, pigmentation from microorganisms, or more rarely, from hyperbilirubinemia [1]. Pigment usually affects the palms and soles where abundant sweat glands are found. We report a rare case of eccrine chromhidrosis in the setting of hyperbilirubinemia, and review the previously reported cases in the literature.

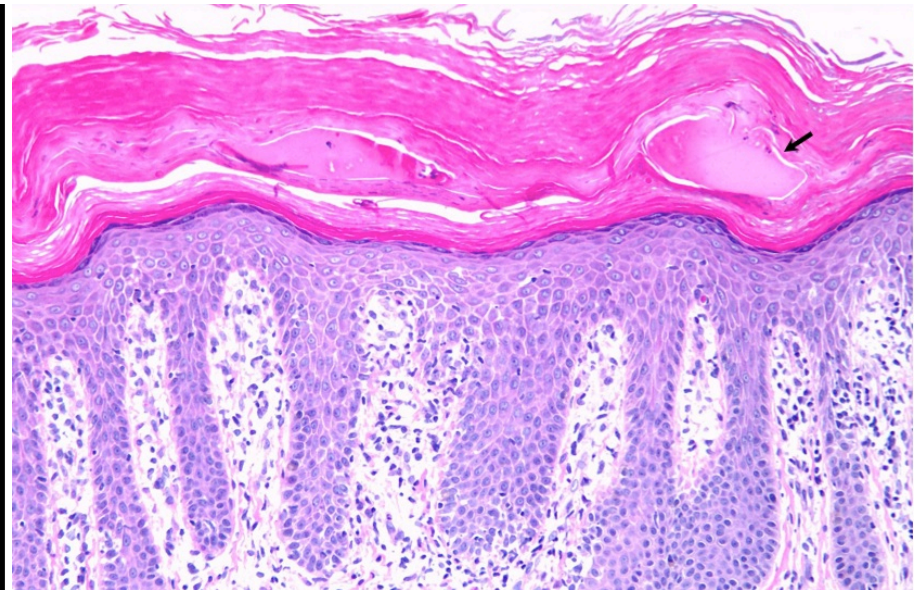
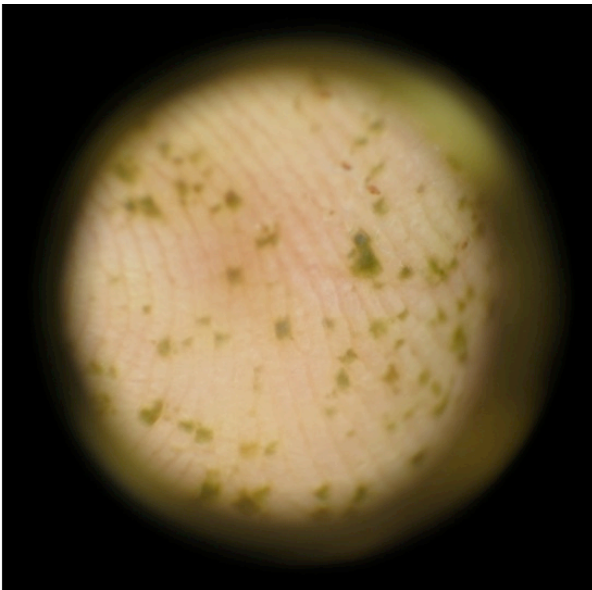
**Case synopsis**

A 61-year-old man with invasive duodenal adenocarcinoma status post pancreaticoduodenectomy and hemicolectomy developed asymptomatic pinpoint dark green macules on his fingertips and anterior thighs (Figures 1 and 2). He had significant hyperbilirubinemia (total 34.7 mg/dL, direct 25.3 mg/dL), as well as fevers (102 F) related to enterococcal bacteremia. Perspiration of the axillae and trunk was colorless. He had no recent contact with colored substances and pigment was not

removable with isopropyl alcohol. Dermoscopy showed green pigment predominantly on the ridges of the skin where eccrine glands open (Figure 3). A lesional skin biopsy revealed hyperkeratosis and amorphous pink material in the stratum corneum consistent with bilirubin (Figure 4). Tissue cultures (bacterial, mycobacterial, fungal), Periodic acid-Schiff, Gram, and Hall stains were negative. A week later, his bilirubin levels were still significantly elevated, but had improved (total 19.9 mg/dL, direct 13.5 mg/dL); the lesions faded and disappeared with sloughing of his skin. Fevers subsided with treatment of bacteremia.



**Figure 1.** Pinpoint dark green macules seen on his fingertips and palms. **Figure 2.** Pinpoint dark green macules seen on his anterior thigh.



**Figure 3.** Dermoscopy showed green pigment predominantly on the ridges of palmar skin. **Figure 4.** Intermediate (20X) magnification view of the lesional skin biopsy showed hyperkeratosis and amorphous pink material in the stratum corneum consistent with bilirubin (arrow).

## Discussion

Of the now seven reported cases of eccrine chromhidrosis in the setting of hyperbilirubinemia, all occurred on the palms and/or soles of men in the setting of severe jaundice, high fevers, and thickened stratum corneum of the affected area (Table 1) [2-6]. Total bilirubin at time of eruption ranged from 12.07 to 34.7 mg/dl (ref range 0.3-1 mg/dl), and direct bilirubin ranged from 7.97 to 25.5 (ref range 0-0.3 mg/dl). All cases spontaneously resolved in one week to two months, usually with sloughing of the skin. In addition, although two cases report positive bilirubin staining on Hall's or Fouchet stain [3,5], in two patients, the stains were negative [4,6], as with our case. This may relate to the fact that the bilirubin stain has not been optimized in skin.

## Conclusion

It is interesting that eccrine chromhidrosis is exceedingly rare, despite the myriad of patients with secondary hyperbilirubinemia. It does appear that high fever and stratum corneum retention are contributing factors. We report this case to highlight the importance

of this condition as a cutaneous sign of liver disease. Eccrine chromhidrosis is self-resolving and can be diagnosed on the basis of classic clinical findings, dermoscopic examination, and negative tissue cultures.

## References

1. Bologna JL, Jorizzo JL, Schaffer JV. *Dermatology*. 3rd edition. (Chapter 39: Diseases of the Eccrine and Apocrine Sweat Glands by JL Miller). Elsevier Saunders (2012).
2. Kanzaki T, Tsuda J. Bile pigment deposition at sweat pores of patients with liver disease. *J Am Acad Dermatol*. 1992 Apr;26(4):655-6. [PMID = 1597560]
3. Allegue F, Hermo JA, Fachal C, Alfonsín N. Localized green pigmentation in a patient with hyperbilirubinemia. *J Am Acad Dermatol*. 1996 Jul;35(1):108-9. [PMID = 8682944]
4. Fung MA, LeBoit PE, Maibach HI. Coalescing green and yellow papules on the feet. *Arch Dermatol*. 2000 Jan;136(1):113, 116. [PMID = 10632213]
5. Di Stefani A, Bianchi L, Orlandi A, Chimenti S. Green sweating spots on hands and feet: unusual expression of hyperbilirubinemia. *Ann Intern Med*. 2006 Nov 7;145(9):710-1. [PMID = 17088594]
6. Triwongwaranat D, Kasemsarn P, Boonchai W. Green pigmentation on the palms and soles. Acral green pigmentation (eccrine chromhidrosis). *JAMA Dermatol*. 2013 Nov;149(11):1339-40. [PMID = 24026431]