

UC Davis

Dermatology Online Journal

Title

Benign symmetric lipomatosis in the tongue: an uncommon case

Permalink

<https://escholarship.org/uc/item/6pt638vz>

Journal

Dermatology Online Journal, 26(1)

Authors

Bastos, Daniela Brito
Figueira, Jéssica Araújo
Furuse, Cristiane
et al.

Publication Date

2020

DOI

10.5070/D3261047192

Copyright Information

Copyright 2020 by the author(s). This work is made available under the terms of a Creative Commons Attribution-NonCommercial-NoDerivatives License, available at <https://creativecommons.org/licenses/by-nc-nd/4.0/>

Peer reviewed

Benign symmetric lipomatosis in the tongue: an uncommon case

Daniela Brito Bastos¹, Jéssica Araújo Figueira¹, Cristiane Furuse², Éder Ricardo Biasoli^{1,2}, Glauco Issamu Miyahara^{1,2}, Daniel Galera Bernabé^{1,2}

Affiliations: ¹Oral Oncology Center, School of Dentistry, São Paulo State University (UNESP), Araçatuba, SP, Brazil, ²Department of Pathology and Clinical Propedeutics, School of Dentistry, São Paulo State University (UNESP), Araçatuba, SP, Brazil

Corresponding Author: Daniel Galera Bernabé, Assistant Professor, Discipline of Oral Medicine and Oral Oncology Center, School of Dentistry, São Paulo State University (UNESP), 1193 José Bonifácio Street, Araçatuba, SP, Brazil, SP 15050-015, Tel: 55-18 36363268/55-18 36363275 Email: danielbernabe@foa.unesp.br

Abstract

Symmetric lipomatosis of the tongue (SLT) is rare and characterized by diffuse growth and unencapsulated lipomas. An 87-year-old man was referred for evaluation of tongue lesions. Intraoral findings showed soft yellowish nodules with a smooth shiny surface diffusely on the lateral border of the tongue, bilaterally. Our clinical diagnosis was multiple tongue lipomas and an incisional biopsy was done. Histopathological examination revealed unencapsulated lobules of mature adipocytes with slight variation in the size and shape, confirming the diagnosis of lipoma. The final diagnosis was SLT. On follow-up at 6 months, the tongue findings were unchanged and no new lesions were observed.

Keywords: benign symmetric lipomatosis, lipoma, lipomatosis, oral lesion, symmetric tongue lipomatosis

Introduction

Lipomas are the most common benign soft tissue mesenchymal tumors composed of mature adipose tissue [1-3]. It may arise in any part of the human body where adipose tissue is present [1-3]. Benign symmetric lipomatosis (BSL) is an uncommon disorder of unknown etiology, characterized by diffuse growth of multiple symmetric and non-encapsulated lipomas [4]. It is commonly found in the posterior neck and upper trunk and oral involvement is extremely rare [4, 5]. The entity is known as “multiple symmetric lipomatosis,”

“Madelung disease,” and “Launois-Bensaude syndrome;” it has a relatively benign natural course to date [4, 5]. Lipomatosis affecting only the oral region is very unusual [6, 7]. Symmetric lipomatosis of the tongue (SLT) was first reported by Desmond in 1944 [8] and only a few cases have been reported in the English literature. Symmetric lipomatosis of the tongue occurs more frequently in middle-aged men [4, 5]. Owing to the lack of a connective tissue capsule and the resulting diffuse growth, in many cases only a reduction in size of the lipomas is possible [5, 9, 10]. The current report describes a rare case of solitary symmetrical lipomatosis in the tongue.

Case Synopsis

An 87-year-old man was referred for evaluation of bilateral tongue lesions. The patient reported the nodules were unpainful and he did not have dysphagia, dysarthria, or sleep apnea. The patient was a heavy drinker and his medical history showed rheumatoid arthritis. Extraoral examination showed no relevant alterations. Intraoral examination revealed no macroglossia and the tongue dorsum had a normal appearance (**Figure 1A**). However, soft yellowish nodules with a smooth shiny surface without erosions were found diffusely on the lateral border of the tongue, bilaterally (**Figures 1B, C**). These findings suggested multiple tongue lipomas as the clinical diagnosis. An incisional biopsy under local anesthesia was performed on the left lateral

border of the tongue. Hematoxyllin and eosin section showed parakeratinized stratified squamous epithelium and a diffuse submucosal proliferation of lobules of unencapsulated mature adipose tissue (**Figures 2A, B**). The histopathologic diagnosis was suggestive of lipoma.

Considering the patient's history, clinical features, and the histopathological examination the definitive diagnosis was SLT. The patient was informed about the diagnosis and no surgical treatment was necessary. On follow-up 6 months, the tongue findings were unchanged and no new growths were observed.

Case Discussion

Lipoma is the most common nonepithelial benign soft tissue neoplasm, which usually occurs as a

solitary lesion in any part of the body [1-4]. In this report, our patient had multiple yellowish nodules of the tongue, which were diagnosed initially as lipoma. Benign symmetric lipomatosis is differentiated from lipoma by specific characteristics, such as the findings of diffuse, nonencapsulated nodules usually involving multiple anatomic sites [9, 10]. The main items in the differential diagnosis include traumatic fibroma, angioliipoma, and neurofibroma [3]. However, although BSL is relatively rare in the oral region, it can sometimes develop bilaterally on the tongue and then is entitled SLT [9, 10]. The current case was deemed to be SLT and could not be BSL owing to occurrence of oral lesions and the absence of other extraoral features. A few cases of SLT in the tongue without involvement of other sites have been reported in recent years [1-4, 6].

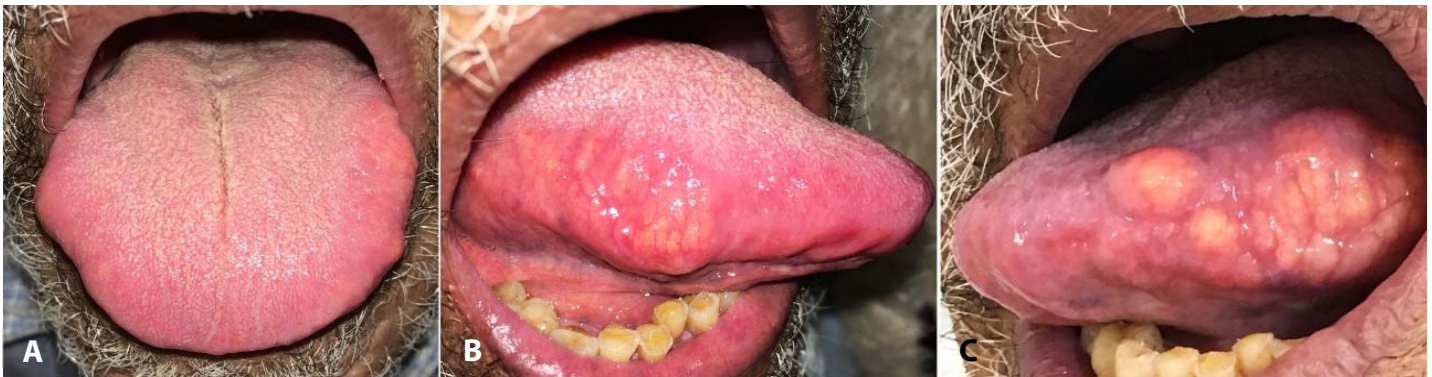

Figure 1. Symmetric lipomatosis of the tongue (SLT) in an 87-year-old man. Intraoral examination showed **A**) normal dorsum, **B, C**) soft yellowish masses with a smooth shiny surface on the lateral borders of the tongue bilaterally.

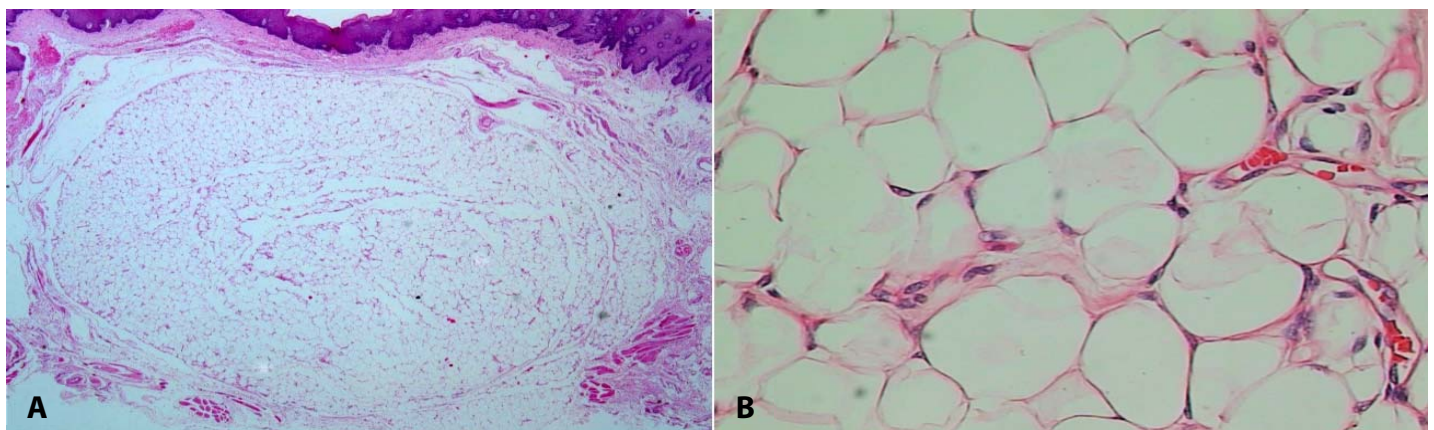


Figure 2. Photomicrographs showing diffuse submucosal proliferation lobules of mature adipose tissue unencapsulated. **A**) H&E, 10x; **B**) H&E, 40x.

As observed in our case, SLT occurs more commonly in elderly men [1, 7-10]. Usually, the multiple nodules of SLT can induce macroglossia [2, 5, 9, 10], which was not noted in this report. One of the first symptoms of SLT is dysphagia, which can progress slowly to dysarthria and dyspnea [9]. Although our patient had multiple nodules of the tongue, the lesions did not induce these symptoms. Therefore, as the patient had no complaints and tongue lesions remained unchanged, no surgical intervention was performed. Surgical treatment, generally with a partial glossectomy, is indicated for most cases to improve symptoms by reducing the size and changing the shape of the tongue [1-5, 9, 10]. In these cases, a clinical follow-up is needed to evaluate recurrence and any functional deficits of the tongue.

Only a few cases of conservative observation were described [6, 7]. Currently the patient is in clinical follow-up without clinical alterations or other lesions.

Conclusion

Symmetric lipomatosis of the tongue usually presents as multiple, non-encapsulated lipomas affecting only the tongue. Although it is a rare condition, SLT should be included in the differential diagnosis of multiple oral nodules in elderly patients.

Potential conflicts of interest

The authors declare no conflicts of interest.

References

1. Azuma M, Adachi M, Motohashi M, Muramatsu Y. Symmetrical lipomatosis of the tongue: Case report and literature review. *J Clin Lipidol*. 2015; 9: 602-6. [PMID: 26228680].
2. Cristofaro MG, Colangeli W, Riccelli U, Giudice M. A case of symmetrical lipomatosis of the tongue presenting as macroglossia. *Ann Ital Chir*. 2016; 87: S2239253X16025627. [PMID: 27427539].
3. Mayo Yáñez M, González Poggioli N, Álvarez-Buylla Blanco M, Herranz González-Botas J. Benign symmetric lipomatosis with lingual involvement: Case report and literature review. *J Stomatol Oral Maxillofac Surg*. 2018; 119: 148-150. [PMID: 29129710].
4. Ettl T, Gaumann A, Ehrenberg R, Reichert TE, Driemel O. Encapsulated lipomas of the tongue in benign symmetric lipomatosis. *J Dtsch Dermatol Ges*. 2009; 7: 441-4. [PMID: 19192164].
5. Lopez-Ceres A, Aguilar-Lizarralde Y, Villalobos Sánchez A, Prieto Sánchez E, Valiente Alvarez A. Benign symmetric lipomatosis of the tongue in Madelung's disease. *J Craniomaxillofac Surg*. 2006; 34: 489-93. [PMID: 17157517].
6. Kang JW, Kim JH. Images in clinical medicine. Symmetric lipomatosis of the tongue. *N Engl J Med*. 2013; 369: e5. [PMID: 23883389].
7. Murakami H, Tamasawa N. Images in clinical medicine. Lipomatosis of the tongue. *N Engl J Med*. 2009; 360: e33. [PMID: 19553642].
8. Desmond AM. A case of lipomatosis of the tongue. *Br J Surg*. 1947; 35: 210. [PMID: 20271770].
9. Vasileiadis I, Mastorakis G, Ieromonachou P, Logothetis I. Symmetrical lipomatosis of the tongue—a rare cause of macroglossia: diagnosis, surgical treatment, and literature review. *Laryngoscope*. 2013; 123: 422-5. [PMID: 23288609].
10. Kudoh M, Omura K, Satsukawa A, et al. Symmetric Lipomatosis Arising in the Tongue Presenting as Macroglossia and Articulatory Disorder. *Case Rep Otolaryngol*. 2016; 2016: 2061649. [PMID: 27413566].