

UC Irvine

Clinical Practice and Cases in Emergency Medicine

Title

Penile Dorsal Vein Rupture Identified by Emergency Department Ultrasound

Permalink

<https://escholarship.org/uc/item/6sr226bh>

Journal

Clinical Practice and Cases in Emergency Medicine, 5(1)

Authors

Scott, Sean E.
Langenohl, Robert
Crisostomo-Wynne, Theodore
et al.

Publication Date

2021

DOI

10.5811/cpcem.2020.10.49631

Copyright Information

Copyright 2021 by the author(s). This work is made available under the terms of a Creative Commons Attribution License, available at <https://creativecommons.org/licenses/by/4.0/>

Peer reviewed

Penile Dorsal Vein Rupture Identified by Emergency Department Ultrasound

Sean E. Scott, MD
Robert Langenohl, DO
Theodore Crisostomo-Wynne, MD
Christopher Kang, MD

Madigan Army Medical Center, Department of Emergency Medicine,
Tacoma, Washington

Section Editor: Rick A. McPheeters, DO

Submission history: Submitted August 27, 2020; Revision received October 6, 2020; Accepted October 9, 2020

Electronically published December 7, 2020

Full text available through open access at http://escholarship.org/uc/uciem_cpem

DOI: 10.5811/cpcem.2020.10.49631

Case Presentation: We present the case of a young male with high clinical suspicion of a penile fracture found to have dorsal vein rupture by emergency department point-of-care ultrasound. This false form of penile fracture was subsequently confirmed intraoperatively.

Discussion: Penile fracture is a rare clinical entity that may be separated into true vs false penile fracture, with only true fracture requiring surgery. The images submitted here add to the sparse literature evidence that point-of-care ultrasound can be used to differentiate between these two clinical entities. Additionally, this case report highlights an opportunity for further research into and application of point-of-care ultrasound to the evaluation of suspected penile fractures. [Clin Pract Cases Emerg Med. 2021;5(1):121–122.]

Keywords: *Penile fracture; emergency ultrasound.*

CASE PRESENTATION

A 26-year-old man presented to the emergency department with penile pain and bruising after accidental trauma during intercourse one hour prior to arrival. He reported immediate pain and bruising with detumescence within minutes. Exam was revealing for eggplant deformity of the penis with soft dorsal ecchymosis and mass felt extending into the scrotum (Image 1).

DISCUSSION

Dorsal Vein Rupture: This patient's ultrasound images showed hematoma external to Buck's fascia and intact tunica albuginea, suggestive of dorsal penile vessel injury (Images 2 and 3). This is a type of false penile fracture and requires only conservative treatment.¹ True penile fracture, with disruption of the tunica albuginea, can be exceptionally difficult to distinguish from false penile fracture, has a worse prognosis, and requires emergency surgery.¹ Along with history and physical exam, point-of-care ultrasound can help differentiate these entities.² Delay of presentation greater than 24 hours of penile fracture has been linked to an increased rate of postoperative complications; so expeditious diagnosis is important to help reduce the time to

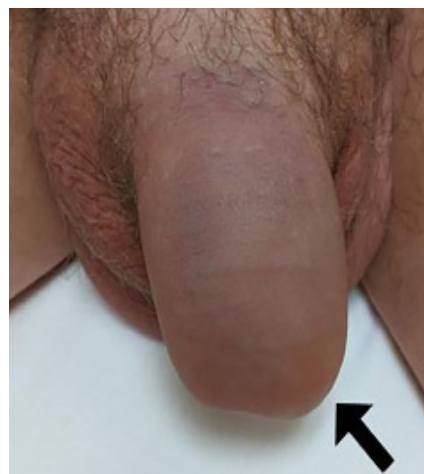

Image 1. Patient's penis with eggplant deformity (arrow) at presentation to the emergency department.

intervention.³ Ultrasound can be an inexpensive, non-invasive, and often readily available means of investigation that may be performed at initial presentation without delay to surgery.⁴ False

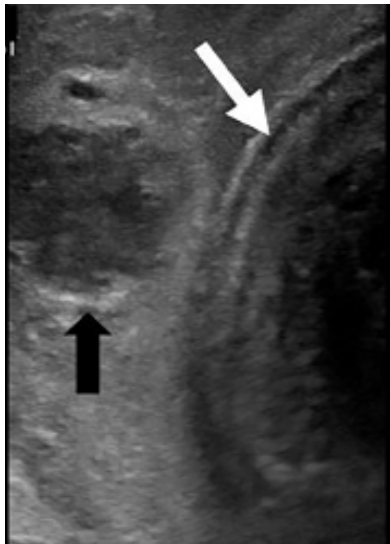


Image 2. Intact tunica albuginea (white arrow) and likely ruptured vein with surrounding hematoma (black arrow).

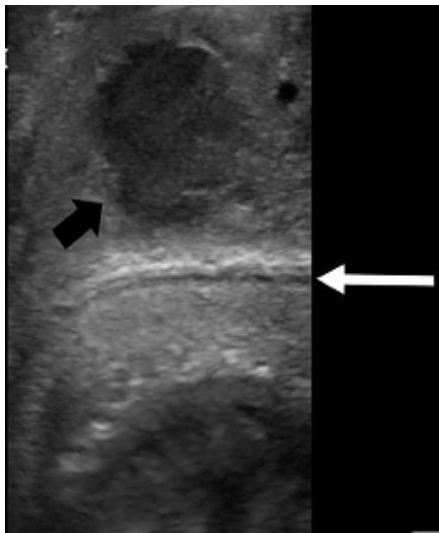


Image 3. Intact tunica albuginea (white arrow) and likely ruptured dorsal vein with surrounding hematoma (black arrow).

penile fracture is exceptionally rare, and is considered exceptionally difficult to distinguish from true penile fracture, often leading to surgery.⁵ Further research is necessary to help delineate the role of ultrasound in separating false from true penile fracture.

Surgical exploration confirmed a dorsal vein rupture with subsequent drainage of a large hematoma involving the dorsal vein and dartos layer dorsally. There were no acute complications. On follow-up the patient reported recovery of sexual function without curvature, but with mild residual pain to the incision site at six-week postoperative follow-up.

Patient consent has been obtained and filed for the publication of this case report.

CPC-EM Capsule

What do we already know about this clinical entity?

Penile fracture is a rare clinical entity encountered following trauma to the erect penis and is typically managed surgically.

What is the major impact of the image(s)?

This image increases awareness of false penile fracture and the utility of ultrasound in evaluation for possible penile fracture.

How might this improve emergency medicine practice?

Increased use of point-of-care ultrasound may allow for improved accuracy in differentiating between true and false penile fracture and reduce the need for surgery.

Address for Correspondence: Sean E. Scott, MD, Madigan Army Medical Center, Department of Emergency Medicine, 9040A Jackson Ave., Joint Base Lewis-McChord, WA 98431. Email: sean.e.scott4.mil@mail.mil.

Conflicts of Interest: By the CPC-EM article submission agreement, all authors are required to disclose all affiliations, funding sources and financial or management relationships that could be perceived as potential sources of bias. The views expressed here are those of the authors and do not reflect the official policy of the Department of the Army, the Department of Defense, or the U.S. Government. The authors disclosed none.

Copyright: © 2021 Scott et al. This is an open access article distributed in accordance with the terms of the Creative Commons Attribution (CC BY 4.0) License. See: <http://creativecommons.org/licenses/by/4.0/>

REFERENCES

1. Sharma GR. Rupture of the superficial dorsal vein of the penis. *Int J Urol.* 2005;12(12):1071-3.
2. Ash A, Miller J, Preston D. Point-of-care ultrasound used to exclude penile fracture. *Crit Ultrasound J.* 2012;4(1):17.
3. Patil B, Kamath SU, Patwardhan SK, et al. Importance of time in management of fracture penis: a prospective study. *Urol Ann.* 2019;11(4):405-9.
4. Dell'Atti L. The role of ultrasonography in the diagnosis and management of penile trauma. *J Ultrasound.* 2016;19(3):161-6.
5. Feki W, Derouiche A, Belhaj K, et al. False penile fracture: report of 16 cases. *Int J Impot Res.* 2007;19(5):471-3.