

UC Irvine

Clinical Practice and Cases in Emergency Medicine

Title

A Plumb Fit

Permalink

<https://escholarship.org/uc/item/6zv916xw>

Journal

Clinical Practice and Cases in Emergency Medicine, 1(4)

Authors

Harrison, Michael F.
Rooney, Kevin
Jaskulka, Bradley

Publication Date

2017

DOI

10.5811/cpcem.2017.9.35222

Copyright Information

Copyright 2017 by the author(s). This work is made available under the terms of a Creative Commons Attribution License, available at <https://creativecommons.org/licenses/by/4.0/>

Peer reviewed

A Plumb Fit

Michael F. Harrison MD, PhD*†
Kevin Rooney, MD, MS*
Bradley Jaskulka, MD*

*Henry Ford Hospital, Department of Emergency Medicine, Detroit, Michigan
†Henry Ford Hospital, Department of Internal Medicine, Detroit, Michigan
‡Henry Ford Hospital, Department of Internal Medicine, Division of Critical Care Medicine, Detroit, Michigan

Section Editor: Rick A. McPheeters, DO

Submission history: Submitted June 18, 2017; Revision received August 19, 2017; Accepted September 6, 2017

Electronically published October 18, 2017

Full text available through open access at http://escholarship.org/uc/uciem_cpem

DOI: 10.5811/cpem.2017.9.35222

[Clin Pract Cases Emerg Med. 2017;1(4):278–279.]

CASE PRESENTATION

In the middle of the night, a young male with no significant past medical history presented from a local detention facility with an unusual chief complaint – entrapment of his right hand in the cell’s stainless steel toilet basin. The circumstances leading to this complaint were unclear, and the hand had been in the toilet for approximately three hours at the time of arrival. When detention facility staff, including a plumber, were unsuccessful in freeing the hand, the patient and the entire toilet and sink assembly were

transported to our emergency department (Image). To assist efforts to safely remove the hand, a plain radiograph identified its location with respect to the toilet’s inner structure (Image).

While preparations were being made to cut the toilet with a power saw, approximately 500mL of ultrasound gel was applied to the basin and allowed to seep into the outflow tract. Using firm manual traction, the patient’s hand was then safely freed. Physical exam of the liberated hand revealed water aging but no other anatomical, functional, or sensory abnormalities. A subsequent (more traditional) series of plain

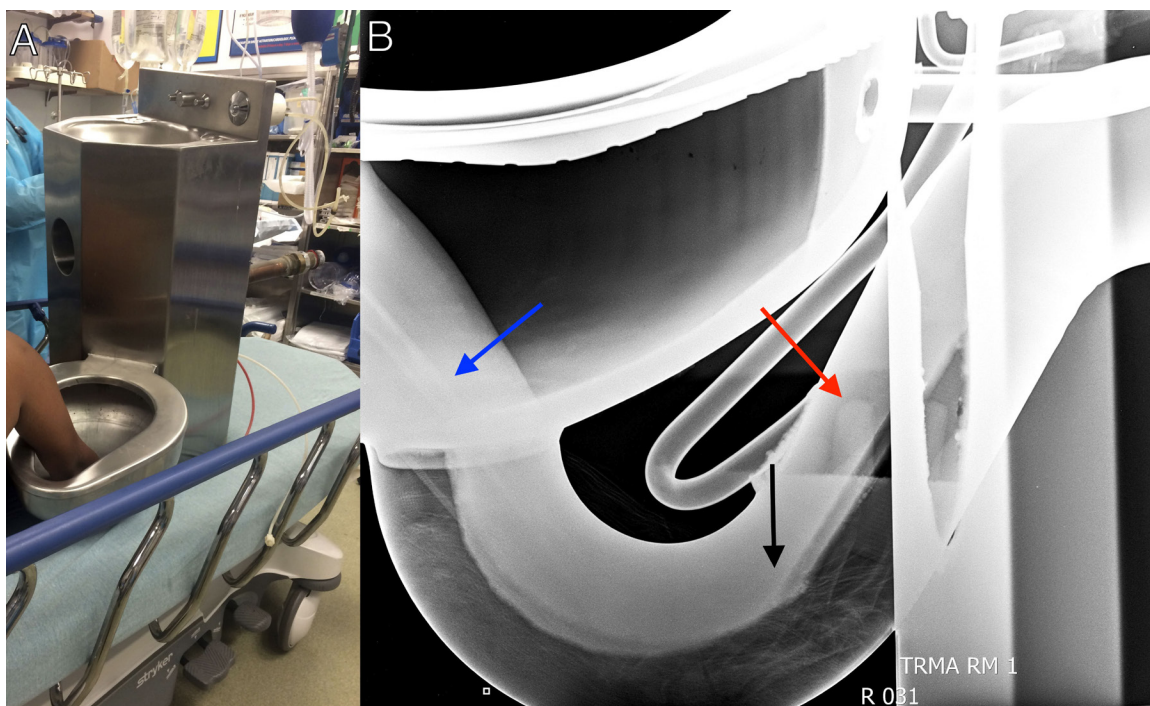


Image. The patient’s right hand and intact sink / toilet assembly (Panel A) on the stretcher in the trauma bay; the lateral view radiograph of the entrapped hand (blue arrow – shaft of radius; black arrow – metacarpals; red arrow – distal tips of fingers) inside the toilet (Panel B).

radiographs revealed no acute osseous injury; and laboratory analysis, including creatinine phosphokinase levels, were within normal limits. The patient and intact toilet were subsequently discharged to the detention center.

DISCUSSION

While using a toilet may seem like a benign common process, injuries do occur.¹⁻³ Alternatively, hand injuries are one of the most common complaints of prisoners requiring medical attention.⁴⁻⁶ Regardless of patient population, this case demonstrates an unusual marriage of hand and toilet injuries requiring medical intervention. The use of ultrasound gel to liberate the patient's hand is an excellent example of the "thinking on your feet" skillset that makes our profession both challenging and enjoyable.

Address for Correspondence: Michael F Harrison, MD, PhD, Henry Ford Hospital, 2799 W Grand Boulevard, Detroit, MI 48202. Email: mharr19@hfhs.org.

Conflicts of Interest: By the CPC-EM article submission agreement, all authors are required to disclose all affiliations, funding sources and financial or management relationships that could be perceived as potential sources of bias. The authors disclosed none.

Copyright: © 2017 Harrison et al. This is an open access article distributed in accordance with the terms of the Creative Commons Attribution (CC BY 4.0) License. See: <http://creativecommons.org/licenses/by/4.0/>

REFERENCES

1. Dar TA, Sultan A, Dhar SA, et al. Toilet seat injury of the Achilles tendon: a series of twelve cases. *Foot Ankle Surg.* 2011;17(4):284-6.
2. Glass AS, Bagga HS, Tasian GE, et al. No small slam: increasing incidents of genitourinary injury from toilets and toilet seats. *BJU Int.* 2013;112(3):398-403.
3. Farhadi MR, Becker M, Stippich C, et al. Transorbital penetrating head injury by a toilet brush handle. *Acta Neurochir (Wien).* 2009;151(6):685-7.
4. Henning J, Frangos S, Simon R, et al. Patterns of traumatic injury in New York City prisoners requiring hospital admission. *J Correct Health Care.* 2015;21(1):53-8.
5. Bond J, Butler T, Kariminia A, et al. Injury surveillance in the New South Wales prison system. *Health Promot J Austr.* 2004;15(2):151.
6. Centers for Disease Control and Prevention (CDC). Injury surveillance in correctional facilities--Michigan, April 1994-March 1995. *MMWR Morb Mortal Wkly Rep.* 1996;45(3):69-72.

CPC-EM Capsule

What do we already know about this clinical entity?

As emergency physicians, we know people often get their hands or other appendages entrapped in usual manners and places. They come to us for help.

What is the major impact of the image(s)?

The current image demonstrates an unusual manner of manual entrapment with an unorthodox use of lubrication and radiographs. We can provide solutions.

How might this improve emergency medicine practice?

The ability to maintain professional composure while thinking on our feet and outside the box defines a successful emergency physician. These cases also make the job fun.