

UC Davis

Dermatology Online Journal

Title

Trichobacteriosis: contribution of dermoscopy

Permalink

<https://escholarship.org/uc/item/7488q7vb>

Journal

Dermatology Online Journal, 20(9)

Authors

Salim, Gallouj
Zahra, Mernissi Fatima

Publication Date

2014

DOI

10.5070/D3209023921

Copyright Information

Copyright 2014 by the author(s). This work is made available under the terms of a Creative Commons Attribution-NonCommercial-NoDerivatives License, available at <https://creativecommons.org/licenses/by-nc-nd/4.0/>

Peer reviewed

Photo Vignette

Trichobacteriosis: contribution of dermoscopy

Gallouj Salim, Mernissi Fatima Zahra

Department of Dermatology, University Hospital Hassan second, Faculty of Medicine of Fez, Morocco.

Dermatology Online Journal 20 (9): 14

Correspondence:

Salim Gallouj
University Hospital Hassan II
sgallouj@gmail.com

Abstract

We report a case of axillary trichobacteriosis in a 34-year-old patient whose complaints were bromhidrosis and hyperhidrosis axillaris. The condition can be diagnosed clinically; dermoscopy may be useful and reveal typical signs.

Keywords: corynebacterium; hyperhidrosis; Wood's light; dermoscopy

Introduction

Trichobacteriosis (formerly called trichomycosis) is an asymptomatic bacterial disorder affecting the hair shafts of the large skin folds. The involvement of pubic hair has been reported. Disturbances in apo-ecrine sweat production and bacterial proliferation are crucial for trichobacteriosis development. We report a case of axillary trichobacteriosis in a adult patient with complaints of bromhidrosis and hyperhidrosis axillaris.

Case synopsis

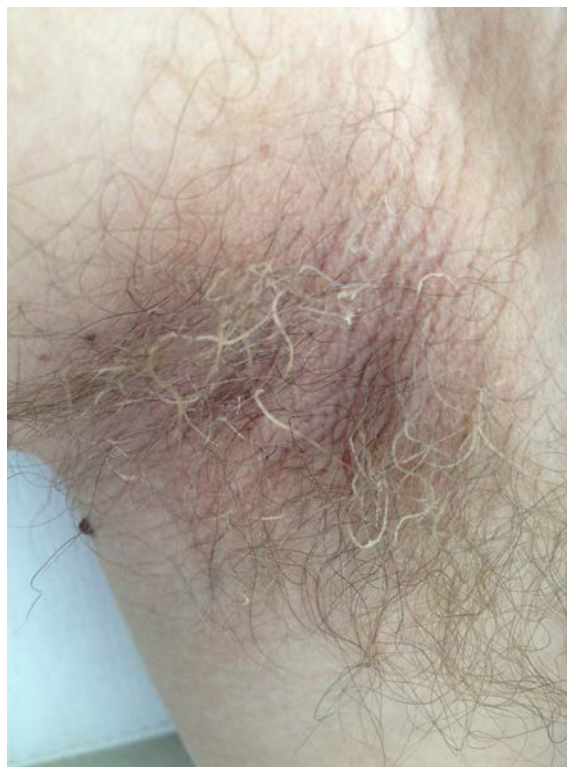

Figure 1. Yellow concretions along hair shafts of right axilla of an adult male patient

A 34-year-old man was admitted to the outpatient department reporting excessive sweating in his axillae and unpleasant odor for many years. On physical examination, it was noticed that his axillary hair was surrounded by soft, waxy, and yellowish concretions (Figure 1). Wood's light examination reveals pale-yellow fluorescence (Figure 2), but the skin of the axilla showed no coral red fluorescence, ruling out erythrasma. Dermoscopy images were taken to improve the diagnosis (Figures 3 and 4) and showed waxy and yellowish adherent nodules and concretions along the entire length of the hair of the axilla, a skewer sign, and a plume sign, a flame-like pale yellowish adherent nodule. The patient was treated by shaving the axillae and using topical erythromycin 2%. Currently, the patient is in remission and has improved his level of hygiene with regular bathing and frequent shaving of axillary hair to prevent recurrences.

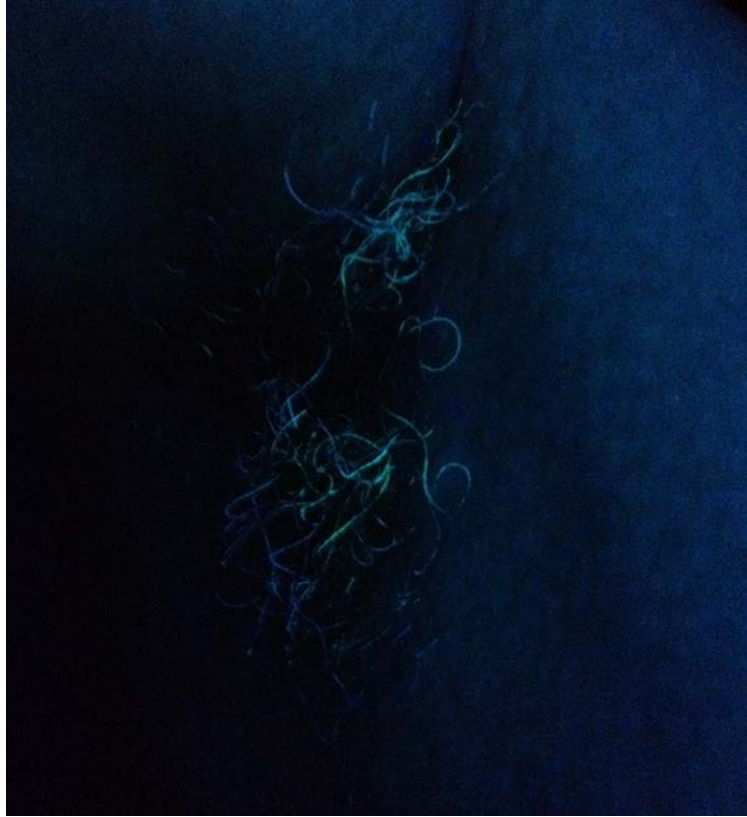

Figure 2. Wood's light examination reveals pale-yellow fluorescence

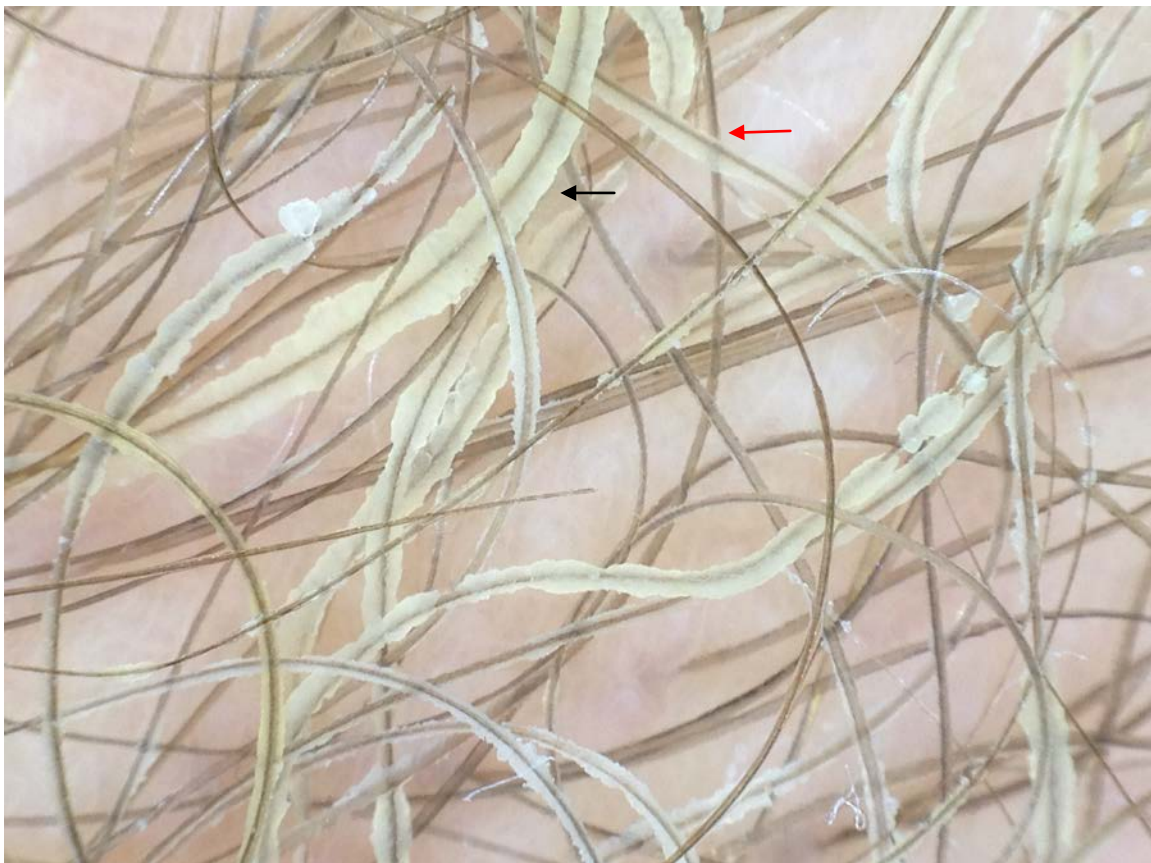


Figure 3. Dermoscopic study with Polarized dermoscopy image revealing waxy and yellowish adherent nodules and concretions along the entire length of the hair of the axilla , skewer sign(red arrow) and plume sign(black arrow)

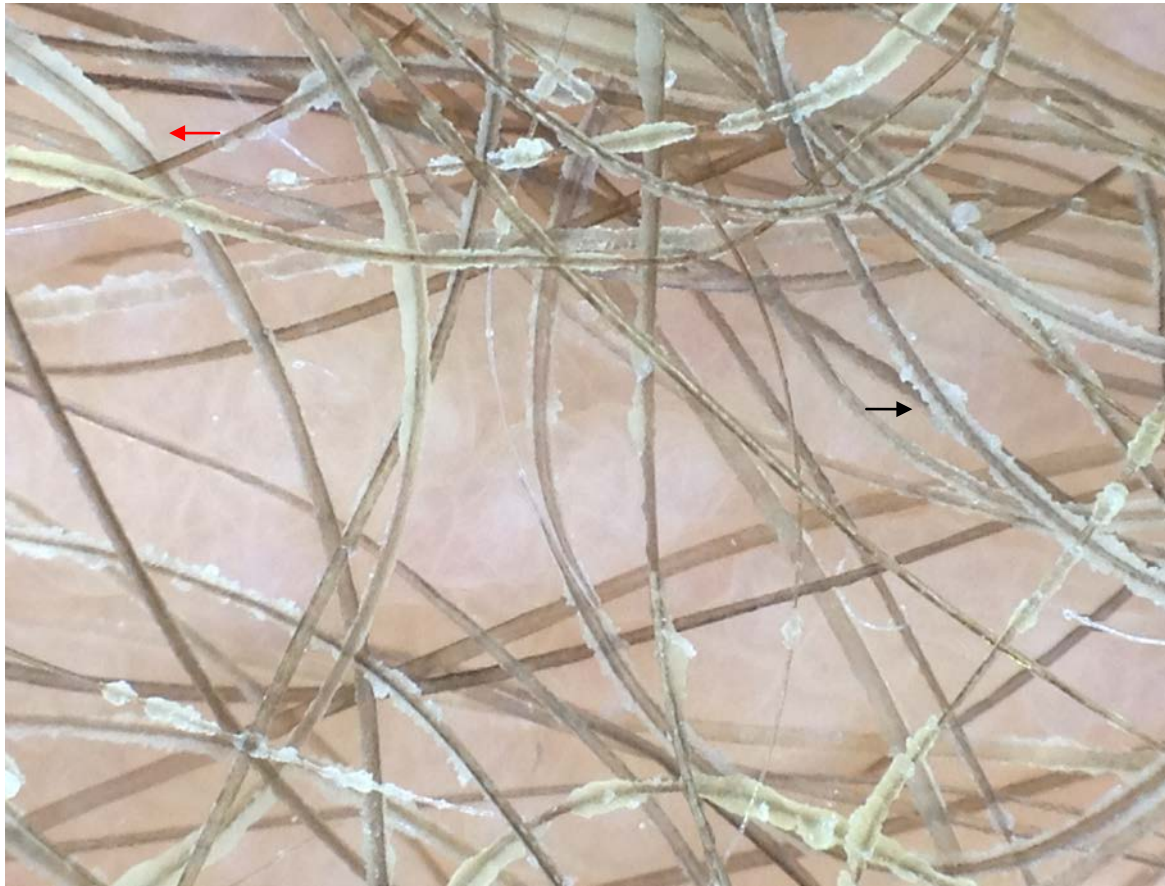

Figure 4. Dermoscopic study: Close-up picture of polarized dermoscopy revealing a flame-like aspect (black arrow) of pale yellowish adherent nodules and concretions and the plume sign (red arrow)

Discussion

Trichobacteriosis, trichomycosis axillaris, or trichomycosis palmellina belongs to the group of cutaneous corynebacterioses that also includes erythrasma and pitted keratolysis. It is mostly caused by *Corynebacterium tenuis* and is clinically characterized by yellowish, reddish, or blackish sticky concretions surrounding the hair shafts of the axillary or pubic regions. Hyperhidrosis and improper hygiene are the main predisposing factors [1].

The concretions contain the bacterial colonies of *Corynebacterium tenuis*, easily recognized in gram stained preparations of crushed concretions. There appear under light microscopy as purple rods and coccobacilli. Different taxonomic species of corynebacteria are identified. The concretion material is derived from bacterial colonization along the hair shaft containing dried apocrine sweat with a cementing substance generated by the bacteria. Encapsulated corynebacteria entrapped in a biofilm serve as the adhering mechanism, which possibly helps the organism to escape immunological attack by the host. The condition is easily recognized by clinicians. Wood's light examination reveals pale-yellow fluorescence contrary to what is seen in erythrasma. In the latter, the Wood's light reveals a bright coral-red appearance, resulting from the presence of porphyrin produced by the bacteria. In trichobacteriosis, ultraviolet light enhances visualization of bacterial colonies and encapsulated biofilm [2,3,4]., By culture, a mixture of microorganisms may be identified: *Corynebacterium* sp. (white-yellow growth) and *Serratia marcescens* (red growth); the red color is produced by bacterial carotenoid pigments [2]. Warm, moist environment, excessive sweating, and poor local hygiene are common predisposing factors. TA often results in a bad odor in axillae and may stain the clothing [3].

The differential diagnosis includes white piedra, black piedra, and hair casts [4]. Rarely, the condition may be confused with pediculosis and *Trichosporon asellei* infections [3]. With the advent of the marketing of polarized dermatoscopes, dermoscopy has increased in popularity among dermatologists worldwide and dermoscopic features of a huge range of dermatoses have been described. Although there is not much challenge in diagnosing trichobacteriosis, we believe that dermoscopy would be a time-saving and helpful tool in doubtful cases [1]. We report new dermoscopic signs, skewer sign and plume sign, that can be helpful to support diagnoses of trichobacteriosis.

For therapy of trichobacteriosis, many authors consider most effective treatment to be shaving of the affected area for a period of 2-3 weeks, but cleansing methods, such as the use of sulfur soaps, is also recommended. Those patients who shave the affected area only once will generally experience a recurrence of the infection because the bacteria begin to proliferate again as the hair grows back. Topical treatments containing any of the following: 3% sulfur, 2% sodium hypochlorite, topical

antibiotics (fusidic acid, erythromycin, and clindamycin), or benzoyl peroxide may be required. Antimycotic agents like naftifine and some azole derivatives are effective as well because of their concomitant antibacterial activity[1,2]. Regular use of topical ammonium chloride solution and drying powders that counter perspiration may prevent further recurrences [3].

References

1. Guiotoku MM, Ramos PM, Miot HA, Marques SA .Trichobacteriosis: case report and dermoscopic study.*An Bras Dermatol.* 2012;87(2):315-6. (PMID: 22570043)
2. Bonifaz A, Vázquez-González D, Fierro L, Araiza J, Ponce RM..Trichomycosis (Trichobacteriosis): Clinical and Microbiological Experience with 56 Cases .*Int J Trichology.* 2013 ; 5(1): 12–16. (PMID: 23960390)
3. Zawar V. Trichomycosis (trichobacteriosis) axillaris .*J Dermatol Case Rep.* 2011 ,5(2):36-37.(PMID: 21894255)
4. Blaise G, Nikkels AF, Hermanns-Le T, Nikkels-Tassoudji N, Pierard GE. Corynebacterium-associated skin infections. *Int J Dermatol.* 2008;47:884-90. (PMID:18937649)