

# UC Davis

## Dermatology Online Journal

### Title

Bullous dermatoses secondary to anti-PD-L1 agents: a case report and review of the literature

### Permalink

<https://escholarship.org/uc/item/7qg9675d>

### Journal

Dermatology Online Journal, 25(10)

### Authors

Kosche, Cory  
Owen, Joshua L  
Sadowsky, Lauren M  
et al.

### Publication Date

2019

### DOI

10.5070/D32510045817

### Copyright Information

Copyright 2019 by the author(s). This work is made available under the terms of a Creative Commons Attribution-NonCommercial-NoDerivatives License, available at <https://creativecommons.org/licenses/by-nc-nd/4.0/>

Peer reviewed

# Bullous dermatoses secondary to anti-PD-L1 agents: a case report and review of the literature

Cory Kosche BS<sup>1</sup>, Joshua L Owen MD PhD<sup>1</sup>, Lauren M Sadowsky BA<sup>1</sup>, Jennifer N Choi MD<sup>1,2</sup>

Affiliations: <sup>1</sup>Department of Dermatology, Northwestern University Feinberg School of Medicine, Chicago, Illinois, USA; <sup>2</sup>Robert H. Lurie Comprehensive Cancer Center of Northwestern University, Chicago, Illinois, USA

Corresponding Author: Jennifer N. Choi, 676 North St. Clair Street, Suite 1600, Chicago, IL 60611, Northwestern email: [jennifer.choi@northwestern.edu](mailto:jennifer.choi@northwestern.edu), Tel: 312-695-8106

## Abstract

Immune checkpoint inhibitors are used to treat numerous malignancies but may be associated with severe adverse events. Bullous dermatoses, chiefly bullous pemphigoid (BP), are potentially progressive adverse events that cause blistering skin lesions and may involve a significant body surface area. Herein, we report an 87-year-old man with urothelial cell carcinoma undergoing atezolizumab treatment who presented with an acute-onset blistering eruption. Biopsy revealed a subepidermal bulla, direct immunofluorescence revealed linear IgG and C3 deposits at the dermal-epidermal junction, and serum studies revealed elevated levels of antibodies to BP180 and BP230. Anti-PD-L1-induced BP was diagnosed, immunotherapy was withheld, and he was treated with oral doxycycline with niacinamide and clobetasol ointment. He restarted atezolizumab and has successfully received four cycles (every 3 weeks) while continuing this BP treatment regimen. A literature review revealed eight other cases of anti-PD-L1-induced bullous disorders. The incidence of bullous dermatoses with anti-PD-1/anti-PD-L1 agents combined is 1%, whereas the reported incidence for anti-PD-L1 agents alone ranges from 1.3-5%, raising concerns for a higher overall risk. In addition to our case, only one other case reported successful resumption of immunotherapy. Early control and management of immunotherapy-induced BP may reduce complications and prevent treatment discontinuation.

Keywords: immunotherapy, bullous pemphigoid,

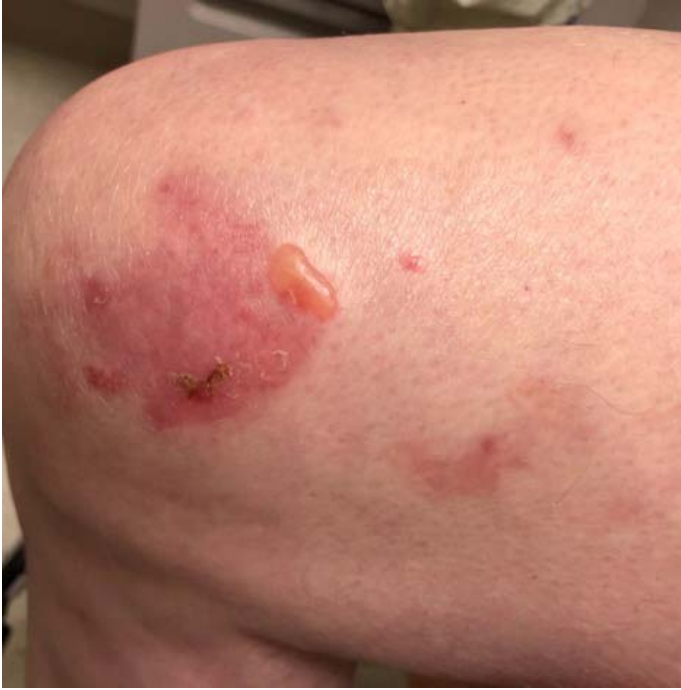*atezolizumab, checkpoint inhibitor, PD-L1, immune-related adverse event*

## Introduction

Immune checkpoint inhibitor therapies are used in the treatment of numerous malignancies. Although inducing immune activation with strong anti-tumor effects, they can lead to toxicities, known as immune-related adverse events (irAEs), which may affect any organ system [1]. Bullous dermatoses, most frequently bullous pemphigoid (BP), may cause interruption and discontinuation of immunotherapy owing to potential extensive skin involvement and complications [2]. Because toxicities of anti-PD-1/anti-PD-L1 agents are frequently grouped together, differences in irAE risk between anti-PD-1 and anti-PD-L1 agents have not been examined. Herein, we present a patient with anti-PD-L1-induced BP and review reported cases of bullous dermatoses secondary specifically to anti-PD-L1 agents.

## Case Synopsis

An 87-year-old man with urothelial cell carcinoma initiated immunotherapy treatment with anti-PD-L1 agent atezolizumab, after no response to carboplatin and gemcitabine. He experienced mild, diffuse pruritus until, at 18 months, he developed "chicken pox-like blisters" on the left forearm. The patient continued immunotherapy for three more months at which time atezolizumab was held owing to progression of the bullous eruption; he was referred to the dermatology department.



**Figure 1.** Clinical photograph demonstrating lower extremity with an erythematous patch and a tense bulla.

Physical examination demonstrated numerous intact, tense bullae, some with adjacent erosions and crusting, localized on the posterior neck, left posterior shoulder, abdomen, arms, and legs (**Figure 1**). The largest bulla was approximately 3cm with several smaller 5-6mm vesicles. The oral and ocular mucosae were unaffected.

Lesional edge punch biopsy revealed a sub-epidermal pauci-cellular blister on hematoxylin and eosin (H&E) staining. Perilesional punch biopsy for direct immunofluorescence (DIF) showed linear IgG and C3 deposits at the dermal-epidermal junction (**Figure 2**). Anti-BP230 IgG levels were 13U/mL (reference range <9U/mL), and anti-BP180 IgG levels were 22U/mL (reference range <14U/mL). As a result, anti-PD-L1-induced BP was diagnosed.

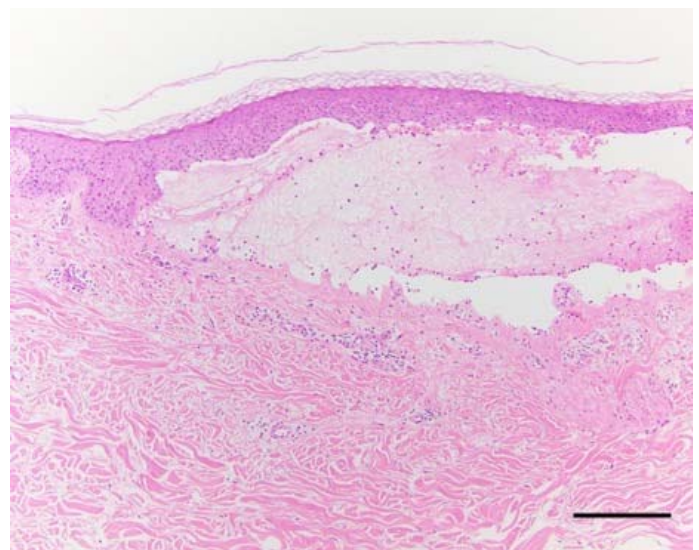
The patient was started on 100mg oral doxycycline twice daily, 500mg oral niacinamide twice daily, and topical clobetasol 0.05% ointment twice daily to affected areas. Three months after BP treatment initiation, the blisters completely resolved. Atezolizumab treatment was held for a total of nine weeks (three cycles), at which point it was restarted with close clinical monitoring. He has since received

four additional immunotherapy cycles while continuing the doxycycline, niacinamide, and clobetasol ointment with only mild intermittent pruritus. He continues to be monitored and remains on atezolizumab therapy.

## Case Discussion

There is limited evidence focusing on the incidence and characterization of anti-PD-L1-induced bullous dermatoses. Anti-PD-L1 immunotherapy targets the PD-L1, expressed in non-T lymphocytes (e.g., antigen-presenting cells), thus relieving the inhibition on T cell-mediated immune response [3]. However, the autoantibody-mediated reaction in bullous dermatoses likely signifies B lymphocyte involvement as well [4]. This reaction may represent enhancement of a pre-existing autoantibody response or an entirely new process directly caused by immunotherapy treatment [4].

There have been nine reported cases of patients who developed bullous dermatoses during anti-PD-L1 therapy. These nine cases showed an average patient age of 70.5 years with an average time to dermatosis diagnosis of 9.4 months (**Table 1**). The prolonged latency is a unique feature of immunotherapy-induced bullous dermatoses because most dermatologic irAEs occur early in treatment, often



**Figure 2.** Histopathological image demonstrating a sub-epidermal pauci-cellular bulla with eosinophils. H&E, 100 $\times$ ; scale bar=100 $\mu$ m.

after the first cycle [1]. The reported malignancies and specific anti-PD-L1 agents were varied, reflecting the primary cancers being treated with anti-PD-L1 agents. Reported incidence rates of anti-PD-L1-induced bullous dermatoses (1.35%, 5%), [2, 5], are higher than the reported 1% for PD-1/PD-L1 combined [2]. In the setting of a bullous dermatosis during anti-PD-L1 therapy, switching to an anti-PD-1 agent or another class of checkpoint inhibitor may be warranted.

For bullous dermatoses, helpful diagnostic tools include lesional biopsy for H&E staining, perilesional biopsy for DIF, and serologic testing for anti-BP180 and anti-BP230 antibodies. All studies found in our literature review that performed a skin biopsy found classic BP on histopathology and immunofluorescence analysis. In addition, in the three cases that tested for autoantibodies, positive results were reported. Skin biopsy and serum studies may aid in distinguishing between bullous dermatoses and other dermatologic reactions early in presentation. Treatment of immunotherapy-induced bullous dermatoses is similar to the treatment of classic BP. Corticosteroids, doxycycline, nicotinamide, methotrexate, and rituximab have been utilized successfully [2, 7, 8]. In all but one of the reviewed studies that reported treatment, oral prednisone was used to achieve disease control. Even with discontinuation of anti-PD-L1 immunotherapy, aggressive management to prevent extensive disease with high morbidity is likely necessary.

None of the nine patients reported a history of bullous dermatoses. In our patient, the first 18 months of pruritus while on anti-PD-L1 therapy may

have signified subclinical BP or the more common clinical scenario of immunotherapy-induced pruritus. In two previously reported cases, when anti-PD-L1 immunotherapy was resumed, BP recurred necessitating permanent discontinuation of immunotherapy [5]. In one case, immunotherapy was not held and the patient was able to continue treatment without BP flares [6]. Overall, two of 9 patients remain on anti-PD-L1 immunotherapy whereas the remaining 7 had to discontinue treatment. Regarding response to immunotherapy, 5 of 6 patients with reported treatment response in the review had a partial response to immunotherapy and the final case reported stable disease. The marked response to immunotherapy is contrasted by the frequent need for treatment discontinuation. Early and effective control of these bullous reactions may prevent the need for treatment discontinuation and allow for continued response to anti-PD-L1 agents.

## Conclusion

To the best of our knowledge, this is only the second reported case of successfully restarting anti-PD-L1 therapy in a patient who developed immunotherapy-induced BP. Dermatologic referral should occur at the onset of any skin reaction believed to be secondary to immunotherapy. This case highlights the importance of prompt and aggressive management of immunotherapy-induced bullous pemphigoid, potentially allowing patients to remain on these life-sustaining therapies.

## Potential conflicts of interest

The authors declare no conflicts of interests.

## References

1. Brahmer JR, Lacchetti C, Thompson JA. Management of immune-related adverse events in patients treated with immune checkpoint inhibitor therapy: American society of clinical oncology clinical practice guideline summary. *J Oncol Pract*. 2018;14:247-249. [PMID: 29442540]
2. Siegel J, Totonchy M, Damsky W, et al. Bullous disorders associated with anti-PD-1 and anti-PD-L1 therapy: a retrospective analysis evaluating the clinical and histopathologic features, frequency, and impact on cancer therapy. *J Am Acad Dermatol*. 2018;79:1081-1088. [PMID: 30025829]
3. Francisco LM, Salinas VH, Brown KE, et al. PD-L1 regulates the development, maintenance, and function of induced regulatory T cells. *J Exp Med*. 2009;206:3015. [PMID: 20008522]
4. Toi Y, Sugawara S, Sugisaka J, et al. Profiling preexisting antibodies in patients treated with anti-PD-1 therapy for advanced non-small cell lung cancer. *JAMA Oncol*. 2018;5:376-83. [PMID: 30589930]
5. Strauss J, Heery CR, Schlom J, et al. Phase I trial of M7824 (MSB0011359C), a bifunctional fusion protein targeting PD-L1

- and TGFbeta, in advanced solid tumors. *Clin Cancer Res.* 2018;24:1287-1295. [PMID: 29298798]
6. Shen J, Chang J, Mendenhall M, et al. Diverse cutaneous adverse eruptions caused by anti-programmed cell death-1 (PD-1) and anti-programmed cell death ligand-1 (PD-L1) immunotherapies: clinical features and management. *Ther Adv Med Oncol.* 2018;10:1758834017751634. [PMID: 29383039]
  7. Naidoo J, Schindler K, Querfeld C, et al. Autoimmune bullous skin disorders with immune checkpoint inhibitors targeting PD-1 and PD-L1. *Cancer Immunol Res.* 2016;4:383-9. [PMID: 26928461]
  8. Sowerby L, Dewan AK, Granter S, Gandhi L, LeBoeuf NR. Rituximab treatment of nivolumab-induced bullous pemphigoid. *JAMA Dermatol.* 2017;153:603-605. [PMID: 28355425]
  9. Kaunitz GJ, Loss M, Rizvi H, et al. Cutaneous eruptions in patients receiving immune checkpoint blockade: clinicopathologic analysis of the nonlichenoid histologic pattern. *Am J Surg Pathol.* 2017;41:1381-1389. [PMID: 28817405]
  10. Russo I, Sacco G, Frega S, et al. Immunotherapy-related skin toxicity: bullous pemphigoid in a lung adenocarcinoma patient treated with the anti-PDL1 antibody atezolizumab. *Eur J Dermatol.* 2017;27:205-208. [PMID: 28251900]
  11. Fontecilla NM, Khanna T, Bayan CY, Antonov NA, Geskin LJ. Bullous pemphigoid associated with a new combination checkpoint inhibitor immunotherapy. *J Drugs Dermatol.* 2019;18:103-104. [PMID: 30681807]

**Table 1.** Reported cases of anti-PD-L1-induced bullous dermatoses.

Article	Age	Sex	Malignancy	Anti-PD-L1 Agent	Histology/Immuno-fluorescence	Serum Studies	Time to development (months)	Effect on immunotherapy	Treatment	Response to treatment	Response to immunotherapy (complete, partial, none)
Kaunitz, G., et al. [9]	65	M	NSCLC*	Not-specified	n/a	n/a	9	Delayed, rechallenged and discontinued with BP flare	Clobetasol spray, prednisone	n/a	n/a
Naidoo, J., et al. [10]	78	F	Metastatic melanoma	Durvalumab	n/a	n/a	12	Discontinued	Clobetasol solution 0.05%	Moderate response, still recurred occasionally 1 year later	Partial response
Russo, I., et al. [11]	59	M	NSCLC*	Atezolizumab	n/a	n/a	15	Discontinued	Prednisone 50mg/d, doxycycline	Complete response	n/a
Shen, J., et al. [6]	67	F	Metastatic adrenocortical carcinoma	Avelumab	First biopsy: epidermal spongiosis and intraepidermal neutrophilic and eosinophilic pustules, consistent with a dermal hypersensitivity reaction; second biopsy: eosinophilic spongiosis with focal subepidermal clefting, DIF with 2+ focal C3 staining (nonspecific)	n/a	n/a	No treatment interruption	Clotrimazole cream, hydrocortisone, TAC ointment, prednisone 10 mg/d, dexamethasone	n/a	Partial response
Siegel, J., et al. [2]	77	F	Urothelial cell	Atezolizumab	HE: Subepidermal bulla DIF: IgG and C3	BP180 level: 47	5	Discontinued	Topical CS, prednisone, omalizumab, methotrexate	Complete response with	Partial response

					at DEJ IIF: IgG and C3 at DEJ						persistent pruritus	
Siegel, J., et al. [2]	66	F	AML	Durvalumab	HE: Subepidermal bulla, neutrophils DIF: IgG, IgA and C3 at DEJ IIF: Intercellular IgG (1:80) and IgA (1:10)	BP180 level: 18	0.5	Discontinued	Topical CS, prednisone, dapsone	Complete response	Stable disease	
Strauss, J., et al. [5]	n/a	n/a	Mismatch repair deficient pancreatic cancer	m7824 (anti-PD-L1)	n/a	n/a	6	Delayed, rechallenged and discontinued with BP flare	n/a	n/a	Partial response, progression upon discontinuation	
Fontecilla, et al. [12]	65	F	NSCLC	Durvalumab+ Tremelimumab	HE: Subepidermal blister, epidermal necrosis, perivascular lymphocytic infiltrate of lymphocytes and eosinophils. DIF: intermittent linear IgG and C3 at DEJ	n/a	10	Held (indefinitely)	Oral prednisone	Complete response	n/a	
Current report	87	M	Urothelial cell	Atezolizumab	HE: Subepidermal paucicellular blister DIF: IgG and C3 at DEJ	BP230 level: 13 BP180 level: 22	18	Held and recontinued	Doxycycline, niacinamide, clobetasol ointment	Complete response	Partial response	

Abbreviations: NSCLC: non-small cell lung cancer, n/a: not available, AML: acute myeloid leukemia, CS: corticosteroids, DEJ: dermal-epidermal junction.

