

UC Davis

UC Davis Previously Published Works

Title

A Combination Flap for Repair of Eclabium

Permalink

<https://escholarship.org/uc/item/854342g8>

Journal

Dermatologic Surgery, 45(2)

ISSN

1076-0512

Authors

Joo, Jayne S
Petukhova, Tatyana
Eisen, Daniel B

Publication Date

2019-02-01

DOI

10.1097/dss.0000000000001254

Peer reviewed

A Combination Flap for Repair of Eclabium

JAYNE S. JOO, MD,*† TATYANA PETUKHOVA, MD, MS,* AND DANIEL B. EISEN, MD*

The authors have indicated no significant interest with commercial supporters.

A 79-year-old man with a biopsy-proven melanoma in situ on the left apical triangle of the lip underwent slow Mohs surgery for definitive treatment. After 5 layers, no residual tumor was seen but a portion of the epidermis was missing. At that time, the defect involved his left nasal sidewall, medial cheek, and upper lip. The patient departed for his native Australia with the resulting defect unrepaired. His plan

was to have the surgery done by another physician while being there. He returned 6 weeks later having not had a chance to seek medical care. The defect healed fully by secondary intention, resulting in eclabium (Figure 1). A sixth and final layer was obtained from the nasal sidewall, which healed uneventfully, but the patient was bothered by the distortion of his lip. How would you repair this distortion?

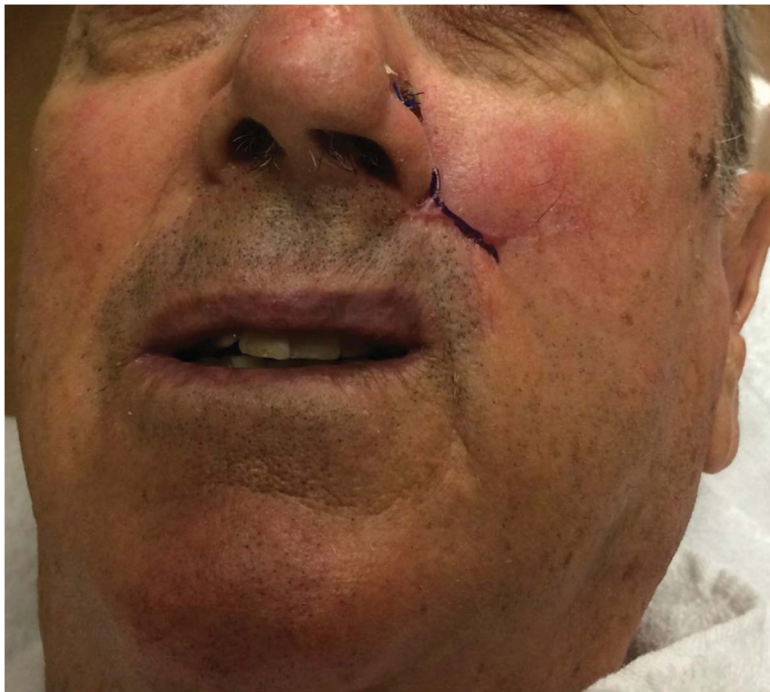

Figure 1. Eclabium resulting from unintended secondary intention healing after slow Mohs surgery. The gentian violet markings indicate the course of the scar.

*Department of Dermatology, University of California, Davis, Sacramento, California; †Dermatology Service, Sacramento VA Medical Center, Sacramento, California

© 2017 by the American Society for Dermatologic Surgery, Inc. Published by Wolters Kluwer Health, Inc. All rights reserved.
ISSN: 1076-0512 • Dermatol Surg 2017;0:1-3 • DOI: 10.1097/DSS.0000000000001254

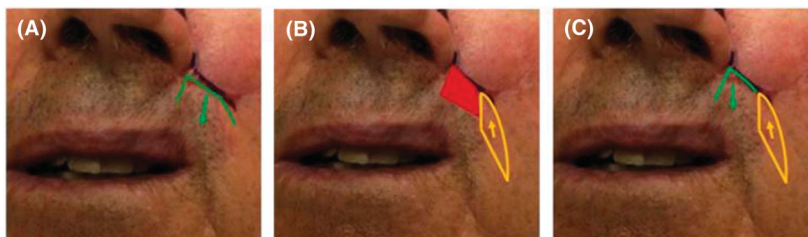


Figure 2. Incision along the left melolabial fold and an adjacent incision at a point about halfway down the lip (green line) to release the upward pull on the left upper lip vermilion (A) combined with an inferolaterally based V-Y advancement flap designed with its superior border along the melolabial fold (orange line) to fill the triangular-shaped defect (red) resulting from release of tension on the upper lip (B). (C) Combination of these 2 flaps. Arrows indicate the direction of movement of tissue.

Resolution

Restoration of form and function underlie the basic principle of lip reconstruction.^{1,2} Eclabium often occurs as a complication from poorly designed flaps or secondary intention healing of the upper cutaneous lip at or near the vermilion border.²⁻⁴ In the case presented here, the patient's eclabium resulted from wound contraction at a distant site. Conventional techniques for correcting eclabium of the vermilion include Z-plasty, V-Y advancement flap and pendulum flap, and have most often been described with reference to cleft lip repair in plastic surgery literature.² Z-plasty is the workhorse flap for correcting distortion of the vermilion or realigning any step-off of the vermilion border.² However, Z-plasty is typically performed along the course of scars. In our situation, the scar was not adjacent to the lip and it was not clear that a Z-plasty in that location would move the tissue in the desired location. Although one can accurately predict the lengthening of the scar that will result by changing the Z-plasty angles, the exact degree of tissue displacement is less predictable and may be less than calculated.⁵

Another option would have been a V-Y advancement flap based directly above the eclabium. However, this would require tissue laxity at the patient's upper cutaneous lip and medial cheek areas to close the defect resulting from movement of the flap inferiorly. Given the presence of significant tissue contraction and hypertrophic scarring in these locations, this was deemed unlikely to be successful.

Here, we describe an eclabium repair using a combination of an inferiorly based unilateral retrograde

advancement flap (to release the tension and to return the vermilion lip to its original location) and an inferolaterally based V-Y advancement flap to repair the resulting defect. This approach has the advantage of not displacing the superior melolabial fold, keeping many of the incisions along the melolabial fold, and easing the design of the repair.

Procedure

The scar was incised along the melolabial fold and an adjacent incision was made in an inferior vertical direction to a point about halfway down the lip (Figure 2A).

The flap was widely undermined and the lip was moved inferiorly until the eclabium was resolved. A V-Y advancement flap originating inferolaterally to the defect was designed with its superior border

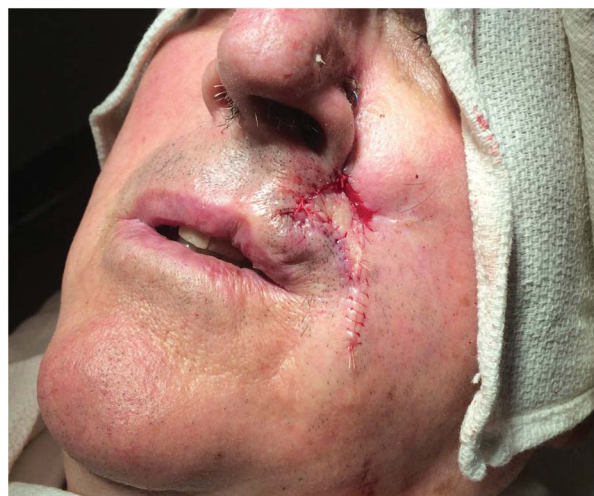

Figure 3. Immediate postoperative photograph of combined inferiorly based unilateral retrograde advancement flap and inferolaterally based V-Y advancement flap.

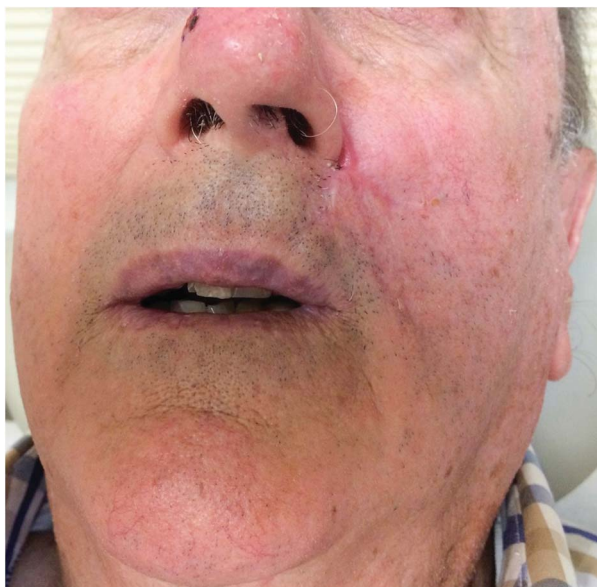

Figure 4. Two months postoperative photograph. Note that the hypertrophic scar in the apical triangle was present before the procedure as seen in Figure 1. Future treatment with intralesional triamcinolone is planned to address that.

positioned along the melolabial fold. The flap was sized to fill the triangular-shaped defect that resulted from the previously accomplished retrograde lip advancement flap (Figure 2B).

After hemostasis was attained, the flap was mobilized and positioned within the defect. Intradermal buried mattress sutures using 5-0 polydioxanone were placed to keep the flap in place and approximate the wound edges of the secondary defect. Both the flap and secondary defect wound edges were further approximated and everted with simple running cuticular sutures using 5-0 fast absorbing gut (Figure 3). A firm pressure dressing was done over petrolatum ointment and a nonstick bandage.

The patient was seen 2 months postoperatively with resolution of the vermilion retraction and acceptable cosmetic outcome (Figure 4). The leading edge of the flap healed with some mild hypertrophic scarring, the cause of which is most likely multifactorial but may have been avoided with greater flap mobilization to reduce tension at the tip. Intralesional triamcinolone injections have been

planned in the future to address this hypertrophic scar as well as the one present at the apical triangle which was present before the eclabium correction but was believed to be best tended to nonsurgically at a later time.

With eclabium, the goal of scar revision surgery is to restore normal appearance. The resultant defect after scar release is in direct proportion to the degree of tension. For the upper lip, this defect can be repaired with relative ease because of the adjacent tissue reservoir from the medial cheek and the melolabial fold within which to camouflage the scar.

Conundrum Keys

- (1) Maintaining the aesthetic integrity of the lip is of fundamental importance in reconstruction after Mohs micrographic surgery.
- (2) Iatrogenic eclabium can be repaired with relative ease using a variety of scar revision techniques. Commonly used procedures include Z-plasty and V-Y advancement flap.
- (3) A combination of 2 advancement flaps (unilateral and V-Y) may have the advantage of hiding the scar along the melolabial fold and maintains simplicity of design.

References

1. McCarn KE, Park SS. Lip reconstruction. *Facial Plast Surg Clin North America* 2005;13:301-14, vii.
2. Leake DS, Baker SR. Chapter 27 (Scar revision and local flap refinement). In: *Local Flaps in Facial Reconstruction* (3rd ed). Philadelphia, PA: Elsevier/Saunders; 2014; pp. 732-4.
3. Becker GD, Adams LA, Levin BC. Outcome analysis of Mohs surgery of the lip and chin: comparing secondary intention healing and surgery. *Laryngoscope* 1995;105:1176-83.
4. Leonard AL, Hanke CW. Second intention healing for intermediate and large postsurgical defects of the lip. *J Am Acad Dermatol* 2007;57: 832-5.
5. Aasi SZ. Z-plasty made simple. *Dermatol Res Pract* 2010;2010:982623.

Address correspondence and reprint requests to: Jayne S. Joo, MD, Department of Dermatology, University of California, Davis Health System, 3301 C Street, Suite 1400, Sacramento, CA 95816, or e-mail: jsjoo@ucdavis.edu